

Radiosynovectomy of Proximal Interphalangeal Joint Synovitis in Rheumatoid Arthritis Treated with Rhenium-188 Labeled Tin-colloid and Imaging with Single-photon Emission Computerized Tomography/Computed Tomography: A First Case Report

Koramadai Karuppusamy Kamaleshwaran, Venkataraman Rajamani¹, Boopathi Krishnan², Madhav Mallia³, Radhakrishnan Kalarikal, Vyshakh Mohanan, Ajit Sugunan Shinto

Departments of Nuclear Medicine and PET/CT, ¹Rheumatology and ²Orthopedics, Kovai Medical Center and Hospital Limited, Coimbatore, Tamil Nadu, ³Radiopharmaceuticals Chemistry Section, Bhabha Atomic Research Centre, Mumbai, Maharashtra, India

Abstract

Rheumatoid arthritis (RA) is a chronic disease that is mainly characterized by the asymmetric erosive synovitis, particularly affecting peripheral joints. Radiation synovectomy or radiosynovectomy (RSV), also known as radiosynoviorthesis was first described in 1950's as an adjuvant treatment for RA. RSV is based on the irradiation of the joint synovium by the intra-articular administration of various β -emitting radiopharmaceuticals. As a generator-produced β -emitting radionuclide, the importance of rhenium-188 (Re-188) for radionuclide therapy is increasing rapidly. There are previous reports which used Re-188 tin colloid in knee joint synovitis, but use of Re-188 tin colloid in small joint is not yet reported. We describe the use of Re-188 tin colloid in a 45-year-old female who presented with right 4th proximal interphalangeal joint synovitis due to rheumatoid arthritis.

Keywords: Radiosynovectomy, rhenium-188 tin colloid, small joint, single-photon emission computerized tomography/computed tomography

Introduction

Rheumatoid arthritis (RA) is a chronic, progressive, inflammatory joint disorder, the primary treatment for which consists of medical regimens aimed at controlling synovial inflammation of the joint.^[1] Radiation synovectomy (RSV) involving a radiopharmaceutical injection into the joint. Its intention is to destroy the inflamed synovium, in the expectation that the regenerated synovium will be disease-free, and the symptoms

will thereby be alleviated.^[2] Rhenium-188 (Re-188) is considered to be a promising radionuclide for use in RSV of joints owing to its favorable decay characteristics. Re-188 is readily available on routine bases from the tungsten-188/Re-188 generator system,^[3] which has a useful shelf-life of several months. Re-188 tin colloid RSV is a useful treatment modality in patients with chronic inflammatory knee joint conditions refractory to conventional treatment.^[4] We describe the first case of application of Re-188 tin colloid in the treatment of small joint synovitis in RA.

Case Report

A 45-year-old female patient, on treatment for RA, presented with right 4th proximal interphalangeal (PIP) joint pain and swelling [Figure 1] for duration of 6 months.

Access this article online	
Quick Response Code: 	Website: www.wjnm.org
	DOI: 10.4103/1450-1147.161730

Address for correspondence:

Dr. Koramadai Karuppusamy Kamaleshwaran, Department of Nuclear Medicine, PET/CT and Radionuclide Therapy, Comprehensive Cancer Care Center, Kovai Medical Center and Hospital Limited, Coimbatore - 641 014, Tamil Nadu, India. E-mail: dr.kamaleshwar@gmail.com

She was treated with antirheumatoid drugs and had no symptom relief. She was referred for three-phase bone scintigraphy and RSV. Blood pool images [Figure 2a] and delayed images [Figure 2b] show increased blood pooling and uptake in the right 4th PIP joint consistent with synovitis. RSV injection was performed according to EANM guidelines.^[5] RSV was performed with precise intra-articular injection of a typical dose of 370 MBq Re-188 tin colloid under sterile conditions and fluoroscopic guidance. Before joint puncture, local anesthesia was administered with 2% lidocaine hydrochloride. Prior to the injection of Re-188 tin colloid, Depo Medrol (10 mg in 0.2 mL) was injected into the joint in order to reduce the risk of acute radiation-induced synovitis and to avoid skin radiation necrosis. Subsequently, 370 MBq dispersed in 0.5 mL of sterile, apyrogenic normal saline was administered intra-articularly into ankle, subtalar and calcaneocuboid joint and then the needle was flushed with 0.3 mL of normal saline. Arthrography was performed to check the correct location. An orthopedic bandage was applied as a semi-rigid splint. Images were acquired in a dual head γ camera (Siemens Symbia True point) in the high energy general purpose collimator with 155 ± 20 KeV. Re-188 tin colloid single-photon emission computerized tomography/computed tomography images [Figure 3] showed good distribution of the tracer in the right 4th PIP joint. Her finger was immobilized for 48 h. On the follow-up, after 3 months, pain and swelling of the joint decreased significantly.

Discussion

Radiation synovectomy is a local intra-articular injection of radionuclides in colloidal form. RSV may relieve synovitis, joint pain, knee flexibility, and joint effusion in about 60–80% of the cases.^[6] First used by Fellingner and Schmid^[7] in 1952, the technique has been applied for over 50 years in the treatment of resistant synovitis in individual joints after the failure of long-term systemic pharmacotherapy and intra-articular steroid injections. Radioisotopes with emission of β radiation have the capacity to diminish the inflammatory process and ablate the inflamed synovial membrane (pannus) with subsequent fibrosis. Three radionuclides are currently in use: Yttrium-90 (Y-90 silicate/citrate), rhenium-186 (sulfide), and erbium-169 (citrate), which have been indicated for large, medium, and small joints, respectively.^[8]

Rhenium-188 is an attractive radionuclide for RSV because of its suitable chemistry, $t_{1/2} = 16.9$ h and average β energy of 776 keV ($E_{\max} = 2.11$ MeV, 79%). These properties enable ankle treatment due to its maximal tissue penetration of 11 mm, and its mean range of 3.8 mm.^[9] Re-188 decays to the stable Osmium-188, with a γ ray emission of 155 KeV (15%) that is suitable for image acquisition. Leakage has been particularly difficult to quantify

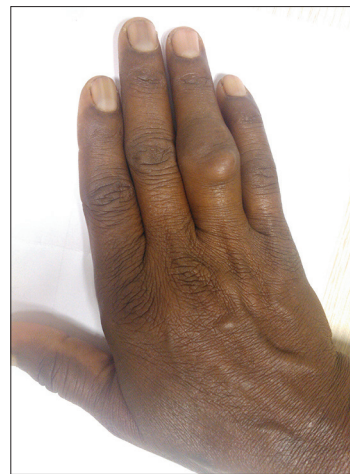


Figure 1: Picture showing swelling in the right 4th proximal interphalangeal joint

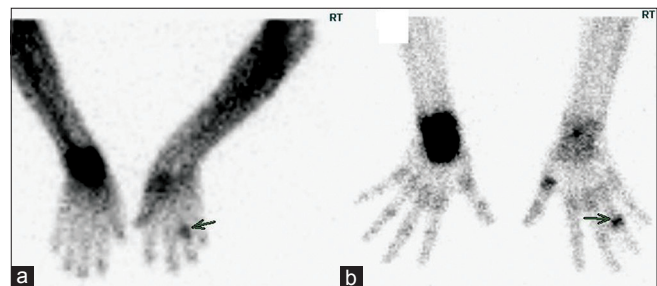

Figure 2: Anterior and posterior blood pool images (a) and delayed images (b) demonstrates increased blood pool concentration and uptake in right 4th proximal interphalangeal joint consistent with synovitis (arrows)

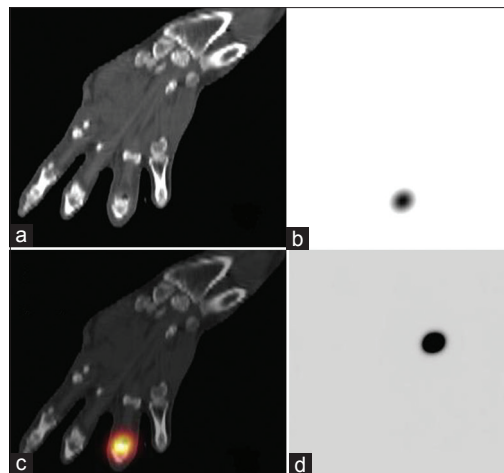


Figure 3: Coronal computed tomography (a), single-photon emission computerized tomography (b), fused single-photon emission computerized tomography/computed tomography (c) and maximum intensity projection image (d) rhenium-188 tin colloid images of hand showing good tracer distribution in the right 4th proximal interphalangeal joint

where the isotope used was Y-90 or P-32, radioisotopes which are both pure β emitters with no accompanying γ emissions that might be used to quantify biodistribution

and dosimetry. This fact allows target uptake evaluation, as well as the estimation of the absorbed radiation dose. Besides this, Re-188 is readily available on routine bases from the tungsten-188/Re-188 generator system which has a useful shelf-life of several months.^[3,9]

Rhenium-188 tin colloid can be potentially used as an ideal agent for RSV of the joints. Weigh approximately 30 mg of stannous chloride in a clean vial. Add the required quantity of sterile water for injection such that the final concentration is of stannous solution is 20 mg/mL. Add 0.5 mL of required amount of Re-188 activity into a clean vial containing 0.5 mL of freshly prepared stannous chloride solution. Mix the solution well, cap the vial and then heat it at 100°C for 2 h. After cooling, add the required amount of 0.2 M phosphate buffer to adjust pH of the final preparation to 8. As per the limited number of stability and animal studies performed by the scientists, it has been observed that Re-188 tin colloid is highly stable, and leakage from the synovial site is negligible compared to Re-188 sulfur colloid.^[10] Study by Savio *et al.*^[11] and Jeong *et al.*^[12] concluded that Re-188 Sn colloid could be selected as the best formulation for synovectomy therapy taking into account ease of labeling procedure, kit formulation, minimum facilities required, suitable physical and biological characteristics, and the lowest absorbed dose for the patient. Because of this, the highest benefit/risk relation was found for Re-188 Sn in comparison with Re-188 ferric hydroxide macro aggregates coated with tin colloid and Re-188 hydroxyapatite particles. In a study by Shin *et al.*,^[13] Ovalbumin-induced arthritic rabbits, the Re-188 tin colloid improved the macroscopic, the histological score and reduced the knee joint diameter when compared to the arthritic control.

Conclusion

A Re-188 tin colloid is considered as a strong candidate for RSV with a superior efficacy and safety.

Lee *et al.* performed first human study of RSV using Re-188 tin colloid in 22 knees from 21 RA patients refractory to intra-articular corticosteroid injection.^[14] No clinical side effects or abnormalities in leukocyte count, platelet count, liver function tests or urine analysis were observed in any patient. In conclusion, in that first study of RSV using Re-188 tin colloid for patients with RA, the treatment resulted in the improvement of arthritis and was well-tolerated. Shin *et al.* showed RSV using Re-188 tin colloid in refractory RA patients improved magnetic resonance imaging findings as well as clinical parameters.^[15] Shamim *et al.*^[4] studied 61 knee joints in 48 patients with chronic synovitis caused by various inflammatory knee joint diseases refractory to conventional therapy. They concluded Re-188 tin colloid RSV is a useful treatment modality in patients with chronic inflammatory knee joint conditions refractory to conventional treatment. Patients with shorter duration of disease, normal or minor

X-ray findings, little or no swelling, mild tenderness, and better mobility are better candidates for RSV. Hence, till now, all studies were done on knee synovitis. Our case describes the use of Re-188 tin colloid in small joint synovitis and our patient has good response to therapy.

References

- Zuckerman JD, Sledge CB, Shortkroff S, Venkatesan P. Treatment of rheumatoid arthritis using radiopharmaceuticals. *Nucl Med Biol* 1987;14:211-8.
- Schneider P, Farahati J, Reiners C. Radiosynovectomy in rheumatology, orthopedics, and hemophilia. *J Nucl Med* 2005;46 Suppl 1:48S-54.
- Kamioki H, Mirzadeh S, Lambrecht RM, Knapp FF Jr, Dadachova K. 188W/188 Re generator for biomedical applications. *Radiochim Acta* 1994;65:39-46.
- Shamim SA, Kumar R, Halanaik D, Kumar A, Shandal V, Shukla J, *et al.* Role of rhenium-188 tin colloid radiosynovectomy in patients with inflammatory knee joint conditions refractory to conventional therapy. *Nucl Med Commun* 2010;31:814-20.
- Clunie G, Fischer M. EANM procedure guidelines for radiosynovectomy. *Eur J Nucl Med Mol Imaging* 2003;30:BP12-6.
- Kampen WU, Brenner W, Kroeger S, Sawula JA, Bohuslavizki KH, Henze E. Long-term results of radiation synovectomy: A clinical follow-up study. *Nucl Med Commun* 2001;22:239-46.
- Fellinger K, Schmid J. Local therapy of rheumatic diseases. *Wien Z Inn Med* 1952;33:351-63.
- Deutsch E, Brodack JW, Deutsch KF. Radiation synovectomy revisited. *Eur J Nucl Med* 1993;20:1113-27.
- Wang SJ, Lin WY, Hsieh BT, Shen LH, Tsai ZT, Ting G, *et al.* Rhenium-188 sulphur colloid as a radiation synovectomy agent. *Eur J Nucl Med* 1995;22:505-7.
- Ures M, Savio E, Malanga A, Fernández M, Paolino A, Gaudiano J. Physico-chemical characterisation and biological evaluation of 188-Rhenium colloids for radiosynovectomy. *BMC Nucl Med* 2002;2:1.
- Savio E, Ures MC, Zeledón P, Trindade V, Paolino A, Mockford V, *et al.* 188Re radiopharmaceuticals for radiosynovectomy: Evaluation and comparison of tin colloid, hydroxyapatite and tin-ferric hydroxide macroaggregates. *BMC Nucl Med* 2004;4:1.
- Jeong JM, Lee YJ, Kim YJ, Chang YS, Lee DS, Chung JK, *et al.* Preparation of rhenium-188-tin colloid as a radiation synovectomy agent and comparison with rhenium-188-sulfur colloid. *Appl Radiat Isot* 2000;52:851-5.
- Shin CY, Son M, Ko JI, Jung MY, Lee IK, Kim SH, *et al.* DA-7911, 188Rhenium-tin colloid, as a new therapeutic agent of rheumatoid arthritis. *Arch Pharm Res* 2003;26:168-72.
- Lee EB, Shin KC, Lee YJ, Lee YJ, Cheon GJ, Jeong JM, *et al.* 188Re-tin-colloid as a new therapeutic agent for rheumatoid arthritis. *Nucl Med Commun* 2003;24:689-96.
- Shin K, Lee JC, Choi HJ, Jeong JM, Son M, Lee YJ, *et al.* Radiation synovectomy using 188Re-tin colloid improves knee synovitis as shown by MRI in refractory rheumatoid arthritis. *Nucl Med Commun* 2007;28:239-44.

How to cite this article: Kamaleshwaran KK, Rajamani V, Krishnan B, Mallia M, Kalarikal R, Mohanan V, *et al.* Radiosynovectomy of Proximal Interphalangeal Joint Synovitis in Rheumatoid Arthritis Treated with Rhenium-188 Labeled Tin-colloid and Imaging with Single-photon Emission Computerized Tomography/Computed Tomography: A First Case Report. *World J Nucl Med* 2015;14:216-8.

Source of Support: Nil, **Conflict of Interest:** None declared.