



# Allogeneic Ex Vivo Expanded Corneal Epithelial Stem Cell Transplantation: A Randomized Controlled Clinical Trial

JOHN D.M. CAMPBELL<sup>1</sup>,<sup>a</sup> SAJJAD AHMAD,<sup>b</sup> ASHISH AGRAWAL,<sup>c</sup> CAROL BIENEK,<sup>a</sup> ANNE ATKINSON,<sup>a</sup> NEIL W.A. MCGOWAN,<sup>a</sup> STEPHEN KAYE,<sup>b</sup> SANJAY MANTRY,<sup>d</sup> KANNA RAMAESH,<sup>d</sup> ALISON GLOVER,<sup>a</sup> JANE PELLY,<sup>a</sup> CORAL MACRURY,<sup>a</sup> MARGARET MACDONALD,<sup>c</sup> EMILY HARGREAVES,<sup>a</sup> JACQUELINE BARRY,<sup>a</sup> JOHN DRAIN,<sup>a</sup> BRUCE CUTHBERTSON,<sup>a</sup> LOUIS NERURKAR,<sup>e</sup> IAN DOWNING,<sup>a</sup> ALASDAIR R. FRASER,<sup>a</sup> MARC L. TURNER,<sup>a</sup> BALJEAN DHILLON<sup>c</sup>

**Key Words.** Allogeneic corneal epithelial stem cell transplantation • Limbal stem cell deficiency • Ocular surface disorders

<sup>a</sup>Scottish National Blood Transfusion Service, Edinburgh, United Kingdom; <sup>b</sup>Royal Liverpool and Broadgreen University Hospitals, St. Paul's Eye Unit, Liverpool, United Kingdom; <sup>c</sup>Princess Alexandra Eye Pavilion, Edinburgh, United Kingdom; <sup>d</sup>Tennent Institute of Ophthalmology, Gartnavel General Hospital, Glasgow, United Kingdom; <sup>e</sup>Institute of Infection, Immunity, and Inflammation, University of Glasgow, Glasgow, United Kingdom

Correspondence: John D.M. Campbell, Ph.D., Advanced Therapeutics, Scottish National Blood Transfusion Service, The Jack Copland Centre, 52 Research Avenue North, Heriot Watt Research Park, Edinburgh EH14 4BE, United Kingdom. Telephone: +44 131 314 5677; e-mail: johncampbell3@nhs.net

Received June 29, 2018; accepted for publication December 3, 2018; first published January 28, 2019.

<http://dx.doi.org/10.1002/sctm.18-0140>

This is an open access article under the terms of the Creative Commons Attribution-NonCommercial-NoDerivs License, which permits use and distribution in any medium, provided the original work is properly cited, the use is non-commercial and no modifications or adaptations are made.

## ABSTRACT

Limbal stem cell deficiency (LSCD) is a disease resulting from the loss or dysfunction of epithelial stem cells, which seriously impairs sight. Autologous limbal stem cell transplantation is effective in unilateral or partial bilateral disease but not applicable in total bilateral disease. An allogeneic source of transplantable cells for use in total bilateral disease can be obtained from culture of donated cadaveric corneal tissue. We performed a controlled multicenter study to examine the feasibility, safety, and efficacy of allogeneic corneal epithelial stem cells in the treatment of bilateral LSCD. Patients were randomized to receive corneal epithelial stem cells cultured on amniotic membrane (AM): investigational medicinal product (IMP) or control AM only. Patients received systemic immunosuppression. Primary endpoints were safety and visual acuity, secondary endpoint was change in composite ocular surface score (OSS). Sixteen patients were treated and 13 patients completed all assessments. Safety was demonstrated and 9/13 patients had improved visual acuity scores at the end of the trial, with no significant differences between IMP and control groups. Patients in the IMP arm demonstrated significant, sustained improvement in OSS, whereas those in the control arm did not. Serum cytokine levels were measured during and after the period of immune suppression and we identified strongly elevated levels of CXCL8 in the serum of patients with aniridia, which persisted throughout the trial. This first randomized control trial of allogeneic corneal epithelial stem cells in severe bilateral LSCD demonstrates the feasibility and safety of this approach. *STEM CELLS TRANSLATIONAL MEDICINE* 2019;8:323–331

## SIGNIFICANCE STATEMENT

This first randomized control trial of allogeneic corneal epithelial stem cells on amniotic membrane in severe bilateral limbal stem cell deficiency demonstrates the feasibility and safety of this approach. The fully controlled trial, including a control product and use of immune suppression in both arms, allowed definitive measurement of the effects of the stem cell-containing-product. There was evidence of sustained improvement in ocular surface score in the stem cell arm and some evidence of improved visual acuity in both arms. Studies examining specific etiologies of LSCD will further define the role of this technique in treating severe bilateral disease.

## INTRODUCTION

The surface of the cornea is maintained by corneal epithelial stem cells located in the transition zone between the cornea and conjunctiva—the limbus [1, 2]. Limbal stem cell deficiency (LSCD) is an irreversible disease resulting from the loss or dysfunction of these epithelial stem cells. The corneal epithelium becomes deficient and is

replaced by the surrounding conjunctival epithelium, resulting in a thickened, irregular, unstable epithelium, often with secondary neovascularization, and inflammation [3]. LSCD causes severe ocular surface disease (OSD) characterized by reduced vision or blindness, chronic ocular irritation, and glare [3]. LSCD can be differentiated into two etiological subcategories [4]. Category 1—aplasia or destruction of limbal stem cells

from chemical and thermal burns. Category 2—loss of limbal stem cell function due to insufficient stromal support and includes aniridia, multiple endocrine deficiency syndrome.

Standard corneal transplantation is not an effective treatment for LSCD. Several case series have provided evidence that grafting viable whole limbal tissue, either from the fellow healthy eye [5] or donor eye [6], may replenish the host corneal epithelium. Large autologous limbal grafts, however, may compromise the healthy donor eye, whereas large allogeneic donor grafts often fail despite immune suppression. Smaller limbal tissue quantities can potentially reduce these limitations and advances in tissue engineering techniques can provide ex vivo expanded autologous or allogeneic corneal epithelium [7–9] with a success rate of approximately 76% in LSCD [9]. Many studies have been published but these form discrete data sets [10–20]. A recent review of the field indicates 9 published uses of allogeneic donated material for treating LSCD in approximately 80 patients [20]. However, this is not a coherent body of data, with cadaveric and living related donors; differing culture methods; variable follow-up times, some of less than 1 year; and great variability in success criteria. Critically none of the allogeneic studies have contained a control arm against which results can be compared. Frequently the studies are single-center due to logistics of transporting clinical grade ex vivo expanded corneal epithelial stem cells. Critically, it is not clear whether the clinical outcome of LSC replacement is independent of biological effect(s) of concomitant surgical pannus excision, amniotic membrane (AM) resurfacing, and immunosuppression. Therefore, our study aimed to address the following. (a) Manufacture of allogeneic ex vivo expanded corneal epithelial stem cells on AM at Good Manufacturing Practice (GMP) standard. (b) A randomized controlled study to investigate safety and efficacy of this investigational medicinal product (IMP). The clinical trial was designed as a randomized, controlled, and partially blinded phase I/II trial and hypothesized that the use of AM, topical autologous serum eye drops and systemic immunosuppression, may have therapeutic benefit. By this highly controlled design it was anticipated that true effects of stem cells in the IMP would be quantified.

## MATERIALS AND METHODS

### Trial Ethics and Review Board Approval

The protocol was approved by SNBTS, and was reviewed and approved by the Lothian Research Ethics Committee June 22, 2011 REC 14/ES/1008. The study was conducted in accordance with the requirements of the International Conference on Harmonization for Good Clinical Practice (GCP) Tripartite Guideline. The study was performed under a Medicines and Healthcare Products Regulatory Agency's Clinical Trials Authorization, Eudract Number 2010-024409-01.

The trial results are now in the public domain: <https://www.clinicaltrialsregister.eu/ctr-search/trial/2010-024409-11/results>

### GMP Manufacturing of Corneal Epithelial Stem Cell Product

All study materials were prepared in strict compliance with EU GMP as defined in Directive 2003/94/EC under the SNBTS Manufacturer's Authorization for Investigational Medicinal Products (MIA [IMP], 3473).

### Eye Tissue

Eyes were procured from deceased donors under appropriate organ and tissue donation consent within 24 hours of death and sent to either the Manchester or Bristol Eye Banks. All donors were virology tested at the NHS Blood and Transplant (NHSBT) National Transfusion Microbiology Reference Laboratory according to the requirements of the Human Tissue (Quality and Safety for Human Application) Regulations 2007.

### Manufacture of the IMP and Control Product

Culture medium was High Glucose Dulbecco's modified Eagle's medium: Hams F12 at a 3:1 ratio (PAA, Pasching, Austria or Life Technologies, Paisley, UK), supplemented to a final concentration of 10% human AB serum (SNBTS), 0.4 µg/ml hydrocortisone (Efcortisol, Sovereign Medical, Basildon, UK), 0.13 IU/ml insulin (Humulin S: Lilly, Basingstoke, UK), 1.4 ng/ml triiodo-L-thyronine (Goldshield Pharmaceuticals, Croydon, UK)—all clinical grade, plus 33 µg/ml adenine (Sigma, Gillingham, UK) and 10 ng/ml epidermal growth factor (Sigma).

The clinical grade AM was supplied frozen by NHSBT, thawed and washed three times with saline and positioned onto an autoclaved glass coverslip, following the method of Kolli et al. [11]. On receipt, the orientation of the cornea was not marked and as such it was not possible to identify superior and inferior regions of the limbus. Explants for culture were taken from adjacent regions on the limbus. Corneal tissues were dissected into explants, so that the dimensions of each explant was ~1 mm by ~2–3 mm (with the longer dimension across the corneal/sclera junction) such that clear corneal and white sclera could be observed macroscopically on each explant and to ensure there was an intact limbal zone centrally. A sample of corneal tissue was also collected for DNA fingerprinting. Up to 5 pieces of dissected limbal tissue, epithelial side up, were evenly distributed over the prepared AM and 1.5 ml of prewarmed culture medium was added to the composite graft. The culture was then incubated at 37°C, 5% CO<sub>2</sub> with media changes every 2–3 days for 12–19 days until the culture showed outgrowth from the limbal explants measuring ≥200 mm<sup>2</sup>. Multiple cultures were generated from each donated tissue.

### Control and Distribution of IMP and Control Product

During process validation, test cultures were assessed for shelf life as follows: at the end of the culture period when outgrowth had reached ≥200 mm<sup>2</sup>, the culture was fed with fresh media (2.5 ml), then sealed with sanitized parafilm and the shelf-life assessed by incubating the cultures at 18°C–24°C in a Medibox Lite Portable transport container (Abacus Instruments Ltd.) for 8 or 24 hours. Two of the cultures used for the 24 hours shelf-life assessment also included a period with transport simulation (the culture was placed on a see-saw rocker (Stuart) within a controlled temperature incubator (RS Biotech 170R) for up to 9–10 hours). At the end of the shelf-life period under assessment, outgrowth regions of each culture (~3 mm × 4 mm) were dissected and fixed in 4% formaldehyde in phosphate-buffered saline (PBS) then assessed for morphological integrity by H&E stain, expression of the epithelial stem cell marker p63 (clone 4A4 recognizes all isoforms of p63—TN and deltaN) and the corneal epithelial marker cytokeratin 3 (CK3) by immunohistochemical analysis as detailed below.

**Table 1.** Patient cohort

Patient number (from study)	Sex	Age	Unilateral (U) or bilateral (B) disease	Diagnosis	Product received	Treatment site
2	F	50	B	Aniridia	IMP	E
3	M	57	B	Pemph	IMP	G
4b	M	48	B	Aniridia	C	E
5a	F	49	B	CI	IMP	G
7	M	20	U	CI	IMP	G
8	M	74	B	CI	C	L
9	F	28	B	CTD	IMP	G
10	M	50	B	CI	C	L
11	M	37	B	CI	C	E
12	F	51	B	Aniridia	IMP	G
13	M	51	B	Aniridia	IMP	L
14a	F	48	B	CI	C	L
15b	M	49	B	Aniridia	IMP	E
16	M	49	B	CI	C	L
17	F	59	B	CI	IMP	L

<sup>a</sup>Did not complete 18 months follow-up and are excluded from vision and OSS analysis.

<sup>b</sup>Patients 4 and 15 are same individual.

Abbreviations: Pemph, ocular cicatricial pemphigoid; CTD, connective tissue disorder; CI, chemical injury; E, Edinburgh; G, Glasgow; L, Liverpool.

During the clinical trial, replicate (normally duplicate) composite cultures were prepared. On the planned release day, the culture to be transplanted was fed with 2.5 ml fresh medium and dishes sealed for transport using sanitized parafilm. Unused replicate culture(s) were retained for QC analysis. The released product was transferred to the operating theater at 18°C–24°C in a Medibox Lite Portable transport container (Abacus Instruments Ltd.) and retained until use. The culture media was removed then the composite graft and was rinsed with sterile balanced salt solution (Alcon) before transplantation. Surgery was performed in Edinburgh, Glasgow, or Liverpool at the institutions listed in the author addresses. Control product for transplantation was prepared as above, without addition of limbal tissue and cultured for 10–14 days.

#### Quality Control of Product—Immunohistochemistry

The immunohistochemistry testing was performed as part of the routine service provided by the Department of Pathology, University of Edinburgh. Briefly, QC samples were placed in 4% formaldehyde in PBS. The samples were stained for the epithelial stem cell marker p63 (clone 4A4 recognizes all isoforms of p63—TN and deltaN—Abcam cat no. P3737) and the corneal epithelial marker cytokeratin 3 (CK3) following the methods of Kolli et al. [11] using an HRP polymer-based detection on Leica Bond Max staining robots. Visualization was with DAB and Hematoxylin counterstain. Staining levels were reported by an independent pathologist.

#### Patient Cohort

Patient characteristics are detailed in Table 1.

#### Autologous Serum Eye Drops

Trial patients donated a unit of whole blood under SNBTS Blood Establishment Authorization before commencement of the study. Serum was collected by SNBTS Component Manufacturing and preservative-free serum eye drops were manufactured under NHSBT MHRA Specials license. Patients administered drops to the affected eye daily as required throughout the trial and compliance with the regimen was checked at each clinical visit.

#### Clinical Study Design

The study was a single-blind, randomized control clinical study designed to treat 20 patients in 2 groups. Randomization method is described in supplementary information. Patients were randomized to receive either allogeneic corneal epithelial stem cells on AM or AM only. Both groups were given autologous serum eye drops and immunosuppressive medication. Inclusion and exclusion criteria are detailed in Supporting Information S1. The primary endpoint was feasibility and safety and the primary efficacy variable was Best Corrected Visual Acuity. The secondary efficacy variables were: Ocular Surface Score (OSS—see below) and Quality of Life (QoL) as assessed by questionnaires VF14, SF36 [21, 22]. Engraftment of donor cells was assessed by impression cytology and cytogenetics.

Patients were clinically assessed preoperatively and then at days 1, 2–3, 7, and 14, and at 1, 3, 6, 9, 12, 15, and 18 months postoperatively with the following investigations taken: full blood count, liver function tests, urea and electrolytes, serum for cytokine analysis, evaluation of corneal vascularization, visual acuity (all time points). DNA fingerprinting of corneal epithelium (duplicate cultures from manufacturing and corneal impression samples), using the DNA fingerprinting method described in references 12, 13, and QoL (VF14 and SF36) assessments were carried out at 6, 12, and 18 months postoperatively.

#### Treatment Administration and Surgical Technique

The surgical technique was discussed by the ophthalmic surgeons from the 3 research centers, to develop a consensus describing the standard operating procedure between investigators. All surgeons were experienced consultant corneal specialists and 4 consultant surgeons from the 3 centers were involved in this study. Following a 360° conjunctival peritomy approximately 2–3 mm behind the limbus, a superficial keratectomy was undertaken to remove abnormal superficial tissue over the cornea from the underlying corneal stroma. The composite graft (or control product) was placed upon the exposed corneal stroma with the epithelium facing upward. The graft was sutured to the limbus, and any remnant material retained for immunohistochemical analysis (IMP only). A second AM was placed on top of the first graft and sutured peripherally to the recessed conjunctival edges. A bandage contact lens was then placed upon the ocular surface to help protect the transplanted tissue. All patients received perioperative subconjunctival antimicrobial and steroid injections according to standard of care.

#### Postoperative Treatment

All patients received postoperative topical dexamethasone (pf) 0.1% 2 hourly initially for 2 weeks, and then gradually tapered (QDS for 1 month, TID for 1 month, BD for 1 month and then OD thereafter. The steroids were used for a minimum of 6 months.

In addition, patients utilized autologous serum eye drops for 12 weeks postoperatively. Systemic oral immunosuppression was used as per the protocol for 1 year postsurgical treatment: Prednisolone: initial dose of 60 mg daily tapering at 5 mg weekly until 10 mg maintenance dosage *plus* Cyclosporine: initial dose of 100 mg twice a day then tapered to 50 mg twice a day *or* Mycophenolate mofetil at a dose between 750 mg and 1 g twice a day.

#### Impression Sampling of Corneal Surface

Impression cytology to collect samples for DNA analysis was performed using a Millipore filter paper applicator mounted on a Goldmann tonometer holder (without prism) held against the corneal surface for 2–3 seconds. Samples were collected at 6, 12, and 18 months postsurgery.

#### Safety Assessment

All adverse events (AE) were reported and recorded in accordance with GCP requirements. Patients were monitored for any AE during throughout the study. No AE were attributed to the IMP/control products and no Serious Adverse Reactions were noted throughout the trial.

#### Visual Acuity

Visual acuity was measured in the index eye using a Snellen chart and a LogMAR score allocated as per Supporting Information Table S1.

#### OSS

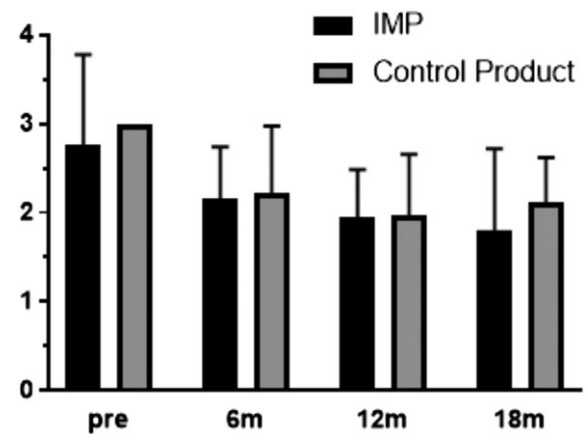
The validated scale described by Shigeru Kinoshita's group [23] was adopted for the ocular surface scoring system. The ocular surface was evaluated using a slit lamp giving consideration to a number of parameters: corneal epithelium, conjunctivalization, corneal neovascularization, corneal opacification and conjunctival hyperemia each of which was scored on a scale of 0 ("normal") to 3 (severe damage). A composite score out of 15 was calculated. The key to the scoring system is given in Supporting Information Table S2.

#### Measurement of Serum Cytokines

Serum cytokine levels were measured throughout the trial in order to monitor the overall immune status of the patients before, during and after the immune suppression treatment associated with this investigation. Patient serum samples were collected at regular intervals and stored at  $-80^{\circ}\text{C}$ . Samples were assayed for TNF- $\alpha$ , IL-1 $\beta$ , IL-2, IL-4, IL-6, IL-8/CXCL8, IL-12 and IFN- $\gamma$  using an eBioscience flow cytometry cytokine bead array kit (ProcartaPlex Human) and a MACSQuant 10 instrument (Miltenyi Biotec). Results were generated against recombinant kit standards and compared against reported normal ranges for these cytokines detailed in reference 24.

#### Statistical Analysis

Patients were grouped according to whether they had received the IMP or control product. Mean changes in vision and combined OSS were compared between the groups at baseline, 6, 12, and 18 months post-treatment. Statistical analysis was carried out using unpaired *t* tests, one-way analysis of variance (ANOVA) and Tukey's post hoc multiple comparison test, as appropriate, using Prism 7 software (details in each section).



**Figure 1.** Mean  $\pm$  SD visual acuity scores in the investigational medicinal product (IMP; black bars) and control (gray) groups pre-treatment and at the 6, 12, and 18 month time points. There is a trend toward reduction (improvement) in scores throughout the study, but this does not reach significance, and there is no difference between the IMP or control groups. Two-way analysis of variance, Tukey's multiple comparisons test. No error bar in "pre" group for control product as all scores were 3 at start of study.

## RESULTS

### Product Manufacture and Quality Control

Definitive proof that implanted grafts all contained LSC is not achievable, as any testing would be destructive. Analysis of remnant material from the 9 transplanted IMPs, showed 5 had cells positive for p63 and 7 had cells positive for CK3 (representative staining Supporting Information Fig. S1). As this is remnant material from the edge of the implanted graft, this is not a definitive proof of LSC content, or lack thereof. Where p63 positive cells were not detected in remnant material from the transplanted product, p63+ cells could always be detected in the duplicate culture, therefore adding weight to the conclusion that it is highly likely that all IMP grafts contained LSC.

### Patient Recruitment

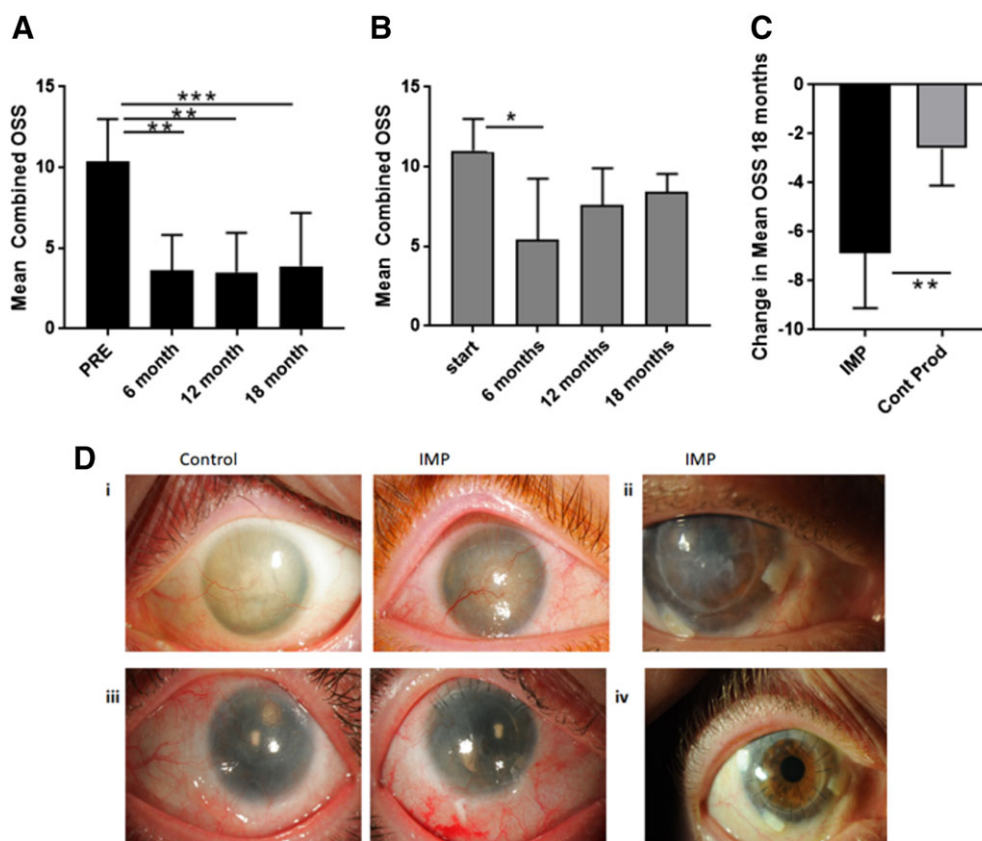
The study was closed at 32 months, due to slow recruitment. A total of 30 patients were screened, with 6 deemed not suitable, 7 declined and the remaining 17 enrolled. A total of 16 out of 17 patients, all with total LSCD, were treated in this study. One patient died of unrelated disease during the trial, and 3 patients withdrew during the study, therefore 13 patients completed all assessments as described in the protocol. Mean age of patients in the IMP ( $44.3 \pm 13$ ) and control ( $52.1 \pm 1.6$ ) groups was not significantly different ( $p = .246$ , unpaired *t* test).

### Safety and Adverse Events

A total of 34 AE were recorded in total throughout the duration of the trial. Raised intraocular pressure was seen in 3 patients (2 from IMP arm and 1 from control). However, these events could have been related to topical steroid use postoperatively. Details of all AEs (serious and nonserious) are described in Supporting Information.

### Visual Acuity

The mean visual acuities in the IMP and control arms were not significantly different at the start of the study (Fig. 1) but 5/8



**Figure 2.** (A): Mean  $\pm$  SD combined ocular surface scores (OSSs) in the investigational medicinal product (IMP) group pretreatment and at the 6, 12, and 18 month time points. Combined OSS is significantly improved (lower) at all time points compared with the beginning of the trial. \*\*,  $p \leq .01$ ; \*\*\*,  $p \leq .001$ . One-way analysis of variance (ANOVA), Tukey's multiple comparisons test. (B): Mean  $\pm$  SD combined OSSs in the control group pretreatment and at the 6, 12, and 18 month time points. Combined OSS is only significantly improved (lower) at 6 months compared with the beginning of the trial and rises to not be significantly different from the start scores by 12 months. \*,  $p \leq .05$ . One-way ANOVA, Tukey's multiple comparisons test. (C): Mean  $\pm$  SD change in combined OSSs in the IMP (black) and control (gray) groups at the end of 18 months follow-up. The mean change in the IMP group is significantly improved (lower) compared with the control product group. \*\*,  $p \leq .01$  unpaired  $t$  test. (D): Representative clinical images from the trial. (Di): Preoperative images from patients before implantation of a control or IMP product. (Dii): Image of IMP product after implantation. (Diii): Eighteen months post-treatment. Both patients underwent cataract surgery at 7 months (control) and 5 months (IMP) postentry to the study. Patient who received IMP shows greater corneal clarity and lower levels of neovascularization. (Div): Image taken 24 months post-LSC graft—the patient received a corneal transplant at 19 months post-IMP—shows a clear corneal transplant which indicates that the limbal epithelium has recovered to maintain corneal clarity.

IMP patients finished the trial with improved visual acuity scores—a mean improvement in LogMAR score of  $-0.957$  compared with the start of the trial. Two patients received cataract operations during the trial, which could have improved their score. The improvement in score from start of trial to end did not reach statistical significance ( $p = .07$ ) due to the standard deviation and the small data set (Fig. 1). Scores at 6 and 12 months compared with day 0 were also improved but not significantly different ( $p = .42$  and  $p = .16$ , respectively).

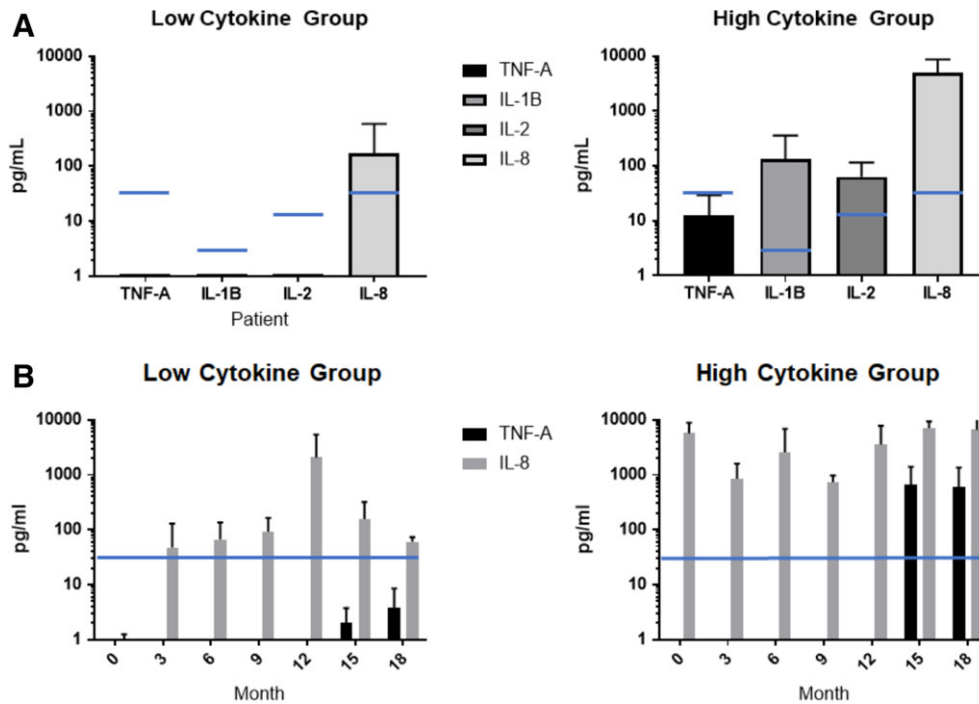
In the control arm, 4/5 patients ended the trial with improved visual acuity scores, mean improvement in LogMAR score was  $-0.888$ . One patient in this group also underwent cataract surgery. The improvement in score from start of trial to end did not reach statistical significance ( $p = .22$ ) due to the due to standard deviation and the small data set (Fig. 1). The mean improvement in visual acuity at 18 months between treatment and control arms did not show a significant difference ( $p = .46$  unpaired  $t$  test).

## OSS

The starting mean combined ocular scores in the IMP (10.38) and control groups (11) were not significantly different ( $p = .65$  unpaired  $t$  test). In the IMP group, the OSS was significantly improved by the 6 month point and remained significantly improved when compared with the starting score at 12 and 18 months ( $p = .0043$ ,  $p = .0018$ ,  $p = .0002$  at 6, 12, and 18 months, respectively (one-way ANOVA Tukey's Multiple Comparisons test; Fig. 2A).

In the control group there was also an initial, significant improvement in scores ( $p = .014$ ) at 6 months, but the effect was not sustained, and the improvement in scores returned to non-significance by 12 and 18 months ( $p = .185$  and  $p = .39$ , respectively; all one-way ANOVA, Tukey's Multiple Comparisons test; Fig. 2B).

All patients showed improved OSSs at conclusion of the trial. Patients who received the IMP showed a significantly higher mean improvement in combined OSSs than those who received the control ( $p = .004$  unpaired  $t$  test) at 18 months



**Figure 3.** (A): Mean serum cytokine levels ( $\pm$ SD) in limbal stem cell deficiency (LSCD) patients at initial screening for entry to the trial. Patients can be grouped as having low serum levels of inflammatory cytokines at study entry (low group,  $n = 7$ ) or high levels (high group,  $n = 8$ ). All aniridia patients are in the high group. Blue line—representative of maximum reported normal serum levels for each cytokine. (B): Mean serum cytokine levels ( $\pm$ SD) in LSCD patients throughout the trial. Patients initially presenting in the low group ( $n = 3$ ) show low levels of TNF- $\alpha$  throughout the period of immune suppression, with a transient increase in mean IL-8 levels on tapering, which resolves to baseline levels at 18 months. Patients who presented in the high group ( $n = 4$ ) continue to show very highly elevated levels of IL-8 throughout the period of immune suppression. TNF- $\alpha$  levels also increase postwithdrawal of immune suppression in this group. Blue line—representative of maximum reported normal levels for TNF- $\alpha$  and IL-8.

post-transplant (Fig. 2C). Example images of eyes before treatment and at the end of the study, having received control or IMP are illustrated in Figure 2D.

### DNA Analysis

Analysis of donors, and patient corneas prior to administration of the IMP showed donor and patient DNA in all cases, respectively, as expected. Analysis of cornea lifts from 6/7 evaluable patients in the IMP arm at 6, 12, and 18 months showed patient DNA but no evidence of donor DNA. One patient showed evidence of mixed patient and donor DNA at the 6- and 12-month time points only.

### White Blood Count and Cytokine Levels

White Blood Count (WBC) and cytokine levels were measured throughout the trial in order to track the effects of immune suppression, and its withdrawal, as well as measuring underlying indicators of inflammatory disease in the patients.

Normal WBC levels were seen in 12/13 enrolled patients throughout the study. The immunosuppression regimen therefore had no gross effect on patient WBC throughout the study (Supporting Information Fig. S2). One patient with chemical injury had elevated WBC at presentation and throughout the clinical study—this patient had ongoing ocular inflammation and had to be withdrawn from the study for subsequent corneal transplant.

### Serum Cytokines—At Enrolment

All patients gave samples for initial cytokine evaluation. An unexpected finding was that while 7 patients presented with serum

cytokines largely in the reported normal ranges, 8 patients presented with highly elevated serum levels of multiple cytokines. [24]. Strikingly, all patients with largely normal cytokine levels (designated “low cytokine group”) consisted of patients with chemical burns and the one patient with autoimmune disease (no patients with aniridia; Fig. 3A). Conversely, 8 patients presented with at least 3/4 cytokines (TNF- $\alpha$ , IL-1 $\beta$ , IL-2, and IL-8/CXCL8) higher than the reference ranges and this “high cytokine group” contained all evaluable patients with aniridia, as well as 1 with chemical burn, and 1 with an autoimmune disease (pemphigus; Fig. 3B).

### Serum Cytokines—During Clinical Trial

A complete set of serum samples were available to measure cytokines from 7 patients at completion of the trial—3 from the low group, and 4 from the high group.

All patients demonstrated normal levels of TNF- $\alpha$  during the period of immune suppression. In the high cytokine group, elevated levels of TNF- $\alpha$  were detected on withdrawal of immune suppression at months 15 and 18 (Fig. 3B). This was not associated with a poor outcome, as all patients with elevated TNF- $\alpha$  levels had improved visual acuity and OSSs at the end of the trial (irrespective of receipt of IMP or control product).

In evaluable patients from the high cytokine group, the preoperative high levels of IL-8 remained consistently high throughout the trial with no pattern of suppression toward the normal range during the period of immune suppression, and after withdrawal (Fig. 3B). Patients in the low cytokine group did exhibit a transient increase in serum IL-8 levels at 12 months, but this

quickly returned to the baseline levels thereafter. Again, high IL-8 levels were not associated with poor outcomes, as all patients had improved visual acuity and OSSs at the end of the trial (irrespective of receipt of IMP or control product).

## DISCUSSION

This is the first randomized controlled study to investigate safety and efficacy of administering allogeneic deceased-donor ex vivo expanded corneal epithelial stem cells in severe bilateral OSD arising from LSCD. Our robust study design allowed us to explore the specific benefits arising from the use of IMP. In addition, we examined serum cytokine profiles in LSCD patients which have not been previously reported.

### IMP

The use of allogeneic deceased-donor limbal tissue introduces variance due to donor age, time to procurement, transport conditions, tissue processing and innate biological variability. We were able to achieve adequate ex vivo outgrowth containing corneal epithelial stem cells from all but one of the donations we received. We chose to use AM as a matrix on which to grow and transfer the cells, rendering this a composite tissue engineered product. QC of such products is not achievable without sacrificing some product. Therefore, we tested remnant material from the transplanted composite product by immunohistochemistry. The stem-like p63+ phenotype was detected in the remnant material from 5 out of the 9 composite transplanted products. The absence of p63+ cells in 4 may be because of the limited tissue availability and/or peripheral nature of the area sampled. Where p63 positive cells were not detected in remnant material from the transplanted product, p63+ cells were detected in the duplicate culture, so we may have a degree of confidence that the transplanted product did contain LSCD. Kolli et al. [11] describe a gradation in the stem cell marker p63 in these cultures, with colony formation highest proximate to the limbal explants and declining in the more distal zones of the culture. Expression of CK3 (a marker of differentiated corneal epithelium) showed the opposite gradation. In the cultures used for the shelf-life validation, around half of the products expressed the CK3 marker, whereas in the transplanted products CK3+ cells were detected in 7 out of 9 products (and in the duplicate cultures from the 2 clinical cultures where CK3 was not detected). This indicates our product was similar to that manufactured by Kolli et al. Variability from product to product is likely a function of the original donated cadaveric material, or the outgrowth region sampled for immunohistochemistry analysis, as the GMP-compliant manufacturing process is highly standardized. The IMP shelf-life of 24 hours at 18°C–24°C allowed transportation of the product to clinical centers such as Glasgow and Liverpool from the manufacturing center (Edinburgh) within the validated timeframe.

### Clinical Trial Outcomes

The IMP was demonstrated to be safe within the limits of the study, with no serious adverse reactions or events attributed to the IMP itself. The primary endpoint was improvement in visual acuity, and there were indicators of transient improvement throughout the study in both groups. These were not statistically

significant, but the majority of patients in both groups ended up with an improved score at 18 months. The IMP group demonstrated statistically significant and sustained improvement in OSS over the period of the study. The control group also demonstrated an initial improvement in OSS, but the effect was not sustained, and the scores returned to near start levels by 18 months. One patient with aniridia was particularly informative. They entered the control arm and the OSS improved from 10 to 8 over 18 months. The patient was then readmitted to the study in respect of his/her other eye and allocated to the IMP arm where OSS improved from 9 to 3. This patient's visual acuity also improved from LogMAR 3 to 2 with control product and from LogMAR 3 to 1.08 with IMP. It therefore may be asserted with a degree of confidence that patients receiving the IMP did benefit overall in terms of OSS improvement, meeting the principal secondary endpoint of the trial.

The clinical trial was designed as a randomized, controlled and partially blinded phase I/II trial and hypothesized that the use of AM, topical autologous serum eye drops and systemic immunosuppression, may have therapeutic benefit. This clearly is the case, as both IMP and control groups show initial improvements in OSS—indeed this is statistically significantly improved in both groups at 6 months. This is not sustained in the control group, returning to be nonsignificantly different from the starting scores, but is clearly sustained in the IMP group. We may conclude that this study demonstrates a pro-regenerative role for transplanted LSC in maintaining improved OSS for a significantly longer time post-transplant than control product. The mechanism for this role is not associated with long-term donor cell engraftment, as there is no sign of donor DNA in eyes of the majority of patients at 6 months. This finding agrees with 2 earlier studies, one which found no evidence of donor DNA in 7 patients 28 weeks postallografting [13], and one on small patient numbers (albeit after longer follow-up) who found sustained benefit in eyes receiving LSC, but with no evidence of engrafted donor DNA [25]. There may be scope to reduce the period of immune suppression in future trials if this is not required to support long-term engrafted allogeneic cells.

In this study we were able to compare improvements in VA between the IMP treatment and control groups, which is a novel approach in this field. In other uncontrolled studies that included allogeneic donor products (although some were from related donors) successful improvement of any kind in VA at the assessment point was seen in, for example, 5/7 patients [26], 2/7 patients [27], 4/7 patients [28]. We saw overall VA improvement in 5/8 IMP patients and 4/5 Control patients at the end of our study. Although generalizations must be drawn carefully between differing studies and protocols, the results of our study has at least comparable outcomes in VA changes to other studies, whether LSC are present or not. The magnitude of change is higher with the IMP but not significantly so, this may well be a factor of the small patient numbers and will require a larger trial to be investigated further.

It should also be noted that randomization led to a skew in the number of patients with different etiologies completing the IMP and control groups. Specifically, 4/8 patients in the IMP group had aniridia compared with 1/5 in the control group. It is possible that patients with aniridia respond better to the treatments. Larger studies with aniridia patients using our IMP are warranted. The majority of IMP group patients did not display sustained engraftment of donor DNA suggesting that engraftment is

transient, as described previously [13]. The benefits in OSS for the IMP group were due to early effects of the stem cells. How these observations relate to the mode of action is unclear. The IMP could induce repair of the limbal niche or stimulate small numbers of dormant residual host stem cells to multiply potentially through a paracrine or chemotactic mechanism, however this remains speculative and we believe that more research is required.

### Inflammation and Underlying Condition

WBC levels were normal in all the evaluable patients except one throughout the study, with no evidence of suppression-induced leukopenia and no cytokine bounce-back at withdrawal. Normal pretransplant TNF- $\alpha$  levels correlated with the WBC levels indicating no chronic inflammation. TNF- $\alpha$  was essentially absent during immune suppression but did show elevation in a few patients on tapering of immune suppression which may indicate responses to cryptic infection, as been reported in other clinical situations where immune competence is restored after a period of suppression [29]. IL-8 levels were consistently elevated in aniridia patients at pretransplant, but not associated with abnormal WBC levels or adverse performance after transplantation. IL-8 is associated with inflammation and neovascularization and can be expressed by various stromal cell types. The nonhematopoietic origin of IL-8 is indicated via continued high levels in some patients despite immune suppression. IL-8 levels have been reported as elevated in tears in aniridia and other eye disorders [30]. However, it is a normal component of tears, and levels in eye disorder patients are approximately 2 times reported values in healthy donors, whereas the levels detected here were 50–500 times normal blood values. This is the first report to the best of our knowledge of chronic, highly elevated serum IL-8/CXCL8 levels in aniridia.

There was no association with a negative treatment outcome in patients with high IL-8 levels—all “high cytokine” patients showed improved VA and OSS at the end of the trial. However, there may be clinical implications of this finding suggesting caution in using autologous serum eye drops in aniridia as the highly elevated levels of proinflammatory/proangiogenic cytokines may exacerbate aniridia-related OSD. Although the IMP can improve the ocular surface in aniridia, other ocular comorbidities associated may limit longer-term benefit.

### CONCLUSION AND FUTURE DIRECTIONS

This RCT demonstrates that sustained benefit is achieved by the IMP in OSD compared with controls and this intervention warrants further study in larger sample sizes in a phase III study. New studies would also benefit from concentrating on a single disease group in order to eliminate some of the variables in this study. Our findings in the subgroup with aniridia

suggests that elevated systemic cytokine levels may have clinical relevance and dissecting both ocular and systemic inflammatory mechanisms in aniridia might shed new light on OSD pathogenesis associated with this condition.

### ACKNOWLEDGMENTS

We thank the Scottish Chief Scientist's Office, UK Stem Cell Foundation, and Scottish Enterprise for their financial support of this work. We thank the University of Edinburgh Pathology Department and Academic Department of Neuropathology for immunohistology analysis; and Department of Clinical Genetics, Western General Hospital, Edinburgh for DNA fingerprinting analysis. Thanks also to the Independent Data Monitoring Committee for their expert guidance throughout the study. We thank NHS Lothian R and D Office and SNBTS Business Services for their administrative support of this study. The current affiliation of S.A. is Moorfields Eye Hospital, London, United Kingdom.

### AUTHOR CONTRIBUTIONS

J.D.M.C.: collection and/or assembly of data, data analysis and interpretation, manuscript writing, final approval of manuscript, cellular product manufacture; S.A., K.R.: conception and design, surgical procedures, collection and/or assembly of data, final approval of manuscript; A. Agrawal, S.K., S.M.: surgical procedures, collection and/or assembly of data, final approval of manuscript; C.B.: collection and/or assembly of data, analysis of data, final approval of manuscript, cellular product manufacture; A. Atkinson, N.W.A.M.: collection and/or assembly of data, final approval of manuscript, cellular product manufacture; A.G., J.P., C.M., M.M.: study administration, collection and/or assembly of data, final approval of manuscript; E.H.: study administration, data analysis and interpretation, final approval of manuscript; J.B.: conception and design, cellular product manufacture, final approval of manuscript; J.D., B.C.: cellular product manufacture, final approval of manuscript; L.N., I.D.: data analysis and interpretation, final approval of manuscript; A.R.F.: data analysis and interpretation, manuscript writing, final approval of manuscript; M.L.T.: conception and design, data analysis and interpretation, manuscript writing, final approval of manuscript, cellular product manufacture; B.D.: conception and design, data analysis and interpretation, manuscript writing, collection and/or assembly of data, final approval of manuscript.

### DISCLOSURE OF POTENTIAL CONFLICTS OF INTEREST

The authors indicated no potential conflicts of interest.

### REFERENCES

- 1 Davanger M, Evenson A. Role of the pericorneal papillary structure in renewal of corneal epithelium. *Nature* 1971;229:560–561.
- 2 Sun TT, Tseng SC, Lavker RM. Location of corneal epithelial stem cells. *Nature* 2010; 463:10–11.
- 3 Ahmad S, Osei-Bempong C, Dana R et al. The culture and transplantation of human limbal stem cells. *J Cell Physiol* 2010;225:15–19.
- 4 Puangsricharern V, Tseng SCG. Cytological evidence of corneal diseases with limbal stem cell deficiency. *Ophthalmology* 1995;102: 1476–1485.
- 5 Kenyon KR, Tseng SCG. Limbal autograft transplantation for ocular surface disorders. *Ophthalmology* 1989;96:709–723.
- 6 Tsubota K, Satake Y, Kaido M et al. Treatment of severe ocular-surface disorders with corneal epithelial stem cell transplantation. *N Engl J Med* 1995;340:1697–1703.
- 7 Pellegrini G, Traverso CE, Franzini AT et al. Long-term restoration of damaged corneal surfaces with autologous cultivated corneal epithelium. *Lancet* 1997;349:990–993.
- 8 Daya SM, Watson A, Sharpe JR et al. Outcomes and DNA analysis of ex vivo expanded stem cell allograft for ocular surface reconstruction. *Ophthalmology* 2005; 112:470–477.
- 9 Baylis O, Figueiredo F, Henein C et al. 13 years of cultured limbal epithelial cell



therapy: A review of outcomes. *J Cell Biochem* 2011;112:993–1002.

**10** Rama P, Matsuka S, Paganoni G et al. Limbal stem cell therapy and long-term corneal regeneration. *N Engl J Med* 2010;363:147–155.

**11** Kolli S, Lako M, Figueiredo F et al. Loss of corneal epithelial stem cell properties in outgrowths from human limbal explants cultured intact amniotic membrane. *Regen Med* 2008;3:329–342.

**12** Henderson TR, Findlay I, Matthews PL et al. Identifying the origin of single corneal cells by DNA fingerprinting: Part II: Application to limbal allografting. *Cornea* 2001;20:404–407.

**13** Sharpe JR, Daya SM, Facs F et al. Survival of cultured allogeneic limbal epithelial cells following corneal repair. *Tissue Eng* 2007;13:123–132.

**14** Meller D, Fuchsluger T, Pauklin M et al. Ocular surface reconstruction in graft-versus-host disease with HLA-identical living-related allogeneic cultivated limbal epithelium after hematopoietic stem cell transplantation from the same donor. *Cornea* 2009;28:233–236.

**15** Nakamura T, Sotozono C, Bentley AJ et al. Long-term phenotypic study after allogeneic cultivated corneal limbal epithelial transplantation for severe ocular surface diseases. *Ophthalmology* 2010;117:2247–2254.

**16** Rama P, Bonini S, Lambiase A et al. Autologous fibrin-cultured limbal stem cells

permanently restore the corneal surface of patients with total limbal stem cell deficiency. *Transplantation* 2001;72:1478–1485.

**17** Koizumi N, Inatomi T, Suzuki T et al. Cultivated corneal epithelial stem cell transplantation in ocular surface disorders. *Ophthalmology* 2001;108:1569–1574.

**18** Sangwan S, Vemuganti G, Iftekhhar G et al. Use of autologous cultured limbal and conjunctival epithelium in a patient with severe bilateral ocular surface disease induced by acid injury. *Cornea* 2003;22:478–481.

**19** Kolli S, Ahmad S, Lako M et al. Successful clinical implementation of corneal epithelial stem cell therapy for treatment of unilateral limbal stem cell deficiency. *STEM CELLS* 2010;28:597–610.

**20** Behaegel J, Ní Dhubhghaill S, Koppen C et al. Safety of cultivated limbal epithelial stem cell transplantation for human corneal regeneration. *Stem Cells Int* 2017;2017:6978253.

**21** Steinberg EP, Tielsch JM, Schein OD et al. The VF-14; an index of functional impairment in patients with cataract. *Arch Ophthalmol* 1994;112:630–638.

**22** Ware JE, Kosinski M, Gandek B. SF-36 Health Survey: Manual & Interpretation Guide. Lincoln: Quality Metric Incorporated, 2005.

**23** Sotozono C, Ang LP, Koizumi N et al. New grading system for the evaluation of chronic ocular manifestations in patients with Stevens-

Johnson syndrome. *Ophthalmology* 2007;114:1294–1302.

**24** Kleiner G, Marcuzzi A, Zanin V et al. Cytokine levels in the serum of healthy subjects. *Mediat Inflamm* 2013;2013:6 Article ID 434010.

**25** Henderson TRM, Coster DJ, Williams KA. The long term outcome of limbal allografts: The search for surviving cells. *Br J Ophthalmol* 2001;85:604–660.

**26** Prabhasawat P, Ekpo P, Uiprasertkul M et al. Efficacy of cultivated corneal epithelial stem cells for ocular surface reconstruction. *Clin Ophthalmol* 2012;6:1483–1492.

**27** Sharma S, Tandon R, Mohanty S et al. Culture of corneal limbal epithelial stem cells: Experience from benchtop to bedside in a tertiary care hospital in India. *Cornea* 2011;30:1223–1232.

**28** Shortt AJ, Secker AJ, Rajan MS et al. Ex vivo expansion and transplantation of limbal epithelial stem cells. *Ophthalmology* 2008;115:1989–1997.

**29** Barber DL, Andrade BB, Sereti I et al. Immune reconstitution inflammatory syndrome: The problem with immunity when you had none. *Nat Rev Microbiol* 2012;10:150–156.

**30** Hagan S, Martin E, Enriquez-de-Salamanca A. Tear fluid biomarkers in ocular and systemic disease: Potential use for predictive, preventative and personalised medicine. *EPMA J* 2016;7:15.



See [www.StemCellsTM.com](http://www.StemCellsTM.com) for supporting information available online.