



Successful outcome of mucormycosis in a child with acute lymphoblastic leukemia

Akut lenfoblastik lösemili bir çocuk hastada mukormikoz enfeksiyonunun başarılı tedavisi

Rejin Kebudi^{1,2,3}, Hande Kızılocak⁴, Günter Hafız^{3,5}, Zayre Erturan⁶

¹Department of Pediatric Hematology-Oncology, İstanbul University, Oncology Institute, İstanbul, Turkey

²Department of Pediatric Hematology and Oncology, İstanbul University-Cerrahpaşa, Cerrahpaşa Faculty of Medicine, İstanbul, Turkey

³American Hospital, İstanbul, Turkey

⁴Children's Hospital Los Angeles, Cancer and Blood Disease Institute, California, USA

⁵Department of Otorhinolaryngology, Head and Neck Surgery, İstanbul University, İstanbul Faculty of Medicine, İstanbul, Turkey

⁶Department of Medical Microbiology, İstanbul University, İstanbul Faculty of Medicine, İstanbul, Turkey

The known about this topic

Mucormycosis in pediatric patients with hematological and oncological malignancies is a rare invasive fungal infection associated with significant morbidity and mortality. Despite the published guidelines on the management of this infection, there is a lack of data on the importance of multidisciplinary approach, including when it is safe to resume chemotherapy and the timing of surgical debridement.

Contribution of the study

In our paper, we emphasized that rapid diagnosis and a multidisciplinary approach can lead to excellent outcomes, even in patients undergoing intensive chemotherapy and we would like to raise awareness of mucormycosis during induction therapy for pediatric acute lymphoblastic leukemia.

Abstract

Invasive fungal infections may cause morbidity and mortality in pediatric patients with hematologic and oncologic malignancies treated with intensive protocols. We present a case of mucormycosis in an 8-year-old boy with acute lymphoblastic leukemia. In our patient, the suspicion for an oculoorbital and paranasal infection only due to mild pain in the orbital area without any abnormal pathologic findings in the ophthalmologic and otolaryngologic examination, led us to an early diagnosis. Despite the use of antifungal therapy, the lesion persisted and fever subsided after surgical drainage of the periorbital abscess. Antifungal treatment continued during chemotherapy. He has been in remission for four years. Mucormycosis should be in the differential diagnosis in infections in children with cancer, especially leukemia, according to clinical and radiologic findings. A high degree of suspicion and prompt systemic empirical antifungal therapy, as well as surgical debridement, are crucial for the survival of patients. Beside antifungals, early surgery plays an important role in patients with mucormycosis.

Keywords: Acute lymphoblastic leukemia, cancer, mucormycosis, pediatric oncology

Öz

Invaziv fungal enfeksiyonlar, yoğun tedaviler alan çocukluk çağı kanserlerinde mortalite ve morbiditenin önemli bir nedenidir. Bu yazıda, akut lenfoblastik lösemi tanılı sekiz yaşındaki erkek hastada saptanan mukormikoz enfeksiyonu irdelenmiştir. Ateş ve orbita etrafında hafif ağrı saptanan olgumuzda, kulak burun boğaz ve oftalmolojik değerlendirilmede patolojik bulgu olmamasına rağmen, okuloorbital ve paranasal enfeksiyonun düşünülmesi, bizi erken tanıya götürdü. Görüntülemeye saptanan periorbital apse, antifungal tedaviye rağmen gerilemedi ve cerrahi drenaj sonrası ateş düştü. Kemoterapi boyunca antifungal tedavisine devam edilen hasta, tedavi bitiminden sonra dört yıldır hastaliksiz izlenmektedir. Çocukluk çağı kanserlerinde, özellikle lösemi tanılı hastaların enfeksiyonlarda, klinik ve radyolojik bulgular doğrultusunda mukormikoz ayırıcı tanıda düşünülmelidir. Bu enfeksiyonun ayırıcı tanıda düşünülmesi, hızla sistemik antifungal tedavi başlanması, ve cerrahi debridman hastaların hayatta kalmaları için çok önemlidir. Antifungal tedavi yanında, erken cerrahi drenaj, mukormikoz tedavisinde önemli rol oynar.

Anahtar sözcükler: Akut lenfoblastik lösemi, kanser, mukormikoz, pediatik hematoloji-onkoloji

Cite this article as: Kebudi R, Kızılocak H, Hafız G, Erturan Z. Successful outcome of mucormycosis in a child with acute lymphoblastic leukemia. *Türk Pediatri Ars* 2020; 55(2): 207–9.

Corresponding Author/Sorumlu Yazar: Rejin Kebudi E-mail/E-posta: rejinkebudi@yahoo.com

Received/Geliş Tarihi: 09.07.2018 **Accepted/Kabul Tarihi:** 04.04.2019

©Copyright 2020 by Turkish Pediatric Association - Available online at www.turkpediatriarsivi.com

©Telif Hakkı 2020 Türk Pediatri Kurumu Derneği - Makale metnine www.turkpediatriarsivi.com web adresinden ulaşılabilir.

DOI: 10.14744/TurkPediatriArs.2019.12129

OPEN ACCESS This work is licensed under a Creative Commons Attribution-NonCommercial 4.0 International License.



Introduction

Morbidity and mortality due to invasive fungal infections (IFIs) remain high in children with cancer treated with intensive protocols. Mortality due to IFIs have been reported to be as high as 18% (1); therefore, precise diagnosis and treatment are crucial. In this paper, we report a child with acute lymphoblastic leukemia (ALL), who presented only with mild pain in the orbital area. He was diagnosed as having mucor and successfully treated with antifungal agents and surgery for orbital mucormycosis.

Case

An 8-year-old boy was treated for moderate risk precursor B cell ALL with a BFM-ALL protocol. At the end of the first phase of delayed intensification (protocol II), he was hospitalized with febrile neutropenia. Intravenous (iv) cefepime was initiated empirically. At 48 hours, fever continued and the patient began to report mild pain in the left orbita. No abnormality was detected in examinations by an ophthalmologist and otolaryngologist. No microbiologic agent was detected in blood cultures. Galactomannan tests were negative in serum. Magnetic resonance imaging (MRI) revealed lesions consistent with infection in the sphenoidal, mastoid, and ethmoid sinuses extruding the left periorbital area. Considering a fungal infection, iv voriconazole was initiated, and after a day, high fever persisted (40°C) and a periorbital swelling was observed. Intravenous liposomal amphotericin B was added to antifungal therapy because we could not rule out a mucormycosis infection.

After five days, fever continued and MRI signs of progressive infection and periorbital abscess formation (Fig. 1) was observed on the same day. Surgical drainage was performed and an absorbable gelatin sponge containing liposomal amphotericin B was inserted locally. Fever subsided in 24 hours. No pathogen was detected in cultures. Mucormycosis was diagnosed by pathology on the surgical drainage material. Chemotherapy was initiated again. Liposomal amphotericin B was continued during delayed intensification and the first month of ALL maintenance treatment for a total of 74 days (2.5 months). Treatment was switched to posaconazole during the continuation of ALL maintenance treatment, which continued at home, because the spectrum of posaconazole covers mucormycosis and it is taken orally. Oral posaconazole was given for a total of six months during the maintenance treatment. The patient has remained in remission for ALL and free of fungal infection for a total of four years from diagnosis. Informed consent was obtained from the parents of the patient who participated in this study.

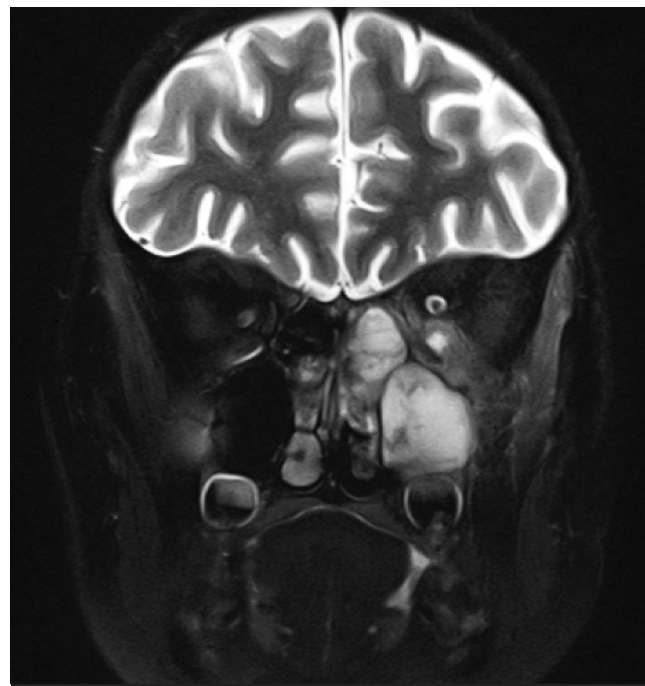


Figure 1. Magnetic resonance imaging revealed lesions consistent with infection in the left maxillar and ethmoid sinuses and left periorbital abscess formation

Discussion

The diagnosis of mucormycosis is difficult and demanding. Treatment should start as soon as possible to decrease morbidity and mortality if there is a suspicion for mucormycosis. No specific antigen detecting test is available.

Prolonged and severe neutropenia, prolonged high-dose systemic corticosteroids, colonization by Mucorales, and either heavy environmental exposure or previous exposure to antifungal agents are reported as important risk factors for mucormycosis.

The treatment of mucormycosis includes antifungal agents, surgical debridement, and correction of the underlying disease predisposing the patient to mucormycosis. The European Conference on Infections in Leukemia (ECIL 3) recommends liposomal amphotericin B or amphotericin B lipid complex as first-line treatment for mucormycosis (BII). The duration of antifungal treatment should be considered for each patient individually, but treatment should usually continue for at least 6-8 weeks. The crucial point, which is as important as the duration of therapy, is the prompt initiation of the antifungal therapy. In our patient, the suspicion for an oculo-orbital and paranasal infection only due to mild pain without any pathologic findings in the ophthalmologic and otolaryngologic examinations, led us to an early diagnosis.

Posaconazole has been reported to be effective in patients with mucormycosis who are refractory to or intolerant of liposomal amphotericin B or who need maintenance treatment (BII) (2, 3). In our case, posaconazole was used during the maintenance chemotherapy phase so that the patient could be treated orally at home, thus leading to a better quality of life.

The importance of surgery has been demonstrated in case series. A single-center study analyzing the impact of combination antifungal therapy for rhino-orbito-cerebral mucormycosis in 41 patients reported that all patients had at least one surgical intervention, showing that the standard approach includes surgical intervention when appropriate (4). In a recent study reviewing 90 patients with rhino-orbito-cerebral mucormycosis and solid organ transplantation, surgical debridement was found to be independently associated with improved outcomes (5).

Gupta et al. (6) reported two patients with ALL with mucormycosis in whom successful results were observed with surgical debridement and amphotericin B therapy. Tuysuz et al. (7) presented a 9-year-old boy with ALL and hepatic mucormycosis. Despite the use of liposomal amphotericin B and posaconazole therapy in combination for a long duration, the lesion persisted and it was treated through surgical excision.

In our case, there was no clinical or radiologic improvement despite specific systemic antifungal treatment in five days. However, fever subsided significantly within 24 hours after surgery, suggesting the importance of surgery in these cases. Also, there were no sequelae in the long-term follow-up.

Mucormycosis should be in the differential diagnosis in infections in children with cancer, especially leukemia, according to clinical and radiologic findings. A high degree of suspicion and prompt systemic empirical antifungal therapy, as well as surgical debridement, are crucial for the survival of patients.

Acknowledgement: We thank Hakan Yıldırım, MD, from the Radiology Department of the American Hospital for the imaging studies.

Informed Consent: Informed consent was obtained from the parents of the patient who participated in this study.

Peer-review: Externally peer-reviewed.

Author Contributions: Concept - R.K., H.K.; Design - R.K., H.K.; Supervision - R.K.; Materials - R.K., G.H., Z.T.; Data

Collection and/or Processing - R.K., H.K., G.H., Z.T.; Analysis and/or Interpretation - R.K., H.K.; Literature Review - R.K., H.K., G.H., Z.T.; Writing - R.K., H.K., G.H., Z.E.; Critical Review - R.K., H.K.

Conflict of Interest: No conflict of interest was declared by the authors.

Financial Disclosure: The authors declared that this study has received no financial support.

Teşekkür: Amerikan Hastanesi Radyoloji Departmanı'ndan Dr. Hakan Yıldırım'a teşekkür ederiz.

Hasta Onamı: Aydınlatılmış onam, bu çalışmaya katılan hastanın ebeveynlerinden alınmıştır.

Hakem Değerlendirmesi: Dış bağımsız.

Yazar Katkıları: Fikir - R.K., H.K.; Tasarım - R.K., H.K.; Denetleme - R.K.; Malzemeler - R.K., G.H., Z.T.; Veri Toplanması ve/veya İşlemesi - R.K., H.K., G.H., Z.T.; Analiz ve/veya Yorum - R.K., H.K.; Literatür Taraması - R.K., H.K., G.H., Z.T.; Yazıyı Yazan - R.K., H.K., G.H., Z.E.; Eleştirel İnceleme - R.K., H.K.

Çıkar Çatışması: Yazarlar çıkar çatışması bildirmemişlerdir.

Mali Destek: Yazarlar bu çalışma için mali destek almadıklarını beyan etmişlerdir.

References

1. Sung L. Invasive fungal infections in children with cancer. *J Pediatr* 2010; 156: 68–73.
2. Greenberg RN, Mullane K, van Burik JA, et al. Posaconazole as salvage therapy for zygomycosis. *Antimicrob Agents Chemother* 2006; 50: 126–33.
3. van Burik JA, Hare RS, Solomon HF, Corrado ML, Kontoyiannis DP. Posaconazole is effective as salvage therapy in zygomycosis: a retrospective summary of 91 cases. *Clin Infect Dis* 2006; 42: e61–5.
4. Herbrecht R, Letscher-Bru V, Bowden RA, et al. Treatment of 21 cases of invasive mucormycosis with amphotericin B colloidal dispersion. *Eur J Clin Microbiol Infect Dis* 2001; 20: 460–6.
5. Sun HY, Forrest G, Gupta KL, et al. Rhino-orbital-cerebral zygomycosis in solid organ transplant recipients. *Transplantation* 2010; 90: 85–92.
6. Gupta A, Jain S, Agrawal C, Kapoor G. Successful outcome of mucormycosis in two children on induction therapy for acute lymphoblastic leukemia. *Indian J Med Paediatr Oncol* 2013; 34: 313–6.
7. Tuysuz G, Ozdemir N, Senyuz OF, et al. Successful management of hepatic mucormycosis in an acute lymphoblastic leukaemia patient: a case report and review of the literature. *Mycoses* 2014; 57: 513–8.