

## Submucosal dissection of a large colonic angiodysplasia in case of failure of conventional treatment

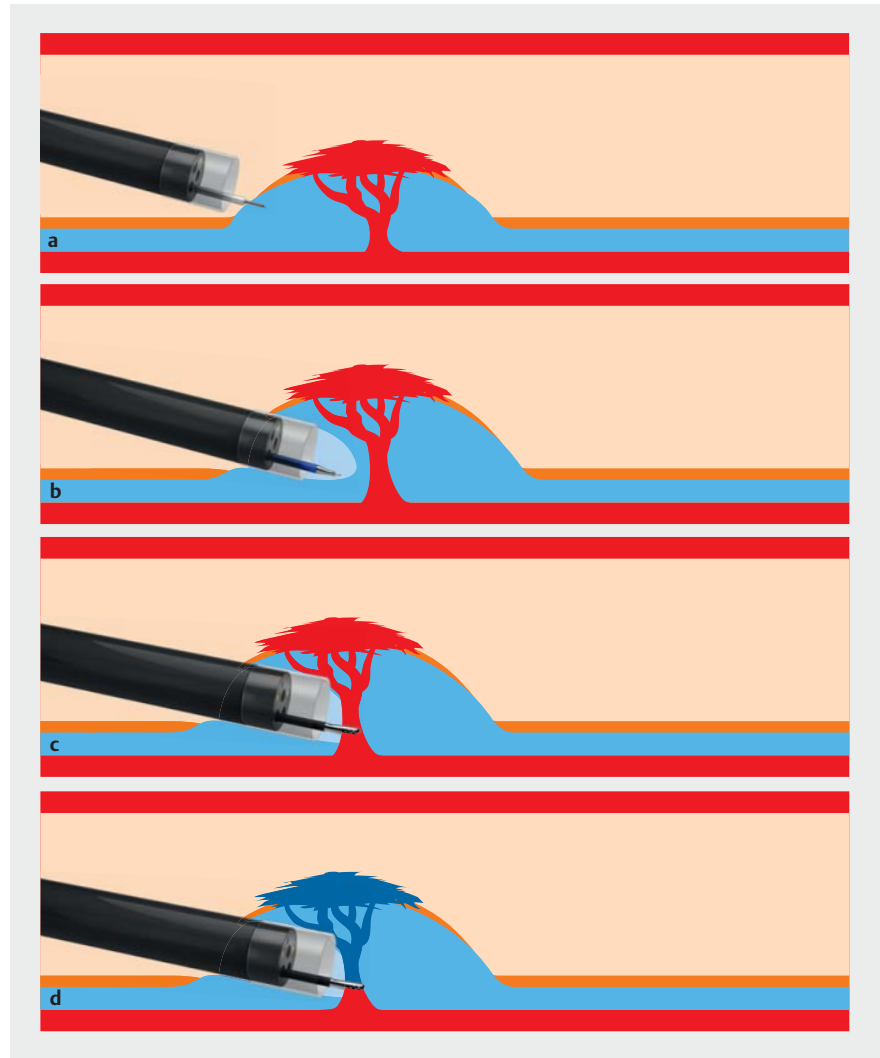


Digestive angiodysplasias are responsible for about 10% of lower digestive bleeds and may also be revealed with an iron deficiency-related anemia [1]. They are common in elderly populations with a history of heart disease or anticoagulant medication. The currently recommended treatment is the use of argon plasma. However, this treatment can be associated with significant morbidity, especially for large angiodysplasias where post-procedural hemorrhage or secondary perforations are reported [2].

As shown in ► **Fig. 1** and ► **Video 1**, we report here the case of a 72-year-old man with a 25-mm large right colonic angiodysplasia, visible on computed tomography (CT) scan at arterial time. This lesion was responsible for recurrent anemia and digestive bleeds, favored by anti-coagulant treatment. A treatment with argon had already been performed but the symptomatology had recurred. An endoscopic submucosal dissection (ESD) was therefore proposed for this patient, with success. We feared a possible intense submucosal fibrosis, which is why the dissection was started 15 mm upstream of the angioma in healthy mucosa. This technique allowed penetrating into the submucosal space in order to treat the feeding vessel in a targeted way. We report no complications following the procedure, and 1 month afterward the CT scan confirmed the vanishing of the angiodysplasia.

Endoscopic mucosal resection has been reported to treat colonic angiodysplasias [3,4]. However, ESD has the advantage of being able to treat angiodysplasias of more than 20 mm and to coagulate the feeding vessel in a targeted manner. In experienced hands, ESD allows targeted coagulation of the feeding vessel and seems to be a promising method to treat large colonic angiodysplasias if conventional treatment fails.

Endoscopy\_UCTN\_Code\_TTT\_1AQ\_2AJ



► **Fig. 1** Schematic representation of submucosal dissection of colonic angiodysplasia. **a** Submucosal injection. **b** Incision. **c** Coagulation of the feeding vessel with monopolar coagulation forceps. **d** Devascularized angiodysplasia.

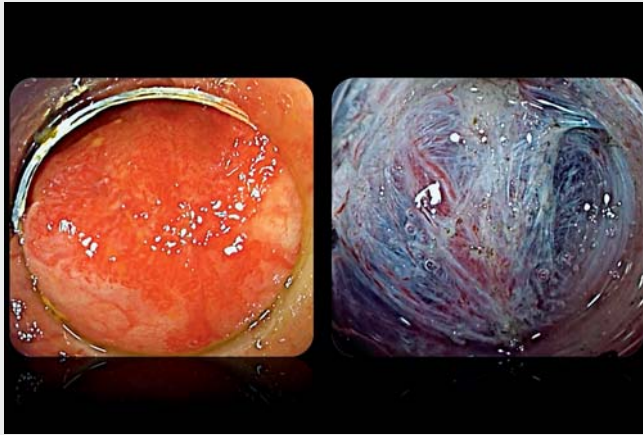### Competing interests

The authors declare that they have no conflict of interest.

### The authors

**Martin Bordet<sup>1</sup>, Jérémie Jacques<sup>2</sup>, Thomas Grainville<sup>1</sup>, Mathieu Pioche<sup>3</sup>, Mael Pagenault<sup>1</sup>, Tanguy Brunet<sup>1</sup>, Timothée Wallenhorst<sup>1</sup>**

<sup>1</sup> Department of Endoscopy and Gastroenterology, Centre Hospitalier Universitaire Pontchaillou, Rennes, France



**Video 1** Submucosal dissection of a large colonic angiodysplasia with targeted coagulation of the feeding vessel.

- 2 Department of Endoscopy and Gastroenterology, Centre Hospitalier Universitaire Dupuytren, Limoges, France
- 3 Department of Endoscopy and Hepatogastroenterology, Pavillon L, Edouard Herriot Hospital, Lyon, France

### Corresponding author

**Timothée Wallenhorst, MD**  
Endoscopy Unit – Department of Gastroenterology, Centre Hospitalier Universitaire Pontchaillou, 35033 Rennes Cedex 9, France  
timothee.wallenhorst@chu-rennes.fr

### References

- [1] García-Compeán D, Del Cueto-Aguilera ÁN, Jiménez-Rodríguez AR et al. Diagnostic and therapeutic challenges of gastrointestinal angiodysplasias: a critical review and view points. *World J Gastroenterol* 2019; 25: 2549–2564. doi:10.3748/wjg.v25.i21.2549
- [2] Triantafyllou K, Gkolfakis P, Gralnek IM et al. Diagnosis and management of acute lower gastrointestinal bleeding: European Society of Gastrointestinal Endoscopy (ESGE) Guideline. *Endoscopy* 2021; 53: 850–868. doi:10.1055/a-1496-8969
- [3] Sriram N, Bar-Yishay I, Kumarasinghe P et al. Definitive therapy of colonic angioectasia by submucosal coagulation. *Endosc Int Open* 2019; 07: E1773–E1777. doi:10.1055/a-0965-6688
- [4] Geyl S, Albuys J, Schaefer M et al. Is endoscopic mucosal resection optimum for treating colonic angiodysplasia? *Endoscopy* 2022. doi:10.1055/a-1750-9105

### Bibliography

*Endoscopy* 2023; 55: E35–E36  
DOI 10.1055/a-1918-0918  
ISSN 0013-726X  
published online 22.9.2022  
© 2022. The Author(s).

This is an open access article published by Thieme under the terms of the Creative Commons Attribution-NonCommercial License, permitting copying and reproduction so long as the original work is given appropriate credit. Contents may not be used for commercial purposes, or adapted, remixed, transformed or built upon. (<https://creativecommons.org/licenses/by-nc-nd/4.0/>)

Georg Thieme Verlag KG, Rüdigerstraße 14, 70469 Stuttgart, Germany



### ENDOSCOPY E-VIDEOS

<https://eref.thieme.de/e-videos>



*Endoscopy E-Videos* is an open access online section, reporting on interesting cases and new techniques in gastroenterological endoscopy. All papers include a high quality video and all contributions are freely accessible online. Processing charges apply (currently EUR 375), discounts and waivers acc. to HINARI are available.

This section has its own submission website at <https://mc.manuscriptcentral.com/e-videos>