

Received: 2016.11.14  
Accepted: 2017.02.11  
Published: 2017.05.16

ISSN 1941-5923  
© Am J Case Rep, 2017; 18: 537-540  
DOI: 10.12659/AJCR.902377

## Melanoma Masquerading as a Zosteriform Rash

Authors' Contribution:  
Study Design A  
Data Collection B  
Statistical Analysis C  
Data Interpretation D  
Manuscript Preparation E  
Literature Search F  
Funds Collection G

AEF 1 **Saif Ibrahim**  
EF 2 **Bashar Al-Turk**  
EF 2 **Ciel Harris**  
FG 3 **Farah Al-Saffar**  
EG 4 **Sayf Said**  
EG 5 **Maheera Farsi**  
FG 2 **Jeffrey Winder**  
AFG 6 **Cristian Landa**

1 Department of Cardiology, University of Florida, Jacksonville, FL, U.S.A.  
2 Department of Medicine, University of Florida, Jacksonville, FL, U.S.A.  
3 Department of Cardiology, Mayo Clinic, Scottsdale, FL, U.S.A.  
4 Department of Medicine, Providence Hospital, Washington, DC, U.S.A.  
5 Department of Dermatology, Largo Medical Center, Largo, FL, U.S.A.  
6 Baptist Health, Jacksonville, FL, U.S.A.

**Corresponding Author:** Bashar Al-Turk, e-mail: [bashar.al-turk@jax.ufl.edu](mailto:bashar.al-turk@jax.ufl.edu)  
**Conflict of interest:** None declared

**Patient:** **Male, 49**  
**Final Diagnosis:** **Melanoma**  
**Symptoms:** **Rash**  
**Medication:** —  
**Clinical Procedure:** —  
**Specialty:** **Dermatology**

**Objective:** **Rare disease**

**Background:** Primary care physicians and internal medicine specialists frequently encounter a variety of rashes. Many of these cases look and feel typical of common entities, resulting in the potential for misdiagnosis.

**Case Report:** This is a case of a zosteriform rash where the surprising true diagnosis of metastatic melanoma was confirmed with bedside skin punch biopsy. Possible mechanisms involve direct cutaneous injury, neuronal, and dorsal root ganglia involvement in metastases.

**Conclusions:** Skin biopsy is indispensable especially when there is a lack of clinical response or deterioration in the clinical condition. The pathophysiology of zosteriform metastasis is unclear.

**MeSH Keywords:** **Herpes Zoster • Lymphatic Metastasis • Melanoma, Amelanotic • Skin Diseases, Vesiculobullous**

**Full-text PDF:** <http://www.amjcaserep.com/abstract/index/idArt/902377>



987



—



3



18



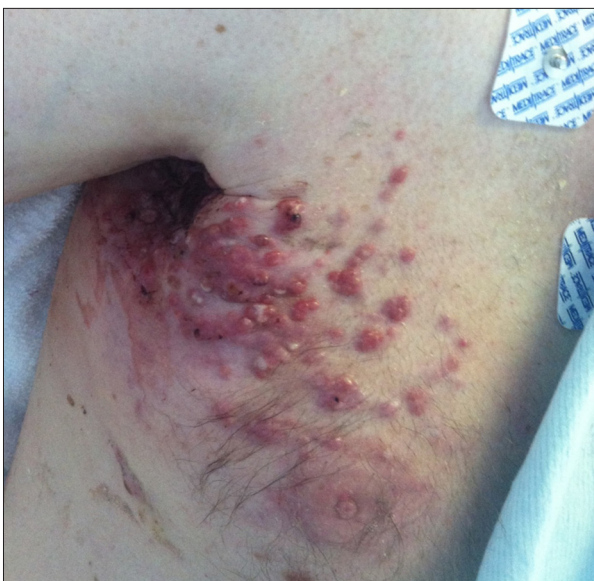## Background

Skin rashes are commonly encountered complaints in clinics and inpatient settings. Physicians rely heavily on their personal exposures in diagnosing rashes. We present a case where a patient's skin lesion was highly suggestive of herpes zoster, both in appearance and symptomatic sequelae, yet the actual diagnosis was a recurrence of metastatic amelanotic melanoma. Amelanotic melanoma is a rare type of melanoma characterized by a lack of melanin in the lesion, thus the lesions typically do not have the darkened appearance that is typical of a melanoma. Because of this atypical presentation, they often go unrecognized by physicians, leading to an increased time lapse for metastasis and poorer prognosis [1].

There have been very few cases that document recurrence of melanoma in a "zosteriform transformation" after treatment of melanoma with chemotherapy, as demonstrated in our case. A literature review revealed seven such cases [2–4]. Zosteriform pattern consists of grouped vesicles on an erythematous base confined to a single unilateral dermatome. Zosteriform metastasis is usually painful, tender or pruritic, and is commonly confined to a single unilateral dermatome, adding to the potential for misdiagnosis [3].

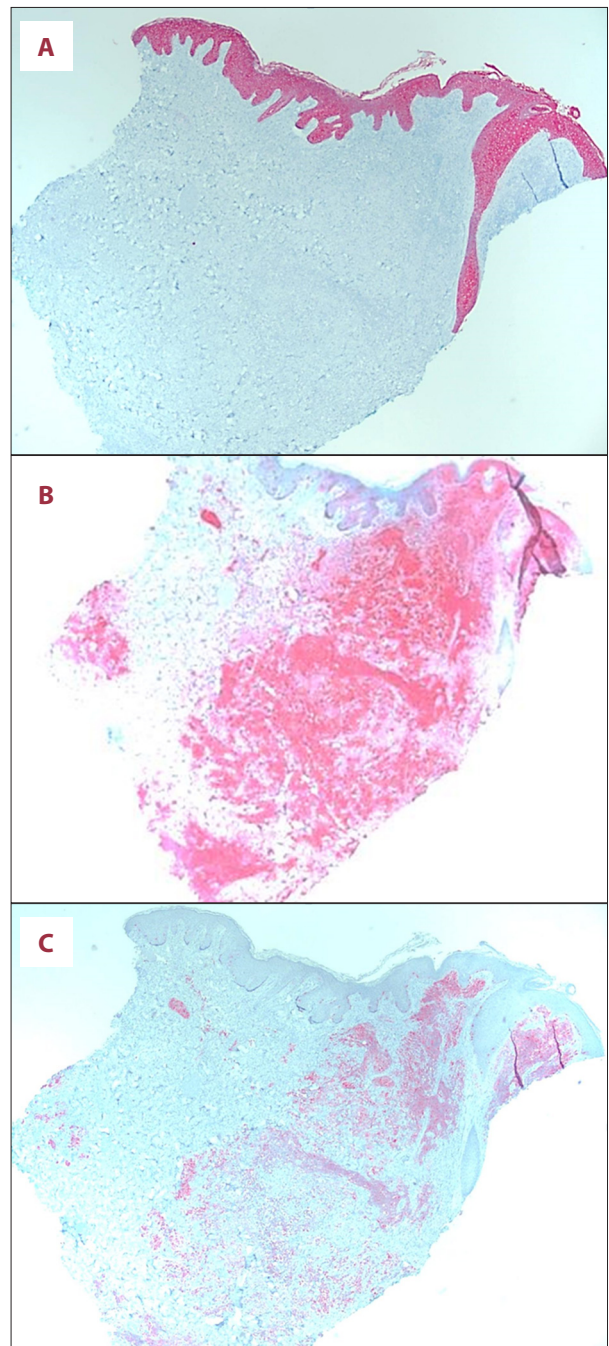
## Case Report

A forty-nine-year-old man with an initially unknown past medical history (except recent treatment for herpes zoster) was brought to the emergency department for a right thoracic rash and skin lesions.

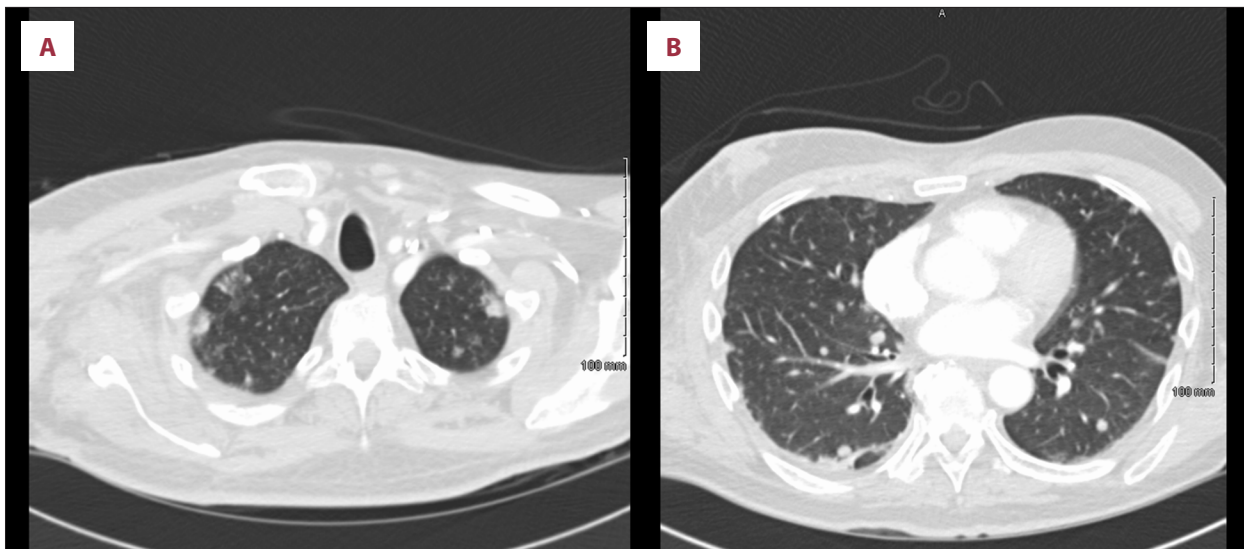


**Figure 1.** Skin rash on presentation.

Physical examination revealed a middle-aged man, not in apparent distress but who appeared confused and could not provide his own history. Scars from previous staples were seen near the right scapular region. Skin examination was significant for a dark red papular skin rash in the right thoracic area roughly at the fourth and fifth intercostal areas (dermatomal T2 and T3 distribution) extending to posterior axilla where



**Figure 2.** (A) Skin biopsy negative for cytokeratin AE1-AE3. (B) Skin biopsy positive for S-100. (C) Skin biopsy positive for Melan-A.



**Figure 3.** (A) Computed tomography (CT) showing postsurgical changes in the right axilla with confluent lymphadenopathy. There is also right retro-areolar soft tissues density/mass with adjacent right breast skin thickening. These findings are suggestive of a recurrent neoplastic process. (B) Computed tomography (CT) of the chest showing innumerable pulmonary nodules seen bilaterally representing metastatic disease.

multiple hard lumps were palpated in groups. Lesions were tender with purulent discharge (Figures 1, 2).

Given the recent history of possible herpes zoster and immunocompromised status he was started empirically on acyclovir 1 g intravenously every eight hours. Yet it was the firmness of the skin lesions and the prominent axillary lymph nodes that prompted our team to proceed with skin biopsy to rule out an underlying malignancy.

Further information was obtained from the patient's family as well as from medical records received later in the admission. The patient had cutaneous melanoma two years ago in the right scapular area, which had been resected, and he had one cycle of chemotherapy but was not willing to continue treatment. He had a recent admission for another skin lesion in the same area (also resected).

Skin biopsy of the lesions demonstrated cells strongly positive for S-100 (the protein usually found in neural crest cells like melanocytes) and Melan-A (recently identifies melanoma-specific marker) immunostain [5,6]. The biopsy was negative for CK AE1/AE3 immunostain, typically an epithelial/myoepithelial cell marker [7]. These findings supported the diagnosis of metastatic amelanotic melanoma (Figure 2A–2C). Computed tomography (CT) of the chest showed evidence of subcutaneous invasion, lung metastasis, and metastatic bony lesions (Figure 3A, 3B).

Given the patient's poor functional status and minimal benefit of pursuing further treatment palliative care was consulted

and the patient elected for discharge with hospice care. No further treatment was administered.

## Discussion

Zosteriform metastasis is a cutaneous manifestation of malignancy resulting in a presentation typical of the dermatomal rash seen in reactivation of the varicella zoster virus. The histotypes in the literature include skin (most common being melanoma), breast, stomach, lungs, uterus, large intestine and kidneys [8,9]. Due to the rarity of metastatic melanoma in the form of zoster-like lesions, it is important to consider a broad differential diagnosis of more common disease processes. The differential diagnoses can include herpes simplex virus, atopic dermatitis, superficial pyoderma, eczema, furunculosis, secondary/tertiary syphilis, post-herpetic granulomatous dermatitis, and sarcoidosis. In this case, the patient's history and overall presentation served to guide our investigation. Diagnosis can be made with a biopsy followed by histopathologic confirmation, and immunostaining, looking for S-100 and Melan-A markers, which are specific for melanoma [10]. While several hypotheses have been made to explain the pathogenesis, the exact etiology remains unclear. Some case reports suggest that previous varicella infections may facilitate subsequent metastasis either through Koebner-like phenomenon or through neuronal injury or lymphatic invasion [8,11,12]. Others have suggested dorsal root ganglia involvement in the metastatic process or direct surgical cutaneous seeding after surgical resection of the previous lesion (which could explain why it involves areas in the vicinity

of the previous melanoma) [8]. An extensive review done by Voss et al. showed that surveillance for recurrent melanoma, especially after treatment for an advanced stage is crucial for better prognosis. This review also suggests the use of imaging with CT scan or positron emission tomography (PET) scan to assess regional lymph nodes [13]. In our case, surveillance and imaging were lacking on presentation which, together with new skin lesions, prompted the skin biopsy. There is no study data to suggest zosteriform presentation of melanoma specifically affects prognostication, however, cutaneous manifestations of metastasis generally carry a poorer prognosis [9]. Prior reported cases found lymphatic spread to be common [14]. Treatment for this type of melanoma is the same as a “traditional” melanoma, and is dependent upon the staging [15,16]. Lesions are treated with supportive care and prevention of secondary infection including radiation therapy for the former and de-roofing or hydrocolloid dressings for the

latter. Recent studies have shown that the immune modulator imiquimod 5% cream may lead to regression of metastases in some patients with melanoma [9,17].

## Conclusions

Direct injury, neuronal involvement in metastasis after previous zoster infection, and lymphatic spread have all been suggested as possible pathophysiological mechanisms for zosteriform metastatic melanoma. There is a lack of clear evidence favoring any hypotheses owing to the extreme rarity of the disease. Even in the face of typical zoster lesions, physicians should consider the whole clinical picture as early diagnosis of recurrent melanoma with biopsy (aided by imaging when indicated by the initial tumor stage) can improve outcomes and prognosis.

## References:

1. Balch CM, Soong S, Ross MI et al: Long-term results of a multi-institutional randomized trial comparing prognostic factors and surgical results for intermediate thickness melanomas (1.0 to 4.0 mm). Intergroup Melanoma Surgical Trial. *Ann Surg Oncol*, 2000; 7(2): 87–97
2. Sinha R, Fearfield L: Images in clinical medicine. Zosteriform metastases from malignant melanoma. *N Engl J Med*, 2014; 370(14): e22
3. Evans AV, Child FJ, Russell-Jones R: Zosteriform metastasis from melanoma. *BMJ*, 2003; 326(7397): 1025–26
4. North S, Mackey JR, Jensen J: Recurrent malignant melanoma presenting with zosteriform metastases. *Cutis*, 1998; 62(3): 143–46
5. Kondras K, Zalewska A, Janowski P, Kordek R: Cutaneous multifocal melanoma metastases clinically resembling herpes zoster. *J Eur Acad Dermatol Venereol*, 2006; 20(4): 470–72
6. Bergler-Czop B, Brzezinska-Wcislo L, Miziolek B: Metastases of malignant melanoma to the skin of abdomen and thorax imitating Herpes Zoster infection. *Ann Saudi Med*, 2015; 35(6): 482–83
7. Savoia P, Fava P, Debolli T et al: Zosteriform cutaneous metastases: A literature meta-analysis and a clinical report of three melanoma cases. *Dermatol Surg*, 2009; 35(9): 1355–63
8. Rekhi B, Sable M, Jambhekar NA: Histopathological, immunohistochemical and molecular spectrum of myoepithelial tumours of soft tissues. *Virchows Arch*, 2012; 461(6): 687–97
9. Helm T, Lee TC: Dermatologic manifestations of metastatic carcinomas. *Medscape*, 2016 Available from: [URL:http://emedicine.medscape.com/article/1101058-overview#a5](http://emedicine.medscape.com/article/1101058-overview#a5)
10. Nonaka D, Chiriboga L, Rubin BP: Differential expression of S100 protein subtypes in malignant melanoma, and benign and malignant peripheral nerve sheath tumors. *J Cutan Pathol*, 2008; 35(11): 1014–19
11. Itin PH, Lautenschlager S, Buechner SA: Zosteriform metastases in melanoma. *J Am Acad Dermatol*, 1995; 32(5 Pt 2): 854–57
12. MacWilliams P, Noojin RO: Vesicular metastatic melanoma. *South Med J*, 1974; 67(11): 1365–67
13. Voss RK, Woods TN, Cromwell KD et al: Improving outcomes in patients with melanoma: Strategies to ensure an early diagnosis. *Patient Relat Outcome Meas*, 2015; 6: 229–42
14. Zalaudek I, Leinweber B, Richtig E et al: Cutaneous zosteriform melanoma metastases arising from herpes zoster infection. *Melanoma Res*, 2003; 13(6): 635–39
15. Balch CM, Gershenwalf JE, Soong SJ et al: Final version of 2009 AJCC melanoma staging and classification. *J Clin Oncol*, 2009; 27(36): 6199–206
16. Chen LQ: [Understanding and appraisal of the new TNM classification for esophageal cancer in the AJCC Cancer Staging Manual (7<sup>th</sup> edition)]. *Zhonghua Zhong Liu Za Zhi*, 2010; 32(3): 237–40 [in Chinese]
17. Turza K, Dengel LT, Harris RC et al: Effectiveness of imiquimod limited to dermal melanoma metastases, with simultaneous resistance of subcutaneous metastasis. *J Cutan Pathol*, 2010; 37(1): 94–98
18. Snyder ML, Paulino AF: Melan-A as a useful diagnostic immunohistochemical stain for the diagnosis of primary sinonasal melanomas. *Head Neck*, 2002; 24(1): 52–55