



How to Articles

How to do it: Plasmapheresis via venoarterial extracorporeal membrane oxygenation circuit for thyroid storm

Lucy Manuel^{a,*}, Laura S. Fong^a, Andrew Lahanas^b, Peter Grant^a^a Department of Cardiothoracic Surgery, Prince of Wales Hospital, Sydney, Australia^b Department of Perfusion, Prince of Wales Hospital, Sydney, Australia

ARTICLE INFO

Keywords:

Plasmapheresis
VA-ECMO
Thyroid storm
Thyrotoxicosis

ABSTRACT

Thyrotoxicosis-induced cardiomyopathy is a rare complication occurring in <1% of the population, which can require mechanical circulatory support (VA-ECMO) as a bridge to anti-thyroid therapies. Therapeutic plasma exchange (TPE) is an alternative treatment used to rapidly reduce thyroid hormone levels in refractory cases of thyrotoxic crisis without clinical improvement from other therapies. We describe a novel technique of facilitating plasmapheresis via a VA-ECMO circuit in a 26-year-old man with thyroid storm and subsequent circulatory collapse.

1. Introduction

Extracorporeal membrane oxygenation (ECMO) is a last line therapy used to enable gas exchange and perfusion through an external membrane lung in critically unwell patients [1]. There are two main types of ECMO, veno-venous (VV-ECMO), used to treat respiratory failure, and veno-arterial (VA-ECMO), which is used for cardiac support [2]. Thyrotoxicosis-induced cardiomyopathy is a rare complication occurring in <1% of the population, which can require mechanical circulatory support (VA-ECMO) as a bridge to anti-thyroid therapies [2]. The utility of therapeutic plasma exchange (TPE) has been documented in case study literature in patients with acute thyrotoxicosis refractory to conventional therapy [3,4]. We describe a novel technique of facilitating plasmapheresis via a VA-ECMO circuit, avoiding the need for alternate central venous access.

2. Technique

A 26-year-old man presented to the emergency department with a 5-day history of shortness of breath, pleuritic and positional chest pain, subjective fevers, lower limb swelling and palpitations. He was found to be in rapid atrial fibrillation (AF) with a heart rate of 180 with a blood pressure of 106/88 mmHg. He was loaded with amiodarone and treated with a trial of IV metoprolol and received gentamicin, ceftriaxone and flucloxacillin for empiric antibiotic coverage. Bedside echocardiogram demonstrated severe global dysfunction with a small-moderate

pericardial effusion. He was also placed on Covid-19 contact precautions and appropriately isolated. The patient was admitted to ICU with worsening cardiogenic shock despite escalation of medical therapy. Following an attempt at Direct Current (DC) cardioversion, the patient had a pulseless electrical activity (PEA) arrest and CPR was commenced. The decision was made for urgent placement of VA-ECMO using a 23Fr cannula in the right femoral vein and a 19Fr arterial in the left femoral artery. A 7Fr arterial backflow cannula was inserted for distal leg perfusion. Anticoagulation was achieved using 20 000 units of heparin resulting in an Activated Clotting Time (ACT) of >400. ECMO was established with initial flows of 4 L/min. Thyroid function tests revealed a Thyroid Stimulating Hormone (TSH) level of <0.005mIU/L (normal range 0.4–4.0mIU/L) and a T4 level of >100 pmol/L (normal range 9.0–25 pmol/L). A diagnosis of thyrotoxicosis-induced cardiomyopathy was made and preparations for plasmapheresis for T4 removal was commenced. Additionally, the patient was treated with carbimazole, Lugol's iodine, cholestyramine and hydrocortisone for thyroid storm, and was supported with levosimendan, vasopressin and noradrenaline.

The Spectra Optia Apheresis System (Terumo BCT) was used. Blood inflow to the plasmapheresis device was via the ECMO post-membrane port three-way tap. The outflow from the plasmapheresis system was connected to the pre-membrane port (see Fig. 1). A calcium gluconate infusion was also connected to this return line as was the continuous heparin infusion via an additional 3-way tap to reduce the risk of oxygenator thrombosis. Extended life plasma (ELP) was utilised as the replacement fluid. The procedure was well tolerated with an inlet

* Corresponding author. Department of Cardiothoracic Surgery, Prince of Wales Hospital, Randwick, Australia.

E-mail address: lucy.manuel@health.nsw.gov.au (L. Manuel).

<https://doi.org/10.1016/j.amsu.2021.102485>

Received 29 April 2021; Received in revised form 31 May 2021; Accepted 5 June 2021

Available online 10 June 2021

2049-0801/© 2021 The Authors. Published by Elsevier Ltd on behalf of IJS Publishing Group Ltd. This is an open access article under the CC BY-NC-ND license

(<http://creativecommons.org/licenses/by-nc-nd/4.0/>).

anticoagulant (AC) ratio of 10:1 and an inlet rate of 45 mL/min, rinse-back was not performed to avoid fluid overload. The TPE run time was 145 min and there were no pressure alarms throughout. Following this, the T4 remained >100 pmol/L and another TPE session was performed the following day. After two sessions there was significant improvement in thyroid function tests and significant improvement of cardiac function on transthoracic echocardiogram on ECMO flows of 2 L/min. The patient was subsequently decannulated 24 h later following improved haemodynamics and stable mixed venous oxygen saturation at low ECMO flows. A total thyroidectomy was performed two weeks later.

3. Comment

Thyroid storm is a rare but life-threatening endocrinological emergency with an estimated mortality of up to 30% [5,6]. The three most common treatments for hyperthyroidism are antithyroid drugs, radioactive iodine, and thyroidectomy. TPE is an alternative treatment used to rapidly reduce thyroid hormone levels in refractory cases of thyrotoxic crisis without clinical improvement from other treatments [5]. During TPE, a patient's plasma is extracted from its cellular components, meaning thyroid hormone-binding globulins and bound thyroid hormone, are removed from the circulation and replaced with new colloid, thereby reducing free hormone concentrations [3]. Clotting factors and immunoglobulins are also removed with TPE, increasing the risk of

bleeding and infection, making the use of TPE and concurrent ECMO requiring anticoagulation with intravenous heparin more hazardous [3]. Moreover, the available literature demonstrates shorter ECMO runs with earlier initiation of TPE, suggesting a significant improvement in cardiovascular function with early therapy [7]. The ECMO run of 24 h in this case is much shorter than previously reported in the literature with the shortest duration previously reported at 82 h and an average run of 183.5 h [2].

There is limited literature regarding concurrent ECMO and TPE in critically unwell patients [4]. There is also no consensus of optimum configuration of the circuit when the procedures are combined, indicating a viable area of future perfusion and critical care research [1]. Laverdure and colleagues [8] have previously described an alternative technique whereby the inlet line is connected to the oxygenator, and the outlet line connected to a venous or arterial cannula. The method described in this case is simpler, allowing a perfusionist to manage the circuit without surgical involvement. Moreover, by using a circuit in parallel, rather than connected to the ECMO return cannula, the risk of clots, air or particulate matter entering the arterial system of the patient is reduced. Connecting the return line to the tubing before the oxygenator allows potential air and thrombi to be trapped while also avoiding unnecessary veno-arterial shunting within the ECMO circuit. The circuit configuration described means the apheresis circuit is exposed to a higher pressure than usual, however, settings on the apheresis machine

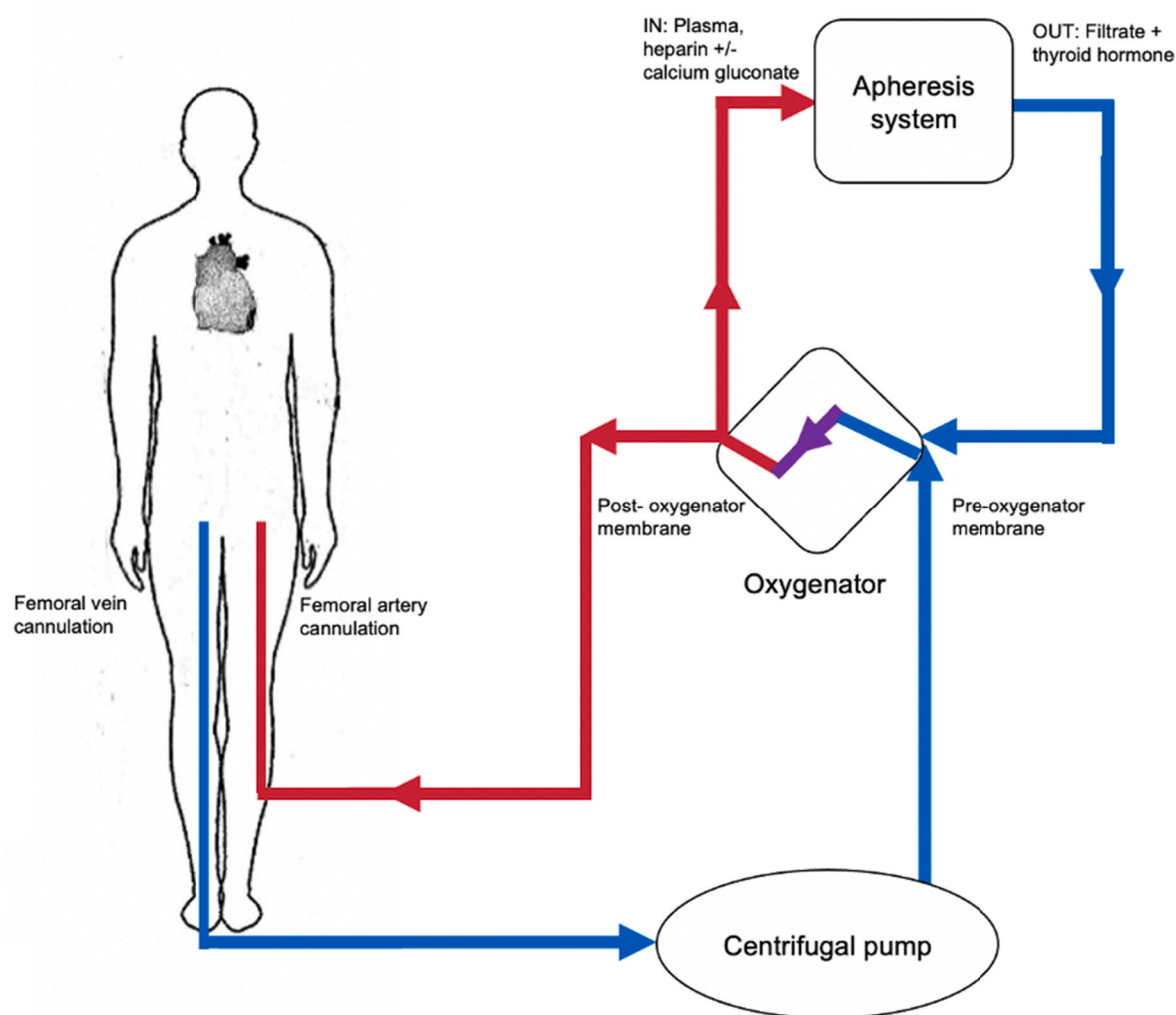


Fig. 1. Schematic of femoral VA-ECMO in parallel with Spectra Optia Apheresis System (Terumo BCT). TPE inflow is connected to the oxygenator post-membrane and returns pre-membrane prior to returning to the patient.

can be altered to lower the return pressures to prevent alarming [1]. Connecting a full plasmapheresis system, rather than using in-line technology, allows accurate monitoring of filtration, fluid balance and keeps a constant flow through the filter. Moreover, filters can be easily changed without disruption of the ECMO flow [1].

Although a rare occurrence, the ultimate goal of VA-ECMO and PTE in thyroid storm is to mechanically support until other antithyroid therapies can return the patient to a euthyroid state. The aforementioned technique allows excellent flows while decreasing the risk of air and thrombi from entering the patient by utilising the oxygenator as a trap. Future research confirming this novel circuit configuration should be considered as the method provides a simple and reproducible method of running PTE in parallel via a VA-ECMO circuit in a critically unwell patient.

Nil. The patient has consented to publication of this case.

Sources of funding

Nil funding for research.

Ethical approval

Nil ethics approval required.

Consent

N/A-nil patients/volunteers.

Author contributions

Lucy Manuel- Literature search, analysis and writing of manuscript
 Laura Fong- Analysis and editing of manuscript
 Andrew Lahanas- Analysis and editing of manuscript.

Peter Grant- Analysis and editing of manuscript.

Trial registry number

1. Name of the registry: NA-nil human participants

2. Unique Identifying number or registration ID:
3. Hyperlink to your specific registration (must be publicly accessible and will be checked):

Guarantor

Peter Grant.

Declaration of competing interest

Nil conflict of interest to declare.

Acknowledgments/Disclosures:

References

- [1] B. Seczyńska, W. Królikowski, I. Nowak, M. Jankowski, K. Szuldrzyński, W. Szczeklik, Continuous renal replacement therapy during extracorporeal membrane oxygenation in patients treated in medical intensive care unit: technical considerations, *Ther. Apher. Dial.* 18 (6) (2014) 523–534.
- [2] A. White, S.J. Bozso, M.C. Moon, Thyrotoxicosis induced cardiomyopathy requiring support with extracorporeal membrane oxygenation, *J. Crit. Care* 45 (2018) 140–143.
- [3] H. Koh, M. Kaushik, J.K. Loh, C.L. Chng, Plasma exchange and early thyroidectomy in thyroid storm requiring extracorporeal membrane oxygenation, *Endocrinol. Diabetes Metabol. Case Rep.* 2019 (2019).
- [4] M. Dyer, M.D. Neal, M.A. Rollins-Raval, J.S. Raval, Simultaneous extracorporeal membrane oxygenation and therapeutic plasma exchange procedures are tolerable in both pediatric and adult patients 54 (4) (2014) 1158–1165.
- [5] R. Pandey, S. Kumar, N. Kotwal, *Thyroid Storm: Clinical Manifestation, Pathophysiology, and Treatment*, IntechOpen, 2020.
- [6] C. Muller, P. Perrin, B. Faller, S. Richter, F. Chantrel, Role of plasma exchange in the thyroid storm, *Ther. Apher. Dial.* 15 (6) (2011) 522–531.
- [7] M. Chong, A.J. Lopez-Magallon, L. Saenz, M.S. Sharma, A.D. Althouse, V.O. Morell, et al., Use of therapeutic plasma exchange during extracorporeal life support in critically ill cardiac children with thrombocytopenia-associated multi-organ failure, *Front. Pediatr.* 5 (2017).
- [8] F. Laverdure, L. Masson, G. Tachon, J. Guihaire, F. Stephan, Connection of a renal replacement therapy or plasmapheresis device to the ECMO circuit, *Asaio J.* 64 (1) (2018) 122–125.