

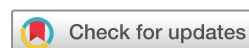# BMJ Open Evaluation of capillary pathologies by nailfold capillaroscopy in patients with psoriasis vulgaris: study protocol for a prospective, controlled exploratory study

Christine Fink,<sup>1</sup> Samuel Kilian,<sup>2</sup> Ines Bertlich,<sup>1</sup> Elti Hoxha,<sup>1</sup> Felicitas Bardehle,<sup>1</sup> Alexander Enk,<sup>1</sup> Holger A Haenssle<sup>1</sup>

**To cite:** Fink C, Kilian S, Bertlich I, *et al.* Evaluation of capillary pathologies by nailfold capillaroscopy in patients with psoriasis vulgaris: study protocol for a prospective, controlled exploratory study. *BMJ Open* 2018;**8**:e021595. doi:10.1136/bmjopen-2018-021595

► Prepublication history for this paper is available online. To view these files, please visit the journal online (<http://dx.doi.org/10.1136/bmjopen-2018-021595>).

Received 9 January 2018  
Revised 12 July 2018  
Accepted 13 July 2018



© Author(s) (or their employer(s)) 2018. Re-use permitted under CC BY-NC. No commercial re-use. See rights and permissions. Published by BMJ.

<sup>1</sup>Department of Dermatology, University of Heidelberg, Heidelberg, Germany

<sup>2</sup>Institute of Medical Biometry and Informatics, University of Heidelberg, Heidelberg, Germany

## Correspondence to

Holger A Haenssle;  
[Holger.Haenssle@med.uni-heidelberg.de](mailto:Holger.Haenssle@med.uni-heidelberg.de)

## ABSTRACT

**Introduction** Psoriasis vulgaris was shown to be an independent factor increasing the risk of several comorbidities such as obesity, diabetes and dyslipidaemia with an increased risk of stroke and myocardial infarction. We hypothesise that early endothelial dysfunction, which plays a crucial role in the pathogenesis of atherosclerosis, may be detected by digital video nailfold capillaroscopy (DVNC) at the level of the dermal capillary microvasculature as a surrogate parameter. Nailfolds represent the only body site allowing for a non-invasive assessment of the capillary microvasculature at a horizontal plane. DVNC is a well-established diagnostic tool for in vivo assessment of the peripheral microcirculation by evaluating the morphology of dermal papillary capillaries. To date, reports on morphological changes of the non-lesional nailfold capillaries in patients with psoriasis vulgaris are scarce and the existing data are not conclusive.

**Methods and analysis** This is a prospective, single-centre, non-randomised, controlled, exploratory study assessing the capillary patterns in 100 subjects affected by psoriasis vulgaris. Non-lesional nailfold capillaries will be imaged by means of DVNC (Optilia Digital Capillaroscopy System, Optilia Instruments AB, Sollentuna, Sweden) in 50 patients affected by psoriasis vulgaris and 50 healthy controls. Assessments will include a qualitative, descriptive analysis of the nailfold capillaries' morphology, as well as a quantitative investigation (frequency, extent) of changes in capillary patterns. Moreover, patients' characteristics associated with the manifestation of nailfold capillaries' pathologies including well-known cardiovascular risk markers will be studied.

**Ethics and dissemination** Ethical approval was provided by the ethic committee of the medical faculty of the University of Heidelberg (Ethics approval number S-447/2017). The design and the final results of the study will be published and made available to the public.

**Trial registration number** DRKS00012856.

## INTRODUCTION

Digital video nailfold capillaroscopy (DVNC) is routinely used for in vivo assessment of the peripheral microcirculation by evaluating the morphology of dermal papillary capillaries.<sup>1</sup> Long before onset of clinical symptoms, pathological capillary patterns may be observed in a number of systemic diseases, which are

## Strengths and limitations of this study

- Until today, there are only very few prospective, controlled studies investigating the frequency and extent of morphological changes of nailfold capillaries in patients with psoriasis vulgaris.
- Within this study, several patient characteristics and their associated specific capillaroscopy patterns will be investigated in a prospective controlled setting on an unprecedented scale.
- Since this is an exploratory study, limitations arise from the small number of subjects in both groups. Moreover, a formal sample size calculation is not feasible due to the absence of a priori knowledge.

accompanied by vascular damage. Therefore, DVNC might be helpful to define surrogate parameters indicative of initial manifestation of cardiovascular disease.<sup>2</sup> Additionally, capillary abnormalities were shown to potentially reflect the severity and long-term prognosis of underlying diseases. For instance, in systemic sclerosis, an association between a decreased capillary density and the development and the severity of pulmonary arterial hypertension was detected.<sup>3</sup>

Psoriasis vulgaris is a common chronic skin disease which is accompanied by a number of comorbidities that are possibly induced by a chronic, low-grade, systemic inflammation leading to vascular insufficiency and finally to clinically relevant atherosclerosis.<sup>2 4 5</sup> Atherosclerosis in patients with psoriasis was shown to be caused by a transfer of inflammatory cells and cytokines from the skin to endothelial tissue and internal organs causing systemic inflammation.<sup>2 5 6</sup> Endothelial dysfunction is often used as a surrogate marker for atherosclerosis and several studies have shown impaired endothelial function in patients with moderate to severe psoriasis or psoriatic arthritis.<sup>2 6 7</sup> Besides broad evidence

for an increased risk of large vessel atherosclerosis, previous studies also indicated changes of the microvasculature in the papillary dermis of psoriatic plaques and the synovia of psoriatic joints.<sup>8,9</sup> However, until today, only little is known about changes in the microcirculation in non-lesional skin of patients with psoriasis. The reported data are controversial with regard to pathologies of nailfold capillaries, which most probably reflects the polyetiology and polymorphology of psoriasis. In one of the earliest studies, Redisch *et al* revealed tortuous capillaries with tight terminal convolutions in lesional and non-lesional skin of patients with psoriasis.<sup>10</sup> A decreased capillary density, shorter capillaries, more nailfold haemorrhages and sluggish blood flow in patients with psoriasis arthritis were observed by Zaric *et al* when compared with healthy controls.<sup>11</sup> A pattern with shorter and more tortuous capillaries was significantly correlated with periungual psoriatic plaques, nail pitting, onycholysis and the extent of the involved body surface in a study by Ohtsuka *et al*.<sup>12</sup> A study by Ribeiro *et al* showed a lower capillary density, increased avascular areas and an increased number of coiled capillaries in the nailfold of patients with psoriasis.<sup>13</sup> Finally, Bushan *et al* reported a significantly decreased capillary loop density and a reduction of arterial and venous capillary limb diameters but found no other of the previously described morphological abnormalities in any of the patients.<sup>14</sup>

The aim of our exploratory study is to generate hypotheses concerning the morphology, frequency and the extent of nailfold capillary changes in patients with psoriasis vulgaris and to identify patient characteristics possibly associated with specific pathological DVNC patterns. We hypothesise that early endothelial dysfunction as caused by the systemic inflammatory immune response in patients with psoriasis may be detected by DVNC at the level of the dermal capillary microvasculature. In addition, this exploratory study will provide the necessary prerequisites for a full-scale study with a formal sample size calculation since there is only little *a priori* knowledge.

## DESIGN/METHODS

### Study design and objectives

This is a prospective, single-centre, non-randomised, controlled exploratory study assessing the capillary patterns in 100 individuals by means of DVNC. The primary objective of this study is to generate hypotheses regarding the frequency, the extent and the morphology of capillary patterns in non-lesional skin of 50 patients that are either affected by psoriasis vulgaris alone (group A) or by psoriasis vulgaris in combination with accompanying psoriasis arthritis (group B) compared with 50 healthy subjects (group C) (figure 1). A secondary objective of this study is to identify patient characteristics that are statistically associated with specific DVNC patterns (eg, psoriasis severity, nail psoriasis, age, gender, duration of the disease, manifest cardiovascular diseases and circulating markers of endothelial damage and inflammation).

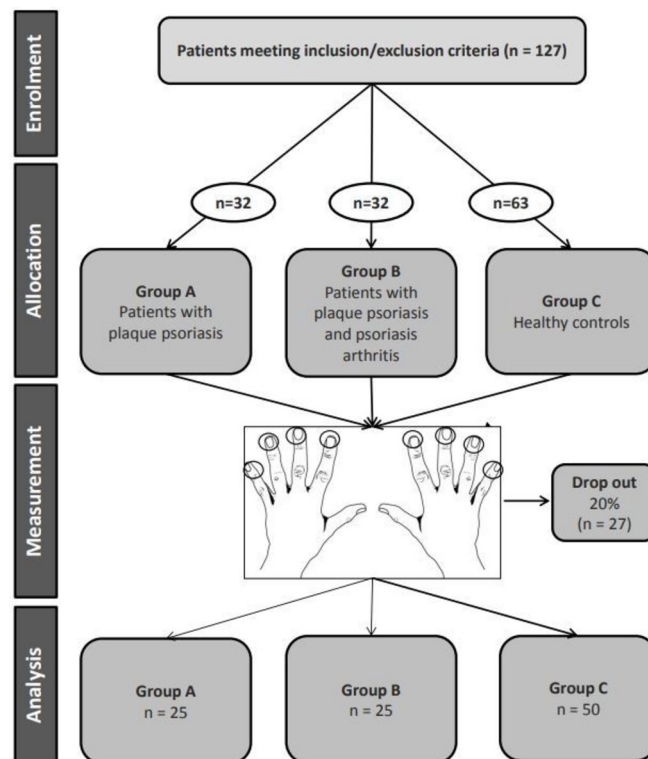


Figure 1 Flowchart of the study.

### Criteria for inclusion/exclusion

Inclusion criteria for group A and B are: patients  $\geq 18$  and  $\leq 80$  years of age with the diagnosis of chronic moderate to severe plaque psoriasis (defined as involved Body Surface Area (BSA)  $\geq 10\%$  and/or Psoriasis Area and Severity Index (PASI) score  $\geq 10$  and Dermatology Quality of Life Index (DLQI)  $\geq 10$ ) with or without psoriatic arthritis for at least 6 months (duration since diagnosis may be reported by the patient). Exclusion criteria for groups A and B are: patients under current exposure to any antipsoriatic or immunosuppressive systemic therapy (discontinuation for at least 4 weeks prior to DVNC is mandatory), patients with any other skin disease or therapy affecting the area of interest for DVNC and subjects with non-plaque forms or drug-induced psoriasis as well as active ongoing inflammatory diseases other than psoriasis that might confound study evaluations. Inclusion criteria for group C (healthy subjects) are: patients  $\geq 18$  and  $\leq 80$  years of age with no skin disease and no inflammatory rheumatic or cardiovascular disease. Patients with any skin disease affecting the area of interest for DVNC or any active ongoing inflammatory disease that might confound study evaluations will be excluded. Patients will be excluded from all three groups if any cosmetic procedure involving the nailfold area was performed over the last 4 weeks since potential microtraumata may lead to false-positive results in DVNC.<sup>15 16</sup>

### Methods

In this study, the nailfold capillaries of 100 individuals will be evaluated by DVNC (Optilia Digital Capillaroscopy System, Optilia OP-120 021, Optilia Instruments

**Table 1** Parameters and morphological findings in capillaroscopy<sup>15–21</sup>

| Parameter               | Definition   | Physiological image                |
|-------------------------|--|------------------------------------|
| Capillary morphology    | Vascular structure   | U-shaped, parallel to nail surface |
| Capillary density       | Number of capillaries per linear mm  | >9–10/linear mm                    |
| Capillary loop diameter | Distance between afferent and efferent loop  | <20 µm                             |
| Capillary enlargement   | >20 µm loop diameter   | Usually absent                     |
| Megacapillaries         | Homogeneously enlarged loops with a diameter >50 µm  | Absent                             |
| Capillary blood flow    | Blood circulation in the capillary   | Dynamic, no stasis/thrombosis      |
| Tortuosity              | Afferent and efferent portion cross at least two times   | Usually absent                     |
| Haemorrhages            | Extravasal detection of erythrocytes or their degradation products (type A: point-like microbleeding, type B: larger confluent bleeding) | Usually absent                     |
| Elongation              | Increased length of the capillaries by 50% or 350 µm   | Usually absent                     |
| Ramification            | Abnormal connections between afferent and efferent portion or for example, tortuous, branching, bushy or coiled                          | Absent                             |
| Capillary loss          | Multifocal (avascular areas) or diffuse loss of capillaries  | Absent                             |
| Pericapillary oedema    | Pericapillary increase in interstitial fluid   | Absent                             |

AB, Sweden) (figure 1). DVNC will be performed with low magnification (x20; for global evaluation of the entire nailfold area) and high magnification (x200; for more detailed observation of separate capillaries). Nailfolds of the second to the fifth finger of both hands will be examined. For the high magnification setting, a total of 32 pictures (four consecutive images per nailfold, each covering 1 mm) will be taken.<sup>15 16</sup> For standardisation and quality assurance, the DVNC is performed after 15–20 min of acclimatisation at room temperature in a sitting position. Smoking and caffeinated beverages should be avoided at least 4 hours before DVNC to avoid capillary constriction. In our study, a semiquantitative image analysis based on the microangiopathy evolution score presented by Cutolo *et al* will be applied.<sup>15</sup> The intra-rater and inter-rater reliability of this semiquantitative scoring algorithm has been demonstrated.<sup>17</sup> Interpretation of findings will be based on criteria established by the European League Against Rheumatism (EULAR) study group.<sup>18</sup> Several capillaroscopic parameters will be evaluated and scored, for example, presence of enlarged (>20 µm loop diameter) and giant capillaries (loop diameter >50 µm), haemorrhages and/or haemosiderin deposits, capillary loss (<9–10 capillaries per linear mm counted at the distal row of the nailfold), disorganisation of the vascular array (distribution and orientation) and ramified capillaries/neoangiogenesis (tortuous, branching, bushy, coiled) (table 1). Optionally, further morphological characteristics may be described. To evaluate patient characteristics possibly associated with specific DVNC patterns, the following parameters will prospectively be assessed: the PASI score, presence of nail psoriasis such as pitting, onycholysis, hyperkeratosis, discolouration, disfiguring or haemorrhages, presence of psoriasis arthritis, demographic and clinical data (eg, age, gender, duration of the disease, drug intake, circulating

markers of endothelial damage and inflammation (table 2), accompanying medical conditions (including history of cardiovascular disease)).

### Statistical considerations

This is the first exploratory study investigating capillary pathologies by DVNC in patients with psoriasis vulgaris since there is only little a priori knowledge about the frequency and extent of morphological changes of nailfold capillaries in patients with psoriasis vulgaris. Thus, a formal sample size calculation is not possible. This exploratory study will provide the necessary prerequisites for a formal sample size calculation for a full-scale study.

A total of 100 complete and evaluable data sets will allow obtaining a first impression of the potential impact of psoriasis on capillary pathologies by descriptive statistics. It is planned to investigate 50 patients with psoriasis

**Table 2** Circulating markers of endothelial damage and inflammation

| Parameter                                    | Standard values (SI units) |
|--|----------------------------|
| C reactive protein (CRP)                     | <0.005 g/L                 |
| Von Willebrand factor                        | 50%–160%                   |
| Fibrinogen                                   | 150–350 mg/dL              |
| Leucocytes                                   | 4–10×10 <sup>9</sup> /L    |
| Blood sedimentation                          | 0–20 mm/hour               |
| D-dimer                                      | ≤300 µg/L                  |
| Total cholesterol (TC)                       | 3.88–5.15 mmol/L           |
| Triglycerides                                | <2.82 mmol/L               |
| High-density lipoprotein cholesterol (HDL-C) | ≥1.04 mmol/L               |
| Low-density lipoprotein cholesterol (LDL-C)  | ≤3.36 mmol/L               |

vulgaris alone or psoriasis vulgaris accompanied by psoriasis arthritis and to compare the results to 50 healthy subjects. The resulting group allocation is sufficient to determine an effect size of 0.7 (Cohen's d) with a t test at 5% significance level and 80% power. Taking into account a dropout rate of 20%, at least 127 patients shall be recruited. All endpoints will be analysed descriptively by tabulation of the measures of the empirical distributions. Depending on the scale level of the variables, means, SD, medians and first and third quartiles, as well as either minimum and maximum or absolute and relative frequency, will be reported. Descriptive p values of the corresponding statistical tests comparing results of patients with healthy subjects will be given, together with the associated 95% CIs. When appropriate, graphical methods will be used to visualise the findings.

### Ethical considerations, dissemination plan and regulatory obligations

The study is conducted in accordance with the Declaration of Helsinki principles (2013), applicable local government regulations and independent Ethics Committee policies and procedures. Before initiation of the study, the protocol was presented and approved. The design and the final results of the study will be presented at meetings and congresses, and will be published in written form in international scientific journals.

### Recruitment and status of the study

Ethical approval was granted in September 2017. Planned date of first enrolment is July 2018. The estimated time required for recruitment of 96 patients is 12 months. The total duration of the study is expected to be 24 months, including statistical analysis.

### Patient and public involvement

Patients or public were not involved in the design or conduct of the study. Study results will be made available to the public via press releases as launched by the media departments of the authors' institutions.

**Contributors** CF, SK, IB, EH, AE and HAH participated in the development and the implementation of the study (writing of the protocol, submission to ethics committee, data management). CF, SK, IB, EH, FB, AE and HAH helped to draft and to review the paper. All authors read and approved the final manuscript.

**Funding** This work was supported by a grant from Novartis Pharma GmbH, Nürnberg, Germany.

**Competing interests** None declared.

**Patient consent** Not required.

**Ethics approval** Independent ethicscommittee of the medical faculty of the University of Heidelberg (Ethics approval numberS-447/2017).

**Provenance and peer review** Not commissioned; externally peer reviewed.

**Open access** This is an open access article distributed in accordance with the Creative Commons Attribution Non Commercial (CC BY-NC 4.0) license, which permits others to distribute, remix, adapt, build upon this work non-commercially, and license their derivative works on different terms, provided the original work is properly cited, appropriate credit is given, any changes made indicated, and the use is non-commercial. See: <http://creativecommons.org/licenses/by-nc/4.0/>.

### REFERENCES

- Smith V, Thevissen K, Trombetta AC, et al. Nailfold capillaroscopy and clinical applications in systemic sclerosis. *Microcirculation* 2016;23:364–72.
- Martínez-Sales V, Vila V, Ricart JM, et al. Increased circulating endothelial cells and microparticles in patients with psoriasis. *Clin Hemorheol Microcirc* 2015;60:283–90.
- Hofstee HM, Vonk Noordegraaf A, Voskuyl AE, et al. Nailfold capillary density is associated with the presence and severity of pulmonary arterial hypertension in systemic sclerosis. *Ann Rheum Dis* 2009;68:191–5.
- Nast A, Boehncke WH, Mrowietz U, et al. S3 - Guidelines on the treatment of psoriasis vulgaris (English version). Update. *J Dtsch Dermatol Ges* 2012;10(Suppl 2):S1–s95.
- Gyldenløve M, Jensen P, Løvendør MB, et al. 'Short-term treatment with methotrexate does not affect microvascular endothelial function in patients with psoriasis'. *J Eur Acad Dermatol Venereol* 2015;29:591–4.
- Gonzalez-Juanatey C, Llorca J, Amigo-Díaz E, et al. High prevalence of subclinical atherosclerosis in psoriatic arthritis patients without clinically evident cardiovascular disease or classic atherosclerosis risk factors. *Arthritis Rheum* 2007;57:1074–80.
- Pirro M, Stingeni L, Vaudo G, et al. Systemic inflammation and imbalance between endothelial injury and repair in patients with psoriasis are associated with preclinical atherosclerosis. *Eur J Prev Cardiol* 2015;22:1027–35.
- Barton SP, Abdullah MS, Marks R. Quantification of microvascular changes in the skin in patients with psoriasis. *Br J Dermatol* 1992;126:569–74.
- Espinoza LR, Vasey FB, Espinoza CG, et al. Vascular changes in psoriatic synovium. A light and electron microscopic study. *Arthritis Rheum* 1982;25:677–84.
- Redisch W, Messina EJ, Hughes G, et al. Capillaroscopic observations in rheumatic diseases. *Ann Rheum Dis* 1970;29:244–53.
- Zaric D, Clemmensen OJ, Worm AM, et al. Capillary microscopy of the nail fold in patients with psoriasis and psoriatic arthritis. *Dermatologica* 1982;164:10–14.
- Ohtsuka T, Yamakage A, Miyachi Y. Statistical definition of nailfold capillary pattern in patients with psoriasis. *Int J Dermatol* 1994;33:779–82.
- Ribeiro CF, Siqueira EB, Holler AP, et al. Periungual capillaroscopy in psoriasis. *An Bras Dermatol* 2012;87:550–3.
- Bhushan M, Moore T, Herrick AL, et al. Nailfold video capillaroscopy in psoriasis. *Br J Dermatol* 2000;142:1171–6.
- Cutolo M, ed. *Atlas of capillaroscopy in rheumatic diseases*. Milano: Elsevier Srl, 2010.
- Sander O, Sunderkötter C, Kötter I, et al. Kapillarmikroskopie Durchführung und Nomenklatur. *Z Rheumatol* 2010;69:253–62.
- Smith V, Pizzorni C, De Keyser F, et al. Reliability of the qualitative and semiquantitative nailfold videocapillaroscopy assessment in a systemic sclerosis cohort: a two-centre study. *Ann Rheum Dis* 2010;69:1092–6.
- Smith V, Beeckman S, Herrick AL, et al. An EULAR study group pilot study on reliability of simple capillaroscopic definitions to describe capillary morphology in rheumatic diseases. *Rheumatology* 2016;55:883–90.
- Klein-Weigel PF, Sunderkötter C, Sander O. Nailfold capillaroscopy microscopy – an interdisciplinary appraisal. *Vasa* 2016;45:353–64.
- Jung P, Trautinger F. Capillaroscopy. *J Dtsch Dermatol Ges* 2013;11:731–6.
- Chojnowski MM, Felis-Giemza A, Olesińska M. Capillaroscopy – a role in modern rheumatology. *Reumatologia* 2016;54:67–72.