

Strategies for maintaining penile size following penile implant

King Chien Joe Lee¹, Gerald B. Brock²

¹Department of Urology, National University Hospital, Singapore; ²Division of Urology, St Joseph's Health Care, London, ON, Canada

Correspondence to: Dr King Chien Joe Lee. National University Hospital, 1E Kent Ridge Road, NUHS Tower Block, Level 8, Singapore 119228;

Prof Gerald B. Brock. St Joseph's Hospital, Division of Urology, 268 Grosvenor Street, London, ON, N6A4V2. Email: joe_kc_lee@nuhs.edu.sg;

gebrock@sympatico.ca.

Introduction: Loss of penile size is a common complaint that can negatively affect patient satisfaction rates following successful penile prosthetic implant surgery.

Objective: The aim of this review is to describe the various strategies that have been used to maintain penile length or girth after the insertion of a penile prosthetic implant.

Methods: An extensive systematic literature review was performed, based on a search of the PUBMED database for articles published between 2002 to 2012. The following key words were used: penile prosthesis, implant, penile length, size, penis, enhancement, enlargement, phalloplasty, girth, lengthening, and augmentation. Only English-language articles that were related to penile prosthetic surgery and penile size were sought.

Discussion: Based on the results of our search, strategies were classified into 3 groups based on the timepoint in relation to the primary penile prosthetic insertion surgery, which included pre-insertion, intraoperative and post-insertion.

Conclusions: Strategies to preserve and potentially increase penile size are of great importance to all implanters. Besides traction therapies and surgeries to enhance perceived penile size, refinements in the surgical approach are simple ways to optimize penile length. A direct comparison of treatment outcomes evaluating the various approaches is not currently possible, owing to divergent study techniques. The implanting surgeon can best serve his patient by adopting a combination of different strategies that are individualized and specific to the patient's needs.

Keywords: Penile prosthesis; implant; penis size; length; enhancement



Submitted Dec 12, 2012. Accepted for publication Jan 15, 2013.

doi: 10.3978/j.issn.2223-4683.2013.01.05

Scan to your mobile device or view this article at: <http://www.amepc.org/tau/article/view/1459/2434>

Introduction

Penile size has been associated with male self-esteem and ego since ancient times. Across different cultures, references to penile enhancement exist in various forms. The Sadhus holy men of India and males of the Cholomec tribe in Peru used weights to increase their penile lengths. In the 16th century, men of the Topinama tribe of Brazil allowed poisonous snakes to bite their penises in order to enlarge them. The injection of exogenous substances or implants of foreign bodies under the genital skin to cause penile enlargement remains a common phenomenon in some parts of the world (1).

Insertion of a penile prosthetic implant (PPI) is typically reserved as the last line of treatment for drug-refractory erectile dysfunction (ED). Loss of penile length as a result of penile prosthesis placement is the most common postoperative patient complaint shown to reduce overall satisfaction with the procedure. There are several reasons for this (*Table 1*).

Firstly, the pathology behind the severe ED such as Peyronie's disease, neglected ischemic priapism, loss of cavernosal smooth muscle and previous radical prostatectomy may have resulted in tunical scarring or fibrosis that severely limits the elasticity of the tunica

Table 1 Causes for loss of penile size

Objective loss of penile size	Subjective loss of penile size
Conditions causing tunical scarring (Peyronie's disease)	Long history of ED with inaccurate recollection of erect penile size
Corporal fibrosis or loss of cavernous smooth muscle (ischemic priapism, previous radical prostatectomy)	Increased prepubic fat distribution
Loss of glanular engorgement	

albuginea. While not apparent in a flaccid penis, it becomes obvious after a PPI has been inserted and inflated.

Secondly, many patients who underwent PPI insertion may have a history of ED lasting many months or years. This could affect the accuracy of their recollection of what their penile sizes were prior to the onset of their condition.

Thirdly, an inflated PPI fills up only the corporal bodies of the penis and has no impact on glanular engorgement, which is a physiological phenomenon in normal erections. This lack of glanular swelling may contribute to the perception of decreased penile size.

Fourthly, men who require PPI are usually in the older age group. As a man ages or puts on weight, the fat in the prepubic region has a tendency to increase and engulf the penile shaft. This phenomenon of a partially "buried penis" may affect the patient's perception of penile length after PPI.

As with other sexual dysfunction therapies, the outcome of PPI surgery are largely dependent on patient and partner satisfaction. Most frequent implanters will realize that perceived inadequacy of penile size, be it penile girth or penile length, are practical issues that need to be addressed in clinical practice, and may be best suited for a full discussion pre-operatively, to set realistic expectations.

In this review article, we will look at the evidence evaluating penile shortening after PPI, including the technical aspects of PPI insertion which can lead to the loss of postoperative penile size.

We will also review the various techniques that have been described in literature to address patient concerns. Some of these techniques can produce a measurable change in penile size, while others may merely work by producing a subjective perception of change, which nonetheless, is often sufficient to address patient concerns.

Does PPI insertion really cause a loss of penile size?

There are studies in the literature that seek to answer this question in an objective manner.

In normal men, a close correlation between stretched

penile length with erect penile length has been shown (2).

Deveci S *et al.* measured the stretched flaccid penile length (SPL) of 56 patients undergoing their first implant surgery pre-operatively and 6 months after (3). Although 40 out of 56 patients (72%) reported a subjective decrease in penile length, there was no significant difference in terms of objective SPL measurements taken before and after surgery. Despite the perceived shortening, there was no overall difference in EF domain scores between men who complained of penile length loss and those who did not.

In a study by Wang *et al.*, the penile lengths of 11 patients who had full erections after intracavernous injections (ICI) done at the time of penile duplex ultrasonography before surgery was compared with measurements 1 year after PPI insertion (4). The mean penile length with PPI was 12.5 cm compared to that induced by ICI, which was 13.2 cm, suggesting a mean erect length loss of 0.7 cm.

Based on the results of our search, strategies were classified into 3 groups based on the timepoint in relation to the primary penile prosthetic insertion surgery, which included pre-insertion, intraoperative and post-insertion (*Table 2*).

Pre-insertion strategies

Traction therapy has been used in the fields of plastic, maxillofacial and orthopedic surgery for decades. The effect of prolonged traction has been studied in skin, bone, muscle and Dupuytren's contractures. The underlying mechano-transduction induces actual tissue growth, and not just merely stretching the tissue (5).

The regular application of an external penile traction device can provide some degree of penile length gain in men with short penises (6,7).

In a pilot study involving 10 men with penile length loss due to radical prostatectomy, prosthesis explantation or Peyronie's disease, Levine *et al.* found that applying external traction therapy (ETT) 2-4 hours daily for 2-4 months prior to prosthesis surgery can increase SPL by an average of 1.5 cm. No subjective or objective penile length loss was observed in this group of patients after the surgery (5).

Table 2 3-stage strategies for maintaining penile size after PPI

Pre-insertion	External traction therapy
	Vacuum erection device
	Surgery at center of excellence
	Immediate PPI (for refractory ischemic priapism)
Intraoperative	New length measurement technique for IPP
	Non-corporal dilation technique
	Ventral phalloplasty
	Suspensory ligament release
	Suprapubic lipectomy
Post-insertion	Augmentation corporoplasty
	MUSE
	PDE5 inhibitors
	Revision of IPP with larger cylinders after intracorporal stretching
	Delayed enhancement surgeries (ventral phalloplasty, suspensory ligament release, suprapubic lipectomy)

The early and daily use of a vacuum erection device (VED) soon after radical prostatectomy may lower the likelihood of penile length loss. In a study of post-radical prostatectomy patients, Dalkin *et al.* found that only 1/36 (3%) of patients had a decrease in SPL of > or =1.0 cm when VED is used regularly after surgery. This decrease in penile length loss is significant when compared to earlier studies where 48% of men after surgery had a significant reduction in SPL ($P<0.0001$) (8). In recent months, there has been interest in the use of VED pump 2-3 months prior to PPI surgery because preliminary studies suggest that preoperative stretching with a VED may allow longer cylinder placements at the time of the penile prosthetic surgery (9).

The choice of surgeon is likely to have an impact on eventual penile length after PPI. A frequent implanter (widely considered as a surgeon who inserts more than 25 PPIs per year) is likely to use a longer PPI cylinder compared to an infrequent implanter. In an outcome analysis study comparing 57 penile prostheses implanted by a multiple surgeon group versus 57 penile prostheses placed by a single surgeon in a center of excellence (COE), Henry *et al.* found that the median cylinder length of implants placed by the COE surgeon was 2 cm greater than those placed by the multiple surgeon group ($P<0.0001$). More than 82% of implants placed by the COE surgeon had cylinders that were 17 cm or longer, with 37% having cylinder lengths between 20-22 cm. This was in contrast to the multiple surgeon group, whereby more than 55% of implants had cylinders that were less than 17 cm with only 14.3% having cylinder lengths between 20-22 cm. Median operative time was also considerably shorter

for the COE surgeon (34 vs. 94 minutes, $P<0.0001$) (10).

In patients with refractory ischemic priapism and corporal smooth muscle necrosis, where subsequent erectile dysfunction, corporal smooth muscle fibrosis and penile shortening are almost certain, Ralph DJ *et al.* advocates immediate insertion of PPI as a way to preserve penile length and restore sexual function. In his study involving 50 patients managed with immediate PPI, overall treatment satisfaction rate was 96% with no complaint of penile shortening. While this approach offers the advantages of an expeditious restoration of sexual function and the avoidance of a potentially difficult implant surgery brought on by dense corporal fibrosis, one may have to contend with a possibly higher rate of infection, which was 6% in this study (11).

Intra-operative strategies

When choosing the size of cylinders to be used, inadequate sizing or intentional downsizing by surgeons will have a direct impact on the final erect penile length. Before the arrival of IPP, synthetic intracavernosal semirigid rod penile prostheses were used extensively. Surgeons trained in the insertion of semirigid prostheses are often taught to downsize the rods to avoid distal erosions. This is not necessary with IPPs, where the risk of distal erosion is minimal.

In fact, a new length measurement technique for IPP has allowed larger cylinders to be inserted in primary implants with no increased risk of distal erosion after 24 months. The key points of this new technique are the addition of 1 cm length to the total measurement when the dilator

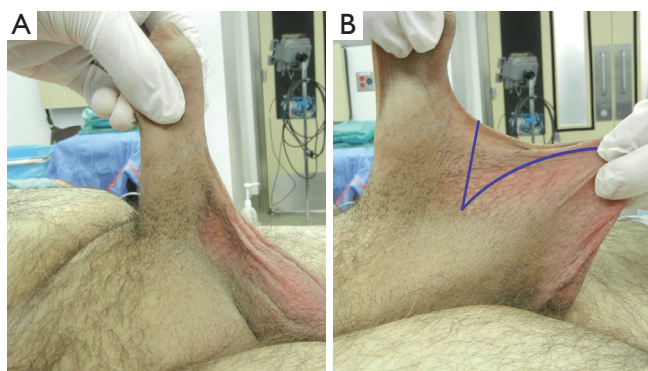


Figure 1 A. Identifying the ventral insertion of scrotum; B. Check mark incision for ventral phalloplasty.

does not drop down proximally into the lateral crux of the corpora onto a firm bone stopping point, and the addition of another 1 cm if the dilator does not go all the way out into the glans (12).

Conserving cavernous tissue during PPI surgery can help to preserve residual sexual function and penile length. And this can be achieved by withholding unnecessary corporeal dilation in primary implants, where corporeal fibrosis is minimal. In a randomized study of 100 patients with PPI, half had corporeal dilation while the other half did not. Average postoperative penile length improved by 1.1 cm in the group without corporeal dilation and decreased by 1.2 cm in the group with corporeal dilation at 6 months ($P < 0.05$) (13). A more intact spongy cavernosal tissue can become engorged and contribute to a more natural response during sexual stimulation.

To improve patient satisfaction and the overall perception of greater penile length, several penile enhancement procedures have been described.

Ventral phalloplasty

In pediatrics, scrotoplasty has been used to improve the projection of an inconspicuous penis. Using the same principle, ventral phalloplasty, which involved the “check mark” excision of penoscrotal web (*Figure 1*) followed by reapproximation of the dartos along the axis of the penile shaft, has been performed concurrently with PPI to enhance the perception of greater penile length. In a study by Miranda-Sousa *et al.*, 36/43 (83.7%) patients who had ventral phalloplasty during PPI reported an increase in their perception of penile length while 2/43 (4.6%) patients reporting a decrease. This was compared to the response

from 37 patients who did not have ventral phalloplasty during PPI, where 31/37 (83.8%) patients complained of penile shortening and only 1 (2.7%) reporting an increase in penile length.

The difference in patients reporting an increase in length compared to decreased length in both groups was statistically significant ($P < 0.001$) (14).

Suspensory ligament release

Incision of the penile suspensory ligament allows the penis to drop into a more dependent position, giving a perceived increase in penile length (15). This procedure is commonly used in combination with inverted V-Y skin plasty.

Borges *et al.* released the penile suspensory ligaments of 303 patients who underwent implantation of IPPs via the infrapubic approach. There was no complaint of penile shortening in all the patients. Penile lengths of 18 patients were measured in a substudy before and after PPI. A mean increase of 2.4 cm flaccid penile length and 1.7 cm erect penile length was observed.

Upon implantation, the device was inflated and the penis pressed downwards. This allowed the fundiform ligament to be incised, so that the suspensory ligament can be exposed and detached from the pubis (16).

To prevent reattachment of the suspensory ligament to the pubic bone, the implant was left partially inflated so that patient could apply downward pressure after surgery to maintain the distance between the pubis and the base of the penis. The use of a silicon spacer to prevent reattachment has also been described (17).

Data on the therapeutic benefits of penile suspensory ligament release is currently inconclusive. Implanters performing this procedure as part of PPI surgery will need to take into consideration the extended operative time, the risks of penile shortening from ligament reattachment contractures, the risk of wound infection and the potential complications associated with the use of a foreign body such as a silicon spacer.

Suprapubic lipectomy

In older men, weight gain together with changes in body fat deposition may cause the penis to be buried under excess skin of the panniculus, thus causing an apparent loss in penile length. Excision of the suprapubic fat pad with release of penile suspensory ligaments can create the perception of greater penile length (18). In a team setting,

where the plastic surgeon works alongside the urologist, suction lipectomy of the abdomen and pubic area combined with penile suspensory ligament release and abdominoplasty can yield satisfactory results (19).

Augmentation corporoplasty

Patch grafting is an established method to correct penile curvature in Peyronie's surgery. In augmentation corporoplasty, tissue grafts are used to elongate the penis during PPI insertion. The use of synthetic materials (Gore-Tex, silicone), human grafts (venous, dermal), and treated biological materials (InteXen, Tutoplast, AlloDerm) have been described (20,21). Synthetic materials are less preferred because of the intense fibrosis associated with their use. Human autologous grafts are good options if longer operative time and donor site complications are not of major concerns. Treated biological materials do not require harvesting and are less likely to incite fibrosis, but they are generally more costly. Augmentation corporoplasty is not commonly done as an adjunct to PPI, due to the costs and usually marginal improvement in final outcome.

Post-insertion strategies

The mechanical erections brought on by PPI are sometimes perceived as inadequate because of absent glans tumescence. This has a negative impact on patient satisfaction after PPI. To overcome this concern, intraurethral alprostadil, in the form of MUSE (medicated urethral system for erection) can be used with a functioning prosthesis to improve glans penis temperature, sensation and engorgement (22,23).

Besides alprostadil, PDE5 inhibitors such as sildenafil have also been used to achieve this goal. In a study by Mulhall *et al.* 32 post-PPI patients reported a statistically significant improvement in satisfaction score when PPI is used in conjunction with sildenafil (24). The benefit arose mainly from better glans engorgement.

The use of intracavernosal injections and vacuum erection devices are generally not used after PPI surgery as there is an inherent risk of prosthetic cylinder damage. In some centers, subcutaneous injection of polyacrylamide gel into the glans are offered as a relief measure. Through one needle point, polyacrylamide gel is injected using a fanning technique and the injection site is sealed with 5/0 vicryl to prevent seeping of the gel and bleeding (25). The usefulness of glans injection is limited by its short-lived results (average 5 months).

If not yet done at the time of PPI insertion, ventral phalloplasty, suprapubic lipectomy and penile suspensory ligament release procedures can be contemplated as part of an overall post-insertion strategy to recover perceptual penile length.

In cases of prolonged ischemic priapism or removal of a previously infected implant, severe corporal fibrosis may preclude the use of larger cylinders. In a study of 37 such patients, where it was impossible to dilate the corporal to 12 mm for standard-sized cylinders, smaller downsized cylinders were inserted to act as tissue expanders. Patients were encouraged to inflate their implant for up to 3 hours daily. After several months of intracorporal stretching, the patients were reoperated and wider and often longer standard-sized prosthetic cylinders can be substituted. For patients with previous infected explants, the substituted cylinders may be 2-4 cm longer (26).

In a separate case report, a patient with post-PPI penile shortening underwent vacuum erection device therapy twice daily for 10 minutes per session for approximately 1 year as well as 8 hours of penile traction therapy daily for 8 months. At the time of PPI revision, a prosthesis that was 20% longer in length was used which improved erect penile length by 4.4 cm. The post-PPI traction therapy also increased SPL by 2.3 cm (27).

Conclusions

Patient's perception of decreased penile size after PPI can negatively influence overall satisfaction and sexual quality of life measures. Strategies to preserve and potentially increase penile size are of great importance to all implanters. The strategies in this review target 3 stages of patient care; pre-insertion, intraoperative and post-insertion. Besides traction therapies and surgeries to enhance perceived penile size, refinements in the surgical approach to allow greater conservation of cavernosal smooth muscle and optimal sizing of the implant cylinders are simple ways to optimize penile length. A direct comparison of treatment outcomes evaluating the various approaches is not currently possible, owing to divergent study techniques across the small numbers of small studies with limited reported measures. The implanting surgeon can best serve his patient by adopting a combination of different strategies that are individualized and specific to the patient's needs.

We are hopeful that advancements in stem cell technology may one day allow surgeons to pre-operatively increase cavernosal smooth muscle content and improve

tunica albuginea elasticity, which are the bane of contemporary penile shortening after PPI.

Acknowledgements

None.

Footnote

Conflicts of Interest: The authors have no conflicts of interest to declare.

References

- Vardi Y, Har-Shai Y, Gil T, et al. A critical analysis of penile enhancement procedures for patients with normal penile size: surgical techniques, success, and complications. *Eur Urol* 2008;54:1042-50.
- Wessells H, Lue TF, McAninch JW. Penile length in the flaccid and erect states: guidelines for penile augmentation. *J Urol* 1996;156:995-7.
- Deveci S, Martin D, Parker M, et al. Penile length alterations following penile prosthesis surgery. *Eur Urol* 2007;51:1128-31.
- Wang R, Howard GE, Hoang A, et al. Prospective and long-term evaluation of erect penile length obtained with inflatable penile prosthesis to that induced by intracavernosal injection. *Asian J Androl* 2009;11:411-5.
- Levine LA, Rybak J. Traction therapy for men with shortened penis prior to penile prosthesis implantation: a pilot study. *J Sex Med* 2011;8:2112-7.
- Gontero P, Di Marco M, Giubilei G, et al. A pilot phase-II prospective study to test the 'efficacy' and tolerability of a penile-extender device in the treatment of 'short penis'. *BJU Int* 2009;103:793-7.
- Nikoobakht M, Shahnazari A, Rezaeidanesh M, et al. Effect of penile-extender device in increasing penile size in men with shortened penis: preliminary results. *J Sex Med* 2011;8:3188-92.
- Dalkin BL, Christopher BA. Preservation of penile length after radical prostatectomy: early intervention with a vacuum erection device. *Int J Impot Res* 2007;19:501-4.
- Pahlajani G, Raina R, Jones S, et al. Vacuum erection devices revisited: its emerging role in the treatment of erectile dysfunction and early penile rehabilitation following prostate cancer therapy. *J Sex Med* 2012;9:1182-9.
- Henry GD, Kansal NS, Callaway M, et al. Centers of excellence concept and penile prostheses: an outcome analysis. *J Urol* 2009;181:1264-8.
- Ralph DJ, Garaffa G, Muneer A, et al. The immediate insertion of a penile prosthesis for acute ischaemic priapism. *Eur Urol* 2009;56:1033-8.
- Henry G, Houghton L, Culkin D, et al. Comparison of a new length measurement technique for inflatable penile prosthesis implantation to standard techniques: outcomes and patient satisfaction. *J Sex Med* 2011;8:2640-6.
- Moncada I, Martínez-Salamanca JI, Jara J, et al. Inflatable penile prosthesis implantation without corporeal dilation: a cavernous tissue sparing technique. *J Urol* 2010;183:1123-6.
- Miranda-Sousa A, Keating M, Moreira S, et al. Concomitant ventral phalloplasty during penile implant surgery: a novel procedure that optimizes patient satisfaction and their perception of phallic length after penile implant surgery. *J Sex Med* 2007;4:1494-9.
- Hakky TS, Suber J, Henry G, et al. Penile enhancement procedures with simultaneous penile prosthesis placement. *Adv Urol* 2012;2012:314612.
- Borges F, Hakim L, Kline C. Surgical technique to maintain penile length after insertion of an inflatable penile prosthesis via infrapubic approach. *J Sex Med* 2006;3:550-3.
- Li CY, Kayes O, Kell PD, et al. Penile suspensory ligament division for penile augmentation: indications and results. *Eur Urol* 2006;49:729-33.
- Horton CE, Vorstman B, Teasley D, et al. Hidden penis release: adjunctive suprapubic lipectomy. *Ann Plast Surg* 1987;19:131-4.
- Adham MN, Teimourian B, Mosca P. Buried penis release in adults with suction lipectomy and abdominoplasty. *Plast Reconstr Surg* 2000;106:840-4.
- Austoni E, Guarneri A, Cazzaniga A. A new technique for augmentation phalloplasty: albugineal surgery with bilateral saphenous grafts--three years of experience. *Eur Urol* 2002;42:245-53; discussion 252-3.
- Sansalone S, Garaffa G, Djinovic R, et al. Simultaneous penile lengthening and penile prosthesis implantation in patients with Peyronie's disease, refractory erectile dysfunction, and severe penile shortening. *J Sex Med* 2012;9:316-21.
- Chew KK, Stuckey BG. Use of transurethral alprostadil (MUSE) (prostaglandin E1) for glans tumescence in a patient with penile prosthesis. *Int J Impot Res* 2000;12:195-6.
- Benevides MD, Carson CC. Intraurethral application of alprostadil in patients with failed inflatable penile prosthesis. *J Urol* 2000;163:785-7.

24. Mulhall JP, Jahoda A, Aviv N, et al. The impact of sildenafil citrate on sexual satisfaction profiles in men with a penile prosthesis in situ. *BJU Int* 2004;93:97-9.
25. Shaeer O. Supersizing the penis following penile prosthesis implantation. *J Sex Med* 2010;7:2608-16.
26. Wilson SK, Delk JR 2nd, Mulcahy JJ, et al. Upsizing of inflatable penile implant cylinders in patients with corporal fibrosis. *J Sex Med* 2006;3:736-42.
27. Moskovic DJ, Pastuszak AW, Lipshultz LI, et al. Revision of penile prosthesis surgery after use of penile traction therapy to increase erect penile length: case report and review of the literature. *J Sex Med* 2011;8:607-11.

Cite this article as: Lee KCJ, Brock GB. Strategies for maintaining penile size following penile implant. *Transl Androl Urol* 2013;2(1):67-73. doi: 10.3978/j.issn.2223-4683.2013.01.05