



Preoperative Diffusion Tensor Imaging in Supratentorial Intra-Axial Brain Tumors: Its Role in Predicting Tumor Histology and Prognosis as well in Surgical Planning and Resection

Ajay Singh¹ Gaurav Jain¹ Vinod Sharma¹ Shaveta Singh¹

¹Department of Neurosurgery, SMS Medical College and Hospital, Jaipur, Rajasthan, India

Address for correspondence Gaurav Jain, MBBS, Department of Neurosurgery, SMS Medical College and Hospital, Jaipur, Rajasthan, 302004, India (e-mail: drgauravjain9@gmail.com).

Asian J Neurosurg 2023;18:476–483.

Abstract

Objective There are a large number of prospective studies that use diffusion tensor imaging (DTI) to show the relationship between intracranial tumors and white matter (WM) fibers. We studied the role of DTI in supratentorial intra-axial (ST-IA) tumors of the brain in deciding the surgical approach with maximal resection and minimal or no deficit and in predicting the histological characterization of the tumor and the neurological outcome.

Methods A total of 91 cases of ST-IA tumors were included in our study. The neurological status of the patients was assessed preoperatively, and the tumor volume and DTI pattern were noted radiologically. Surgical plan was decided by the senior consultants of the neurosurgery department taking into consideration the findings of tractography and magnetic resonance imaging. The neurological status and the extent of resection were evaluated postoperatively, and the correlation between histopathology with DTI was studied.

Results Of the 91 patients, 25 had high-grade glioma (HGG), 60 had low-grade glioma (LGG), and 6 were metastatic lesions. Gross total excisions were done mostly in patients with DTI showing displaced fibers and subtotal/partial resections were done mostly in disrupted/infiltrated tracts, which was statistically significant. The correlation between histopathology and tractography revealed that intact/displaced tracts were seen mostly in LGG (79%), whereas 86% of HGG showed disrupted/infiltrated fibers; both were statistically significant.

Conclusion Preoperative DTI in ST-IA brain tumors is an important tool for deciding the appropriate surgical approach for maximal safe resection, thus improving the post-op neurological outcome in patients. It also helps in predicting the tumor histology while also serving as an important prognostication indicator.

Keywords

- ▶ diffusion tensor imaging
- ▶ white matter
- ▶ supratentorial intra-axial
- ▶ low-grade glioma
- ▶ high-grade glioma

article published online
September 13, 2023

DOI <https://doi.org/10.1055/s-0043-1772758>.
ISSN 2248-9614.

© 2023. Asian Congress of Neurological Surgeons. All rights reserved.

This is an open access article published by Thieme under the terms of the Creative Commons Attribution-NonDerivative-NonCommercial-License, permitting copying and reproduction so long as the original work is given appropriate credit. Contents may not be used for commercial purposes, or adapted, remixed, transformed or built upon. (<https://creativecommons.org/licenses/by-nc-nd/4.0/>)

Thieme Medical and Scientific Publishers Pvt. Ltd., A-12, 2nd Floor, Sector 2, Noida-201301 UP, India

Introduction

Intra-axial tumors are the most common brain tumors encountered by neurosurgeons. The challenge that surgeons face in dealing with these tumors is the proximity of these tumors to the eloquent areas,¹ damage to which can increase the morbidity in these patients. Diffusion tensor imaging (DTI) can assess the white matter (WM) tract orientation with respect to tumor location in numerous planes,^{2,3} so it is a good option to plan for surgical approach and path.^{4,5} We evaluated the role of DTI in planning the approach, pattern of tracts in various histologies, and neurological outcome.

Methods

The study was conducted in the Department of Neurosurgery of Sawai Maan Singh Medical College and Hospital, Jaipur, Rajasthan, India, from August 2019 to January 2021 after approval of the ethical committee of the institution. All the patients of supratentorial intra-axial tumors who fulfilled the inclusion criteria were included in the study after obtaining well-informed consent from patients and their relatives. The institute did not provide any funds or scholarships. In this prospective study, a total 91 patients were included.

Inclusion Criteria

Patients with supratentorial intra-axial (ST-IA) brain tumors in all age groups who were fit for surgery and follow-up were included in the study.

Exclusion Criteria

- Supratentorial extraparenchymal brain tumors and infratentorial tumors.
- Any contraindication to surgery or if the patient is unfit for surgery.
- Patients in whom magnetic resonance imaging (MRI) could not be done.

History taking and thorough neurological/clinical examination were done for all the patients included in the study. Preoperative MRI and DTI were done in all the patients and the preoperative tumor volume and pattern of tracts in tractography were evaluated. Surgical approach with site of corticotomy and extent of resection was planned by consultants of the neurosurgery department using sulcal/gyral pattern adjacent to the tumor in MRI and WM tract pattern in DTI in relation with the tumor, and the same consultants operated upon these patients.

The post-op neurologic status was assessed at first, post-operative day 7 and then at 3 weeks after surgery, and a comparison with the preoperative neurological status was done. After surgery, MRI was done at 3 weeks and the tumor volume was assessed compared with the presurgical volume. The relationship of the DTI findings with the extent of resection and tumor histology was studied.

Magnetic Resonance Imaging Protocol

A MR study was done using a 3-T MR system of Philips (3T-Ingenuia) having an encoding head coil of eight-element phased-array sensitivity.

Sequences seen were the following: T2-weighted, fluid-attenuated inversion recovery (FLAIR), diffusion-weighted imaging (DWI), and T1-weighted sequence with and without contrast.

Diffusion Tensor Imaging

It was done by a single-shot spin echo planar pulse sequence with repetition time of 3,000 microseconds, 94-microsecond echo time, thickness slice of around 2.5 mm, 92 × 88 matrix, and 90-degree flip angle with a nil slice gap. Using the regions of interest (ROI) for each tract, the corticospinal tract, optic radiations and tract, uncinate fascicle, inferior longitudinal fasciculus (ILF), and superior longitudinal fascicle (SLF) were made. DTI Studio was used to assess the images and eigenvector with maps of fractional anisotropy (FA). Direction of diffusion was described by FA. A higher FA in a voxel suggested movement, mostly in one direction/axis, and low FA indicated movement occurring in all three directions/axes. Different but specific color maps with standard coding were generated using their combination, with red (x, left-right), blue (z, craniocaudal), and green (y, anteroposterior), using intensity scale proportional to their FA. Formed images were thoroughly evaluated and then the tracts were labeled as displaced, infiltrated, and disrupted.

- **Displaced tracts** are defined as tracts showing normal or only slightly decreased FA, resulting from bulk mass displacement (– Figs. 1, 2).
- **Infiltrated** tracts are defined as tracts showing reduced anisotropy but that remained identifiable on color maps (– Figs. 3, 4).

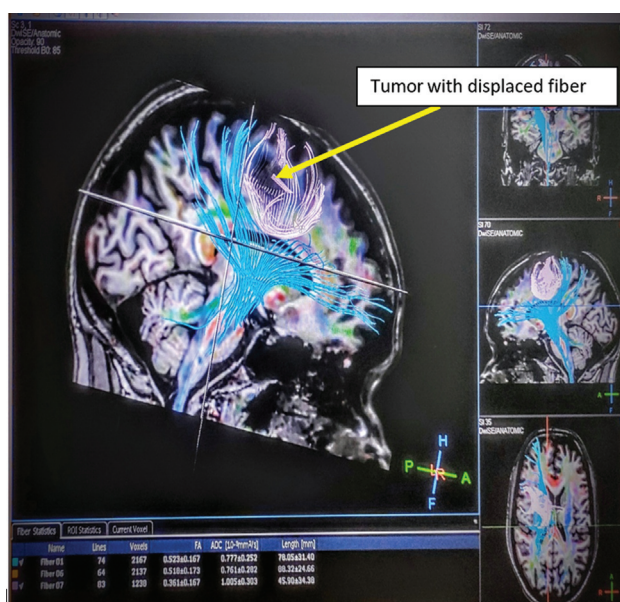

Fig. 1 Sagittal diffusion tensor imaging (DTI) of supratentorial intra-axial (ST-IA) brain tumor with displaced fascicles.

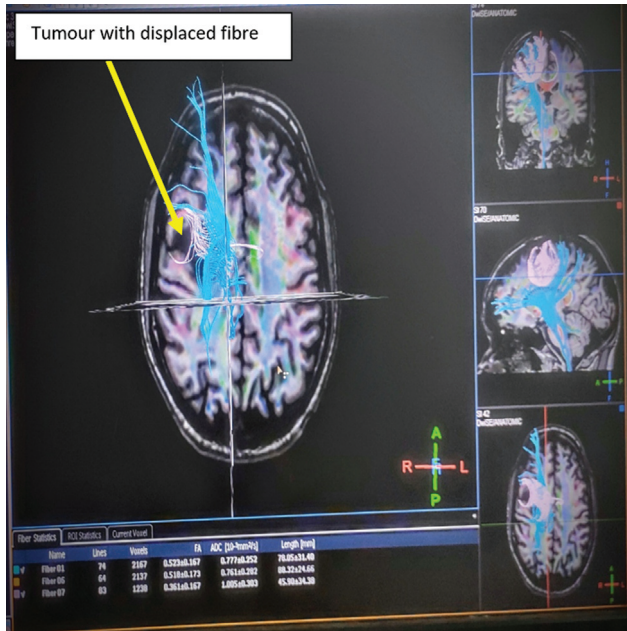


Fig. 2 Axial diffusion tensor imaging (DTI) of supratentorial intra-axial (ST-IA) brain tumor with displaced fascicles.

- A **disrupted** tract is defined as a tract showing isotropic (or near-isotropic) diffusion, such that it could not be identified on directional color maps (→Figs. 5, 6).

Tumor volume analysis: In low-grade gliomas, FLAIR sequences of MRI were used to assess the preoperative and postoperative tumor volumes, while in high-grade gliomas, postcontrast T1 images were assessed for the same using OSIRIX software. Small and large tumors were classified as preoperative tumor volume less than 100 cm³ and greater than 100 cm³,

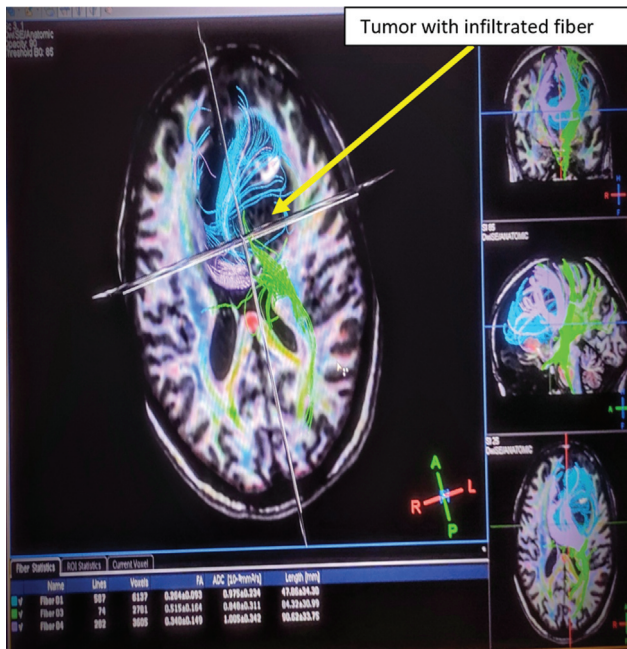


Fig. 3 Axial diffusion tensor imaging (DTI) of supratentorial intra-axial (ST-IA) brain tumor with infiltrated fascicles.

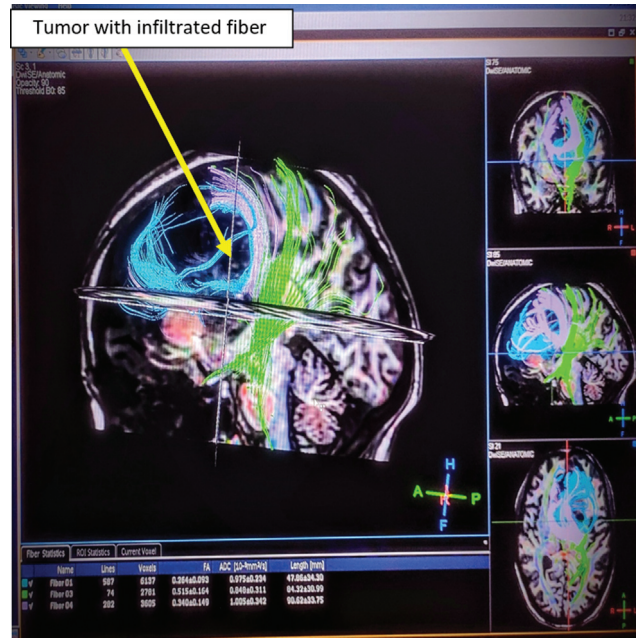


Fig. 4 Sagittal magnetic resonance (MR) images of supratentorial intra-axial (ST-IA) brain tumor with infiltrated fascicles.

respectively. The amount of tumor resected was assessed on postoperative MRI done at 3 weeks and classified as per the Berger classification^{6,7} with surgical outcome defined as total excision with postoperative volume less than 1 cm³, subtotal excision with residual volume of 1 to 10 cm³, and partial removal/excision with residual volume greater than 10 cm³.

Statistical analysis: Computer software SPSS was used for statistical analysis with percentages and proportions used to express categorical data with standard deviations and mean for assessable data as χ^2 test was used to analyze the difference in proportion. For tests, the level of significance was determined as 95% (p value <0.05).

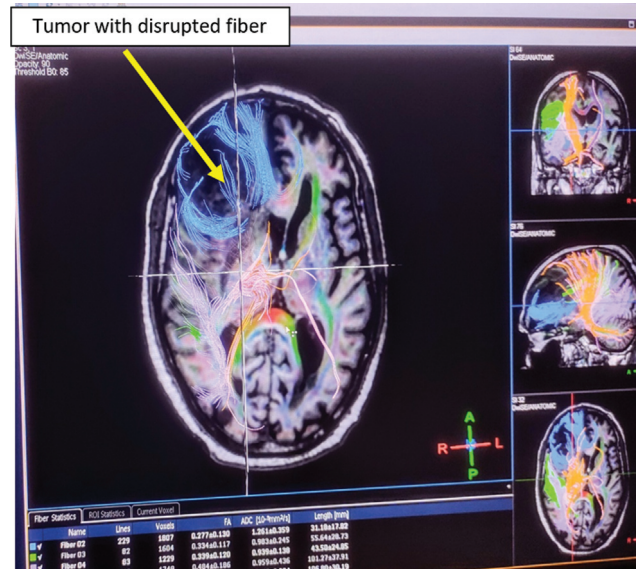


Fig. 5 Axial diffusion tensor imaging (DTI) images of supratentorial intra-axial (ST-IA) brain tumor with.

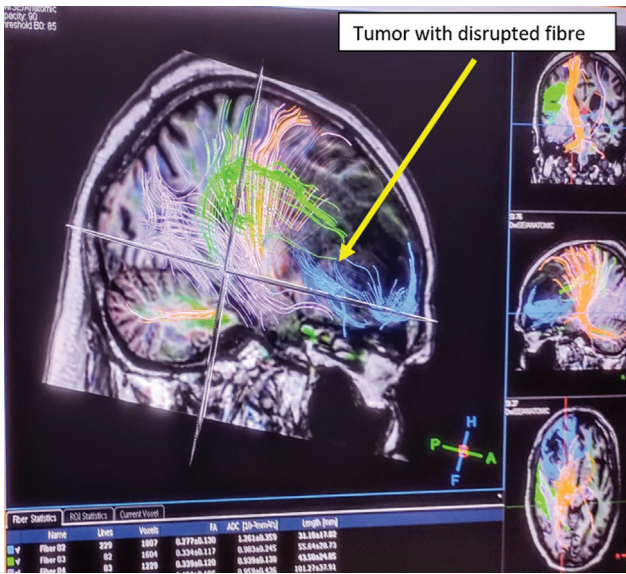


Fig. 6 Sagittal magnetic resonance (MR) images of supratentorial intra-axial (ST-IA) brain tumor with disrupted fascicles.

Table 1 Signs and symptoms preoperatively in our study

Preoperative neurologic examination	Total no. of patients	%
Seizure	41	45.05
Motor weakness	30	32.96
Headache	61	67.03
Behavior charges	14	15.38
Memory impairment	6	6.59
Sensory impairment	2	02.19
Language abnormality	4	04.39
Cognitive defect	16	17.58

Table 2 Different patterns of tracts in DTI in this study

Diffusion tensor imaging	Total no. of patients	%
Displaced	39	42.85
Infiltrated	33	36.26
Disrupted	19	20.87

Abbreviation: DTI, diffusion tensor imaging.

Results

Patient Population

Of the 91 patients included in the study, 61 (67%) were males and 30 (32.9%) were females. The mean age was 43 years (range: 15–81 years). Power weakness was present in 30 (32.9%) patients, speech/language abnormality in 04 (4.4%) patients, headache in 61 (67.03%) patients, behavior charges in 14 (15.38%) patients, seizure in 41 (45.05%) patients, and memory impairment in 6 (6.59%) patients, with 16 patients (17.5%) presenting with cognitive impairment (►Table 1).

In 44 patients (48.35%), tumors were present in the left cerebral hemisphere, while in the remaining 47 (51.64%) patients, tumors were present in right cerebral hemisphere. A frontal lobe pathology was seen in 34 (37%) patients, parietal lobe was involved in 11 (12.08%) patients, and temporal lobe was involved in 12 (13.18%) patients. Involvement of more than one lobe was observed in 26 (28.57%) patients (►Fig. 7).

DTI showed displaced fascicles in 39 (42.8%) patients, infiltrated fascicles in 33 (36.2%) patients, and disrupted fascicles in 19 (20.8%) patients (►Table 2).

On histopathological analysis, LGG was present in 60 patients, HGG in 25 patients, and metastatic lesions in 6 patients (►Table 3). Oligodendroglioma was present in 19 (20.87%) patients, glioblastoma (GBM) in 14 (15.38%) patients, neurocytoma in 3 (3.29%) patients, astrocytoma in 37 (40.65%) patients, oligoastrocytoma in 12 (13.18%) patients, and adenocarcinoma in 4 (4.34%) patients (►Fig. 8).

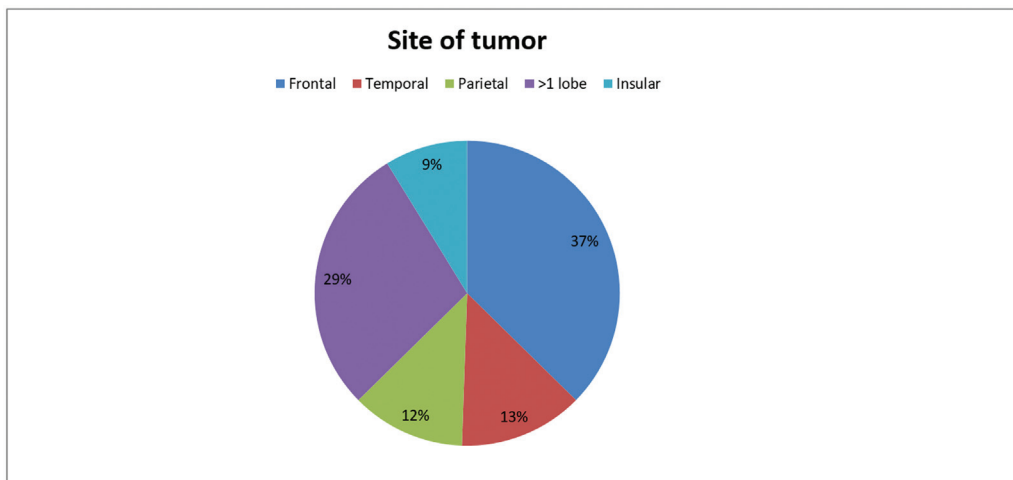


Fig. 7 Pie chart showing different sites of tumors in our study.

Table 3 Patients in different histology grades

Grade of tumor	Total no. of patients	%
Low-grade glioma	60	65.9
High-grade glioma	25	27.47
Metastasis	6	5.49

Surgical Outcome

Seventy-three (80.21%) patients had a tumor volume of less than 100 cm³ and 17 (18.68%) had a tumor volume greater than 100 cm³ preoperatively (►Table 4). Only 54 of 91 patients came for follow-up and their post-op MRI was done at 3 weeks to calculate the residual tumor volume. Due to the COVID-19 pandemic, our institution was turned into a dedicated COVID-19 treatment center, so many of the patients went to other regional hospitals for further chemoradiotherapy and were lost to follow-up.

In tumors less than 100 cm³, displaced tracts were seen in 19 patients preoperatively. In these patients, a postoperative tumor volume of less than 1 cm³ was seen in 12 patients (63.15%), while 5 patients had a tumor volume of 1 to 10 cm³ (26.3%) and 2 patients had a tumor volume of greater than 10 cm³ (10.5%) postoperatively. Infiltrated fascicles were present in nine patients, with one patient (11.1%) with a tumor volume of less than 1 cm³ postoperatively, six (66.6%) patients with a volume of 1 to 10 cm³, and two patients (22.2%) with tumor volume greater than 10 cm³. Disrupted tracts were seen in 10 patients in the same category of patients, with postoperative tumor volume less than 1 cm³ in one (10%) patient, 1 to 10 cm³ in three (30%) patients, and greater than 10 cm³ in 6 (60%) patients (►Table 5). Statistical analysis showed significant results on χ^2 test between the fascicle type and tumor residual volumes postoperatively, thus confirming that surgical resection is complete/maxi-

Table 4 Relationship of different tumor volumes in patients

Tumor volume, operative (cm ³)	Total no. of patients	%
< 100	73	80.21
> 100	17	18.68

imum in displaced fascicles and subtotal or partial resection done maximally in infiltrated/disrupted tracts (►Table 5).

Seven patients with a tumor volume greater than 100 cm³ had displaced/intact fascicles. Among these patients, postoperatively, one (14.2%) patient had a tumor volume of less than 1 cm³, two (28.57%) patients had a tumor volume of 1 to 10 cm³, and four (57.14%) patients had a tumor volume of greater than 10 cm³. Infiltrated fascicles were seen in six patients with a tumor volume greater than 100 cm³ and postoperatively no patient had tumor volume less than 1 cm³, two (33.33%) patients had a tumor volume of 1 to 10 cm³, and four (66.67%) patients had a tumor volume greater than 10 cm³. Disrupted fascicles were present in three patients and postoperatively a tumor volume less than 1 cm³ was seen in none of the patients, tumor volume of 1 to 10 cm³ was seen in one (33.33%) patient, and tumor volume greater than 10 cm³ was observed in two (66.67%) patients. Statistical analysis showed no significant difference in results with regard to fascicle involvement in the postoperative residual tumor volume in the greater than 100 cm³ category, suggesting that maximum patients with large tumors had subtotal or partial resections (►Table 6).

Histopathology was correlated with fascicle type in DTI in all patients. LGGs were seen in 35 (38.46%) patients, HGGs in 50 (54.94%) patients, and metastatic lesions in 6 (6.5%) patients. The pattern of fascicles in different histopathologic findings was studied. In the displaced fascicle category, 30

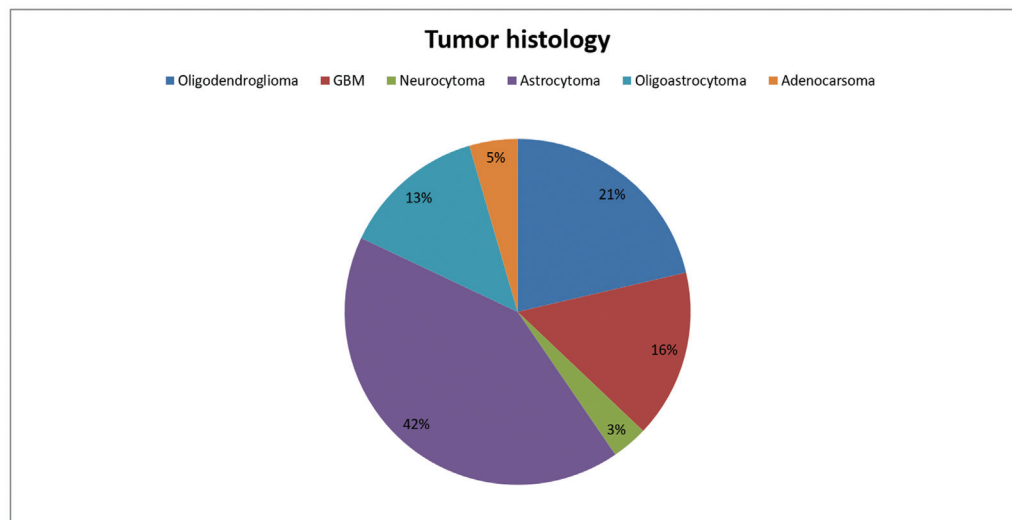
**Fig. 8** Pie chart showing different histological outcomes in our study. GBM, glioblastoma.

Table 5 Correlation between postoperative tumor volume and fiber type in < 100 cm³ pre-op tumor volume category

Type of fiber on DTI	Tumor volume of < 100 cm ³ preoperatively							
	N	< 1 cm ³ (n = 14)		1–10 cm ³ (n = 14)		> 10 cm ³ (n = 10)		p-Value
		N	%	N	%	N	%	
Intact/displaced fascicles	19	12	85.71	5	35.7	2	20	< 0.05
Infiltrated fascicles	9	1	7.14	6	42.85	2	20	0.14
Disrupted fascicles	10	1	7.14	3	21.42	6	60	0.04
Total	38	14	100	14	100	10	100	

Abbreviation: DTI, diffusion tensor imaging.

Table 6 Correlation between postoperative tumor volume and fiber type in >100 cm³ pre-op tumor volume category

Type of fiber on DTI	Tumor volume of > 100 cm ³ preoperatively							
	N	< 1 cm ³ (n = 14)		≤ 10 cm ³ (n = 14)		> 10 cm ³ (n = 10)		p-Value
		N	%	N	%	N	%	
Intact/displaced fascicles	7	1	14.2	2	28.57	4	57.14	0.0008
Infiltrated fascicles	6	0	0	2	33.33	4	66.67	0.8
Disrupted fascicles	3	0	0	1	33.33	2	66.67	0.89
Total	16	1		5		10		

Abbreviation: DTI, diffusion tensor imaging.

patients (76.92%) had LGGs, 7 patients (9.3%) had HGGs, and 2 patients (5.1%) had metastatic lesions. In infiltrated and disrupted fascicles, LGGs were seen in 5 (9.6%) patients, HGGs in 43 (82.69%) patients, and metastatic lesions in 4 (7.6%) patients. The relationship between the fascicle type on DTI and histopathology was statistically significant on χ^2 test. Thus, displaced fascicles were maximally seen in LGGs, while infiltrated or disrupted fascicles were mostly seen in HGGs and metastatic lesions (►Table 8, ►Fig. 9).

Improvement in the postoperative neurological status was found in 34 of 39 (86%) patients with displaced WM tracts, while in the remaining 5 patients, no improvement was seen. Also, improvement in the neurological status was seen in only 25 (48%) cases with infiltrated and disrupted

pattern of WM tracts, and in other 27 cases, there was no improvement postoperatively (►Table 7).

Discussion

Neuro-oncological surgeries demand a balance between maximal tumor resection and preservation of neurological functions. The maximal tumoral resection with radiotherapy or chemotherapy appears to be more effective and also diminishes chances of early recurrence.^{8–12} Safeguarding of the somatomotor, language, visual, and other eloquent cortical areas during resection improves the outcome of patients.^{6,7} In DTI, we can study the different patterns of WM tract involvement by the tumors as being intact/displaced, infiltrated, or damaged.¹³

Our study is unique in depicting the role of preoperative DTI in supratentorial tumors and presents a new tool to predict the tumor histology and help in surgical planning and resection while also serving as the prognostication indicator.

We studied 91 patients, comprising 61 males (67%) and 30 females (32%), with age ranging from 16 to 82 years. The most common location of tumors was found in the frontal lobes (37%), followed by the temporal (13%) and parietal regions (12%), and more than one lobe was seen involved in 29% of cases (►Table 1). The most common histopathology seen are astrocytomas (low and high grades), followed by oligodendroglioma, GBM, and oligoastrocytoma (►Fig. 8).

In our study, as described in previous studies, the WM tracts were classified as intact/displaced, infiltrated, and disrupted on the basis of direction of strands and their FA

Table 7 Relationship between type of fascicle in DTI with postoperative neurological status

Neurological status post-op	Displaced fascicles	%	Infiltrated/disrupted fascicles	%
	N = 39		N (33 + 19)	
Improved	34	86	25	48
Same/deteriorate	5	14	27	52
Total	39	100	52	100

Abbreviation: DTI, diffusion tensor imaging.

Note: p-value = 0.000111.

Chi-square value: 14.9.

Table 8 Correlation between various histopathologies and fiber type in DTI preoperatively in ST-IA brain tumors

Fiber type	Histopathological correlation with fiber type in DTI					p-Value
	Total	Displaced		Infiltrated/disrupted		
	N	N	%	N	%	
Low-grade glioma	35	30	76.92	5	9.6	0.0006
High-grade glioma	50	7	9.3	43	82.69	0.004
Metastasis	06	2	5.1	4	7.6	0.6
Total	91	39	100	52	100	

Abbreviations: DTI, diffusion tensor imaging; ST-IA, supratentorial intra-axial.

values. On the basis of the pattern of tracts in relation to the tumor, a safest surgical approach was selected in each patient individually. In tumors with a preoperative size less than 100 cm³, it was found that maximal resection was possible in tumors with displaced tracts (89% of cases) and subtotal resections were done mostly in patients with infiltrated/disrupted (56% of cases) tracts showing that in comparison to HGGs a plane for surgical resection between tumor and parenchyma was easily available in LGGs, leading to their maximal safe resection, and these results were also statistically significant with *p*-value less than 0.05 (►Table 5).

Similar findings were noticed in studies done by Castellano et al¹⁴ and Khan et al¹⁵ where DTI predicted the extent of resection with maximal resections possible in tumors with displaced/intact WM tracts, while infiltrating tumors were less likely to be resected completely.

In our study, we also found that the size of the tumor is also an independent factor for the extent of resection as in tumor with size greater than 100 cm³, 60% of patients had subtotal resection irrespective of the pattern of tracts in pre-op DTI. Our study did not use neuromonitoring, awake craniotomy, functional MRI, intraoperative MRI, and ultrasound. Thus, due to risks involved in extensive resections to adjacent eloquent areas, subtotal resections must have been preferred in these cases. Statistical analysis of the relation of the pattern of the WM tracts with the extent of resection

showed no significant results in tumors greater than 100 cm³ with *p* value greater than 0.05. Studies conducted by Khan et al also showed similar results¹⁴ (►Table 6).

The histopathological analysis after resection of tumors showed that displacement of the WM tracts was characteristically seen in LGGs (30 of 39 patients, i.e., 79%), while infiltrated/damaged fibers tracts were seen HGGs (43 of 52 patients, i.e., 82.69%). These results were statistically significant with *p* value less than 0.05, suggesting that LGGs mostly displace the WM tracts, while infiltrated/disrupted fibers are mostly seen in HGGs. On the basis of the pattern of the WM tracts, we can predict (►Table 8) the histological characterization of tumors, which can help in prognosticating the patients before surgery. In our study, as maximal resection of tumors without damaging the WM tracts was possible mostly in LGGs, while subtotal resections were done mostly in tumors with HGGs, a similar pattern is also seen in previously conducted studies^{5,16,17} (►Fig. 9).

Improvement in postoperative neurological status was found in 34 of 39 (86%) patients with displaced WM tracts and in only 25 (48%) cases with infiltrated and disrupted pattern of WM tracts. This study showed that displaced WM tracts, mostly seen in (►Table 7) LGGs, had improvement in neurological status postoperatively, due to the good plane between tumor and adjacent parenchyma, which attributes to preserved anisotropy of fibers. On the other hand, infiltrated/disrupted tracts in high-grade tumors had no clear margin, which

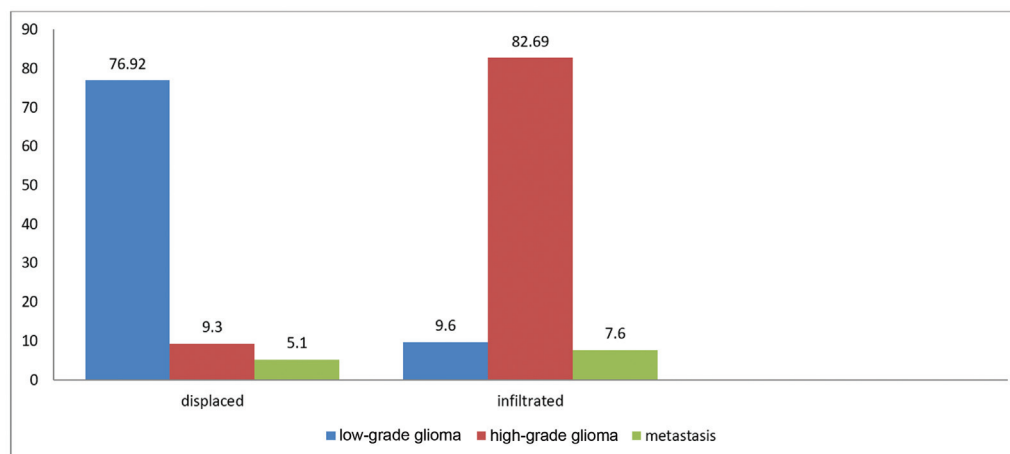


Fig. 9 Bar graph showing the correlation between various histopathologies and fiber type in diffusion tensor imaging (DTI) preoperatively in supratentorial intra-axial (ST-IA) brain tumors.

could be ascertained, leading to their subtotal resections with minimal improvement in neurological status postoperatively.

Hence, on the basis of the pattern of tracts in the preoperative DTI, one can predict the histopathology (either low or high grade), extent of resections, and neurological outcome in patients; hence, we can prognosticate about these patients as well.

DTI also has some drawbacks. In cases of significant peritumoral edema, it is difficult to differentiate whether this change or decrease in anisotropy is due to edema or infiltration due to neoplasm, which is a tricky situation to assess in HGGs. Also, there is significant shift of brain tissue during surgical maneuver, so preoperative DTI may not tell us the exact location of fibers in relation to the tumor while operating due to a shift seen in tracts during surgery.^{17,18} These two reasons can be the significant causes for subtotal resection, which were done in big tumors with disrupted fibers on DTI. Also, DTI adds up in cost of treatment, which is a major drawback.

Conclusion

Our study has shown that preoperative DTI provides the neurosurgeon with a safe surgical corridor preserving the WM tracts, thus improving both surgical and neurological outcome in patients. The displaced fiber pattern is mostly seen in LGGs, while the infiltrated and disrupted patterns of fascicles are seen in HGGs, revealing the prognostic value of DTI in brain tumors. The pattern of fascicle involvement also correlates with the extent of tumor resection, as in intact fascicles, the extent of resection was more when compared with the infiltrated/disrupted fascicles. Thus DTI acts as a pre-operative prognostication indicator in relation to the tumour before the actual histologic grading. It also helps neurosurgeon to decide upon a safe surgical corridor while proceeding towards gross total resection in displaced fibres and near total resections in infiltrated fibres.

Funding

None.

Conflict of Interest

None declared.

References

- 1 Sugahara T, Korogi Y, Tomiguchi S, et al. Posttherapeutic intraaxial brain tumor: the value of perfusion-sensitive contrast-enhanced MR imaging for differentiating tumor recurrence from nonneoplastic contrast-enhancing tissue. *AJNR Am J Neuroradiol* 2000; 21(05):901–909
- 2 Giese A, Westphal M. Glioma invasion in the central nervous system. *Neurosurg* 1996;39(02):235–250
- 3 Chanraud S, Zahr N, Sullivan EV, Pfefferbaum A. MR diffusion tensor imaging: a window into white matter integrity of the working brain. *Neuropsychol Rev* 2010;20(02):209–225
- 4 Ansari SF, Bohnstedt BN, Perkins SM, Althouse SK, Miller JC. Efficacy of postoperative seizure prophylaxis in intra-axial brain tumor resections. *J Neurooncol* 2014;118(01):117–122
- 5 Ammirati M, Vick N, Liao YL, Ciric I, Mikhael M. Effect of the extent of surgical resection on survival and quality of life in patients with supratentorial glioblastomas and anaplastic astrocytomas. *Neurosurgery* 1987;21(02):201–206
- 6 Bello L, Gallucci M, Fava M, et al. Intraoperative subcortical language tract mapping guides surgical removal of gliomas involving speech areas. *Neurosurgery* 2007;60(01):67–80, discussion 80–82
- 7 Mandonnet E, Jbabdi S, Taillandier L, et al. Preoperative estimation of residual volume for WHO grade II glioma resected with intraoperative functional mapping. *Neuro-oncol* 2007;9(01): 63–69
- 8 Smith JS, Chang EF, Lamborn KR, et al. Role of extent of resection in the long-term outcome of low-grade hemispheric gliomas. *J Clin Oncol* 2008;26(08):1338–1345
- 9 Stummer W, Reulen HJ, Meinel T, et al; ALA-Glioma Study Group. Extent of resection and survival in glioblastoma multiforme: identification of and adjustment for bias. *Neurosurgery* 2008; 62(03):564–576, discussion 564–576
- 10 Sanai N, Berger MS. Glioma extent of resection and its impact on patient outcome. *Neurosurgery* 2008;62(04):753–764, discussion 264–266
- 11 Berger MS, Rostomily RC. Low grade gliomas: functional mapping resection strategies, extent of resection, and outcome. *J Neurooncol* 1997;34(01):85–101
- 12 Talos IF, Zou KH, Ohno-Machado L, et al. Supratentorial low-grade glioma resectability: statistical predictive analysis based on anatomic MR features and tumor characteristics. *Radiology* 2006;239(02):506–513
- 13 Field AS, Alexander AL, Wu YC, Hasan KM, Witwer B, Badie B. Diffusion tensor eigenvector directional color imaging patterns in the evaluation of cerebral white matter tracts altered by tumor. *J Magn Reson Imaging* 2004;20(04):555–562
- 14 Castellano A, Bello L, Michelozzi C, Gallucci M, Fava E, Iadanza A, Riva M, Casaceli G, Falini A. Role of diffusion tensor magnetic resonance tractography in predicting the extent of resection in glioma surgery. *Neuro Oncol* 2012;14(02):192–202
- 15 Khan KA, Jain SK, Sinha VD, Sinha J. Preoperative diffusion tensor imaging: a landmark modality for predicting the outcome and characterization of supratentorial intra-axial brain tumors. *World Neurosurg* 2019;124:e540–e551
- 16 Kono K, Inoue Y, Nakayama K, et al. The role of diffusion-weighted imaging in patients with brain tumors. *AJNR Am J Neuroradiol* 2001;22(06):1081–1088
- 17 Maesawa S, Fujii M, Nakahara N, Watanabe T, Wakabayashi T, Yoshida J. Intraoperative tractography and motor evoked potential (MEP) monitoring in surgery for gliomas around the corticospinal tract. *World Neurosurg* 2010;74(01): 153–161
- 18 Nimsy C, Ganslandt O, Hastreiter P, et al. Preoperative and intraoperative diffusion tensor imaging-based fiber tracking in glioma surgery. *Neurosurgery* 2005;56(01):130–137, discussion 138