

Received: 2020.05.10

Accepted: 2020.06.06

Available online: 2020.07.15

Published: 2020.08.17

Potential Role of Oxygen–Ozone Therapy in Treatment of COVID-19 Pneumonia

Authors' Contribution:

Study Design A
Data Collection B
Statistical Analysis C
Data Interpretation D
Manuscript Preparation E
Literature Search F
Funds Collection G

AE 1 **Alberto Hernández**
F 2 **Montserrat Viñals**
F 3 **Tomas Isidoro**
E 3 **Francisco Vilàs**

1 Department of Anesthesiology, Policlinica Ibiza Hospital, Ibiza, Spain
2 Department of Internal Medicine, Policlinica Ibiza Hospital, Ibiza, Spain
3 Department of Surgery, Policlinica Ibiza Hospital, Ibiza, Spain

Corresponding Author: Alberto Hernández, e-mail: albimar23@yahoo.es

Conflict of interest: None declared

Case series

Patients: Male, 49-year-old • Male, 61-year-old • Female, 64-year-old

Final Diagnosis: COVID-19

Symptoms: Respiratory distress

Medication: —

Clinical Procedure: —

Specialty: Infectious Diseases • Pulmonology

Objective: Unusual setting of medical care


Background: Pneumonia caused by coronavirus originated in Wuhan, China in late 2019 and has spread around the world, becoming a pandemic. Many patients deteriorate rapidly and require intubation and mechanical ventilation, which is causing the collapse of healthcare systems in many countries. Coronavirus infection is associated with extensive lung inflammation and microvascular thrombosis, which can result in hypoxia. It can also cause severe and lasting harm in other organs, including the heart and kidneys. At present, there is no proven and efficacious treatment for this new disease. Consequently, there is a growing tendency to use novel methods. Ozone therapy consists of administration of a mixture of oxygen and ozone (a molecule consisting of 3 oxygen atoms). The potential benefits of this therapy include reduced tissue hypoxia, decreased hypercoagulability, renal and heart protection, modulated immune function, improved phagocytic function, and impaired viral replication.

Case Reports: We report rapidly improved hypoxia with associated decreases in inflammatory markers and D-dimer immediately after 1–4 sessions of oxygen–ozone (O₂–O₃) therapy in 3 patients with COVID-19 pneumonia who presented with respiratory failure. Invasive mechanical ventilation was not required in these 3 patients. All patients were discharged home on days 3–4 after O₂–O₃ therapy.

Conclusions: O₂–O₃ therapy appears to be an effective therapy for COVID-19 patients with severe respiratory failure. Large controlled clinical trials are required to study the efficacy and safety of using O₂–O₃ therapy compared with the standard supportive care in patients with COVID-19 in terms of the need for invasive ventilation and length of hospital and intensive care unit stays.

MeSH Keywords: COVID-19 • Ozone • SARS Virus

Full-text PDF: <https://www.amjcaserep.com/abstract/index/idArt/925849>




1441



—



8



19



Background

Ozone (O_3) is a gas composed of 3 atoms of oxygen, including a stable pair (O_2) and a third, unstable, atom, which gives ozone its beneficial effects. Medical ozone generators produce 1–5% ozone gas in 95–99% oxygen from pure oxygen. For medical purposes, concentrations of 10–70 $\mu\text{g}/\text{mL}$ are commonly used. Ozone therapy can be administered systemically by adding it to a sample of a patient's own blood and then reinfusing it, in what is termed "ozonated autohemotherapy." When blood is exposed to this gas mixture (O_2-O_3), oxygen equilibrates with the extracellular and intraerythrocytic water before becoming bound to hemoglobin until it is fully oxygenated; in contrast, ozone, which is about 10 times more soluble than oxygen, allows its immediate reaction with any soluble compounds and biomolecules present in biological fluids, readily dissolves in water, and reacts instantaneously with several biomolecules such as ascorbic acid, urate, free cysteine, glutathione molecules, and albumin thiol groups, and then disappears. The compounds generated during the reactions (reactive oxygen species and lipid ozonation products) are the "ozone messengers" and are responsible for its biological and therapeutic effects.

O_2-O_3 therapy has many beneficial effects, including inactivation of microorganisms such as viruses, modulation of the immune system, improvement of microcirculation, anti-inflammatory action stimulation of oxygen metabolism, and promotion of tissue oxygenation.

Case Reports

Three patients presenting with severe COVID-19 pneumonia had marked and rapid clinical improvement after O_2-O_3 therapy. Informed consent was obtained from all 3 patients. Ozonated autohemotherapy involved intravenous infusion of ozonated autologous whole blood. Initially, 200 mL of autologous whole blood was drawn from the antecubital vein into a standard plastic disposable blood collection bag (certified $SANO_3$ bag) containing 35 mL of anticoagulant citrate dextrose solution. The blood was then enriched with 200 mL of gas mixture O_2-O_3 with an ozone concentration of 40 $\mu\text{g}/\text{mL}$ obtained using an Ozonobaric P Sedecal device, which is an ozone generator with CE0120 certificate type IIb. The ozonized blood was then slowly reinfused into the same vein over a period of approximately 10 min.

Case 1

A 49-year-old man (body mass index [BMI] 31 kg/m^2) presented to the Emergency Department (ED) with abdominal discomfort for 1 week and progressive shortness of breath during the previous day. On examination, the abdomen was soft and lax,

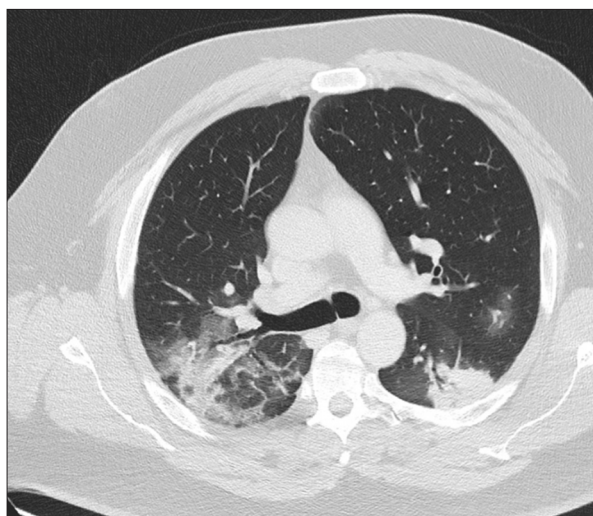


Figure 1. Chest computed tomography on admission, showing bilateral infiltrates.

with no distension noted. Chest auscultation revealed bilateral crackles with reduced air entry. A computed tomography (CT) of the chest–abdomen revealed bilateral lung infiltrates compatible with COVID-19 pneumonia (Figure 1). Laboratory tests showed increased levels of ferritin (1609 ng/mL), D-dimer (1900 ng/dL), C-reactive protein (CRP, 17.3 mg/dL), and lactate dehydrogenase (LDH, 536 IU/L). Real-time polymerase chain reaction (RT-PCR) analysis from a nasopharyngeal swab sample was positive for viral ribonucleic acid (RNA). The patient was admitted to the Intensive Care Unit (ICU), with clearly improved conditions and was discharged to the general ward after 24 h. Unfortunately, the patient experienced worsening hypoxemia and respiratory distress during the next 24 hours. The $\text{PaO}_2/\text{FiO}_2$ ratio was 235. He was put on a non-rebreather face mask with oxygen on FiO_2 of 0.8, but noninvasive ventilation (NIV) was not required. An X-ray showed diffuse bilateral infiltrates. Two sessions of ozone autohemotherapy were administered daily for 3 days, with 12 hours between each session, which was followed by rapid improvement in respiratory rate and increased $\text{PaO}_2/\text{FiO}_2$ ratio, with decreased FiO_2 to 0.31% (3 L) after only 1 day. Figure 2 shows the X-ray before and after only 2 sessions of ozone therapy. Figures 3 and 4 illustrate the trend of changes in ferritin and D-dimer levels before and after O_2-O_3 therapy. The patient was discharged to home on day 4 after ozone therapy.

Case 2

A 61-year-old male patient (BMI 29 kg/m^2), with a background of hypertension, presented to the ED with a week of fever ($>39^\circ\text{C}$) and progressive shortness of breath over the last 48 hours. On examination, chest auscultation showed crackles with reduced air entry over the right hemithorax. A CT of the chest–abdomen revealed right upper infiltrates compatible

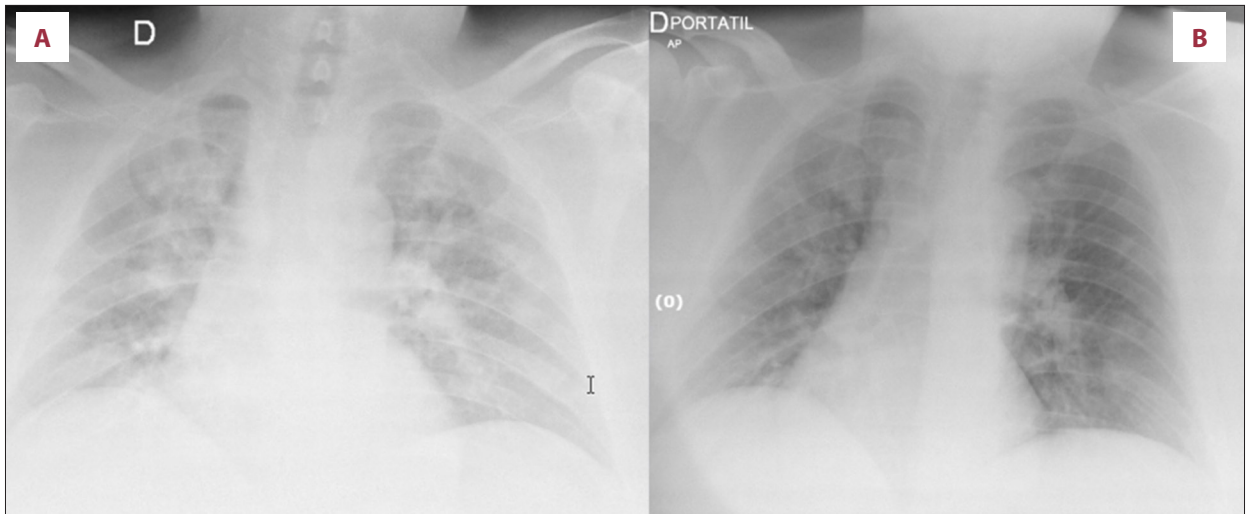


Figure 2. Chest X-ray before (A) and after only 2 sessions of oxygen–ozone therapy (B).

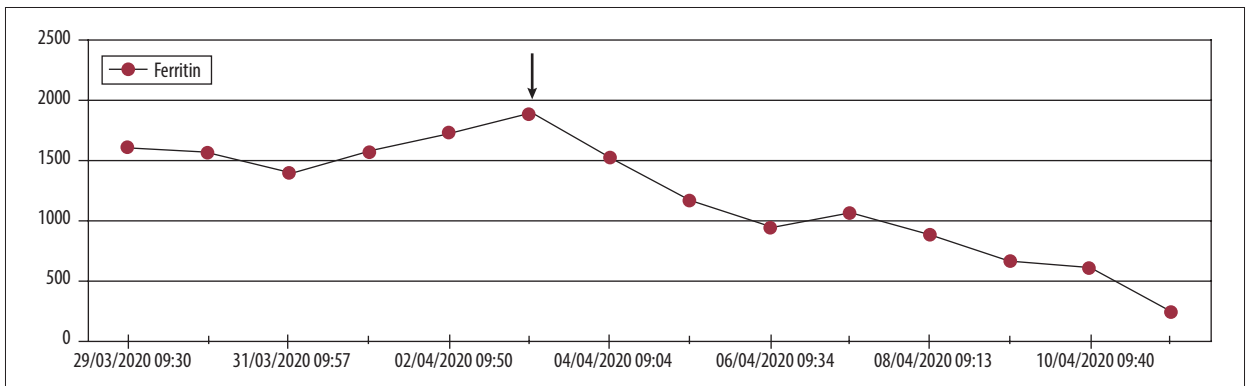


Figure 3. Ferritin levels dropped from >2000 ng/mL to 246 ng/mL after start of ozone therapy.

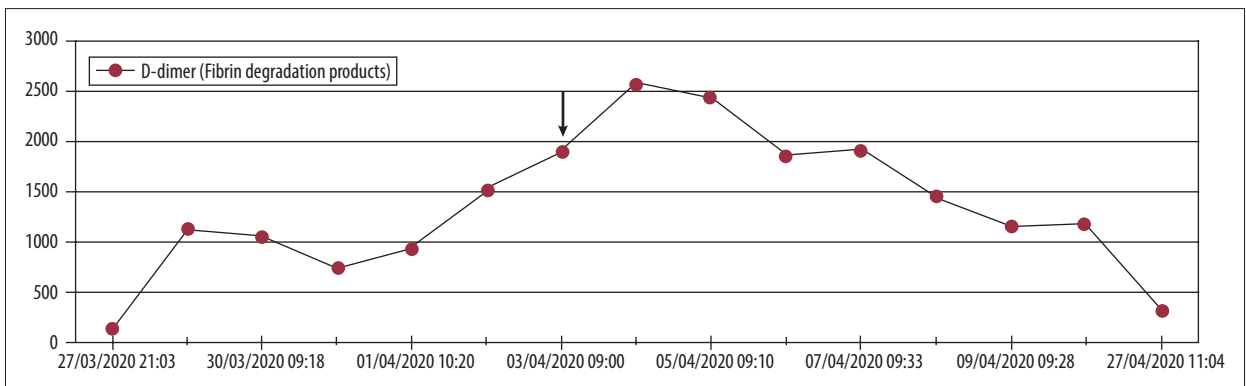


Figure 4. D-dimer levels dropped from 1900 ng/mL to 323 ng/mL after start of ozone therapy.

with COVID-19 pneumonia. High levels of ferritin (2200 ng/mL), D-dimer (3660 ng/mL), CRP (10 mg/dL), and LDH (816 IU/L) were reported. Baseline PaO₂/FiO₂ was 253. Oxygen at a FiO₂ of 0.6 was provided via face mask to the patient in the general ward. NIV was not required. Two sessions of ozone autohemotherapy were administered over a period of 24 hours for 2 days, which was followed by decreased FiO₂ 0.31% (3 L) with

improved PaO₂ to 90 mmHg, and decreased levels of laboratory markers. Figures 5 and 6 show the trend of changes in the LDH and CRP levels before and after O₂–O₃ therapy. The patient received 4 sessions of O₂–O₃ therapy in total and was discharged to home on day 3 after ozone therapy.

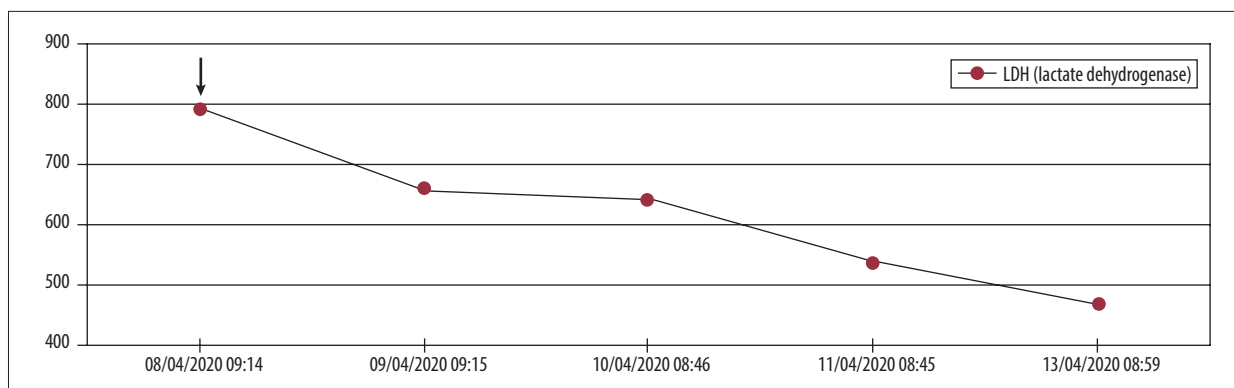


Figure 5. Lactate dehydrogenase levels dropped from 816 U/L to 469 U/L after start of ozone therapy.

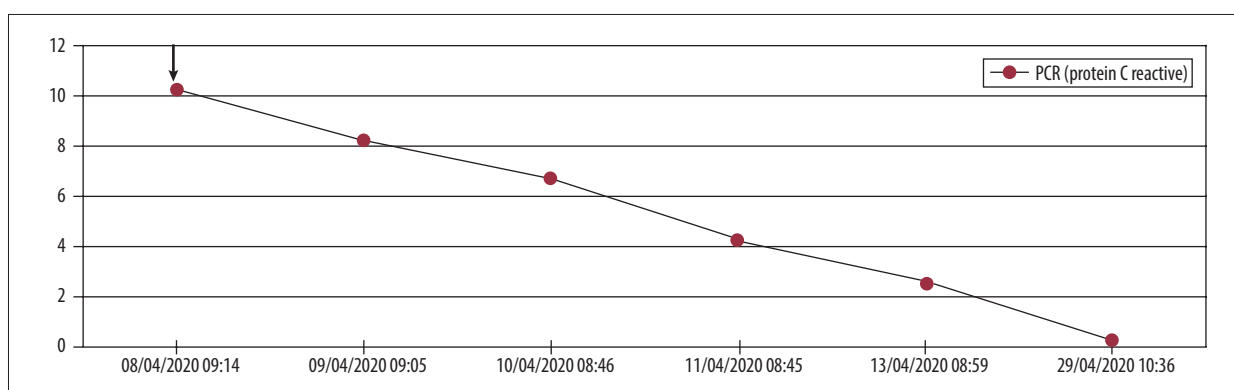


Figure 6. C-reactive protein levels dropped immediately after start of ozone therapy.

Case 3

A 64-year-old woman (BMI 20 kg/m²) presented to the ED with progressive shortness of breath over 3 days. She was diagnosed with COVID pneumonia. Laboratory tests showed high levels of ferritin (656 ng/mL), D-dimer (657 ng/dL), CRP (5 mg/dL), and LDH (452 IU/L). RT-PCR analysis from a nasopharyngeal swab sample was positive for viral RNA. Baseline PaO₂/FiO₂ was 243. Oxygen at an FiO₂ of 0.8 was provided via face mask in the general ward. NIV was not required. O₂–O₃ therapy was commenced immediately after admission to the ward, which was followed by rapid clinical and laboratory recovery profiles similar to those of the previous 2 cases. Figures 7 and 8 show the trend of changes in D-dimer and CRP before and after O₂–O₃ therapy. The patient received 6 sessions of O₂–O₃ therapy in total, and was discharged to home on day 4 after ozone therapy.

Discussion

We report successful use of ozone therapy in 3 patients with COVID-19 pneumonia in terms of precluding the need for invasive ventilation and early discharge to home after 4–6 sessions of ozonated autohemotherapy.

There is no currently available effective treatment for COVID-19 pneumonia. The pathogenesis of the virus is not fully understood, but the pathological picture in the lungs varies significantly in terms of diffuse alveolar damage and microcirculopathy leading to life-threatening hypoxia [1]. Ozone has multiple beneficial properties that could be useful in treatment of COVID-19 pneumonia.

Ozone can deliver sufficient energy and oxygen to the tissues through activating the pentose phosphate pathway, elevating 2,3-diphosphoglyceric acid content in erythrocytes, and stimulating erythrocyte oxygen metabolism [2]. Furthermore, it improves the rheology and capillary action of the blood [3], which has been reported to be helpful for patients with ischemic vascular diseases [4–7]. Additionally, ozone has an antiplatelet effect and increases release of some prostacyclins such as PGI₂, which are beneficial for patients with microthrombosis [8]. All of these effects can help decrease the hypercoagulation phenomena observed in COVID-19 patients. Another important role played by ozone in COVID-19 is its immunomodulatory effects. The inflammatory response is a hallmark of severe infection, and cytokine modulation is key to avoid patient deterioration. Ozone has potent anti-inflammatory properties through modulation of the NLRP3 inflammasome, which plays a crucial role in the initiation and persistence of

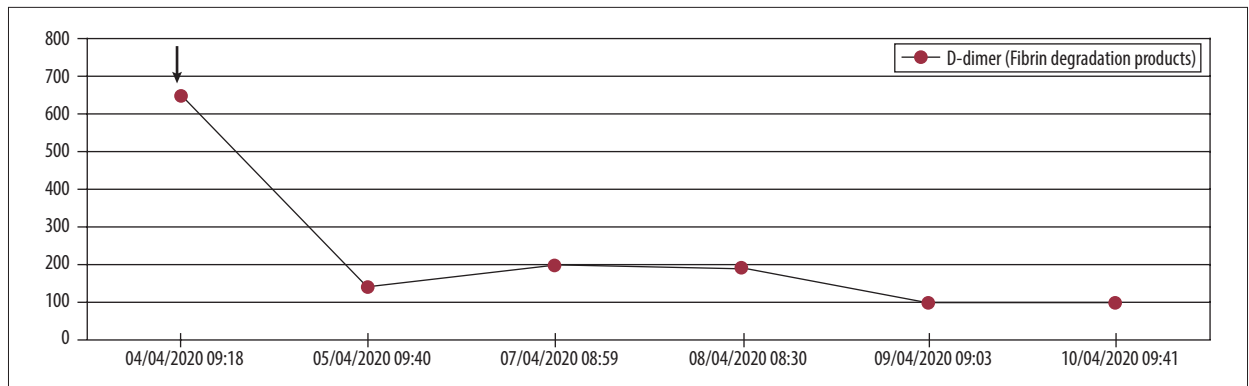


Figure 7. D-Dimer levels dropped from 657 ng/mL to >100 ng/mL after start of ozone therapy.

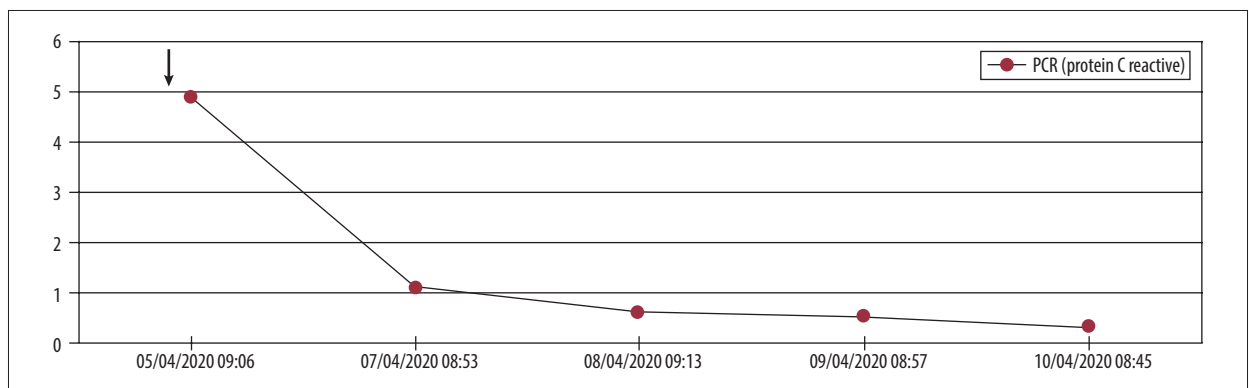


Figure 8. C-reactive protein levels dropped immediately after start of ozone therapy.

inflammation in various diseases [9]. Ozone can also confer renal protection; the rate of kidney damage in COVID patients is significant, and ozone modulates the accumulation of neutrophils locally, the expression of interleukin (IL)-6, tumor necrosis factor (TNF)- α , and albumin modified by ischemia in the kidneys, and increases local antioxidant capacity [10,11].

The effectiveness of ozone against pathogens is well known. Ozone can induce the release and modulation of interferons (IFNs) and related cytokines, such as IL-2, IFN- γ , and TNF, and colony-stimulating factors [12,13], and can also modulate and stimulate phagocytic function [14,15], which can have a very positive effect in COVID-19 infection. Angiotensin-converting enzyme 2 (ACE-2) is an entry receptor for COVID [16]; the virus's spike protein attaches to an ACE-2 receptor on the cell surface, mediating virus fusion with and entry into the host cell [17]. This receptor can be blocked by control of the nuclear

factor erythroid 2-related factor 2 (Nrf2), which regulates and blocks the activity of this receptor [18]. Because ozone causes rapid Nrf2 activation [19], it seems very likely that this is an important physiological mechanism in blocking endogenous COVID-19 reduplication by preventing contact with this receptor.

Conclusions

O₂-O₃ therapy appears to be effective in COVID-19 patients with severe respiratory failure; however, it is not yet an approved therapeutic technique. Large controlled clinical trials are required to study the efficacy and safety of using O₂-O₃ therapy compared with standard supportive care in patients with COVID-19 in terms of the need for invasive ventilation and length of hospital and ICU stays.

References:

1. Carsana L, Sonzogni A, Nasr A, Rossi R: Pulmonary post-mortem findings in a large series of COVID-19 cases from Northern Italy. *Br Med J*, 2020 [in press]
2. Bateman RM, Sharpe MD, Ellis CG: Bench-to-bedside review: Microvascular dysfunction in sepsis – Hemodynamics, oxygen transport, and nitric oxide. *Crit Care*, 2003; 7(5): 359–73
3. Giunta R, Coppola A, Luongo C et al: Ozonized autohemotransfusion improves hemorheological parameters and oxygen delivery to tissues in patients with peripheral occlusive arterial disease. *Ann Hematol*, 2001; 80: 745–48
4. Wu XN, Zhang T, Wang J et al: Magnetic resonance diffusion tensor imaging following major ozonated autohemotherapy for treatment of acute cerebral infarction. *Neural Regen Res*, 2016; 11: 1115–21
5. Borroto RV, Lima HLB, Lima GS et al: Prevention of the stroke with the application of ozone therapy. *Rev Cub Med Fis Rehab*, 2013; 5(1): 3–16
6. Pandolfi S, Zammitti A, Franzini M et al: Effects of oxygen ozone therapy on cardiac function in a patient with a prior myocardial infarction. *Ozone Ther*, 2017; 2(1)
7. Clavo B, Suarez G, Aguilar Y et al: Brain ischemia and hypometabolism treated by ozone therapy. *Forsch Komplementmed*, 2011; 18(5): 283–87
8. Schulz S, Ninke S, Watzet B et al: Ozone induces synthesis of systemic prostacyclin by cyclooxygenase-2 dependent mechanism *in vivo*. *Biochem Pharmacol*, 2012; 83: 506–13
9. Yu G, Bai Z, Chen Z et al: The NLRP3 inflammasome is a potential target of ozone therapy aiming to ease chronic renal inflammation in chronic kidney disease. *Int Immunopharmacol*, 2017; 43: 203–9
10. Sancak EB, Turkon H, Cukur S et al: Major ozonated autohemotherapy preconditioning ameliorates kidney ischemia-reperfusion injury. *Inflammation*, 2016; 39(1): 209–17
11. Foglieni C, Fulgenzi A, Belloni D et al: Ozonated autohemotherapy: Protection of kidneys from ischemia in rats subjected to unilateral nephrectomy. *BMC Nephrol*, 2011; 12: 61
12. Notarangelo L, Casanova JL, Fisher A et al: Primary immunodeficiency diseases: Na update. *J Allergy Clin Immunol*, 2004; 114: 677–87
13. Paulesu L, Luzzi E, Bocci V: Studies on the biological effects of ozone: 2. Induction of tumor necrosis factor (TNF- α) on human leucocytes. *Lymphokine Cytokine Res*, 1991; 10: 409–12
14. Diaz-Luis J, Menendez-Cepero S, Diaz-Luis A et al: *In vitro* effect of ozone on phagocytic function of leucocytes in peripheral blood. *J Ozone Ther*, 2015; 1
15. Frush BW, Li Z, Stiles JV et al: Ozone primes alveolar macrophage-derived innate immunity in healthy human subjects. *J Allergy Clin Immunol*, 2016; 138(4): 1213–15.e1
16. Li W, Moore MJ, Vasilieva N et al: Angiotensin-converting enzyme 2 is a functional receptor for the SARS coronavirus. *Nature*, 2003; 426: 450–54
17. Xia S, Zhu Y, Liu M et al: Fusion mechanism of 2019-nCoV and fusion inhibitors targeting HR1 domain in spike protein. *Cell Mol Immunol*, 2020; 17(7): 765–67
18. Sagai M, Bocci V: Mechanisms of action involved in ozone therapy: Is healing induced via a mild oxidative stress? *Med Gas Res*, 2011; 1: 29
19. Pecorelli A, Bocci V, Acquaviva A et al: Nrf2 activation is involved in ozonated human serum upregulation of HO-1 in endothelial cells. *Toxicol Appl Pharmacol*, 2013; 267(1): 30–40