

Case Report

A Case of Primary Duodenal Liposarcoma

Zachary Whitham^a Aaron Blackham^b Victoria Loven^c

^aUniversity of South Florida Morsani College of Medicine, Tampa, FL, USA;

^bDepartment of Surgical Oncology, Lehigh Valley Health Network, Allentown, PA, USA;

^cDepartment of Pathology, Lehigh Valley Health Network, Allentown, PA, USA

Keywords

Duodenum · Liposarcoma · Sarcoma

Abstract

Soft tissue sarcomas are common neoplasms accounting for 1% of all adult malignancies; however, soft tissue sarcomas infrequently arise from the abdominal viscera. Many case reports discuss gastric and esophageal neoplasms. In the group of gastrointestinal liposarcomas, primary duodenal liposarcomas are among the rarest, with only three previous cases reported in the literature. Herein, we discuss a case of primary duodenal liposarcoma. A 59-year-old woman presented with symptoms consistent with anemia raising suspicion for an upper gastrointestinal bleed. Upper endoscopy revealed an ulcerated mass in the first portion of the duodenum. The patient underwent a segmental duodenal resection and distal gastrectomy with Roux-en-Y reconstruction. A diagnosis of dedifferentiated liposarcoma was rendered on the resected specimen. At 16 months' follow-up, the patient remains without evidence of disease recurrence. We have presented a case of primary duodenal liposarcoma, which is among the rarest locations for gastrointestinal sarcomas with only three previous reports in the literature. Liposarcomas should be included in the differential for submucosal masses of the duodenum.

© 2020 The Author(s).
Published by S. Karger AG, Basel

Introduction

Soft tissue sarcomas comprise a large group of tumors arising from mesenchymal origin. Overall, sarcomas account for 1% of all adult malignancies, with liposarcomas among the most common types of soft tissue sarcoma [1]. The World Health Organization recognizes

Zachary Whitham
University of South Florida Morsani College of Medicine
6409 S 156th Ave Cir
Omaha, NE 68135 (USA)
zwhitham@gmail.com

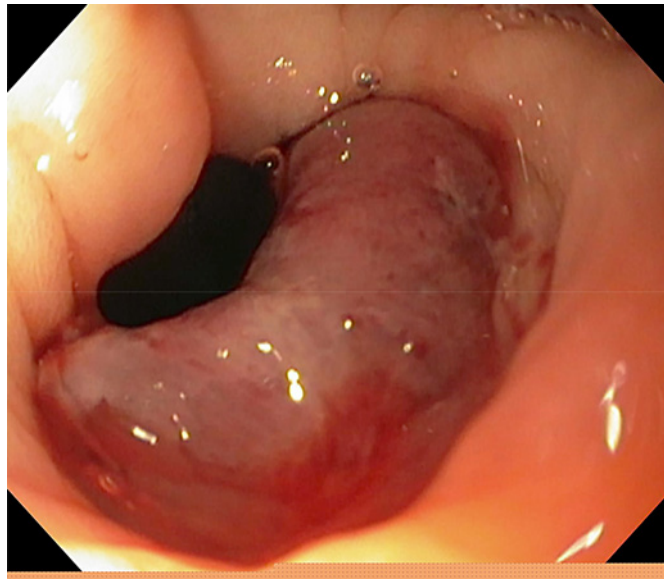


Fig. 1. Endoscopic image demonstrating a submucosal mass with mucosal ulceration on the posterior wall of the duodenal bulb.

four subtypes of liposarcomas based on pathological characteristics: atypical lipomatous tumor/well-differentiated liposarcoma, dedifferentiated liposarcoma, myxoid liposarcoma, and pleomorphic liposarcoma. Well-differentiated liposarcomas and dedifferentiated liposarcomas are the most common subtypes, most frequently occurring the extremities and the retroperitoneum [2, 3].

Experience with gastrointestinal liposarcomas are limited to case reports. Primary liposarcomas of the esophagus are perhaps the most common with over 20 reported cases, followed by primary gastric liposarcomas with 15 cases reported in the literature [4, 5]. Cases of primary liposarcomas have also been reported in the gastroesophageal junction and colon [2, 6]. Primary duodenal liposarcomas appear to be among the rarest subtypes of gastrointestinal liposarcomas. To the best of our knowledge, two cases of primary duodenal liposarcoma and one case of synchronous retroperitoneal and duodenal liposarcomas exist in the literature [3, 7, 8]. Herein, we report a case of primary duodenal liposarcoma arising from the duodenal bulb.

Case Report

A 59-year-old female initially presented to the emergency department with several weeks of worsening fatigue, shortness of breath with exertion, and palpitations. Initial lab studies were significant for a hemoglobin of 6.9 mg/dL. Due to suspected gastrointestinal bleed, an upper endoscopy was performed, which revealed a submucosal mass with mucosal ulceration on the posterior wall of the duodenal bulb (Fig. 1). The primary differential diagnosis at the time was duodenal adenocarcinoma, gastrointestinal stromal tumor, or lymphoma. A subsequent CT scan of chest, abdomen, and pelvis showed a 5.2 × 4.9 × 4.8 cm heterogeneous mass in the duodenal bulb without evidence of metastatic disease. Initial pathology results, obtained from endoscopic biopsy, showed evidence of a spindle cell neoplasm without features of lymphoma, neuroendocrine tumor, or adenocarcinoma. However, c-kit and DOG1 pathological immunohistochemical stains were negative, ruling out gastrointestinal stromal tumor. Supplementary stains showed diffuse positivity for vimentin and patchy positivity for SMA, and stains were negative for CD34, CD117, DOG1, S100, desmin, BCL2, NSE, synapto-

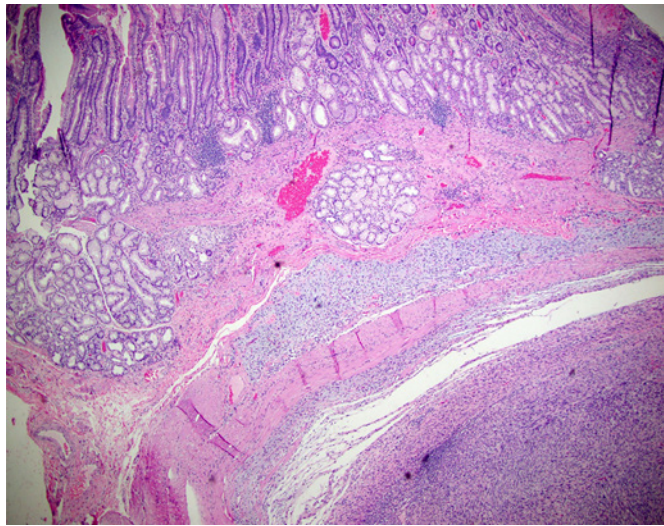


Fig. 2. Duodenal resection demonstrating a spindle cell neoplasm arising from the muscularis propria of the duodenum and extending into the overlying mucosa ($\times 4$).

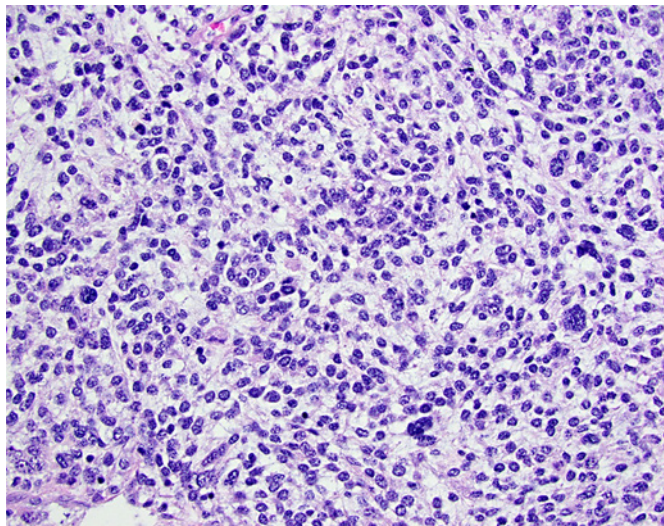


Fig. 3. Dedifferentiated sarcomatoid morphology demonstrating marked nuclear atypia, pleomorphism, and mitotic activity ($\times 40$).

physin, chromogranin A, and pancytokeratin AE1/AE3. Additional staining was positive for MDM2 and showed a Ki67 of approximately 40%, rendering the diagnosis of dedifferentiated liposarcoma. Surgical resection was recommended.

Intraoperatively, the mass was well circumscribed and limited to the first portion of the duodenum and pylorus without signs of perforation or extension through the duodenal wall into adjacent structures. As the mass did not extend to the second portion of the duodenum, a pancreaticoduodenectomy was avoided. Our patient underwent a segmental duodenal resection and distal gastrectomy with Roux-en-Y reconstruction. The patient's initial postoperative course was uncomplicated, and she was discharged home on postoperative day 5. She did re-present with pain, and CT imaging showed a fluid collection near the duodenal stump. A percutaneous drain was placed for possible duodenal stump leak; however, drainage was more consistent with hematoma, likely originating from the duodenal staple line.

Pathological evaluation revealed a 5.4-cm malignant spindle cell lesion arising from the muscularis of the duodenum with extension into the overlying mucosa with surface ulceration (Fig. 2). Microscopically, the tumor is characterized by a fascicular growth pattern alternating with solid areas of undifferentiated tumor cells with marked nuclear pleomorphism and brisk mitotic activity (Fig. 3). Immunoperoxidase stains for MDM2, CDK4, and vimentin

were positive, and a diagnosis of dedifferentiated liposarcoma was rendered. Stains for CD117, DOG1, CD34, S100, BCL2, SMA, NSE, synaptophysin, chromogranin A, and pancytokeratin AE1/AE3 were negative. Stain for desmin was equivocal. Four lymph nodes were negative for metastatic malignancy.

Following multidisciplinary evaluation, no adjuvant treatment was recommended. She is now 16 months out from surgery, and CT chest, abdomen, and pelvis revealed no evidence of recurrence or metastatic disease.

Discussion/Conclusion

A limited number of cases of primary duodenal liposarcomas are reported in the literature. Similar to our patient, Okabayashi et al. [3] report a case of primary duodenal liposarcoma where the patient presented with an ulcerating, bleeding, peri-ampullary duodenal mass. In this case, it was not possible to control the bleeding endoscopically, and the patient subsequently underwent an emergent pylorus-preserving pancreaticoduodenectomy. Subsequent pathological evaluation showed immunohistochemical staining for MDM2 resulting a final diagnosis of dedifferentiated liposarcoma. Follow-up at 10 months revealed no signs of recurrence [3]. Trindade et al. [8] detail a case of subepithelial lesion of the duodenal bulb where the patient presented with nausea and abdominal pain. Endoscopic biopsy revealed spindle cells concerning for liposarcoma. Surgical resection and examination of pathology confirmed the diagnosis of well-differentiated liposarcoma arising from the submucosal layer of the gastrointestinal tract [8]. Lastly, Tsang et al. [7] report a case of synchronous primary retroperitoneal and duodenal liposarcomas. The patient presented with a prolonged course of weight loss, anorexia, and abdominal distension. Initial CT findings were consistent with retroperitoneal liposarcoma, but biopsy results were inconclusive. The patient underwent laparotomy with right colectomy to remove the retroperitoneal mass. During laparotomy, a palpable duodenal mass was encountered, with duodenotomy showing a mass occluding the lumen without gross evidence of invasion of the retroperitoneum. Pathological assessment of the specimens was consistent with two well-differentiated liposarcomas. At the time of their report, the authors note two previous cases of recurrence in the duodenum, but no primary cases of duodenal liposarcoma [7].

Each of the four cases presented with symptoms directly related to tumor mass effects, which include upper gastrointestinal bleeding and anorexia secondary to luminal obstruction. Based on a common presentation with upper gastrointestinal bleeding, upper endoscopy is the recommended initial step to detect masses suspicious for malignancy and obtain biopsies. Subsequent CT appropriately allows for further characterization and detection of metastasis [5, 8]. Biopsy allows for immunohistochemical staining for characteristic MDM2 and CDK4 markers. Dual staining with MDM2 and CDK4 has been shown to be both sensitive and specific for dedifferentiated liposarcoma [9] and results from overexpression of the protein product from chromosomal amplification of the 12q13–15 region of the MDM2 and CDK4 oncogenes. Amplification of these genes can then be confirmed with FISH if diagnostic uncertainty remains [2].

All four cases were managed with surgical resection. Complete surgical resection remains the gold standard of treatment for soft tissue sarcomas and currently provides the only chance for a cure [2, 5, 6, 10–12]. Surgical specimens with positive margins are strongly correlated with disease recurrence and decreased overall survival [11, 12]. As such, patients are typically managed with radical en bloc resections to provide optimal local control rates and overall survival, despite increased surgical morbidity [5, 11]. The limited case reports of duodenal liposarcomas demonstrate that negative margins can be achieved with various surgical options depending on the location of the tumor. While distal gastrectomy and proximal duodenectomy

with Roux-en-Y reconstruction can be performed for lesions of the duodenal bulb, liposarcomas of other areas of the duodenum will likely require pancreaticoduodenectomy.

Although negative margins for tumors arising from the gastrointestinal tract are easier to achieve than for retroperitoneal sarcomas, disease recurrence occurs in upwards of 50% of all cases of retroperitoneal and intra-abdominal sarcomas by 5 years [6, 12]. The subtype of liposarcoma strongly affects the likelihood and location of recurrence. Dedifferentiated liposarcomas, as seen in our patient, will present with local recurrence in 40% of all cases and with metastasis in 17% of all cases, which necessitates long-term follow-up [2]. In comparison, 30–47% of all well-differentiated liposarcomas present with local recurrence, while metastasis is almost unseen without prior dedifferentiation [5, 12]. The need for follow-up surveillance is well documented, but the duration of follow-up remains unclear. For example, one case report discusses local recurrence of primary esophageal liposarcoma 25 years after initial resection [10]. Additionally, it is uncertain whether the detection of recurrence provides a mortality benefit, as overall survival once recurrence has occurred is more closely associated with tumor morphology [11].

Treatment of soft tissue sarcomas requires a multidisciplinary approach, which is increasingly based on tumor morphology and genetics [12]. Due to the rarity of gastrointestinal liposarcomas, treatment guidelines are extrapolated from retroperitoneal liposarcomas. Adjuvant treatment with chemotherapy and/or radiotherapy has not proven beneficial to date [5]. Radiotherapy possibly enhances locoregional control, which remains paramount as surgical margin status plays an integral role in overall survival. However, this benefit must be balanced against the adverse effects of radiation on healthy abdominal viscera [13]. In recent years, doxorubicin has remained the mainstay of chemotherapeutic regimens for soft tissue sarcomas with consideration for multiagent regimens on an individual basis. Olaratumab, a monoclonal antibody that blocks platelet-derived growth factor receptor alpha, was approved by the FDA in 2016 for use in combination with doxorubicin for the treatment of retroperitoneal sarcomas following a randomized phase II study, which showed a difference in overall survival of 25.0 versus 14.7 months for olaratumab plus doxorubicin versus doxorubicin alone [13]. As new immunotherapy options progress and the genetic characteristics of liposarcomas continue to be unraveled, it is possible for immunotherapies to play a larger role in the management of recurrent or unresectable disease.

We have presented a case of primary duodenal liposarcoma, which is among the rarest locations for gastrointestinal sarcomas with only three previous reports in the literature. Liposarcomas should be included in the differential diagnosis of submucosal masses which would guide immunohistochemical staining to include MDM2 and CDK4 to prevent delays in diagnosis. Current management of gastrointestinal liposarcomas is similarly to the treatment of retroperitoneal liposarcomas. Due to the scarcity of cases, we cannot definitively determine recurrence patterns and long-term outcomes specifically for gastrointestinal liposarcomas, but we expect similarities when compared with retroperitoneal liposarcomas.

Acknowledgement

There are no other substantive contributions.

Statement of Ethics

The subject of this case report has given their written informed consent to publish their case including publication of images.

Disclosure Statement

The authors have no conflicts of interest to declare.

Funding Resources

The authors received no funding for this case report.

Author Contributions

Zachary Whitham and Aaron Blackham: conception, preparation, and review of the manuscript; Victoria Loven: preparation and review of the manuscript.

References

- 1 von Mehren M, Randall RL, Benjamin RS, Boles S, Bui MM, Ganjoo KN, et al. Soft Tissue Sarcoma, Version 2.2018, NCCN Clinical Practice Guidelines in Oncology. *J Natl Compr Canc Netw*. 2018 May;16(5):536–63.
- 2 Askan G, Bagci P, Hameed M, Basturk O. Dedifferentiated liposarcoma of the gastroesophageal junction. *Turk Patoloji Derg*. 2018;34(1):104–7.
- 3 Okabayashi T, Shima Y, Iwata J, Sumiyoshi T, Kozuki A, Tokumaru T, et al. Primary liposarcoma of the duodenum: a first case presentation. *Intern Med*. 2013;52(24):2753–7.
- 4 Torres-Mora J, Moyer A, Topazian M, Alexander J, Wu TT, Seys A, et al. Dedifferentiated liposarcoma arising in an esophageal polyp: a case report. *Case Rep Gastrointest Med*. 2012;2012:141693.
- 5 Matone J, Okazaki S, Maccapani GN, Amancio TT, Filippi RZ, Macedo AL. Giant gastric liposarcoma: case report and review of the literature. *Einstein (Sao Paulo)* 2016;14(4):557–60.
- 6 Hollowo B, Lamps LW, Mizell JS, English GW, Bridge JA, Ram R, et al. Dedifferentiated liposarcoma mimicking a primary colon mass. *Int J Surg Pathol*. 2018;26:1066896917731517–9.
- 7 Tsang A, Nash JR, Fordham MV, Hartley MN, Poston GJ. The management of retroperitoneal liposarcoma with synchronous intra-duodenal sarcoma. *Eur J Surg Oncol*. 2003;29(6):515–8.
- 8 Trindade AJ, Deng K, Wang J. Endoscopic ultrasonography imaging characteristics of a subepithelial liposarcoma: new addition to the differential diagnosis of subepithelial lesions. *Dig Endosc*. 2015;27(4):533–4.
- 9 Chung L, Lau SK, Jiang Z, Loera S, Bedel V, Ji J, et al. Overlapping features between dedifferentiated liposarcoma and undifferentiated high-grade pleomorphic sarcoma. *Am J Surg Pathol*. 2009;33(11):1594–600.
- 10 Beaudoin A, Journet C, Watier A, Mongeau CJ, Chagnon M, Beaudry R. Giant liposarcoma of the esophagus. *Can J Gastroenterol*. 2002;16(6):377–9.
- 11 Lewis JJ, Leung D, Woodruff JM, Brennan MF. Retroperitoneal soft-tissue sarcoma: analysis of 500 patients treated and followed at a single institution. *Ann Surg*. 1998;228(3):355–65.
- 12 Ford SJ, Almond LM, Gronchi A. An update on non-extremity soft tissue sarcomas. *Clin Oncol (R Coll Radiol)*. 2017;29(8):516–27.
- 13 George S. Evolving treatment of soft tissue sarcoma. *J Natl Compr Canc Netw*. 2017;15(5S):733–6.