

Fibreoptic Laryngoscopic Assessment of Patients with Hoarseness: A Cross-sectional Analysis

Abstract

Background: Hoarseness is a common clinical manifestation of laryngeal diseases. The cause of hoarseness may not always be a simple inflammatory disease, but it can be from other serious life-threatening conditions such as laryngeal cancer, for which a delay in diagnosis of such condition may compromise treatment, resulting in poor prognosis and a decreased survival rate. Against this background, we evaluated the causes of hoarseness using fibreoptic laryngoscopy in our environment. **Materials and Methods:** This was a cross-sectional study of patients with hoarseness attending ENT clinic of our institution. Ethical clearance and consent were obtained. A questionnaire was used to collect relevant clinical data, fibreoptic laryngoscopy was carried out, and the data was analysed using the Statistical Products and Service Solution version 20.0. **Results:** The study recruited 90 patients with hoarseness. The age of the patients ranged between 18 and 70 years with a mean of 40.1 ± 14.8 years. There were 51 (56.7%) males and 39 (43.3%) females. About 46 (51.2%) of the patients had intermittent hoarseness, whereas 44 (48.8%) had persistent hoarseness. Most of the patients, 49 (54.4%), had hoarseness for less than 6 months before presentation. The fibreoptic laryngoscopic findings were non-specific laryngitis 49 (54.5%), laryngeal tumor 20 (22.2%), vocal cord polyp 7 (7.7%), laryngeal papilloma 6 (6.7%), vocal cord palsy 5 (5.6%), and others 3 (3.3%). **Conclusion:** Laryngeal tumour constituted a significant percentage of fibreoptic laryngoscopic findings in patients with hoarseness after nonspecific laryngitis. Therefore, fibreoptic laryngoscopy is recommended for all patients with hoarseness in order to detect sinister pathology early.

Keywords: Aetiology, fibreoptic laryngoscopy, hoarseness, laryngeal tumour

Introduction

Hoarseness is a common clinical manifestation of laryngeal diseases that result from structural or functional abnormalities of the vocal folds. The prevalence of hoarseness is high; a lifetime prevalence of 28.8% has been reported among the general population in the United States.^[1] Hoarseness is also a common condition in Nigeria as reported by several workers among different study populations: A prevalence of 5.6% was seen among patients attending ear, nose, and throat (ENT) clinic in Ile-Ife,^[2] 15.79% among asthmatic patients in Benin City,^[3] and up to 42% among primary school teachers in Lagos.^[4] Similarly, a high prevalence of 62.2% was reported among secondary school teachers in Ogun,^[5] and 66.7% was documented among patients with acute laryngeal obstruction in Ilorin.^[6] In addition, hoarseness was also reported to

be the commonest mode of presentation of laryngeal cancer in Port Harcourt,^[7] Ile-Ife,^[8] Jos,^[9] and Sokoto.^[10]

The aetiology of hoarseness may not always be a self-limiting inflammatory disease but can be from other serious life-threatening conditions such as laryngeal cancer, for which a delay in the diagnosis of such condition may compromise treatment, resulting in a poor prognosis and a decreased survival rate.^[11] To avoid these untoward outcomes, laryngoscopy may be required so as to establish the underlying diagnosis early. Other advantage of early laryngoscopy includes avoiding missed or delayed diagnoses, reducing patient anxiety, and initiating appropriate treatment or referral.^[12] Some authors have recommended that comprehensive assessment of patients with hoarseness requires visualisation of the larynx.^[13,14] Various methods of visualisation of the larynx have been reported in the literature, such as indirect laryngoscopy, direct laryngoscopy, and fibreoptic laryngoscopy.

This is an open access journal, and articles are distributed under the terms of the Creative Commons Attribution-NonCommercial-ShareAlike 4.0 License, which allows others to remix, tweak, and build upon the work non-commercially, as long as appropriate credit is given and the new creations are licensed under the identical terms.

For reprints contact: reprints@medknow.com

**Auwal Adamu¹,
Emmanuel Sara Kolo²,
Abdulrazak Ajiya²,
Ahmad Mahmud³,
Iliyasu Yunusa
Shuaibu⁴,
Onyekwere George B.
Nwaorgu⁵**

¹Department of Otorhinolaryngology, Head & Neck Surgery, Abubakar Tafawa Balewa University Teaching Hospital/Abubakar Tafawa Balewa University Bauchi, ²Department of Otorhinolaryngology, Aminu Kano Teaching Hospital/Bayero University, Kano, ³Department of Otorhinolaryngology, Federal Medical Centre Yola/College of Medicine Modibbo Adama University, Yola, ⁴Department of Surgery, Division of Otorhinolaryngology, Faculty of Clinical Sciences, Ahmadu Bello University, Zaria/Ahmadu Bello University Teaching Hospital, Zaria, ⁵Department of Otorhinolaryngology, University College Hospital/Ibadan/College of Medicine, University of Ibadan, Nigeria

Received: 27-Feb-2022

Accepted: 19-May-2022

Published: 27-Aug-2022

Address for correspondence:

Dr. Auwal Adamu,
Department of
Otorhinolaryngology, Head &
Neck Surgery, Abubakar Tafawa
Balewa University Teaching
Hospital/Abubakar Tafawa
Balewa University Bauchi, Nigeria.
E-mail: auwal.adamu@npmcn.
edu.ng

Access this article online

Website:

www.jwacs-jcoac.com

DOI: 10.4103/jwacs.jwacs_75_22

Quick Response Code:



How to cite this article: Adamu A, Kolo ES, Ajiya A, Mahmud A, Shuaibu IY, Nwaorgu OG. Fibreoptic laryngoscopic assessment of patients with hoarseness: A cross-sectional analysis. J West Afr Coll Surg 2022;12:12-6.

Indirect laryngoscopy provides a limited view of the larynx; hidden areas of the larynx are difficult to visualise; and an excessive gag reflex or overhanging epiglottis may obscure a clear view of the larynx.^[15] Therefore, a significant laryngeal pathology could be missed. Direct laryngoscopy, on the other hand, requires general anaesthesia, which needs patient's fitness, other investigations, theatre space, and hospital admission, and there may be possible risk associated with surgery and general anaesthesia.^[16] As such, the cost of direct laryngoscopy was reported to be substantially higher than that of office-based fiberoptic laryngoscopy.^[17] Fiberoptic laryngoscopy is a very effective diagnostic and therapeutic tool. It is simple, fast, less invasive, gives real-time and high definition view of the larynx. It enables the assessment of vocal cord mobility and can be performed under local anaesthesia in an outpatient setting.^[18] Against this background, this study is aimed at evaluating the cause of hoarseness using fiberoptic laryngoscopy in our environment.

Materials and Methods

This was a cross-sectional study conducted at the ENT clinic of Aminu Kano Teaching Hospital, Kano, between March 2019 and February 2020. Ethical approval was obtained from the institution's Research and Ethics Committees with protocol number: NHREC/21/08/2008/AKTH/EC/2467. Informed consent was obtained from each study participant. The participants included in the study were patients with hoarseness aged ≥ 18 years who presented at the institution's ENT clinic within the study period. Patients excluded from the study were those who had laryngeal surgery or tracheostomy previously, patients with nasal, nasopharyngeal, or oropharyngeal tumours, patients with bleeding disorders, and uncooperative patients. An interviewer-administered questionnaire was used to collect relevant clinical data on demographic variables, nature and duration of hoarseness, history of other symptoms and comorbidities, and fiberoptic laryngoscopic findings.

The fiberoptic laryngoscopy was carried out according to standard procedure.^[19] Anterior rhinoscopy was carried out using an appropriate sized Thudicum nasal speculum and a bright illuminating headlamp to identify the most capacious nasal cavity, and to confirm the absence of gross nasal pathology. Patients with gross pathology that could prevent passage of the fiberoptic scope were excluded from the study. Nasal secretions and crusts were suctioned out. Topical anaesthetic agent (10% xylocaine) was sprayed into the nasal cavity and the throat to ease the procedure. Additionally, 0.5% xylometazoline nasal spray was applied to the nose of the participants with engorged inferior turbinates. Five minutes were given for xylocaine and/or xylometazoline to take effect. The procedure was carried out in the endoscopy room of the ENT clinic, where there are materials for resuscitation in case of vagal reflex or reaction to the local anaesthetic agent. Sterile fiberoptic laryngoscope (Medtronic Xomed, FL, USA; model no: 68E3566M, diameter: 2.7 mm) was used for the procedure. The laryngoscope was lubricated

using KY jelly and defogged by wiping the tip of the scope with cotton wool soaked with Savlon. The tip of the scope was passed into the most capacious nasal cavity along the nasal floor to the nasopharynx. The tip of the scope was then turned inferiorly, and the patient was asked to inspire gently to retract the soft palate anteriorly. The scope was advanced gently to visualise the surrounding structures such as the postcricoid area, pyriform sinuses, lateral and posterior hypopharyngeal walls, and pre-epiglottic space. The endolaryngeal structures such as the epiglottis, aryepiglottic folds, ventricular folds, and vocal cords were examined in detail, and any pathology seen was noted. The mobility of the vocal cords during respiration and phonation was also examined, and the findings were recorded.

For the purpose of this study, clinical history, examination and laryngeal findings were interpreted as follows: (1) Acute laryngitis was defined as hoarseness with or without symptoms of upper respiratory tract infection of less than 3 weeks, and fiberoptic laryngoscopic findings of diffuse hyperemia of the larynx. (2) Chronic laryngitis was defined as hoarseness lasting for more than 3 weeks with history of voice abuse or misuse, and fiberoptic laryngoscopic findings of diffuse hyperemia/edema of the larynx and thickening of the vocal cords. (3) Gastroesophageal reflux disease was defined as history of regurgitation associated with hoarseness in a peptic disease ulcer patient, and fiberoptic laryngoscopic findings of diffuse edema of the postcricoid area with hyperemia, edema or thickening of the vocal cords. (4) Vocal cord nodule was defined as fiberoptic laryngoscopic findings of solitary sessile nodule on the anterior one-third of one or both vocal cords, and history of hoarseness with or without voice abuse or misuse. (5) Vocal cord polyp was defined as fiberoptic laryngoscopic findings of solitary pale pedunculated polyp on one vocal cord, anterior or posterior commissure, with history of persistent hoarseness (6) Vocal cord palsy was defined as persistent hoarseness, and fiberoptic laryngoscopic findings of decreased or complete absence of mobility of one or both vocal cords. (7) Laryngeal papilloma was defined as history of persistent hoarseness with fiberoptic laryngoscopic findings of multiple or solitary glistening grape-like growth involving the larynx. (8) Laryngeal tumour was defined as persistent/unremitting hoarseness with history of smoking/alcohol ingestion, and fiberoptic laryngoscopic findings of irregular fleshy friable mass involving the larynx.

The data obtained was analysed using Statistical Products and Service Solution version 20.0 for windows (IBM Inc., Chicago, IL, USA). Descriptive statistics were performed, and results were presented using frequencies, percentages, mean, and standard deviation. Chi-square test was used to determine the relationship between the variables.

Results

There were 90 participants, comprised of 51 (56.7%) males and 39 (43.3%) females. The age of the participants ranged between

18 and 70 years with a mean of 40.1 ± 14.8. Out of the 90 participants, 27 (30.0%) smoked cigarette, whereas 10 (11.1%) had a history of alcohol intake. None of the participants had a history of exposure to radiation or industrial chemicals.

About 46 (51.2%) of the patients had intermittent hoarseness while 44 (48.8%) had persistent unremitting hoarseness. Table 1 shows the duration of hoarseness before presentation. Most of the patients, 49 (54.4%), had hoarseness for < 6 months before presentation. In addition to hoarseness, the participants also presented with other symptoms such as dyspnea in 21 (23.3%), cough in 21 (23.3%), dysphagia in 13 (14.4%), and neck swelling in 12 (13.3%), and a history of regurgitation at night in 16 (17.8%) of the patients. The distribution of comorbidities among the participants has been shown in Table 2. Peptic ulcer disease was the most common comorbidity among the participants (23.3%); other comorbidities were hypertension (10.0%), diabetes mellitus (7.8%), and asthma (5.6%).

The distribution of fiberoptic laryngoscopic findings is shown in Table 3. Nonspecific laryngitis (including vocal cord nodule) was the commonest finding, 49 (54.5%), followed by laryngeal tumours in 20 patients (22.2%). The nonspecific laryngitis comprised of acute laryngitis, chronic laryngitis, gastroesophageal reflux disease (GERD), and vocal nodule. This study found no statistical significant difference between males and females in terms of fiberoptic findings (*P* = 0.06) as shown in Table 4. Figures 1 and 2 show fiberoptic laryngoscopic pictures of laryngeal tumour and vocal cord nodules, respectively.

Discussion

The age of patients with hoarseness in this study ranged between 18 and 70 years with a mean of 40.1 ± 14.8. This is similar to the findings of previous studies in our environment.^[20,21] However, other studies reported hoarseness in younger age group.^[22,23] In this study, hoarseness was found to be the main symptom of the patients, most of them had hoarseness for < 6 months before presentation. This is similar to the findings of a study conducted in our environment where most of the patients presented within 6 months of the onset of hoarseness.^[21] In contrast, another author reported that a large proportion of their patients had hoarseness for over 24 months before presentation.^[23] This may be due to poor healthcare-seeking behaviour of their patients. This study showed that hoarseness was intermittent in 51.2% and

persistent in 48.8% of the patients. Intermittent hoarseness is more in keeping with inflammatory causes, whereas persistent hoarseness is mainly seen in laryngeal tumours or laryngeal nerve palsy as described in the literature.^[23] The clinical implication of this is that laryngoscopy is strongly indicated in all patients with persistent hoarseness in order to exclude serious laryngeal pathology.

The most common fiberoptic laryngoscopic finding (54.5%) in this study was nonspecific laryngitis (including vocal cord nodule). This is similar to the findings of Okeowo^[24] in Lagos and Nwaorgu *et al.*^[21] in Ibadan where nonspecific laryngitis (including vocal cord nodule) was the commonest cause of hoarseness in their series (62.8% and 55.6%, respectively). This implies that the pattern of aetiology of hoarseness has not changed significantly from the previous studies. The predisposing factors to nonspecific laryngitis such as upper respiratory tract infections and atmospheric pollution still remain prevalent in our environment. Acute laryngitis as a separate entity was found in 11.1% of patients with hoarseness in this study; this is similar to the findings of studies conducted in Nigeria^[20,25] and Nepal.^[26] However, Coyle *et al.*^[27] in the United States reported a lower percentage of laryngitis (2.4%) among the first group of patients they studied. The lower percentage of laryngitis in their study may be attributed to difference in weather conditions and probably lower rate of upper respiratory tract infections in their environment. Dusty Harmattan weather and a high rate of upper respiratory tract infections in our environment were some of the reasons behind a high rate of laryngitis pointed out by some authors.^[24,28] Vocal cord nodule as a separate

Table 1: Duration of hoarseness before presentation

Duration (months)	Frequency	%
<6	49	54.4
6–12	23	25.6
13–18	3	3.3
19–24	2	2.2
>24	13	14.5
Total	90	100.0

Table 2: Distribution of comorbidities among the participants

Comorbidities	Frequency	%
Asthma	5	5.6
Peptic ulcer	21	23.3
Hypertension	9	10.0
Diabetes mellitus	7	7.8
Others	4	4.4
None	44	48.9
Total	90	100.0

Table 3: Distribution of fiberoptic laryngoscopic findings

Fiberoptic laryngoscopic findings	Frequency (%)
Nonspecific laryngitis	
Acute laryngitis	10 (11.1)
Chronic laryngitis	14 (15.6)
GERD	15 (16.7)
Vocal cord nodule	10 (11.1)
Subtotal	49 (54.5)
Vocal cord polyp	7 (7.7)
Vocal cord palsy	5 (5.6)
Laryngeal tumour	20 (22.2)
Laryngeal papilloma	6 (6.7)
Others	3 (3.3)

entity was found in 11.1% of patients with hoarseness in this study. This is similar to the findings of Bogaardt *et al.* where vocal nodules/incomplete posterior commissure closure were reported in 11.9% of their patients.^[29] Similarly, our findings are consistent with those of Coyle *et al.* where vocal cord nodule was found in 9.3% and 11% in the first and second group of patients with voice disorder, respectively.^[27] Conversely, higher percentage (34.21%) of vocal cord nodule was reported in Nepal.^[26] The higher rate of vocal cord nodule in their study may be due to the use of videostroboscopy in their study, which can detect even a small nodule that may not be seen with fiberoptic laryngoscopy.

In this study, vocal cord palsy was found in 5.6% of patients with hoarseness; this is similar to the findings of authors in Nigeria^[23] and Nepal.^[26] However, other workers reported lower rates of laryngeal nerve palsy among patients with hoarseness (3.4% and 1.9%).^[21,24] The lower rate of laryngeal nerve palsy in their study may be attributed to differences in the study population. For instance, one of the authors reported postthyroidectomy laryngeal nerve palsy,^[24] which is only one of the several causes of laryngeal nerve paralysis.

Laryngeal tumour was found in 22.2% of patients with hoarseness in this study; this is similar to the findings of researchers in Nigeria who reported laryngeal tumours in 23.1% and 24.2% of patients with hoarseness.^[20,21] Similarly, another study in Nigeria reported a bit higher rate of laryngeal tumours (33.3%) among patients with hoarseness.^[23] In contrast, other workers in developed countries reported lower proportion of laryngeal tumours among patients with hoarseness: Bogaardt *et al.*^[29] in the Netherland found laryngeal tumour in 2.1% of their patients, whereas Coyle *et al.*^[27] in the United States reported laryngeal tumour in 5.4% of the first group and 1.2% in the second group of patients with voice disorder. The lower proportion of laryngeal tumour in their studies may not be unrelated to disparities in knowledge and the application of cancer preventive measures, differences in social habits (smoking and alcohol consumption), or exposure to other risk factors of laryngeal tumours.

One of the limitations of this study was the failure to follow up the patients with laryngeal lesions so as to confirm

the diagnosis histologically. We therefore recommend a longitudinal follow-up study on this topic. Notwithstanding, this study highlighted that not all patients with hoarseness have simple inflammatory disease; rather, a significant number of them have hidden laryngeal lesions that require early diagnosis and prompt treatment. Therefore, this study has further strengthened the importance of flexible laryngoscopy in the evaluation of patients with hoarseness.

Conclusion

Laryngeal tumour constituted a significant percentage of fiberoptic laryngoscopic findings in patients with hoarseness in this study. Therefore, it is recommended that all patients with hoarseness should have fiberoptic laryngoscopy in order to detect a sinister laryngeal lesion early.

Financial support and sponsorship

Nil.

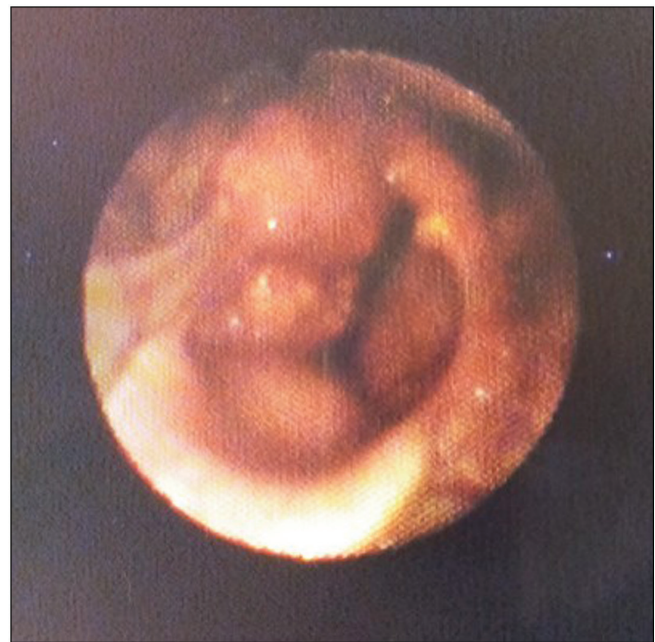

Figure 1: Fiberoptic laryngoscopic picture showing laryngeal tumour more prominent on the right hemilarynx

Table 4: Distribution of fiberoptic laryngoscopic findings based on gender

Fiberoptic laryngoscopic findings	Males (%)	Females (%)	Chi-square test	P-value
Acute laryngitis	6 (60.0)	4 (40.0)		
Chronic laryngitis	9 (64.3)	5 (35.7)		
GERD	4 (26.7)	11 (73.3)		
Vocal cord nodule	4 (40.0)	6 (60.0)		
Vocal cord polyp	6 (85.7)	1 (14.3)	22.26	0.06*
Vocal cord palsy	2 (40.0)	3 (60.0)		
Laryngeal tumour	14 (70.0)	6 (30.0)		
Laryngeal papilloma	3 (50.0)	3 (50.0)		
Others	3 (100.0)	0 (0.0)		
Total	51 (56.7)	39 (43.3)		

*No statistical significant difference

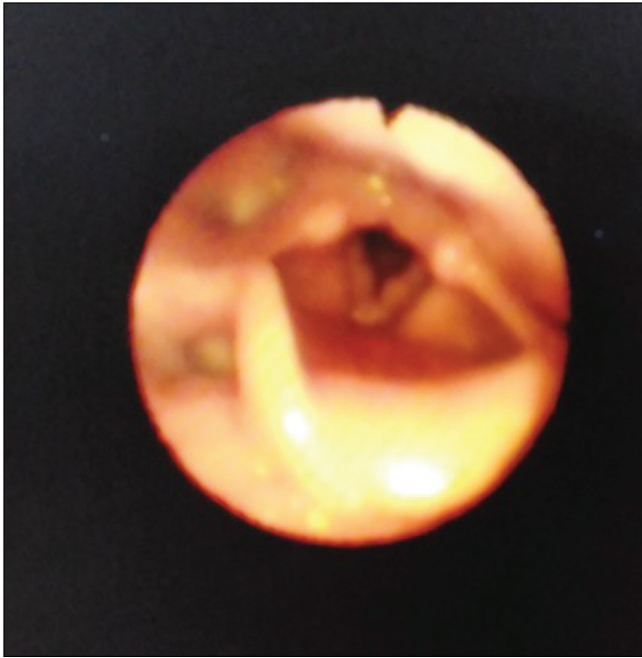


Figure 2: Fibreoptic laryngoscopic picture showing bilateral vocal cord nodules

Conflicts of interest

There are no conflicts of interest.

References

- Roy N, Merrill RM, Thibeault S, Parsa RA, Gray SD, Smith EM. Prevalence of voice disorders in teachers and the general population. *J Speech Lang Hear Res* 2004;47:281-93.
- Eziyi JAE, Amusa YB, Akinpelu OV. Prevalence of otolaryngological diseases in Nigerians. *East Cent Afr J Surg* 2010;15:85-9.
- Adobamen PROC, Egbagbe EE. Prevalence of throat symptoms in asthmatic patients in Nigeria. *Pak J Otolaryngol* 2014;30: 53-5.
- Alabi BS, Nwawolo CC, Okeowo PA, Somefun OA. Prevalence of hoarseness and vocal cord abnormalities among school teachers in Surulere local government area of Lagos State. *Nig J Surg* 2005;11:21-5.
- Johnson KJ, Akinola MA, Okonkwo KC. The prevalence of voice disorders in secondary school teachers in South West Nigeria. *IOSR J Dent Med Sci* 2017;16:76-9.
- Alabi BS, Ologe FE, Dunmade AD, Segun-Busari S, Olatoke F. Acute laryngeal obstruction in a Nigerian hospital: Clinical presentation and management. *Niger Postgrad Med J* 2006;13:240-3.
- Onotai LO, Nwosu C. Laryngeal tumours: Clinical features and management challenges as seen in two centres in Port Harcourt, Nigeria. *Port Harcourt Med J* 2016;10:31-5.
- Amusa YB, Badmus A, Olabanji JK, Oyebamiji EO. Laryngeal carcinoma: Experience in Ile-Ife, Nigeria. *Niger J Clin Pract* 2011;14:74-8.
- Lilly-Tariah OB, Ukoli CO, Nwana EJ. Cancer of the larynx in black Africans in Jos Nigeria. *Cent Afr J Med* 1999;45:40-2.
- Aliyu D, Iseh KR. Clinical profile of post-operative complications of total laryngectomy for laryngeal carcinoma: A 12-year observation in Sokoto, Nigeria. *Orient J Med* 2015;27:99-104.
- Teppo H, Alho OP. Comorbidity and diagnostic delay in cancer of the larynx, tongue and pharynx. *Oral Oncol* 2009;45:692-5.
- Stachler RJ, Francis DO, Schwartz SR, Damask CC, Digoy GP, Krouse HJ, *et al.* Clinical practice guideline: Hoarseness (dysphonia) (update). *Otolaryngol Head Neck Surg* 2018;158: S1-42.
- Resouly A, Hope A, Thomas S. A rapid access husky voice clinic: Useful in diagnosing laryngeal pathology. *J Laryngol Otol* 2001;115:978-80.
- Schwartz SR, Cohen SM, Dailey SH, Rosenfeld RM, Deutsch ES, Gillespie MB, *et al.* Clinical practice guideline: Hoarseness (dysphonia). *Otolaryngol Head Neck Surg* 2009;141:S1-31.
- Garcia de Hombre AM, Paz Cordoves A. Diagnostic correlation between indirect laryngoscopy, fibrolaryngoscopy and microlaryngoscopy with anatomicopathological result. *An Otorrinolaringol Ibero Am* 2003;30:151-60.
- Rosen CA, Andrade Filho PA, Scheffel L, Buckmire R. Oropharyngeal complications of suspension laryngoscopy: A prospective study. *Laryngoscope* 2005;115:1681-4.
- Andrade Filho PA, Carrau RL, Buckmire RA. Safety and cost-effectiveness of intra-office flexible videolaryngoscopy with transoral vocal fold injection in dysphagic patients. *Am J Otolaryngol* 2006;27:319-22.
- Miteab RT. Accuracy of fiberoptic nasopharyngoscopy in the diagnosis of pharyngolaryngeal diseases. *Iraqi Postgr Med J* 2015;14:912-6.
- Adamu A, Jibril YN, Hasheem MG, Abdullahi H, Salisu AD, Nwaorgu OG. Comparison of flexible nasopharyngoscopy with plain radiograph in the assessment of children with adenoid hypertrophy. *J West Afr Coll Surg* 2020;10(4):6-10.
- Isa A, Sandabe MB, Ngamdu YB, Garandawa HI, Kodiya AM. A clinical appraisal of hoarseness in adults at University of Maiduguri Teaching Hospital. *Bo Med J* 2013;10:36-41.
- Nwaorgu OG, Onakoya PA, Ibekwe TS, Bakari A. Hoarseness in adult Nigerians: A University College Hospital Ibadan experience. *Niger J Med* 2004;13:152-5.
- Sood S, Street I, Donne A. Hoarseness in children. *Br J Hosp Med (Lond)* 2017;78:678-83.
- Okhakhu AL, Emma-Nzekwue NH. Pattern of persistent hoarseness at the University of Benin Teaching Hospital. *Arch Int Surg* 2015;5:69-73.
- Okeowo PA. Hoarseness in Nigeria. *Nig Med J* 1977;7:458-60.
- Onotai LO, Nwosu C. Laryngoscopy: Appraisal of 202 procedures carried out in two centers in Port Harcourt, Nigeria. *Nig Health J* 2017;17:1-8.
- Parajuli R. Spectrum of etiological factors for hoarseness: A retrospective study in a Teaching Hospital. *Glob J Oto* 2016;1:1-4.
- Coyle SM, Weinrich BD, Stemple JC. Shifts in relative prevalence of laryngeal pathology in a treatment-seeking population. *J Voice* 2001;15:424-40.
- Adobamen PO. Causes of hoarseness in Benin City, Nigeria. *J Otol Rhinol* 2015;4:5-7.
- Bogaardt HC, Hakkesteegt MM, Grolman W, Lindeboom R. Validation of the voice handicap index using Rasch analysis. *J Voice* 2007;21:337-44.