

CASE REPORT

Pyoderma Gangrenosum with Oral Involvement – Case Report and Review of the Literature

Geetha Paramkusam, Venkateswarlu Meduri, Naresh Gangeshetty*

Department of Oral Medicine and Radiology, Kaminein Institute of Dental Sciences, Nagonda, India

Abstract

Pyoderma gangrenosum (PG) is a rare, noninfectious neutrophilic dermatosis. Clinically, it begins with sterile pustules that rapidly progress into painful ulcers of variable depth and size with undermined violaceous borders. The diagnosis of PG is based on the history of an underlying disease, a typical clinical presentation, histopathology, and exclusion of other diseases. The peak incidence occurs between the ages of 20 to 50 years with women being more often affected than men. There have been very few reports of pyoderma gangrenosum with oral mucosal involvement. Oral lesions in previously reported cases have included ulcers of varying sizes from

a few mm to several cm and have been reported to have been found on the tongue, soft and hard palate, buccal mucosa, and gingiva. Some of these oral lesions have been associated with ulcerative colitis, inflammatory bowel disease, and polycythemia rubra vera. A few cases were reported with biopsy findings, the histological picture being nonspecific, showing ulceration, and necrosis with inflammatory cell infiltrate. A peculiar case of pyoderma gangrenosum with an oral lesion is presented here, and the differential diagnosis is discussed.

Keywords pyoderma gangrenosum, oral lesion of pyoderma gangrenosum, diagnosis

Received Jan. 28, 2010; Revision accepted Mar. 23, 2010

Introduction

Pyoderma gangrenosum is a rare dermatological disease. It is primarily a sterile inflammatory neutrophilic dermatosis. Its etiology is unknown, but it may be an autoimmune disease. It is characterized by recurrent cutaneous ulcerations with mucopurulent or hemorrhagic exudate. These very painful ulcers present with undermined bluish borders and surrounding erythema. Skin lesions are mostly ulcerative with central necrosis. Extracutaneous involvement is reported to occur in bone and lungs (Burns *et al.*, 2004; Wollina, 2007). Pyoderma gangrenosum may occur in the form of deep ulcers in the oral cavity that sometimes ulcerate through the tonsillar pillar (Greenberg and Glick, 2003). Pyoderma gangrenosum-like lesions

can be seen in patients with ulcerative colitis and crohn's disease (Bork *et al.*, 1993). Only a few cases of pyoderma gangrenosum with involvement of the oral cavity have, however, been reported (Margoles and Wenger, 1961; Basu and Asquith, 1980; Yusuf and Ead, 1985; Snyder, 1986; Kennedy *et al.*, 1987; Yco *et al.*, 1988; Setterfield *et al.*, 2001; Hiromi, 2008).

Case Report

A 42-year-old female patient (Figure 1) reported to the department of oral medicine and radiology of the Kamineni Institute of Dental Sciences at Narketpally with symptoms of an ulcer on the hard palate and loosening of the upper front teeth for

three months. The patient first noticed a papule on the hard palate three months prior, this papule then rupturing, with concomitant exposure of bone. The ulcer thus formed extended anteriorly between teeth 12 and 13.

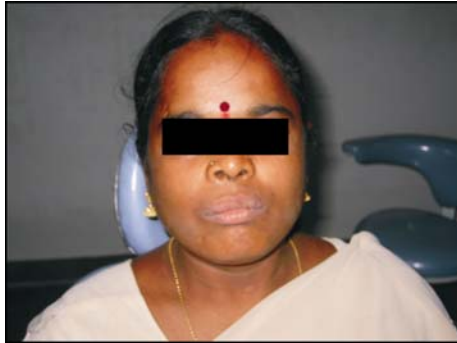

Figure 1 Extra oral view of patient

On clinical examination: a solitary ulcer was seen on the anterior hard palate, the ulcer being about 4 cm × 2 cm in size, elliptical in shape, with undermined edges. The floor of the ulcer was covered by necrotic bone and pus discharge was noted. The surrounding area of the ulcer was red and inflamed. The ulcer was tender on palpation (Figure 2).

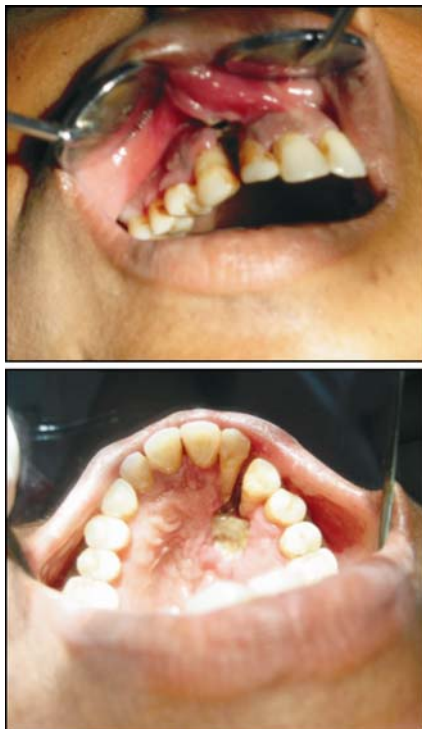

Figure 2 The intraoral lesion from labial and palatal aspect

There was grade III mobility with 13, grade II mobility with 12 and 11. Her past medical history revealed that she was suffering from multiple ulcers of the skin on the lower and upper extremities, and on the stomach, for the prior three years. These lesions were recurrent (see Figure 3). The lesions were diagnosed as pyoderma gangrenosum by a dermatologist. The patient had been receiving corticosteroids, dapsone, cyclosporine, and metrogyl DG gel.

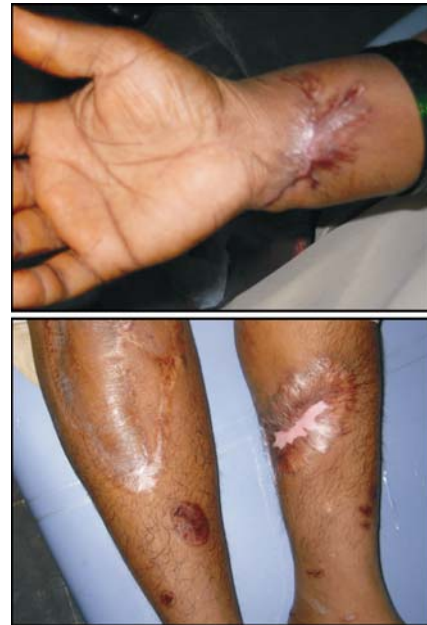

Figure 3 Healed skin lesions on hand and legs

Investigations included complete blood picture, bleeding time, clotting time, serum HBs and HIV detection, liver function tests, random blood sugar, random urine sugar, creatinine level in the urine and complete urine examination, all within normal limits. Maxillary anterior occlusal view (Figure 4) showed a radiolucency in the palate i.r.t. apical region of 11, 12, and 13 teeth. Orthopantomograph (Figure 4), submento-vertex and antero-posterior views of skull were normal. Swab and smear examination were normal. Incisional biopsy from the labial gingiva of upper right lateral incisor and anterior hard palate was performed (Figure 5). Examination of the specimen from the oral lesion under microscope (Figure 6) showed stratified squamous epithelium, subepithelial connective tissue with a central necrotic area, a collection of neutrophil, surrounded by dense collections of lymphocytes, plasma cells, and many proliferating

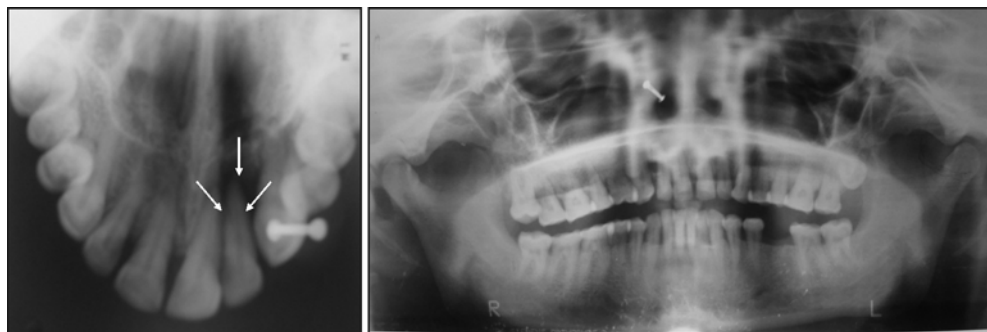


Figure 4 Occlusal radiograph revealing the radiolucency in the palate in relation to the 12,13 region and orthopantamograph

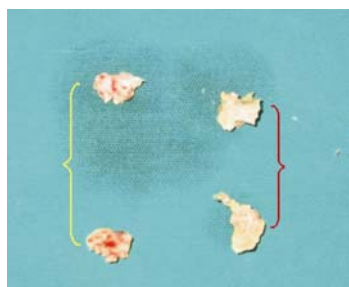

Figure 5 Surgical specimen of the lesion

Yellow arrow indicates specimen from gingiva and red arrows indicate specimen from palate.

capillaries. The histopathological picture was suggestive of a chronic, non-specific suppurative inflammatory lesion. The hard tissue section showed numerous fragments of bone along with necrotic debris. Incisional biopsy from the skin lesion showed thickening and acanthosis of the epidermis with mild spongiosis. There was elongation and uniform broadening of rete ridges with focal blurring of the basement membrane. The papillary dermis showed swelling and necrosis of connective

tissue with infiltration of neutrophils and few lymphocytes and eosinophils along with swollen necrosed blood vessels. These features were consistent with pyoderma gangrenosum.

Differential diagnosis included osteo-myelitis of the maxilla, deep fungal infection like histoplasmosis, blastomycosis, mucormycosis, and Wegener’s granulomatosis. As the biopsy report was not suggestive of any of other diseases, and pyoderma lesions are expected to show only necrosis and inflammatory reaction, it was finally concluded the patient had an oral manifestation of pyoderma gangrenosum.

Treatment included extraction of 12, 13 with debridement of the lesion. The patient was also advised to use metronidazole ointment thrice daily over the lesion and to use of chlorhexidine mouth rinse thrice daily, as well as prednisolone 30 mg daily and dapsone. The patient also developed a fresh lesion on the left retromolar area after two weeks, while the lesion on the palate was partially healed. Both of the lesions were completely healed after 6 weeks (Figures 7 and 8).

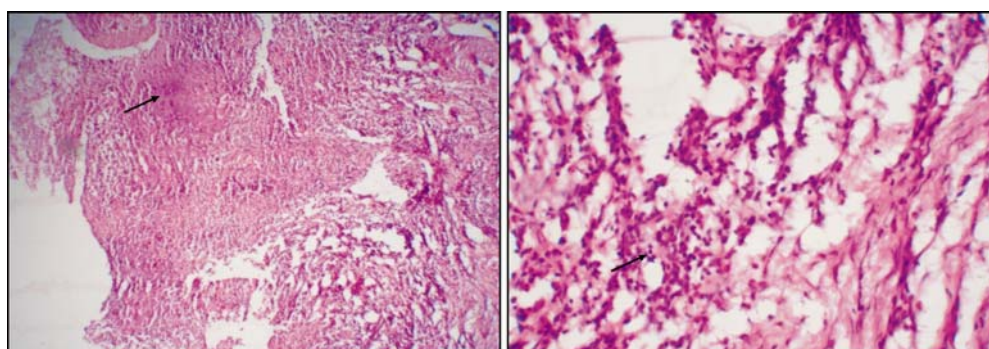


Figure 6 Examination of specimen from the gingival lesion under microscope

At low power ($\times 10$), showing the necrotic area surrounded by inflammatory cells and at high power ($\times 45$), showing the inflammatory cells.

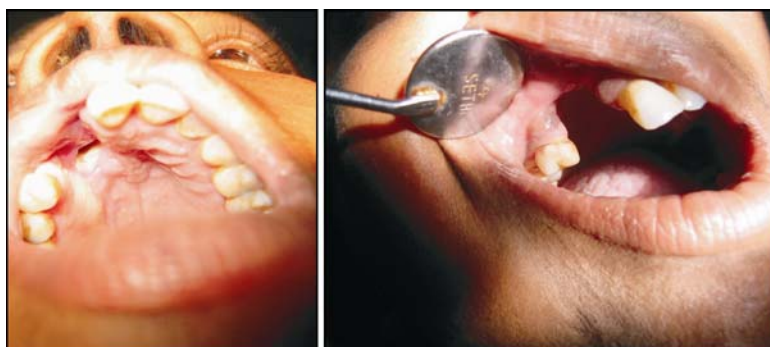

Figure 7 Palatal lesion two and six weeks after initiation of treatment

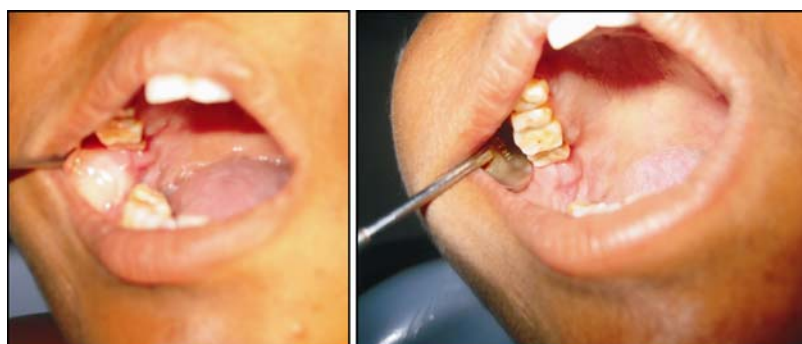


Figure 8 Lesion in right buccal mucosa which developed two weeks after the initial visit and which healed after four weeks of treatment

Discussion

Pyoderma gangrenosum is a rare, neutrophilic dermatosis commonly associated with underlying systemic disease. Pyoderma gangrenosum was first described and named by Brunsting, Goekerman and O'Leary in 1930 (Burns *et al.*, 2004). Approximately 50% of patients have an associated systemic disease, commonly inflammatory bowel disease (IBD), ulcerative colitis, arthritis, hematological and lymphoreticular malignancies, or diseases known to be associated with significant immunocompromise, while in another 40%–50% patients, no underlying disease is found. The disease is recurrent in approximately 30% of patients (Setterfield *et al.*, 2001; Burns *et al.*, 2004). It predominately occurs in adults between the ages of 25–54 years; rarely in children. The classic presentation begins with small tender papules, pustules or nodules which breakdown centrally and rapidly progress to a painful ulcer with characteristic violaceous undermined edges. There may be granulation tissue, necrosis or

purulent exudate at the ulcer base. Lesions may be solitary or multiple, commonly found on the lower legs, followed by the thighs, buttocks, chest, head, and neck. Generally, lesions are less than 10 cm in size, but can be very large. Lesions tend to endure, lasting months to years and heal with an atrophic cribriform scar. Associated symptoms include fever, malaise, myalgia, and arthralgia. Extracutaneous involvement is reported in bone and lungs with neutrophilic infiltrate. The disease may have a variety of clinical presentations: ulcerative, pustular, bullous or atypical, vegetative or superficial granulomatosis (Burns *et al.*, 2004; Wollina, 2007).

Oral involvement in pyoderma gangrenosum is uncommon. The oral lesions may appear as irregular shaped ulcers 15 mm to 20 mm in diameter with rolled out margins and a grayish colored base. The lesions are painful (Yusuf and Ead, 1985). Pyostomatitis vegetans is considered to be the oral counterpart of pyoderma gangrenosum (Bork *et al.*, 1993). This is another rare condition which can occur in association with ulcerative colitis and is characterized by active exacerbations which often coincide with those of

the colitis. The lips and cheeks are diffusely swollen with deep fissure-like ulcerations separating papillary projections of the mucous membrane. The patient is often pyrexial with generalized lymphadenopathy (Yusuf and Ead, 1985).

Previously reported cases of prominent oral mucosal involvement in patients with pyoderma gangrenosum have indicated that the sites of involvement are the tongue, palate, lips, buccal mucosa, gingiva and tonsillar fauces (Margoles and Wenger, 1961; Basu and Asquith, 1980; Yusuf and Ead, 1985; Snyder 1986; Kennedy *et al.*, 1987; Yco *et al.*, 1988; Setterfield *et al.*, 2001; Hiromi, 2008). In five of the previously reported cases, PG was associated with inflammatory bowel disease, usually ulcerative colitis (UC).

The histopathology of the skin lesions is often variable and nonspecific, but can be useful in excluding other possible etiologies. Findings include: central necrosis and ulceration of the epidermis and dermis surrounded by an intense, acute inflammatory cell infiltrate, with a more peripheral mixed-to-chronic inflammatory cell infiltrate (Burns *et al.*, 2004; Wollina, 2007). The histopathology of the oral lesions in previously reported cases shows necrosis, ulceration with an overlying fibrinopurulent membrane; heavy infiltration of the lamina propria with chronic inflammatory cells predominately neutrophils and perivascular hyalinization and fibrin deposition (Margoles and Wenger, 1961; Yco *et al.*, 1988; Setterfield *et al.*, 2001).

As there are no diagnostic features on biopsy, it is of little diagnostic value. The aim of the biopsy is to rule out diagnoses that mimic pyoderma gangrenosum. No specific laboratory test available. Laboratory investigations are done to identify associated diseases and to rule out diagnoses that mimic pyoderma gangrenosum (Burns *et al.*, 2004; Wollina, 2007). Therefore, the diagnosis is primarily clinical and often a diagnosis of exclusion. Features of the ulcer on clinical examination include tenderness, necrosis, irregular violaceous border, with undermined, rolled edges.

Treatment depends on the disease and the presence of associated disease. Systemic therapy for early or mild lesions included topical therapy with hydrophilic occlusive dressings, antimicrobial agents or topical or intralesional corticosteroids.

For extensive disease, systemic corticosteroids and cyclosporins are used. For more severe disease, oral corticosteroids, sulphones and other antimicrobial agents like dapsone, clofazimine, minocycline are used. Refractory cases may need pulsed intravenous corticosteroid therapy. Local therapy of the lesions includes pain relief, prevention of secondary bacterial infections and dressings (Burns *et al.*, 2004; Wollina, 2007).

The patient we have described had classical lesions of pyoderma gangrenosum of the legs, wrist and abdomen which were healed. There was no evidence of inflammatory bowel disease in this patient or any of the other described disease associations. The lesion on her palate was consistent with previous reports of a chronic inflammatory lesion with neutrophils. Its occurrence in association with pyoderma gangrenosum elsewhere and its very rapid resolution with systemic steroids suggests that it was also a manifestation of this disease.

References

- Basu M, Asquith P (1980). Oral manifestations of inflammatory bowel disease. *Clin Gastroenterol*, 9(2): 307–321.
- Bork K, Hoede N, Korting GW, Burgdorf WHC, Young SK (1993). *Diseases of the oral mucosa and the lips*. 3rd ed. Philadelphia: Saunders, p.46.
- Greenberg MS, Glick M (2003). *Burket's oral medicine: diagnosis and treatment*. 10th ed. Hamilton: BC Decker, p.397.
- Hiromi T (2008). Case of pyoderma gangrenosum showing oral and genital ulcers, misdiagnosed as Behcet's disease at first medical examination. *J Dermatol*, 35(5): 289–292.
- Kennedy KS, Prendergast ML, Sooy CD (1987). Pyoderma gangrenosum of the oral cavity, nose and larynx. *Otolaryngol Head Neck Surg*, 97(5): 487–490.
- Margoles JS, Wenger J (1961). Stomal ulceration associated with pyoderma gangrenosum and ulcerative colitis. Report of two cases. *Gastroenterology*, 41: 594–598.
- Setterfield JF, Shirlaw PJ, Challacombe SJ, Black MM (2001). Pyoderma gangrenosum associated with severe oropharyngeal involvement and IgA paraproteinaemia. *Br J Dermatol*, 144(2): 393–396.
- Snyder RA (1986). Pyoderma gangrenosum involving the head and neck. *Arch Dermatology*, 122(3): 295–302.

Burns T, Breathnach S, Cox N, Griffiths C (2004). *Rook's textbook of dermatology*. Vol.3, 7th ed. Massachusetts: Blackwell publishing, p.36–39.

Wollina U (2007). Pyoderma gangrenosum – a review. *Orphanet J Rare Dis*, 2:19.

Yco MS, Warnock GR, Cruickshank JC, Burnett JR (1988).

Pyoderma gangrenosum involving the head and neck. *Laryngology*, 98(7): 765–768.

Yusuf H, Ead RD (1985). Pyoderma Gangrenosum with Involvement of the Tongue. *Br J Oral Maxillofac Surg*, 23(4): 241–250.

*Corresponding author: Naresh Gangeshetty

Address: Department of Oral Medicine and Radiology, Kaminein Institute of Dental Sciences, Sreepuram, Narketpally, Nagonda, Andhra Pradesh, India

Tel: 9866063380 E-mail: gnareshdr@gmail.com
