


# Hypertrophic Cardiomyopathy in the Elderly: A Case Identified With Genetic Screening

Journal of Investigative Medicine High  
Impact Case Reports  
Volume 10: 1–5  
© 2022 American Federation for  
Medical Research  
DOI: 10.1177/23247096221109204  
journals.sagepub.com/home/hic  


Gaspar Del Rio-Pertuz, MD<sup>1</sup> , Pooja Sethi, MD<sup>2</sup>,  
Deephak Swaminath, MD<sup>2</sup>, and Erwin Argueta-Sosa, MD<sup>2</sup>

## Abstract

Hypertrophic cardiomyopathy (HCM) is a hereditary disease with an autosomal dominant pattern of inheritance, that is caused by a mutation in one of several sarcomere genes that encodes components of the contractile system of the heart. Hypertrophic cardiomyopathy has been described as a disease that is more heavily diagnosed in the second decade of life, that may present with abnormal syncopal episodes or sudden cardiac death. However, with a better understanding of the genetic changes that occur in HCM and with improved imaging techniques, there has now been an increased recognition of a late-onset disease that can occur in the elderly population. We report a case of a 73-year-old woman who was found to have HCM after various clinical events took place.

## Keywords

hypertrophic cardiomyopathy, recognition, genetic screening, elderly

## Background

Hypertrophic cardiomyopathy (HCM) is a hereditary disease with an autosomal dominant pattern of inheritance that is caused by a mutation in one of several sarcomere genes that encodes components of the contractile apparatus of the heart. It has been described to have an estimated prevalence of 1 in 500 people.<sup>1–3</sup> Before the CARDIA study, HCM had been considered as an uncommon heart disease, but its results provided an appropriate estimate of the general frequency with which HCM is found in young adults.<sup>1</sup> Due to the increase in the understanding of the genetic substrate,<sup>4,5</sup> the implementation of family screening, and improved cardiac imaging, there is a current notion that the prevalence of the disease may have been underestimated. These days, it is identified with increasing frequency, at any time in life, from childhood to elderhood.<sup>6,7</sup> Therefore, by the current practice, better recognition of this disease in patients of all ages<sup>8</sup> will allow a more timely diagnosis and implementation of appropriate treatment options for those involved, including family screening if pursued.

Transthoracic echocardiogram (TTE) is the recommended first-line test when HCM is suspected. In the case that the TTE demonstrates inconclusive results, cardiac magnetic resonance (CMR) is indicated to clarify the diagnosis.<sup>7</sup>

Classically, HCM is thought to be an inherited cardiomyopathy that occurs mainly in the second decade of life that may present with sudden death or episodes of syncope.<sup>9</sup> This classic age factor,<sup>1</sup> and the fact that elderly people have multiple comorbidities that might explain the increase in left ventricular (LV) wall thickness (ie, hypertension and aortic valve stenosis),<sup>1,10,11</sup> has inhibited HCM from being high on many physicians' differential diagnosis when an elderly patient presents with left ventricular hypertrophy (LVH). Thus, this can delay a timely diagnosis, the implementation of appropriate treatment options, and family screening if indicated. In this case report, we described an elderly patient who was found to have inherited HCM, after diverse clinical manifestations followed by careful evaluation and genetic studies.

<sup>1</sup>Department of Internal Medicine, Texas Tech University Health Sciences Center, Lubbock, Texas, USA

<sup>2</sup>Division of Cardiology, Department of Internal Medicine, Texas Tech University Health Sciences Center, Lubbock, Texas, USA

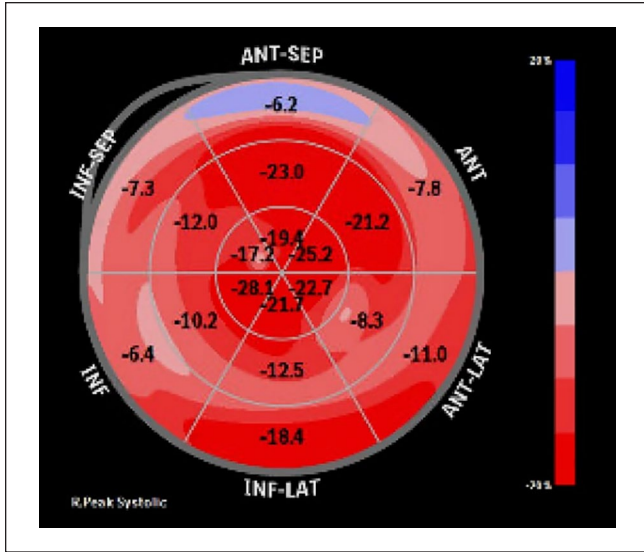
Received March 21, 2022. Revised May 25, 2022. Accepted June 7, 2022.

## Corresponding Author:

Gaspar Del Rio-Pertuz, MD, Department of Internal Medicine, Texas Tech University Health Sciences Center, 3601 4th Street, Lubbock, TX 79430, USA.

Email: gaspar.del-rio-pertuz@ttuhsc.edu





**Figure 1.** Transthoracic echocardiogram strain assessment demonstrating antero-septal strain.

## Case

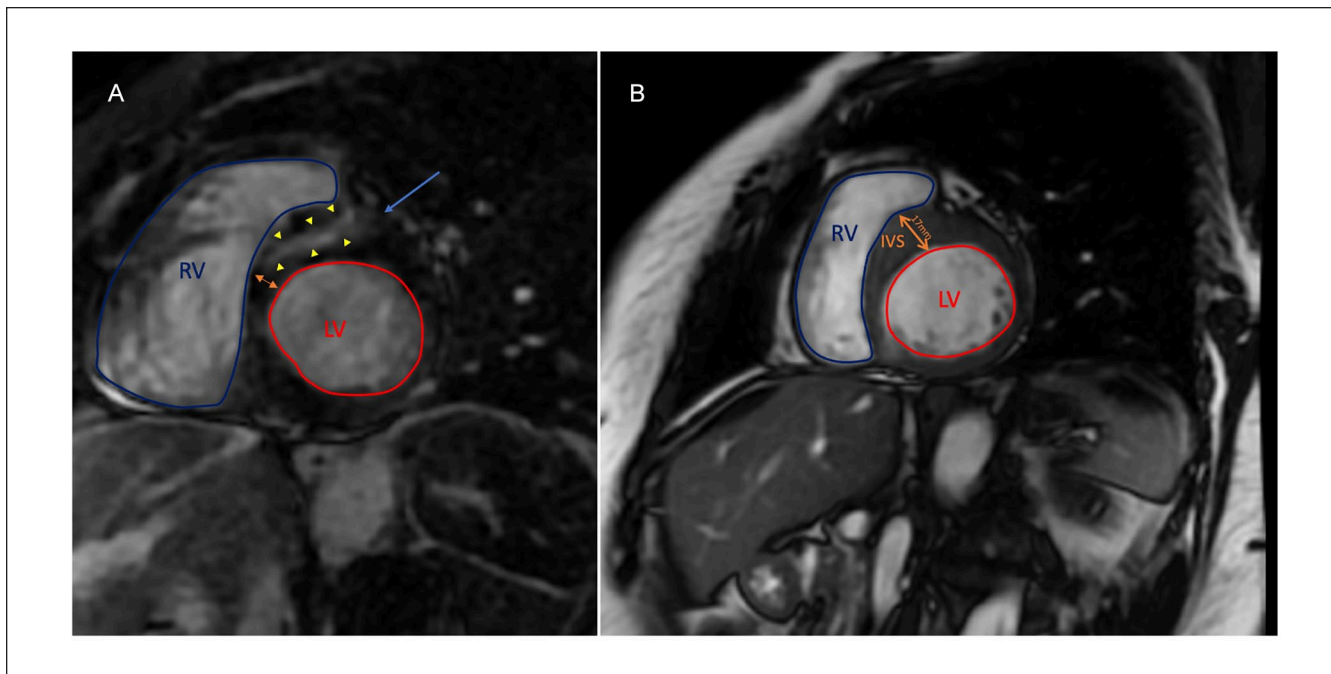
A 73-year-old woman with past medical history of hypertension, hyperlipidemia, breast cancer, paroxysmal atrial fibrillation status post pulmonary vein and cavo-tricuspid isolation, and recurrent gastrointestinal bleeding on rivaroxaban was admitted to the hospital for left atrial appendage closure with a watchman device. In the immediate postoperative period, the patient received one dose of lisinopril that led to hypotension so severe that she required resuscitation with intravenous fluids and a low-dose vasopressor. In this period, the patient had a transient troponin elevation that was thought to be secondary to demand ischemia. The advanced heart failure team was consulted for further evaluation. After interviewing the patient, she reported that one of her sons had died due to sudden cardiac arrest at work (she was told it was a heart attack) when he was in his early 50s. She also noted that she had had ongoing shortness of breath, fatigue, lower extremity edema, chest tightness, and orthopnea for many years. Her symptoms were severe enough to affect her daily life activities, and more specifically she said she was limited due to recurring symptoms of orthostatic hypotension, shortness of breath, and chest tightness that all improved with rest. A TTE demonstrated an LV ejection fraction of 67% (suggesting preserved LV ejection fraction), an LV internal diastolic diameter of 4.4 (suggesting a preserved internal diastolic diameter; normal range is from 3.5 to 6.5 cm), with an estimated right ventricular systolic pressure of 40 mm Hg (suggesting elevated pulmonary artery pressures; normal is <36 mm Hg), the LV outflow tract gradient was less than 30 mm Hg (gradient greater than 30 mm Hg marks the diagnosis of obstructive HCM) and reduced strain on the antero-septal region of the LV with a global longitudinal strain of  $-15\%$  (suggests depressed LV function; normal

is  $>-18\%$ ) (Figure 1). Due to concerns for cardiomyopathy as an etiology of her heart failure symptoms, left and right heart catheterizations were done, and no obstructive coronary artery disease was found. Hemodynamics demonstrated a pulmonary arterial wedge pressure of 36 mm Hg, mean pulmonary arterial pressure of 45 mm Hg, right ventricular systolic pressure of 62 mm Hg, and right atrial pressure 12 mm Hg. These pressures were considerably elevated and brought the diagnosis of World Health Organization pulmonary hypertension group 2. With the suspicious family history (son's sudden and premature death without a clear etiology), regular episodes of orthostatic hypotension, and heart failure symptoms, genetic screening for cardiomyopathies was performed. They showed that she was heterozygous for an abnormal MYBPC3 gene with a pathogenic mutation p.E1085 commonly associated with HCM. Cardiac magnetic resonance imaging (MRI) was obtained, and it demonstrated asymmetric thickening of the LV wall with an antero-septal wall thickness up to 17 mm, abnormal delayed enhancement in the basal to mid antero-septal wall in the subepicardial mid myocardial region. These findings are all suggestive of asymmetric HCM (Figure 2A and B).

## Discussion

There are many systemic disorders (mitochondrial myopathies, storage diseases, amyloid, sarcoid, hemochromatosis) or secondary causes of LVH (athletic heart, hypertensive cardiomyopathy, and valvular lesions) different from inherited HCM that can all cause a thickening of the LV wall. The name HCM has constantly been misemployed, all of which has led to confusion about its true diagnostic factor.<sup>7</sup> Although many diseases may cause LVH, HCM cannot be effectively ruled out in all situations. To back up or rule out an HCM diagnosis, many clinical markers and testing strategies are used to facilitate the differentiation between HCM and all the other conditions that may cause thickening of the LV wall.

If HCM is suspected, the first step should be to perform a TTE. If those results are inconclusive, a CMR is done. The findings of LVH are described as a maximal end-diastolic wall thickness of  $\geq 15$  mm anywhere across the LV. In the lack of other etiologies that could explain LVH in adults, diagnosis could possibly be HCM. Limited LVH of 13 to 14 mm can be diagnostic for HCM if there is a presence of HCM in family members or in concurrence with a positive genetic test. Other suggested echocardiogram findings include a small LV cavity, nonexistence of LV dilation, or a typical sigmoid-shaped septum.<sup>7,12</sup> Genetic tests are recommended in case it is beneficial to elucidate the genetic basis and to facilitate the identification of family members at risk for developing HCM. In the case we described, it was considered that the patient had the benefit from genetic testing because of her son's history of sudden cardiac death. With the patient's positive genetic results, a genetic origin as a



**Figure 2.** Cardiac magnetic resonance (RV: right ventricle, LV: left ventricle, IVS: interventricular septum). (A) Post-gadolinium contrast short axis showing abnormal delayed enhancement in the basal to mid antero-septal wall in the subepicardial, mid myocardial region. Red line is bordering the left ventricular wall (endocardium), blue line is bordering the right ventricular wall (endocardium), the space between the blue and red line is the myocardium (orange arrow). Blue arrow is pointing the subepicardial region. (B) Steady-state free precession short axis demonstrating asymmetric thickening of the left ventricular wall in the antero-septal wall up to 17 mm. Red line is bordering the left ventricular wall (endocardium), blue line is bordering the right ventricular wall (endocardium), and the myocardial wall between the left ventricle and right ventricular is known as the interventricular septum.

cause of her disease was clarified and screening with electrocardiography and 2-dimensional echocardiography can be planned for asymptomatic family members.<sup>7</sup>

Hypertrophic cardiomyopathy is characterized by LVH with various phenotypic expressions. The phenotypes depend on the location and extension of cardiac hypertrophy, ranging from complete asymptomatic to diastolic dysfunction, mitral regurgitation, myocardial infarction, LV outflow obstruction, and sudden death. Classically, HCM has been described as a disease that is identified in the second decade of life,<sup>13</sup> but recently, HCM has been recognized in patients with advanced age.<sup>14</sup> Interestingly, studies suggest that this hereditary disease has a different phenotype when it is first diagnosed in the advanced age group and may ultimately represent a disease entity that is different from that which predominates in young patients.<sup>9,14,15</sup>

The study done by Lever et al<sup>9</sup> compared HCM that presented later onset to a population that presented at a younger age (<40 years). They found that nearly any pattern and location of LV wall thickening could be observed in HCM irrespective of the age of presentation. In their study, the reported most common location for LVH was the basal anterior septum in continuity with the anterior free wall. Lever et al<sup>9</sup> noted that there was a greater predominance of disease in young men and was more commonly present in the elderly

if they had atrial fibrillation and or hypertension. This supports the idea that the older population may largely be a neglected subgroup of patients with this hereditary disease, because of the belief that this condition is predominantly secondary to uncontrolled chronic diseases. One limitation of the previous study was that there was no control for chronic conditions that could explain LVH in the elderly population and genetic tests were not performed. More recently, Alashi et al<sup>12</sup> studied a group of elderly patients diagnosed with HCM by imaging criteria, excluding the population that may have had a secondary cause of LVH (something that was not done on the study of Lever et al<sup>9</sup>). They found that all their population had a significantly increased LV mass index, small, indexed LV cavity dimensions, and the typical sigmoid-shaped basal septal hypertrophy. This suggests that both populations, secondary LVH and inherited HCM, may have similar echocardiographic findings. One limitation of the study done by Alashi et al<sup>12</sup> was that no comparisons were done with other population; thus, it brings the issue of whether the cohort studied (HCM in elderly individuals) represents or not the same disease as in young and middle-aged individuals who have positive genetic tests, in those who have a phenocopy related to aging due to unmasked chronic diseases, or those who have a positive genetic test for HCM in the elderly.

Myocardial strain assessed by echocardiography has shown to play a key role in patients with HCM.<sup>16</sup> The characteristic longitudinal strain “bull’s eye” pattern in patients with HCM is due to the asymmetrical hypertrophy that is characteristic of the disease, represented by a reduced average global longitudinal strain with significantly reduced strain in hypertrophic regions.<sup>17</sup> Our patient had thickening of the antero-septal wall that was seen on the MRI (Figure 1) and that area was the one that had localized reduced strain (blue area in Figure 2) and reduced average global longitudinal strain. It has previously been described that global longitudinal strain can be found reduced in patients with HCM, ranging from  $-10\%$  to  $-16\%$ , with a statistically significant association between lower (less negative) global longitudinal strain and elevated risk of adverse disease-related outcomes.<sup>18</sup>

To summarize, our patient described transient dyspnea on exertion alternating with episodes of dizziness, with variable response to antihypertensives, and a concern for orthostasis. At that time, left heart catheterization was done to rule out obstructive coronary artery disease and right heart catheterization was pursued due to concern for pulmonary hypertension. Echocardiography demonstrated a preserved ejection fraction, localized reduced strain in the antero-septal wall (bull’s eye), and a global longitudinal strain of  $-15\%$ . With hemodynamics suggesting World Health Organization pulmonary hypertension group 2, localized reduced strain, orthostasis, troponin elevations without obstructive coronary artery disease, and premature family death, we started to entertain the idea of hereditary cardiomyopathies. Differentials included hereditary amyloid cardiomyopathy, and less likely HCM. The genetic screening for cardiomyopathies then identified a pathologic mutation in the MYBPC3. This led to the CMR which identified scarring and asymmetric hypertrophy, a phenotype of HCM that most likely was missed for years due to lack of suspicion.

To the best of our knowledge, there is no straightforward clinical implications in missing the HCM diagnosis in elderly patients. However, we consider the importance of a timely diagnosis of hereditary HCM because of the following: First, the results of gene tests for patients with HCM can help in diagnosis and management. Second, in case it is found, it could confer implications to family members. Genetic testing is beneficial to clarify the genetic basis to facilitate the identification of family members at risk for developing HCM (also known as the cascade testing).<sup>7</sup> And third, when hereditary HCM is diagnosed, it is important to note that the treatment options and management are different from unknown causes of heart failure with preserved ejection fraction (ie, indication for beta-blocker or a no dihydropyridine calcium channel blocker).<sup>7</sup>

Nowadays, contemporary treatments have transformed HCM in a manageable disease with relatively low morbidity and mortality.<sup>6</sup> Even though the medical therapy in HCM is

advancing with emerging pharmacological options for obstructive and nonobstructive HCM, by the time this article was submitted, there is not an approved medication by US Food and Drug Administration for use in HCM. Therefore, we consider that the greatest clinical utility of finding HCM in the elderly, in addition to the management of disease-related complications, may be starting early cascade screening in family members rather than a direct benefit to the patient.

## Conclusion

Hypertrophic cardiomyopathy is a hereditary condition with various phenotypic expressions that can be asymptomatic until late ages. As the diagnostic and therapeutic paradigms for HCM are developing, physicians need to become familiar with the diagnosis of this condition even in the elderly.

## Declaration of Conflicting Interests

The author(s) declared no potential conflicts of interest with respect to the research, authorship, and/or publication of this article.

## Funding

The author(s) received no financial support for the research, authorship, and/or publication of this article.

## Ethics Approval

Our institution does not require ethical approval for reporting individual cases or case series.

## Informed Consent

Verbal informed consent was obtained from the patient for their anonymized information to be published in this article.

## ORCID iD

Gaspar Del Rio-Pertuz  <https://orcid.org/0000-0002-5996-0730>

## References

1. Maron BJ, Gardin JM, Flack JM, et al. Prevalence of hypertrophic cardiomyopathy in a general population of young adults. Echocardiographic analysis of 4111 subjects in the CARDIA Study. Coronary Artery Risk Development in (Young) Adults. *Circulation*. 1995;92(4):785-789.
2. Tuohy CV, Kaul S, Song HK, Nazer B, Heitner SB. Hypertrophic cardiomyopathy: the future of treatment. *Eur J Heart Fail*. 2020;22(2):228-240.
3. Klues HG, Schiffrers A, Maron BJ. Phenotypic spectrum and patterns of left ventricular hypertrophy in hypertrophic cardiomyopathy: morphologic observations and significance as assessed by two-dimensional echocardiography in 600 patients. *J Am Coll Cardiol*. 1995;26(7):1699-1708.
4. Wolf CM. Hypertrophic cardiomyopathy: genetics and clinical perspectives. *Cardiovasc Diagn Ther*. 2019;9(suppl 2):S388-S415.



5. Maron BJ, Maron MS, Semsarian C. Genetics of hypertrophic cardiomyopathy after 20 years: clinical perspectives. *J Am Coll Cardiol*. 2012;60(8):705-715.
6. Maron BJ, Desai MY, Nishimura RA, et al. Management of hypertrophic cardiomyopathy: JACC state-of-the-art review. *J Am Coll Cardiol*. 2022;79(4):390-414.
7. Ommen SR, Mital S, Burke MA, et al. 2020 AHA/ACC guideline for the diagnosis and treatment of patients with hypertrophic cardiomyopathy: executive summary: a report of the American College of Cardiology/American Heart Association Joint Committee on clinical practice guidelines. *J Am Coll Cardiol*. 2020;76(25):3022-3055.
8. Semsarian C, Ingles J, Maron MS, et al. New perspectives on the prevalence of hypertrophic cardiomyopathy. *J Am Coll Cardiol*. 2015;65(12):1249-1254.
9. Lever HM, Karam RF, Currie PJ, et al. Hypertrophic cardiomyopathy in the elderly. Distinctions from the young based on cardiac shape. *Circulation*. 1989;79(3):580-589.
10. Nkomo VT, Gardin JM, Skelton TN, et al. Burden of valvular heart diseases: a population-based study. *Lancet*. 2006;368(9540):1005-1011.
11. Iung B, Baron G, Butchart EG, et al. A prospective survey of patients with valvular heart disease in Europe: the Euro heart survey on valvular heart disease. *Eur Heart J*. 2003;24(13):1231-1243.
12. Alashi A, Smedira NG, Popovic ZB, et al. Characteristics and outcomes of elderly patients with hypertrophic cardiomyopathy. *J Am Heart Assoc*. 2021;10(3):e018527.
13. Maron BJ. Hypertrophic cardiomyopathy: a systematic review. *JAMA*. 2002;287(10):1308-1320.
14. Lee DZJ, Rakowski H. Hypertrophic cardiomyopathy in elderly individuals: is it a rose by another name? *J Am Heart Assoc*. 2021;10(3):e020204.
15. Maron BJ, Casey SA, Olivotto I, et al. Clinical course and quality of life in high-risk patients with hypertrophic cardiomyopathy and implantable cardioverter-defibrillators. *Circ Arrhythm Electrophysiol*. 2018;11(4):e005820.
16. Maron MS, Wells S. Myocardial strain in hypertrophic cardiomyopathy: a force worth pursuing. *JACC Cardiovasc Imaging*. 2019;12(10):1943-1945.
17. Liu D, Hu K, Nordbeck P, et al. Longitudinal strain bull's eye plot patterns in patients with cardiomyopathy and concentric left ventricular hypertrophy. *Eur J Med Res*. 2016;21(1):21.
18. Tower-Rader A, Mohananey D, To A, Lever HM, Popovic ZB, Desai MY. Prognostic value of global longitudinal strain in hypertrophic cardiomyopathy: a systematic review of existing literature. *JACC Cardiovasc Imaging*. 2019;12(10):1930-1942.