

# Patterns and Distribution of Deep Vein Thrombosis and Its Effects on Clinical Outcomes After Opening-Wedge High Tibial Osteotomy

Hyung Jun Park,\* MD, Seung-Baik Kang,\*<sup>†</sup> MD, PhD, Jisu Park,\* MD, Moon Jong Chang,\* MD, PhD, Tae Woo Kim,\* MD, PhD, Chong Bum Chang,\*<sup>‡</sup> MD, PhD, and Byung Sun Choi,\* MD

*Investigation performed at SMG-SNU Boramae Medical Center, Seoul, Republic of Korea*

**Background:** Although a few studies have reported the incidence of deep vein thrombosis (DVT) after opening-wedge high tibial osteotomy (OWHTO), previous studies focused only on symptomatic DVT. Information is lacking regarding the overall incidence of DVT after OWHTO, thrombus location, and the relationship between DVT and clinical outcome.

**Purpose:** To determine the overall incidence of DVT and classify the location of DVT after OWHTO. We also determined whether significant differences in clinical improvement exist in patients with and without DVT at 6 months and at 2 years after OWHTO.

**Study Design:** Case-control study; Level of evidence, 3.

**Methods:** This study included 46 patients (47 knees) who underwent OWHTO. All patients were instructed to perform knee range of motion exercises and partial weightbearing after drain removal. None of the patients received a chemoprophylaxis for DVT except intermittent pneumatic compression. DVT was diagnosed using 128-row multidetector computed tomography performed before discharge on the fourth postoperative day. The location was classified into 6 segments in the distal portion (muscular and axial veins) and proximal portion (popliteal, femoral, and common femoral veins and veins located above the iliac vein). International Knee Documentation Committee (IKDC) score was assessed preoperatively and postoperatively at 6 months, 1 year, and 2 years using a linear mixed model.

**Results:** Although the incidence of symptomatic DVT was 8.5% ( $n = 4$ ), the overall incidence of early DVT was 44.7% ( $n = 21$ ). All DVTs were located in the distal portion of the lower extremity vein, and 76.2% of the DVTs were located in an axial vein. The IKDC scores were  $33.6 \pm 7.2$  and  $35.3 \pm 9.1$  ( $P = .910$ ) preoperatively,  $38.1 \pm 5.6$  and  $40.6 \pm 8.4$  ( $P = .531$ ) at 6 months after surgery, and  $44.8 \pm 6.9$  and  $45.9 \pm 11.4$  ( $P = .786$ ) at 2 years after surgery in patients without and those with DVT, respectively.

**Conclusion:** The overall incidence of early DVT after OWHTO was 44.7%. DVT after OWHTO was found particularly around the osteotomy site (76.2%). Patients with DVT did not have inferior short-term clinical outcomes after surgery.

**Keywords:** opening-wedge high tibial osteotomy; incidence; deep vein thrombosis; clinical outcomes

The clinical significance of deep vein thrombosis (DVT) after surgery is known to depend on the location of the DVT.<sup>1,17,29,43</sup> A consensus has been reached that proximal DVT increases the risk of pulmonary thromboembolism (PTE) and the mortality rate and induces severe postthrombotic syndrome as compared with distal DVT.<sup>1,14,17,29</sup> By contrast, the management of distal DVT is controversial. One study has reported that distal DVT resolved spontaneously.<sup>43</sup> However, another study has reported that 15% of distal DVTs propagated proximally to

the popliteal vein or to a higher level.<sup>25</sup> Furthermore, a study has reported that distal DVT contributed to 13% of fatal PTEs.<sup>15</sup> Therefore, some authors have recommended either anticoagulant treatment or close follow-up with imaging modality for 2 weeks for patients with distal DVT.<sup>18,25</sup>

A few studies have reported on the incidence of symptomatic DVT after opening-wedge high tibial osteotomy (OWHTO), finding that it ranged from 1.4% to 9.7%.<sup>24,27,30,39</sup> However, the incidence of DVT after OWHTO might vary depending on whether asymptomatic DVT is included, considering the results of a study by Lee et al.<sup>23</sup> In addition, given that the surgical procedure of OWHTO is performed on the medial side of the proximal tibia, DVT symptoms and postoperative painful swelling of

The Orthopaedic Journal of Sports Medicine, 9(10), 23259671211030883  
DOI: 10.1177/23259671211030883  
© The Author(s) 2021

This open-access article is published and distributed under the Creative Commons Attribution - NonCommercial - No Derivatives License (<https://creativecommons.org/licenses/by-nc-nd/4.0/>), which permits the noncommercial use, distribution, and reproduction of the article in any medium, provided the original author and source are credited. You may not alter, transform, or build upon this article without the permission of the Author(s). For article reuse guidelines, please visit SAGE's website at <http://www.sagepub.com/journals-permissions>.

the surgical site are difficult to differentiate. Therefore, the incidence of DVT after OWHTO in previous studies that included only symptomatic DVT may have been exaggerated or underestimated.

In terms of location, DVT after OWHTO may differ from DVT after total knee arthroplasty (TKA). While performing OWHTO, the surgeon needs to dissect the posterior soft tissue, including the neurovascular structure. In addition, retraction of the soft tissues around the proximal tibial area is needed to protect the neurovascular bundles.<sup>2</sup> Considering the characteristics of surgical procedures, the thrombus might have formed mainly on veins of the lower extremity around the osteotomy site. However, no study results have been classified according to the location of the DVT after OWHTO.

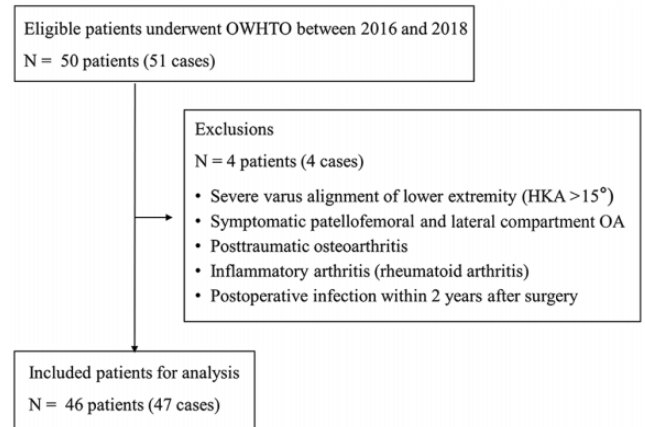
The clinical outcomes of DVT have been reported to be influenced by the causes of thrombus formation.<sup>9,33</sup> The risk of mortality increased when the DVT was caused by concomitant malignant diseases.<sup>33</sup> However, when the DVT was related to the surgery, the clinical outcomes and the satisfaction level were not inferior when they were properly managed.<sup>9</sup> However, a previous study showed that when the DVT was in an axial vein (peroneal and tibial veins), the prognosis was inferior to that when the DVT was in a muscular vein (gastrocnemius and soleus veins).<sup>18</sup> Therefore, given the potential for DVT around the osteotomy site, clinical outcomes after OWHTO may be affected by DVT.

We sought to determine the overall incidence of DVT, including asymptomatic cases. We also classified the location of the DVT after OWHTO. Finally, we determined whether significant differences in early clinical improvement at 6 months and clinical outcome at 2 years after OWHTO exist between the patients with and without DVT after surgery. We hypothesized that the overall incidence of DVT after OWHTO would be substantially higher than that reported in previous studies. We also hypothesized that DVT after OWHTO might be located at the lower extremity vein around the osteotomy site. Finally, we hypothesized that the short-term clinical outcomes after OWHTO would be worse in patients with DVT versus those without DVT.

## METHODS

### Study Designs and Population

This retrospective study included 46 patients (47 knees) who underwent OWHTO. The inclusion criteria were as



**Figure 1.** Selection of patients for study. HKA, hip knee ankle angle; OA, osteoarthritis; OWHTO, opening-wedge high tibial osteotomy.

follows: (1) medial compartment osteoarthritis that did not respond to conservative management, (2) varus deformity of the proximal tibia and varus alignment of the lower extremity (medial proximal tibial angle <90° and mechanical axis of the lower extremity >5°), (3) presence of postoperative venographic evaluation for DVT, and (4) preoperative and postoperative clinical evaluations until 2 years after OWHTO. In total, 50 patients (51 knees) were eligible for inclusion. Among the patients, 4 patients (4 knees) were excluded. The exclusion criteria were as follows: (1) severe varus alignment of the lower extremity (mechanical axis of the lower extremity >15°), (2) symptomatic patellofemoral osteoarthritis (Kellgren-Lawrence grade ≥3), (3) posttraumatic osteoarthritis and inflammatory arthritis such as rheumatoid arthritis, and (4) postoperative complications such as fracture and infection within 2 years of surgery (Figure 1).

The patients included in this study were divided into 2 groups according to the occurrence of DVT after OWHTO (DVT versus no-DVT groups). We found no significant difference in descriptive data between the study groups (Table 1). The study had been approved by our institutional review board before we pursued the retrospective review of data.

### Surgical Techniques

All OWHTOs were performed by a single senior surgeon (S.-B.K.) using the same surgical techniques. Full

<sup>†</sup>Address correspondence to Seung-Baik Kang, MD, PhD, Department of Orthopedic Surgery, Seoul National University College of Medicine, SMG-SNU Boramae Medical Center, 5 Gil 20, Boramae-road, Dongjak-gu, Seoul 07061, Republic of Korea (email: ossbkang@gmail.com).

<sup>\*</sup>Department of Orthopedic Surgery, Seoul National University College of Medicine, SMG-SNU Boramae Medical Center, Seoul, Republic of Korea.

<sup>‡</sup>Department of Orthopedic Surgery, Seoul National University College of Medicine, Seoul National University Bundang Hospital, Seongnam, Republic of Korea.

Final revision submitted March 2, 2021; accepted March 21, 2021.

One or more of the authors has declared the following potential conflict of interest or source of funding: This work was supported by the Bio & Medical Technology Development Program of the National Research Foundation (NRF) funded by the Korean government (MSIT) (2017M3A9D8063538). AOSSM checks author disclosures against the Open Payments Database (OPD). AOSSM has not conducted an independent investigation on the OPD and disclaims any liability or responsibility relating thereto.

Ethical approval for this study was obtained from SMG-Boramae Medical Center (Institutional Review Board No. 30-2019-112).

TABLE 1  
Baseline Characteristics<sup>a</sup>

Characteristics	Overall (N = 47)	No-DVT Group (n = 26)	DVT Group (n = 21)	P
Age, y	58.2 ± 6.6	56.9 ± 7.1	59.7 ± 5.8	.150 <sup>b</sup>
Sex				
Female	33 (70.2)	15 (57.7)	17 (81.0)	.089 <sup>c</sup>
Male	14 (29.8)	11 (42.3)	4 (19.0)	
Laterality				
Right	18 (38.3)	12 (46.2)	6 (28.6)	.218 <sup>c</sup>
Left	29 (61.7)	14 (53.8)	15 (71.4)	
BMI	27.9 ± 3.4	28.6 ± 3.9	27.1 ± 2.5	.132 <sup>b</sup>
Risk factors for VTE				
Previous VTE	0 (0)	0 (0)	0 (0)	≥.999 <sup>c</sup>
Hypertension	21 (45.7)	13 (52)	8 (38.1)	.346 <sup>c</sup>
Diabetes	6 (13)	3 (12)	3 (14.3)	≥.999 <sup>c</sup>
Dyslipidemia	13 (28.33)	5 (20)	8 (38.1)	.175 <sup>c</sup>
Malignancy	1 (2.2)	1 (4)	0 (0)	≥.999 <sup>c</sup>
Anticoagulant medication	7 (15.2)	5 (20)	2 (9.5)	.428 <sup>c</sup>
Smoking	3 (6.5)	2 (8)	1 (4.8)	≥.999 <sup>c</sup>
Hormone replacement therapy	3 (6.5)	2 (8)	1 (4.8)	≥.999 <sup>c</sup>

<sup>a</sup>Data are reported as mean ± SD or n (%). BMI, body mass index; DVT, deep vein thrombosis; VTE, venous thromboembolism.

<sup>b</sup>Independent-samples *t* test.

<sup>c</sup>Chi-square test.

weightbearing standing anteroposterior (AP) radiographic images were obtained from all patients preoperatively. The amount of correction was calculated using the method of Miniaci et al.<sup>12,28</sup> The correction target point was 62.5%, in accordance with the Fugisawa point. After a tourniquet was applied, all patients were assessed via arthroscopy to determine the presence of other pathologies before the osteotomy. A longitudinal incision was made along the medial side of the proximal tibia. The superficial medial collateral ligament was detached at the distal insertion site, and the pes anserinus was retracted. After 2 guide-wires were inserted toward the tip of the fibular head, a biplanar osteotomy was performed. To protect the neurovascular bundles, a Hohmann retractor was placed just the posterior side of the proximal tibia.<sup>2</sup> To achieve the preoperatively calculated correction amount, the surgeon applied valgus force using the 3-chisel technique. After the correction amount was confirmed via intraoperative C-arm, the osteotomy site was fixed with a locking compression plate (TOMOFIX; DePuy Synthes). A drain was inserted around the osteotomy site before closure. The patients were instructed to perform knee range of motion exercises after drain removal. Partial weightbearing up to half of body weight was allowed until 6 weeks postoperatively. After the stability around the osteotomy site was confirmed, the patients were allowed full weightbearing. Although intermittent pneumatic compression was used immediately

after surgery, none of the patients received a chemoprophylaxis for DVT.

## DVT Evaluation and Management

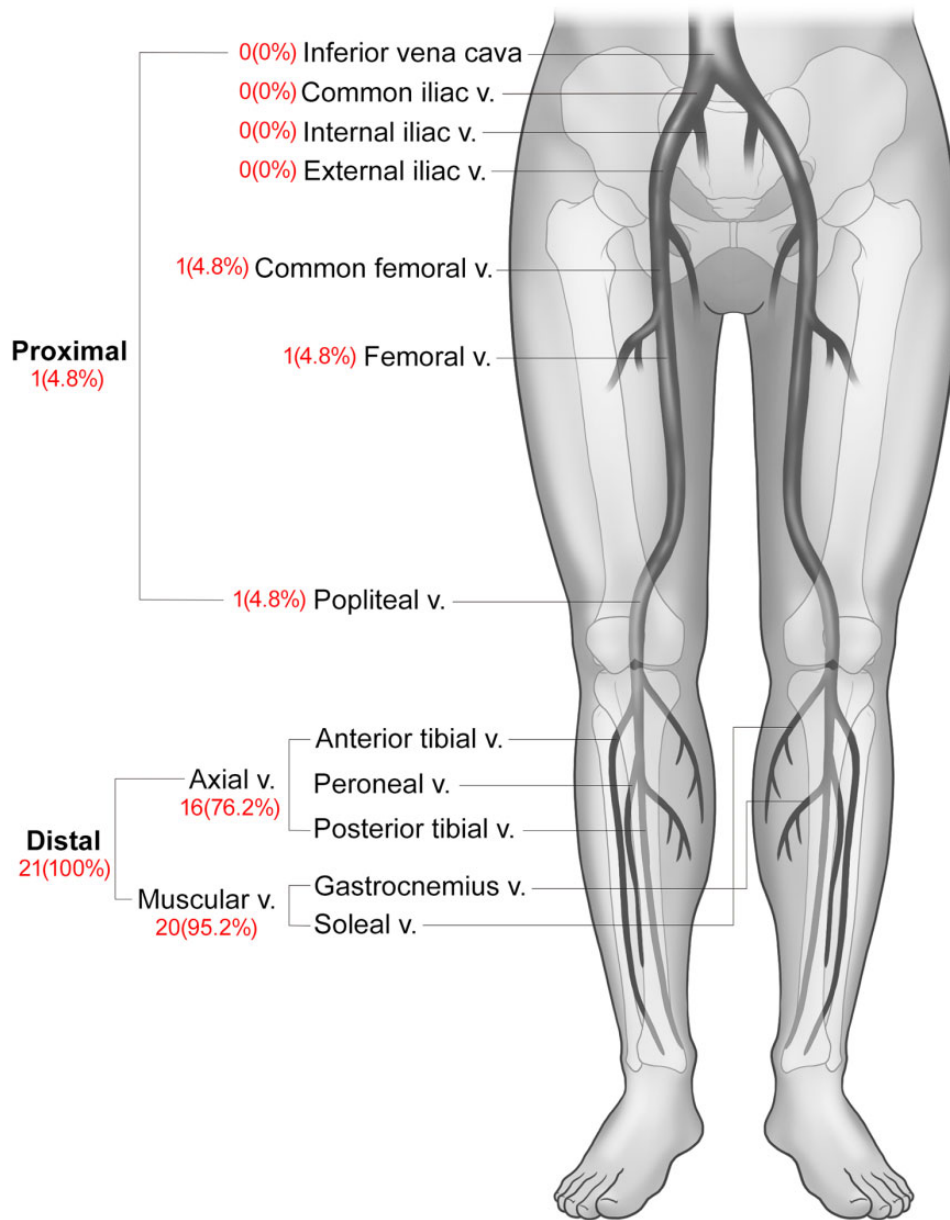
Considering its high sensitivity and specificity compared with ultrasonography, 128-row multidetector computed tomography (MDCT) indirect venography (Phillips Healthcare) was used to evaluate DVT in all patients on postoperative day 4 before they were discharged.<sup>34</sup> All the scans were performed after injection of contrast media. The slice thickness was 2 mm. The venographic images obtained were interpreted by a single radiologist who was blinded to the study protocols. DVT was defined as a low-attenuating partial or complete intraluminal filling defect surrounded by a high-attenuating peripheral ring of blood.<sup>6,37</sup> The location of the DVT was classified into 6 segments as follows: muscular vein (gastrocnemius and soleus veins), axial vein (peroneal and tibial veins), popliteal vein, femoral vein, common femoral vein, and veins located above the iliac vein (including the infra vena cava).<sup>11,18</sup> DVTs in the muscular and axial veins were classified as distal DVTs, and those in the popliteal vein, femoral vein, common femoral vein, and veins above iliac vein were classified as proximal DVTs (Figure 2).<sup>11</sup> DVT-related symptoms, defined as signs such as unusual calf pain, swelling, and pitting edema, were reviewed in the patients' medical records.<sup>44</sup> According to the presence of symptoms, DVT was classified as symptomatic or asymptomatic.

## Radiographic and Clinical Evaluations

Patient evaluations were performed preoperatively and at 6 weeks, 3 months, 6 months, 1 year, and 2 years postoperatively. At every visit, a radiographic evaluation was performed using standing knee AP, lateral radiography, and standing full limb AP radiography. Preoperative and final follow-up radiographic indexes were compared between the 2 groups. The hip knee ankle axis was measured for the mechanical axis of the lower extremity.<sup>8</sup> The Blackburne-Peel and modified Insall-Salvati ratios were measured for patellar height.<sup>3</sup> The posterior tibial slope was defined as the angle between the mid-diaphyseal and proximal tibia plateau lines.<sup>32</sup> The lateral hinge fracture after surgery was diagnosed using MDCT venography and classified in accordance with a previous study.<sup>38</sup> We found no significant difference in radiographic indexes and surgical procedures between the 2 groups (Table 2). The International Knee Documentation Committee score was also assessed preoperatively and at 6 months, 1 year, and 2 years postoperatively.<sup>16</sup>

## Statistical Analysis

The independent-samples *t* test, Mann-Whitney test, and chi-square test were performed to compare the descriptive and radiographic data. To analyze the clinical outcomes at the different time points, a linear mixed model was used. For post hoc analysis, the independent-samples *t* test and Mann-Whitney test were performed, with the *P* value



**Figure 2.** Patterns and distribution of DVT after OWHTO. DVT, deep vein thrombosis; OWHTO, opening-wedge high tibial osteotomy; V, vein.

corrected using the Bonferroni method. All data were analyzed using SPSS Version 26 (IBM Corp).  $P < .05$  was considered as statistically significant.

## RESULTS

Although the incidence of symptomatic early DVT after OWHTO was 8.5%, the overall incidence of early DVT was 44.7% (Table 3). No case of PTE occurred after OWHTO, regardless of symptoms.

All the DVTs were located in the distal portion of the lower extremity vein, and 76.2% of DVTs were located around the osteotomy site. All DVT cases (100%, 21/21) were located at

the distal segment; however, among them, 1 case (4.8%, 1/21) was also located at the proximal segment. The proportion of patients with muscular DVT was 95.2% (20/21), and that of axial DVT was 76.2% (16/21) (Table 3 and Figure 2).

The clinical outcomes did not worsen in the patients with DVT after OWHTO. The clinical score showed no significant difference according to the presence of DVT ( $P = .906$ ). The International Knee Documentation Committee scores were  $33.6 \pm 7.2$  and  $35.3 \pm 9.1$  ( $P = .910$ ) preoperatively,  $38.1 \pm 5.6$  and  $40.6 \pm 8.4$  ( $P = .531$ ) at 6 months after surgery, and  $44.8 \pm 6.9$  and  $45.9 \pm 11.4$  ( $P = .786$ ) at 2 years after surgery, respectively, in the patients without and those with DVT (Table 4 and Figure 3).

TABLE 2  
Comparison of Radiographic Data and Surgical Procedures Between Study Groups<sup>a</sup>

	Overall (N = 47)	No DVT Group (n = 26)	DVT Group (n = 21)	P
Preoperative radiographic data				
HKA axis, deg	-6.8 ± 3.7	-6.5 ± 4.6	-7.1 ± 2.4	.864 <sup>b</sup>
Blackburne-Peel ratio	0.89 ± 0.10	0.89 ± 0.12	0.89 ± 0.09	.884 <sup>c</sup>
Modified Insall-Salvati ratio	1.67 ± 0.17	1.66 ± 0.17	1.67 ± 0.17	.802 <sup>b</sup>
Posterior tibial slope, deg	9.2 ± 3.2	8.5 ± 3.0	9.9 ± 3.2	.166 <sup>c</sup>
Postoperative radiographic data				
HKA axis, deg	2.5 ± 2.6	2.3 ± 3.0	2.6 ± 2.2	.704 <sup>c</sup>
Blackburne-Peel ratio	0.71 ± 0.13	0.69 ± 0.15	0.72 ± 0.11	.495 <sup>b</sup>
Modified Insall-Salvati ratio	1.55 ± 0.17	1.54 ± 0.20	1.55 ± 0.15	.820 <sup>b</sup>
Posterior tibial slope, deg	12.1 ± 3.8	12.1 ± 0.7	12.2 ± 4.1	.856 <sup>b</sup>
Change in HKA, deg	9.2 ± 4.6	8.8 ± 5.5	9.7 ± 3.4	.724 <sup>b</sup>
Correction amount, deg	9.9 ± 2.9	10.1 ± 3.3	9.7 ± 2.5	.891 <sup>b</sup>
Lateral hinge fracture, n (%)				.919 <sup>d</sup>
No fracture	12 (26.1)	7 (28)	5 (23.8)	
Takeuchi type I	29 (63)	15 (60)	14 (66.7)	
Takeuchi type II	5 (10.9)	3 (12)	2 (9.5)	
Takeuchi type III	0 (0)	0 (0)	0 (0)	
Bone graft, n (%)				.538 <sup>e</sup>
No graft	14 (30.4)	7 (28.0)	7 (33.3)	
Allograft	32 (69.6)	18 (72.0)	14 (66.7)	
Operating time, min	107.3 ± 34.0	106.8 ± 38.7	107.9 ± 28.4	.911 <sup>c</sup>
Tourniquet time, min	92.2 ± 24.7	94.3 ± 29.9	89.6 ± 22.6	.561 <sup>c</sup>
Anesthesia, n (%)				.788 <sup>d</sup>
Spinal	42 (89.4)	23 (88.5)	19 (90.5)	.788 <sup>d</sup>
General	5 (10.6)	3 (11.5)	2 (9.5)	

<sup>a</sup>Data are reported as mean ± SD unless otherwise indicated. DVT, deep vein thrombosis; HKA, hip knee angle; OWHTO, opening-wedge high tibial osteotomy.

<sup>b</sup>Mann-Whitney test.

<sup>c</sup>Independent-samples *t* test.

<sup>d</sup>Linear-by-linear association.

<sup>e</sup>Chi-square test.

TABLE 3  
Incidence and Location of DVT After OWHTO Based on Symptoms and Radiographs<sup>a</sup>

	Symptomatic DVT	Asymptomatic DVT	Overall DVT
Incidence, n (%)	4/47 (8.5)	17/47 (36.2)	21/47 (44.7)
Location, n (%)			
Distal	4/4 (100)	17/17 (100)	21/21 (100)
Muscular vein (gastrocnemius, soleus)	4/4 (100)	16/17 (94.1)	20/21 (95.2)
Axial vein (peroneal, tibial)	2/4 (50)	14/17 (82.4)	16/21 (76.2)
Peroneal vein	2/2 (100)	9/14 (64.3)	11/16 (68.8)
Tibial vein	1/1 (100)	8/14 (57.1)	9/16 (56.3)
Proximal	1/4 (25)	0/17 (0)	1/21 (4.8)
Popliteal vein	1/4 (25)	0/17 (0)	1/21 (4.8)
Femoral vein	1/4 (25)	0/17 (0)	1/21 (4.8)
Common femoral vein	0/4 (0)	0/17 (0)	1/21 (4.8)
Above iliac vein	0/4 (0)	0/17 (0)	0/21 (4.8)

<sup>a</sup>DVT, deep vein thrombosis; OWHTO, opening-wedge high tibial osteotomy.

## DISCUSSION

No guidelines have been established for DVT in patients undergoing OWHTO.<sup>39</sup> Although some studies have not recommended prophylactic management based on the lower incidence of DVT after OWHTO, a previous study has focused only on symptomatic DVT.<sup>31</sup> Information is lacking regarding the overall incidence of early DVT after OWHTO, thrombus location, and the relationship between DVT and clinical outcome. The principal findings of our study were that the overall incidence of DVT after OWHTO was 44.7% and that DVT was located mostly at the distal portion of the lower extremity around the osteotomy site. However, these had no adverse effects on clinical outcome until 2 years after surgery.

Our findings confirmed our hypothesis that the overall incidence of DVT after OWHTO would be higher than that reported in previous studies. The incidence of symptomatic DVT after OWHTO had been reported to range from 1.4% to 9.7%, even with VTE chemoprophylaxis.<sup>24,27,30,39</sup> The overall incidence (symptomatic and asymptomatic) of DVT after HTO has been reported only after closing-wedge HTO.<sup>40</sup> Turner et al<sup>40</sup> found through postoperative venography that the overall incidence of DVT was 41%. Our findings

TABLE 4  
Comparison of Clinical Outcomes Between Study Groups<sup>a</sup>

	IKDC score			P
	Overall (N = 47)	No DVT Group (n = 26)	DVT Group (n = 21)	
Time period				.906 <sup>b</sup>
Preoperative	34.2 ± 7.8	33.6 ± 7.2	35.3 ± 9.1	.910 <sup>c</sup>
Postoperative 6 mo	39.2 ± 7.0	38.1 ± 5.6	40.6 ± 8.4	.531 <sup>c</sup>
Postoperative 1 y	44.3 ± 8.0	41.4 ± 7.3	48.0 ± 7.5	.013 <sup>c</sup>
Postoperative 2 y	45.5 ± 9.9	44.8 ± 6.9	45.9 ± 11.4	.786 <sup>d</sup>

<sup>a</sup>Data are reported as mean ± SD. P values were corrected using the Bonferroni method. DVT, deep vein thrombosis; IKDC, International Knee Documentation Committee; OWHTO, opening-wedge high tibial osteotomy.

<sup>b</sup>Linear mixed model.

<sup>c</sup>Mann-Whitney test.

<sup>d</sup>Independent-samples *t* test.

on the incidence of symptomatic DVT after OWHTO (8.5%) were in line with previous studies. However, the overall incidence of DVT (44.7%) was higher than that reported by Turner et al.<sup>40</sup> This discrepancy might be explained by the difference in leg length after surgery. After surgery, the length of the tibia was shortened to  $-6.0 \pm 2.1$  mm after closing-wedge HTO; however, it was lengthened to  $5.2 \pm 3.7$  mm after OWHTO, which might have caused stretching of the neurovascular bundles.<sup>20</sup>

Our findings confirmed our hypothesis that DVT after OWHTO might be located at the lower extremity vein around the osteotomy site. As no studies have investigated the location of DVT after OWHTO, we referred to a study on DVT after TKA.<sup>7,21</sup> The incidence and location of DVT after TKA was analyzed by Keum Min Hwang using MDCT venography during the same period when OWHTO was performed in our institute (unpublished data, 2019). The incidence of DVT after TKA was 65.6% (59/90 cases), which is comparable with that reported in previous studies (40.4%-72%).<sup>13,41,42,45</sup> The proportions of distal and axial DVT were 93.2% (55/59 cases) and 71.2% (42/59 cases), which were lower than our results. The difference in the proportion of DVT might have stemmed from not only characteristics such as age, body mass index, and underlying diseases but also the characteristics of the surgical procedure. Neurovascular bundles were located close to the posterior tibial cortex.<sup>10,19</sup> The distance from the posterior tibial cortex to the neurovascular bundles was  $9.4 \pm 3.6$  mm at 30° of flexion at 2.0 cm below the knee joint line.<sup>19</sup> In our study, the surgical procedures performed around the osteotomy site during OWHTO might have stimulated the stretched neurovascular bundles, even though they were protected by a Hohmann retractor. The characteristics of the surgical procedure might have contributed to the location of distal DVT. Therefore, surgeons should be aware that the overall incidence of DVT after OWHTO is higher than that reported in previous studies and particularly pay attention to the possibility of DVT around the osteotomy site.

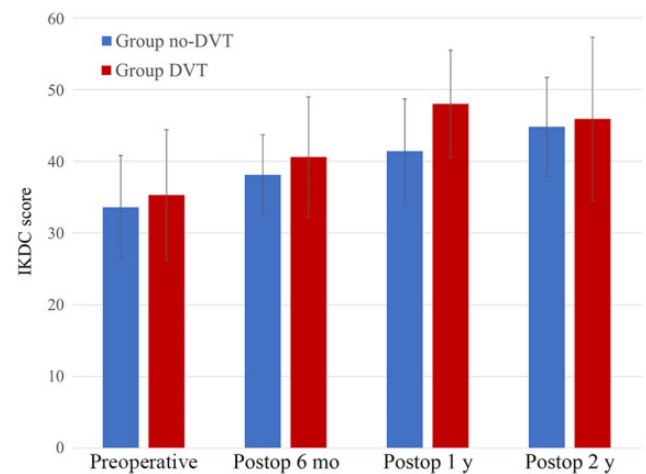


Figure 3. Mean IKDC scores between patients with and without DVT after opening-wedge high tibial osteotomy. Error bars indicate SD. DVT, deep vein thrombosis; IKDC, International Knee Documentation Committee; Postop, postoperative.

The results of our study did not support our hypothesis that the clinical outcomes after OWHTO would be worse in patients with DVT than in patients without DVT. The clinical significance of DVT is related to the location and the cause of DVT.<sup>9,22,33,36</sup> The survival rate of patients with proximal DVT is lower than that of patients with distal unilateral DVT.<sup>36</sup> Poor clinical outcomes have been reported when patients with DVT had a malignancy at 8-year follow-up.<sup>33</sup> However, a good clinical outcome has been reported when DVT was associated with surgery.<sup>9,22</sup> Cordell-Smith et al<sup>9</sup> performed venography after total hip arthroplasty and TKA postoperatively between the 7th and 10th day in all patients. After managing the proximal DVT using warfarin for 3 months, they found no difference in patient satisfaction after total hip arthroplasty and TKA according to DVT. Another study has reported that both proximal and distal DVTs after TKA did not progress to PTE without treatment.<sup>22</sup> In our study, the clinical outcomes of OWHTO with DVT were comparable with those of OWHTO without DVT. This might stem from the high proportion of distal DVTs as compared with that of proximal DVTs. As the clinical significance of distal DVT is known to be lower than that of proximal DVT, it might not have a significant effect on the clinical outcome after OWHTO.<sup>14,17,29,36</sup> Therefore, even though DVT developed after OWHTO, it did not affect significantly the clinical outcome of OWHTO.

Several limitations of this study should be considered. First, the study was evaluated retrospectively and had a relatively small number of cases. However, postoperative MDCT venography was performed in all patients after surgery, and the overall incidence of DVT after OWHTO could be analyzed accurately. Thus, we believe that our findings can provide valuable information to readers. Second, the short-term follow-up after surgery was inadequate. Although no significant difference in clinical outcomes after

surgery was observed, the time of evaluation was at least 6 months after surgery. If the clinical outcomes were evaluated in <6 months, the recovery patterns may be different. Third, we performed MDCT venography on the fourth postoperative day, as Tilton et al<sup>39</sup> indicated that symptoms related to DVT occurred within 48 hours of surgery, and patients at our hospital were discharged 5 to 7 days after OWHTO. However, the time when DVT was formed varied depending on the type of surgery.<sup>4,5,26</sup> Although 80% of DVTs were found within 2 weeks of knee arthroscopy,<sup>26</sup> DVTs have been reported to occur at 1 month after TKA.<sup>4,35</sup> Therefore, if we performed MDCT venography after the fourth postoperative day, the incidence of DVT after OWHTO might increase. In addition, based on previous studies, MDCT venography should be performed if patients are suspected of having DVT even up to postoperative 1 month.<sup>4,26,35</sup> Fourth, we did not perform MDCT preoperatively to find asymptomatic DVT. However, preoperative evaluation of DVT was unnecessary, even in patients who underwent TKA because preoperative DVT was rare and clinical relevance was limited.<sup>7</sup> Patients included in our study were younger and had fewer comorbidities compared with those who underwent TKA. Although patients were evaluated to determine whether they had DVT or not via history and physical examination, there was the possibility that patients had asymptomatic DVT preoperatively, which affected the incidence of DVT after OWHTO. Finally, this study enrolled Asian and mostly female patients. The incidence of DVT after surgery in Westerners has been reported to be higher than in Asians.<sup>21,23</sup> Thus, the differences in ethnicity and proportion of sex should be considered.

## CONCLUSION

Although the incidence of symptomatic DVT after OWHTO was 8.5%, the overall incidence was 44.7%. All DVTs were found in the distal portion of the lower extremity vein, particularly around the osteotomy site (76.2%). Even though the patients had DVT after OWHTO, this was not related to the inferior short-term clinical outcomes after surgery.

## REFERENCES

- Asbeutah AM, Riha AZ, Cameron JD, McGrath BP. Five-year outcome study of deep vein thrombosis in the lower limbs. *J Vasc Surg.* 2004; 40(6):1184-1189.
- Attinger MC, Behrend H, Jost B. Complete rupture of the popliteal artery complicating high tibial osteotomy. *J Orthop.* 2014;11(4): 192-196.
- Berg EE, Mason SL, Lucas MJ. Patellar height ratios: a comparison of four measurement methods. *Am J Sports Med.* 1996;24(2):218-221.
- Björnarå B, Gudmundsen T, Dahl O. Frequency and timing of clinical venous thromboembolism after major joint surgery. *J Bone Joint Surg Br.* 2006;88(3):386-391.
- Bushnell BD, Anz AW, Bert JM. Venous thromboembolism in lower extremity arthroscopy. *Arthroscopy.* 2008;24(5):604-611.
- Cham M, Yankelevitz D, Shaham D, et al. Deep venous thrombosis: detection by using indirect CT venography. The Pulmonary Angiography-Indirect CT Venography Cooperative Group. *Radiology.* 2000; 216(3):744-751.
- Chang MJ, Song MK, Kyung MG, et al. Incidence of deep vein thrombosis before and after total knee arthroplasty without pharmacologic prophylaxis: a 128-row multidetector CT indirect venography study. *BMC Musculoskelet Disord.* 2018;19(1):1-6.
- Cooke TDV, Sled EA, Scudamore RA. Frontal plane knee alignment: a call for standardized measurement. *J Rheumatol.* 2007;34(9):1796.
- Cordell-Smith J, Williams S, Harper W, Gregg P. Lower limb arthroplasty complicated by deep venous thrombosis: prevalence and subjective outcome. *J Bone Joint Surg Br.* 2004;86(1):99-101.
- Darnis A, Villa V, Debette C, et al. Vascular injuries during closing-wedge high tibial osteotomy: a cadaveric angiographic study. *Orthop Traumatol Surg Res.* 2014;100(8):891-894.
- De Maeseneer M, Bochanen N, van Rooijen G, Neglén P. Analysis of 1338 patients with acute lower limb deep venous thrombosis (DVT) supports the inadequacy of the term "Proximal DVT". *Eur J Vasc Endovasc Surg.* 2016;51(3):415-420.
- Elson D, Petheram T, Dawson M. High reliability in digital planning of medial opening wedge high tibial osteotomy, using Miniaci's method. *Knee Surg Sports Traumatol Arthrosc.* 2015;23(7):2041-2048.
- Fukuda A, Hasegawa M, Kato K, et al. Effect of tourniquet application on deep vein thrombosis after total knee arthroplasty. *Arch Orthop Trauma Surg.* 2007;127(8):671-675.
- Galanaud J, Kahn S, Khau AVK, Laroche J, Quere I. Epidemiology and management of isolated distal deep venous thrombosis. Article in French. *Rev Med Intern.* 2012;33(12):678-685.
- Giachino A. Relationship between deep-vein thrombosis in the calf and fatal pulmonary embolism. *Can J Surg.* 1988;31(2):129-130.
- Irrgang JJ, Anderson AF, Boland AL, et al. Development and validation of the international knee documentation committee subjective knee form. *Am J Sports Med.* 2001;29(5):600-613.
- Kakkar V, Howe C, Flanc C, Clarke M. Natural history of postoperative deep-vein thrombosis. *Lancet.* 1969;294(7614):230-233.
- Kearon C, Akl EA, Ornelas J, et al. Antithrombotic therapy for VTE disease: CHEST guideline and expert panel report. *Chest.* 2016; 149(2):315-352.
- Kim J, Allaire R, Harner CD. Vascular safety during high tibial osteotomy: a cadaveric angiographic study. *Am J Sports Med.* 2010;38(4): 810-815.
- Kim JI, Kim BH, Lee KW, et al. Lower limb length discrepancy after high tibial osteotomy: prospective randomized controlled trial of lateral closing versus medial opening wedge osteotomy. *Am J Sports Med.* 2016;44(12):3095-3102.
- Kim K-I, Cho K-Y, Jin W, Khurana SS, Bae D-K. Recent Korean perspective of deep vein thrombosis after total knee arthroplasty. *J Arthroplasty.* 2011;26(7):1112-1116.
- Kim Y-H, Kim J-S. Incidence and natural history of deep-vein thrombosis after total knee arthroplasty: a prospective, randomised study. *J Bone Joint Surg Br.* 2002;84(4):566-570.
- Lee W-S, Kim K-I, Lee H-J, Kyung H-S, Seo S-S. The incidence of pulmonary embolism and deep vein thrombosis after knee arthroplasty in Asians remains low: a meta-analysis. *Clin Orthop Relat Res.* 2013;471(5):1523-1532.
- Martin R, Birmingham TB, Willits K, et al. Adverse event rates and classifications in medial opening wedge high tibial osteotomy. *Am J Sports Med.* 2014;42(5):1118-1126.
- Masuda EM, Kistner RL, Musikasinthorn C, et al. The controversy of managing calf vein thrombosis. *J Vasc Surg.* 2012;55(2):550-561.
- Michot M, Conen D, Holtz D, et al. Prevention of deep-vein thrombosis in ambulatory arthroscopic knee surgery: a randomized trial of prophylaxis with low-molecular weight heparin. *Arthroscopy.* 2002; 18(3):257-263.
- Miller BS, Downie B, McDonough EB, Wojtys EM. Complications after medial opening wedge high tibial osteotomy. *Arthroscopy.* 2009; 25(6):639-646.
- Miniaci A, Ballmer F, Ballmer P, Jakob R. Proximal tibial osteotomy: a new fixation device. *Clin Orthop Relat Res.* 1989(246):250-259.
- Moser KM, LeMoine JR. Is embolic risk conditioned by location of deep venous thrombosis? *Ann Intern Med.* 1981;94(4 part 1):439-444.

30. Motycka T, Eggerth G, Landsiedl F. The incidence of thrombosis in high tibial osteotomies with and without the use of a tourniquet. *Arch Orthop Trauma Surg.* 2000;120(3-4):157-159.
31. Noyes F, Barber-Westin S, Levy M. Are anticoagulants required after high tibial osteotomy to prevent venous thromboembolism events? A systematic review. *J Orthop Res Physiother.* 2017;3:030.
32. Ozel O, Yucler B, Mutlu S, Orman O, Mutlu H. Changes in posterior tibial slope angle in patients undergoing open-wedge high tibial osteotomy for varus gonarthrosis. *Knee Surg Sports Traumatol Arthrosc.* 2017;25(1):314-318.
33. Prandoni P, Lensing AW, Prins MR. Long-term outcomes after deep venous thrombosis of the lower extremities. *Vasc Med.* 1998;3(1): 57-60.
34. Schellong S, Beyer J, Kakkar A, et al. Ultrasound screening for asymptomatic deep vein thrombosis after major orthopaedic surgery: the VENUS study. *J Thromb Haemost.* 2007;5(7):1431-1437.
35. Seagroatt V, Tan HS, Goldacre M, et al. Elective total hip replacement: incidence, emergency readmission rate, and postoperative mortality. *Br Med J.* 1991;303(6815):1431-1435.
36. Seinturier C, Bosson J, Colonna M, Imbert B, Carpentier P. Site and clinical outcome of deep vein thrombosis of the lower limbs: an epidemiological study. *J Thromb Haemost.* 2005;3(7): 1362-1367.
37. Shin WC, Woo SH, Lee S-J, et al. Preoperative prevalence of and risk factors for venous thromboembolism in patients with a hip fracture: an indirect multidetector CT venography study. *J Bone Joint Surg Am.* 2016;98(24):2089-2095.
38. Takeuchi R, Ishikawa H, Kumagai K, et al. Fractures around the lateral cortical hinge after a medial opening-wedge high tibial osteotomy: a new classification of lateral hinge fracture. *Arthroscopy.* 2012;28(1): 85-94.
39. Tilton A, Frank RM, Park W, Cole BJ. Rates of deep vein thrombosis occurring after osteotomy about the knee. *Am J Orthop.* 2017;46(1): E23-E27.
40. Turner R, Griffiths H, Heatley F. The incidence of deep-vein thrombosis after upper tibial osteotomy: a venographic study. *J Bone Joint Surg Br.* 1993;75(6):942-944.
41. Wang C-J, Huang C-C, Yu P-C, Chen H-H. Diagnosis of deep venous thrombosis after total knee arthroplasty: a comparison of ultrasound and venography studies. *Hospitals.* 2004;8:12.
42. Wang C-J, Wang J-W, Chen L-M, et al. Deep vein thrombosis after total knee arthroplasty. *J Formos Med Assoc.* 2000;99(11):848-853.
43. Wang C-J, Wang J-W, Weng L-H, Hsu C-C, Lo C-F. Outcome of calf deep-vein thrombosis after total knee arthroplasty. *J Bone Joint Surg Br.* 2003;85(6):841-844.
44. Wells P, Hirsh J, Anderson D, et al. Accuracy of clinical assessment of deep-vein thrombosis. *Lancet.* 1995;345(8961):1326-1330.
45. Yamaguchi T, Hasegawa M, Niimi R, Sudo A. Incidence and time course of asymptomatic deep vein thrombosis with fondaparinux in patients undergoing total joint arthroplasty. *Thromb Res.* 2010;126(4): e323-e326.