

Clinical significance and epidemiological evolution of epitrochlear lymphadenopathy in pre- and post-highly active antiretroviral therapy era: A systematic review of the literature

Valliappan Muthu, Inderpaul Singh Sehgal, Sahajal Dhooria, Ritesh Agarwal

Department of Pulmonary Medicine, Postgraduate Institute of Medical Education and Research, Chandigarh, India

ABSTRACT

Epitrochlear lymphadenopathy is believed to be associated with distinct etiologies, however the evidence for the same is lacking. We systematically reviewed the reported causes of an enlarged epitrochlear lymph node and compared them over different time periods. Epitrochlear lymphadenopathy was encountered in a wide range of diseases, and we found no association with any particular disease.

KEY WORDS: Human immunodeficiency virus, infection, lymphoma, sarcoidosis, tuberculosis

Address for correspondence: Dr. Ritesh Agarwal, Department of Pulmonary Medicine, Postgraduate Institute of Medical Education and Research, Chandigarh - 160 012, India. E-mail: agarwal.ritesh@outlook.in

INTRODUCTION

The site of enlarged lymph nodes has little relevance to the etiology. However, epitrochlear lymph nodes have been linked in the past with syphilis and recently to sarcoidosis and human immunodeficiency virus (HIV) infection.^[1-3] Traditional teaching in clinical medicine emphasizes the importance of examining this node, considering the specific diseases it can diagnose. The scientific basis for such an assumption is lacking, and a comprehensive review on the various causes of epitrochlear lymphadenopathy is not available. Herein, we systematically review the literature to ascertain the various causes of epitrochlear lymphadenopathy and its possible association with a distinct etiology.

METHODS

We performed a search of the PubMed database from inception till 31st August 2017 using the following

free-text terms: “epitrochlear” OR “epitrochlear node” OR “epitrochlear adenopathy” OR “epitrochlear lymph node” OR “epitrochlear lymphadenopathy” OR “epitrochlear gland”. In addition, we reviewed the reference list of all the included articles and sifted our personal files.

Inclusion and exclusion criteria

We included articles meeting the following criteria: (a) palpable epitrochlear lymphadenopathy ≥ 1 cm in transverse diameter or the presence of hard immobile nodes and (b) cases reported to have definitive diagnosis proven by histology/cytology/microbiology or other ancillary tests. Articles were excluded if: (a) epitrochlear node enlargement was evident only on investigations like lymphoscintigraphy, (b) no specific etiology was identified, (c) animal studies, and (d) publications in language other than English.

This is an open access article distributed under the terms of the Creative Commons Attribution-NonCommercial-ShareAlike 3.0 License, which allows others to remix, tweak, and build upon the work non-commercially, as long as the author is credited and the new creations are licensed under the identical terms.

For reprints contact: reprints@medknow.com

How to cite this article: Muthu V, Sehgal IS, Dhooria S, Agarwal R. Clinical significance and epidemiological evolution of epitrochlear lymphadenopathy in pre- and post-highly active antiretroviral therapy era: A systematic review of the literature. Lung India 2018;35:150-3.

Access this article online	
Quick Response Code: 	Website: www.lungindia.com
	DOI: 10.4103/lungindia.lungindia_13_17

A database was created from our search using the reference manager EndNote (version X8.1; Clarivate Analytics). Duplicate citations were discarded. Two authors (VM and RA) independently screened the database for relevant articles, and any discrepancy was resolved by discussion. After scrutiny, we reviewed the full text of the selected articles. The following information was then extracted: (a) details of publication (year, country and authors), (b) number of patients with enlarged epitrochlear node in each study, and (c) the final etiology of the enlarged epitrochlear node.

We compared the various causes of epitrochlear enlargement over the three-time periods: (a) pre-HIV (1983 and before), (b) pre-highly active antiretroviral therapy (HAART) (1984 till 1996), and (c) post-HAART era (1997 till 2017).

Data were represented as number (percentages) and the reported etiology was tabulated for the three different time periods.

RESULTS

We identified 144 articles, of which 79 (including 507 subjects) were found to be eligible for inclusion.^[2-80] Infections ($n = 356$, 70.2%) and neoplasms ($n = 116$, 22.9%) were the most common reported causes of an enlarged epitrochlear node [Table 1].

Pre-human immunodeficiency virus era

Infections represented more than two-thirds of the reported causes, with leprosy being the most common ($n = 68$, 74.7%). Neoplasms (Hodgkin's lymphoma [HL], followed by non-Hodgkin's lymphoma [NHL] and melanoma) were the next common cause.

Pre-highly active antiretroviral therapy era

The most common cause in this era was infections (82.6%) of which HIV (with or without tuberculosis [TB]) infection constituted the majority (71.8%). Tuberculous epitrochlear lymphadenitis was either secondary to disseminated

Table 1: Specific etiologies of epitrochlear lymph node enlargement reported in literature-compared between pre-human immunodeficiency virus, pre-highly active antiretroviral therapy, and post-highly active antiretroviral therapy era

Etiology	Disease	Pre-HIV era (1983 and before), <i>n</i> (references)	Pre-HAART era (1984-1996), <i>n</i> (references)	Post-HAART era (1997-2017), <i>n</i> (references)
Infectious causes ($n=356$, 70.2%)	TB in HIV individuals	-	57 ^[69]	-
	HIV (without TB)	-	83* ^[3,21,69]	-
	Acute suppurative lymphadenitis	15 ^[58]	1 ^[72]	1 ^[46]
	Cat scratch disease	2 ^[33]	7 ^[14,26,53,55,80]	42 ^[12,22,28,35,46,47,54,66]
	TB	4 ^[19,63]	15 ^[20,69]	2 ^[49,59]
	Leprosy	68 ^[36]	-	-
	Cutaneous leishmaniasis	-	18 ^[52,68,71,75,78]	16 ^[17,43,48]
	Infectious mononucleosis	-	12 ^[21]	6 ^[74]
	Filariasis	-	2 ^[57,76]	1 ^[50]
	<i>Mycobacterium avium</i>	-	-	1 ^[70]
	Syphilis	1 ^[64]	-	-
	<i>Salmonella enteritis</i>	1 ^[30]	-	-
	<i>Staphylococcus sp.</i>	-	-	1 ^[46]
	Noninfectious, nonneoplastic causes ($n=35$, 6.9%)	Rheumatoid arthritis	4 ^[10,15]	9 ^[21]
Sarcoidosis		-	3 ^[21]	8 ^[8,23,28]
Kimura disease		-	-	8 ^[4,9,24,31,41,61,62]
Silicone in rheumatoid patient		-	-	1 ^[73]
Talc in IV drug user		-	1 ^[42]	-
Neoplastic causes ($n=116$, 22.9%)	Lymphoma HL	12 ^[11,27,65,67]	6 ^[5,18,21]	21 ^[2,7,13,32,38]
	NHL	17 ^[45]	17 ^[21,37]	1 ^[39]
	Chronic lymphocytic leukemia	-	4 ^[21]	-
	Melanoma	7 ^[16]	-	12 ^[6,40,60]
	Squamous cell carcinoma	-	-	5 ^[29,44,79]
	Kaposi sarcoma	-	-	5** ^[51]
	Metastases	-	-	2 ^[34,46] #
	Merkel cell carcinoma	-	-	2*** ^[46,56]
	Soft tissue sarcoma	-	1 ^[25]	3 ^[28]
	Reticulum cell neoplasia	-	-	1 ^[77]
Total ($n=507$)		131	236	140

*123 patients had enlargement >0.5 cm but only those 53 patients with a node >1 cm are included here, **Only one of these five cases were HIV positive, # Metastases from spinocellular epithelioma of face and invasive ductal carcinoma of breast, ***Biopsy/lymphadenectomy and hence definite proof of Merkel cell carcinoma available in one patient only (though 8 of the total 38 patients had axillary/epitrochlear node enlargement). HAART: Highly active antiretroviral therapy, HIV: Human immunodeficiency virus, HL: Hodgkin's lymphoma, IV: Intravenous, *n*: Number of cases, NHL: Non-Hodgkin's lymphoma, TB: Tuberculosis

TB or synovial TB of the wrist.^[19] Noninfectious causes such as rheumatoid arthritis and sarcoidosis were also diagnosed during this period; however, their proportion was small (5.5%). Lymphoma (NHL and HL) was the most commonly reported neoplasm in this era as well.

Post-highly active antiretroviral therapy era

Unlike the previous two-time periods, the proportion of infectious causes decreased to 50.4% [Figure 1]. Cat-scratch disease was the most common reported infectious cause (60%). Among the neoplastic causes, HL was the most common, apart from several other tumors (Kaposi's sarcoma, Merkel-cell carcinoma, and others). Kimura's disease and sarcoidosis were infrequently reported noninfectious causes.

DISCUSSION

The results of this systematic review suggest that the epidemiology of epitrochlear lymphadenopathy has evolved over the last few decades. There was a 3-fold increase in the rate of noninfectious causes (from 17.5% to 49.6%) over time [Figure 1]. The apparent increase in the noninfectious causes is probably due to a decreased burden of infectious illnesses in the post-HAART era. The "traditional" etiologies including syphilis and sarcoidosis were seldom encountered. This is because epitrochlear adenopathy results either from involvement of its drainage area by pathologic processes (analogous to other regional lymph nodes) or part of a systemic illness, rather than any particular etiology (syphilis, sarcoidosis, or HIV).

Our review has certain limitations. As most of the causes of an enlarged epitrochlear node were identified from case reports and series, it is not possible to estimate the true proportion of various etiologies. Nevertheless, it provides an overview of the various etiologies causing epitrochlear node enlargement in contemporary medicine.

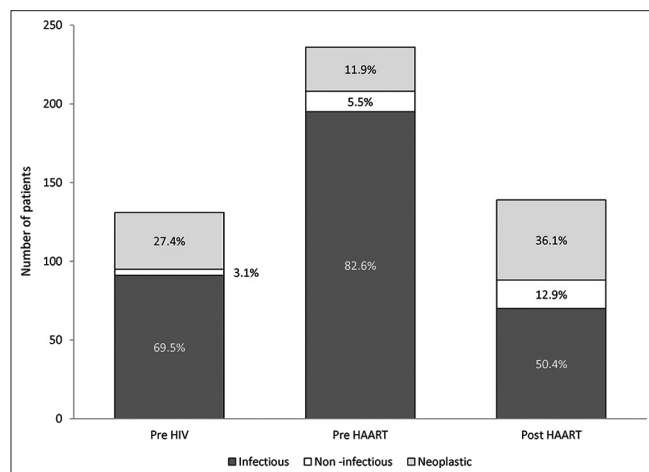


Figure 1: Comparison of the proportion of infectious, noninfectious and neoplastic causes of epitrochlear node enlargement reported in the pre-human immunodeficiency virus, pre- and post-highly active antiretroviral therapy era

Financial support and sponsorship

Nil.

Conflicts of interest

There are no conflicts of interest.

REFERENCES

- Martin L. Palpable epitrochlear glands; incidence and relation to syphilis. *Lancet* 1947;1:363.
- Chang BK, Backstrand KH, Ng AK, Silver B, Hitchcock SL, Mauch PM, et al. Significance of epitrochlear lymph node involvement in Hodgkin disease. *Cancer* 2001;91:1213-8.
- Malin A, Ternouth I, Sarbah S. Epitrochlear lymph nodes as marker of HIV disease in sub-Saharan Africa. *BMJ* 1994;309:1550-1.
- Zhu SL, Wei PF, Chen JH, Zhao ZF, Xu QN, Ye L, et al. Diagnosis and treatment of a patient with Kimura's disease associated with nephrotic syndrome and lymphadenopathy of the epitrochlear nodes. *BMC Nephrol* 2015;16:10.
- Yu A, Steinfeld AD. Hodgkin's disease presenting in epitrochlear nodes. *Med Pediatr Oncol* 1984;12:244-6.
- Yoshida Y, Takahashi A, Koga M, Koga K, Kubota Y, Nakayama J. Case of metastatic melanoma in an epitrochlear lymph node arising in a pregnant woman. *J Dermatol* 2007;34:48-51.
- Yardimci VH, Yardimci AH. An unusual first manifestation of hodgkin lymphoma: Epitrochlear lymph node involvement – A case report and brief review of literature. *J Investig Med High Impact Case Rep* 2017;5:2324709617706709.
- Yanardag H, Caner M, Papila I, Uygun S, Demirci S, Karayel T, et al. Diagnostic value of peripheral lymph node biopsy in sarcoidosis: A report of 67 cases. *Can Respir J* 2007;14:209-11.
- Yadla M, Sriramaveen P, Sivakumar V, Sandeep Reddy Y, Sridhar AV, Krishna Kishore C, et al. Epitrochlear mass in a patient on maintenance hemodialysis – Kimura disease. *Hemodial Int* 2012;16:568-70.
- Weston WJ. Enlarged supratrochlear lymphatic glands in rheumatoid arthritis. *Australas Radiol* 1968;12:260-4.
- Weiss RB, Jenkins JJ 3rd. Hodgkin's disease presenting in epitrochlear lymph nodes. *South Med J* 1977;70:513-5.
- Vögelin E, Büchler U. An epitrochlear tumour. *J R Soc Med* 2001;94:403-5.
- Vicente Baz D, Ruiz Borrego M, Arriola Arellano E, Fernández-Freire A, Moreno Nogueira JA. Epitrochlear Hodgkin's disease. Report of a new case. *An Med Interna* 2003;20:332.
- Vanlemmens P, Leroy J, Estavoyer JM, Destuynder O, Aubert D, Viennet G, et al. A little known cause of persistent fever and granulomatous hepatitis in children: Cat scratch disease. *Arch Pediatr* 1995;2:657-61.
- Spriggs EI. Rheumatoid arthritis with enlargement of lymphatic glands and spleen. *Proc R Soc Med* 1910;3:15-9.
- Smith TJ, Sloan GM, Baker AR. Epitrochlear node involvement in melanoma of the upper extremity. *Cancer* 1983;51:756-60.
- Silveira FT, Lainson R, Corbett CE. Further observations on clinical, histopathological, and immunological features of borderline disseminated cutaneous leishmaniasis caused by leishmania (Leishmania) amazonensis. *Mem Inst Oswaldo Cruz* 2005;100:525-34.
- Shah KJ. Hodgkin's disease in epitrochlear lymph node only. *South Med J* 1991;84:1509.
- Sevitt S. The diagnosis of synovial tuberculosis of the hand and wrist by epitrochlear gland biopsy. *Br J Surg* 1954;41:375-6.
- Seth V, Kabra SK, Jain Y, Semwal OP, Mukhopadhyaya S, Jensen RL, et al. Tubercular lymphadenitis: Clinical manifestations. *Indian J Pediatr* 1995;62:565-70.
- Selby CD, Marcus HS, Toghil PJ. Enlarged epitrochlear lymph nodes: An old physical sign revisited. *J R Coll Physicians Lond* 1992;26:159-61.
- Schmoor P, Darie H, Maccari F, Gros P, Millet P. Cutaneous vasculitis disclosing cat-scratch disease. *Ann Dermatol Venereol* 1998;125:894-6.
- Rajasekharan P, Narurkar S, Patel K, Rajpal A. Asteroid bodies in a lymph node aspirate. A case report. *Acta Cytol* 2007;51:66-7.
- Park JS, Jin W, Ryu KN, Won KY. Bilateral asymmetric superficial soft tissue masses with extensive involvement of both upper extremities: Demonstration of Kimura's disease by US and MRI (2008: 12b). *Eur Radiol* 2009;19:781-6.

25. Okunieff P, Suit HD, Proppe KH. Extremity preservation by combined modality treatment of sarcomas of the hand and wrist. *Int J Radiat Oncol Biol Phys* 1986;12:1923-9.
26. Nimityongskul P, Anderson LD, Sri P. Cat-scratch disease: Orthopaedic presentation. *Orthop Rev* 1992;21:55-9.
27. Meyer JE, Halperin EC, Linggood RM. Upper extremity lymphangiography as an aid to treatment planning for stage 1A epitrochlear Hodgkin's disease. *Cardiovasc Intervent Radiol* 1982;5:279-80.
28. Melville DM, Jacobson JA, Downie B, Biermann JS, Kim SM, Yablon CM, et al. Sonography of cat scratch disease. *J Ultrasound Med* 2015;34:387-94.
29. Meesiri S. Subungual squamous cell carcinoma masquerading as chronic common infection. *J Med Assoc Thai* 2010;93:248-51.
30. Macdougall LG. Epitrochlear abscess formation complicating salmonella enteritis. *East Afr Med J* 1954;31:427-30.
31. Lu HJ, Tsai JD, Sheu JC, Tzen CY, Tsai TC, Lin CC, et al. Kimura disease in a patient with renal allograft failure secondary to chronic rejection. *Pediatr Nephrol* 2003;18:1069-72.
32. Llamas-Velasco M, Fraga J, Pérez-Gala S, Cannata J, Kempf W, Adrados M, et al. Specific skin infiltration as first sign of localized stage Hodgkin's lymphoma involving an epitrochlear node. *Am J Dermatopathol* 2015;37:499-502.
33. Laskin RS, Potenza AD. Cat scratch fever – A confusing diagnosis for the orthopaedic surgeon. Two case reports and a review of the literature. *J Bone Joint Surg Am* 1971;53:1211-4.
34. Kumar P, Singh S, Datta NR, Tandon A. Epitrochlear lymph node metastases from invasive ductal breast cancer. *J Cancer Res Ther* 2009;5:203-5.
35. King KY, Hicks MJ, Mazziotti MV, Eldin KW, Starke JR, Michael M, et al. Persistent cat scratch disease requiring surgical excision in a patient with MPGN. *Pediatrics* 2015;135:e1514-7.
36. Kar HK, Mohanty HC, Mohanty GN, Nayak UP. Clinico-pathological study of lymph node involvement in leprosy. *Lepr India* 1983;55:725-38.
37. Kant JA, Hubbard SM, Longo DL, Simon RM, DeVita VT Jr., Jaffe ES. The pathologic and clinical heterogeneity of lymphocyte-depleted Hodgkin's disease. *J Clin Oncol* 1986;4:284-94.
38. Jiménez Gonzalo FJ, Medina Pérez M, Ríos Herranz E. Hodgkin's disease with epitrochlear onset. *An Med Interna* 2001;18:554.
39. Jeong G, Kim J, Han S, Lee J, Park K, Pak C, et al. Coexistence of follicular lymphoma and an unclassifiable myeloproliferative neoplasm in a treatment-naive patient: A case report. *Oncol Lett* 2016;11:1469-73.
40. Hunt JA, Thompson JF, Uren RF, Howman-Giles R, Harman CR. Epitrochlear lymph nodes as a site of melanoma metastasis. *Ann Surg Oncol* 1998;5:248-52.
41. Huang GS, Lee HS, Chiu YC, Yu CC, Chen CY. Kimura's disease of the elbows. *Skeletal Radiol* 2005;34:555-8.
42. Housini I, Dabbs DJ, Coyne L. Fine needle aspiration cytology of talc granulomatosis in a peripheral lymph node in a case of suspected intravenous drug abuse. *Acta Cytol* 1990;34:342-4.
43. Harms G, Fraga F, Batroff B, Oliveira F, Feldmeier H. Cutaneous leishmaniasis associated with extensive lymphadenopathy during an epidemic in Ceara State, Northeast Brazil. *Acta Trop* 2005;93:303-10.
44. Goh A, Howle J, Hughes M, Veness MJ. Managing patients with cutaneous squamous cell carcinoma metastatic to the axilla or groin lymph nodes. *Australas J Dermatol* 2010;51:113-7.
45. Glatstein E, Fuks Z, Goffinet DR, Kaplan HS. Non-Hodgkin's lymphomas of stage III extent. Is total lymphoid irradiation appropriate treatment? *Cancer* 1976;37:2806-12.
46. Gielen J, Wang XL, Vanhoenacker F, De Schepper H, De Beuckeleer L, Vandevenne J, et al. Lymphadenopathy at the medial epitrochlear region in cat-scratch disease. *Eur Radiol* 2003;13:1363-9.
47. Giannotti BF, Bush DC, Tyler WB. Cat-scratch disease presenting as an epitrochlear arm mass. *Orthopedics* 1998;21:586-8.
48. Garg VK, Agrawal S, Rani S, Joshi A, Agarwalla A, Das ML, et al. Post-kala-azar dermal leishmaniasis in Nepal. *Int J Dermatol* 2001;40:179-84.
49. Garg PK, Kumar A. Tubercular epitrochlear lymphadenopathy. *Surg Infect (Larchmt)* 2012;13:177-8.
50. Garg PK, Jain BK, Rath V, Singh N, Mohanty D. Mid-arm and epitrochlear lymphadenopathy: A clinico-radiological surprise. *J Infect Dev Ctries* 2011;5:820-4.
51. Gamborino E, Carrilho C, Ferro J, Khan MS, Garcia C, Suarez MC, et al. Fine-needle aspiration diagnosis of Kaposi's sarcoma in a developing country. *Diagn Cytopathol* 2000;23:322-5.
52. Gaafar A, Ismail A, el Kadar AY, Hashim E, Khalil EA, el Hassan AM, et al. Necrotizing and suppurative lymphadenitis in leishmania major infections. *Trop Med Int Health* 1996;1:243-50.
53. Fox BC, Gurtler RA. Cat-scratch disease mimicking rhabdomyosarcoma. *Orthop Rev* 1993;22:1148-9.
54. Dyachenko P, Ziv M, Raz R, Chazan B, Lev A, Rozenman D, et al. Cat scratch disease encephalopathy in an immunocompetent patient. *Eur J Intern Med* 2005;16:610-1.
55. Donnelly A, Hendricks G, Martens S, Strovers C, Wiemerslage S, Thomas PA, et al. Cytologic diagnosis of cat scratch disease (CSD) by fine-needle aspiration. *Diagn Cytopathol* 1995;13:103-6.
56. Deneve JL, Messina JL, Marzban SS, Gonzalez RJ, Walls BM, Fisher KJ, et al. Merkel cell carcinoma of unknown primary origin. *Ann Surg Oncol* 2012;19:2360-6.
57. De Saram GS, Pieris MV. Filariasis epitrochlear gland. *J Pathol Bacteriol* 1946;58:586.
58. Currarino G. Acute epitrochlear lymphadenitis. *Pediatr Radiol* 1977;6:160-3.
59. Crum NF. Tuberculosis presenting as epitrochlear lymphadenitis. *Scand J Infect Dis* 2003;35:888-90.
60. Covarelli P, Tomassini GM, Servoli A, Picciotto F, Noya G. Epitrochlear lymph node dissection and axillary lymph node biopsy. An unusual clinical presentation in a patient with forearm melanoma. *Ann Surg Oncol* 2013;20:4378.
61. Chokkappan K, Al-Riyami AM, Krishnan V, Min VL. Unusual cause of swelling in the upper limb: Kimura disease. *Oman Med J* 2015;30:372-7.
62. Chen H, Thompson LD, Aguilera NS, Abbondanzo SL. Kimura disease: A clinicopathologic study of 21 cases. *Am J Surg Pathol* 2004;28:505-13.
63. Chanarin I. Epitrochlear adenopathy in the bantu. *S Afr Med J* 1949;23:960-2.
64. Bucher CJ, Ono J. Tracheo-esophageal fistula of syphilitic origin: Report of a case. *Am J Pathol* 1934;10:391-8.5.
65. Birkhead BM, Dobbs CE, Grimaldi M, Shaw JW. Epitrochlear presentation of Hodgkin's disease: Report of a case and review of the literature. *J Ky Med Assoc* 1981;79:717-8.
66. Bernard SA, Walker EA, Carroll JF, Klassen-Fischer M, Murphey MD. Epitrochlear cat scratch disease: Unique imaging features allowing differentiation from other soft tissue masses of the medial arm. *Skeletal Radiol* 2016;45:1227-34.
67. Berman BW, McIntosh S, Goldenring H, Prosnitz LR. Hodgkin's disease as epitrochlear adenopathy. *Am J Dis Child* 1980;134:319.
68. Berger TG, Meltzer MS, Oster CN. Lymph node involvement in leishmaniasis. *J Am Acad Dermatol* 1985;12:993-6.
69. Bem C. Human immunodeficiency virus-positive tuberculous lymphadenitis in central Africa: Clinical presentation of 157 cases. *Int J Tuberc Lung Dis* 1997;1:215-9.
70. Beghin JC, Charlier H, Bodart E, Tuerlinckx D. Nontuberculous mycobacterial epitrochlear adenitis. *Arch Pediatr* 2012;19:1070-3.
71. Barral A, Guerreiro J, Bomfim G, Correia D, Barral-Netto M, Carvalho EM, et al. Lymphadenopathy as the first sign of human cutaneous infection by *Leishmania braziliensis*. *Am J Trop Med Hyg* 1995;53:256-9.
72. Barr LL, Kirks DR. Ultrasonography of acute epitrochlear lymphadenitis. *Pediatr Radiol* 1993;23:72-3.
73. Balint PV, McEntegart A, Jackson R, Forrester AW, Simpson RG. Epitrochlear lymphadenopathy in rheumatoid arthritis caused by silicone particles. *J Rheumatol* 2002;29:1097-9.
74. Balasubramanian S, Ganesh R, Kumar JR. Profile of EBV associated infectious mononucleosis. *Indian Pediatr* 2012;49:837-8.
75. Azadeh B. "Localized" leishmania lymphadenitis: A light and electron microscopic study. *Am J Trop Med Hyg* 1985;34:447-55.
76. Arora VK, Sen B, Dev G, Bhatia A. Fine needle aspiration identification of the adult worm of *Brugia malayi* and its ovarian fragment from an epitrochlear lymph node. *Acta Cytol* 1993;37:437-8.
77. Andriko JW, Kaldjian EP, Tsokos M, Abbondanzo SL, Jaffe ES. Reticulum cell neoplasms of lymph nodes: A clinicopathologic study of 11 cases with recognition of a new subtype derived from fibroblastic reticular cells. *Am J Surg Pathol* 1998;22:1048-58.
78. al-Gindan Y, Kubba R, el-Hassan AM, Omer AH, Kutty MK, Saeed MB, et al. Dissemination in cutaneous leishmaniasis 3. Lymph node involvement. *Int J Dermatol* 1989;28:248-54.
79. Agir H, Adams BM, Mackinnon CA. Squamous cell carcinoma of the palm: A case report. *Acta Orthop Traumatol Turc* 2007;41:321-5.
80. Abarca K, Vial PA, Rivera M, García C, Oddó D, Prado P, et al. Bartonella henselae infection in immunocompetent patients: Cat scratch disease. *Rev Med Chil* 1996;124:1341-9.