

Received: 2018.06.18
Accepted: 2018.08.13
Published: 2018.11.05

e-ISSN 1941-5923
© Am J Case Rep, 2018; 19: 1317-1323
DOI: 10.12659/AJCR.911701

Acquired Platythorax, or Anteroposterior Flattening of the Chest Wall, as a Late Complication of Cyclophosphamide Treatment for Childhood Acute Lymphoblastic Leukemia, Presenting in a Young Man with Respiratory Failure

Authors' Contribution:
Study Design A
Data Collection B
Statistical Analysis C
Data Interpretation D
Manuscript Preparation E
Literature Search F
Funds Collection G

ABCDEF 1 **Tsuyoshi Ito**
ABCD 1 **Satoshi Koyama**
ABCD 2 **Shotaro Iwamoto**
ABCD 2 **Masahiro Hirayama**
ABCDEF 3 **Eiichi Azuma**

1 Department of Pediatrics, Toyohashi Municipal Hospital, Toyohashi, Aichi, Japan
2 Department of Pediatrics, Mie University Graduate School of Medicine, Tsu, Mie, Japan
3 Department of Clinical Engineering, Suzuka University of Medical Science, Suzuka, Mie, Japan

Corresponding Author: Tsuyoshi Ito, e-mail: ito0112@ss.iij4u.or.jp
Conflict of interest: None declared

Patient: Male, 26
Final Diagnosis: Cyclophosphamide-induced pulmonary fibrosis
Symptoms: Platythorax • progressive cardiopulmonary failure
Medication: Cyclophosphamide
Clinical Procedure: Supportive care
Specialty: Oncology

Objective: Adverse events of drug therapy

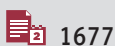
Background: Acquired platythorax, or flattening of the chest with a reduction in the anteroposterior (AP) diameter, is very rare and the prognosis depends on the degree of the deformity, respiratory function, and on any underlying disease. Drug-induced pulmonary fibrosis is associated with pulmonary hypoplasia. A case of acquired platythorax is presented in a young man previously treated with cyclophosphamide in childhood.

Case Report: A 20-year-old man began to experience cough, chest pain, and mild exertional dyspnea. He was admitted to the hospital at 23 years of age with respiratory failure. Chest imaging showed pleural thickening and platythorax. He had been successfully treated for acute lymphoblastic leukemia (ALL), at 3 years of age, with chemotherapy that included a cumulative dose of cyclophosphamide of 15.6 g/m². His ALL relapsed six years later and he was treated again with cyclophosphamide and underwent a second and complete remission. A clinical diagnosis of late-onset cyclophosphamide-induced lung disease with progressive platythorax was made on the basis of his clinical history and on imaging findings of the ratio of the AP to lateral chest wall diameter when compared with age-matched controls. Despite continued remission of his ALL, he died of progressive cardiopulmonary failure at 25 years of age.

Conclusions: This report described a rare case of acquired platythorax, or flattening of the chest, in a young adult. The use of the ratio of the chest wall AP diameter to lateral diameter may be used in the early detection of this rare chemotherapy-induced complication in children and adults.

MeSH Keywords: Cyclophosphamide • Pulmonary Fibrosis • Thoracic Diseases

Full-text PDF: <https://www.amjcaserep.com/abstract/index/idArt/911701>



1677



1



2



18



Background

Chest wall deformities can be congenital or acquired. The most common chest wall deformity is congenital pectus excavatum, which occurs in 88% of cases [1]. Platythorax, or flattening of the chest with a reduction in the anteroposterior (AP) diameter, is very rare [2]. Platythorax can be primary or secondary to diseases of the bone of the chest wall, including pectus excavatum [2] and scoliosis [3] or to pulmonary disease associated with pulmonary fibrosis or pulmonary hypoplasia including congenital diaphragmatic hernia, chronic bronchopulmonary dysplasia [4], pulmonary infection, autoimmune disease, drug-induced pulmonary fibrosis [5], and idiopathic pleuroparenchymal fibroelastosis [6].

Platythorax is very rare, and the prognosis is varied, depending on the degree of the deformity, its effects on respiratory function, and on any underlying disease. Because the condition is rare, the mechanism of its development, pathogenesis, and prognosis remain unknown.

This report is of a young man who developed platythorax due to cyclophosphamide-related pulmonary fibrosis eight years after the cessation of chemotherapy for acute lymphoblastic leukemia (ALL). This report also describes the method used to determine the ratio of the chest wall AP diameter to lateral diameter to show the timeline of progression in the flattening of the chest wall in this patient, compared with twenty long-term survivors of childhood ALL. The pathogenesis of platythorax due to drug-induced pulmonary fibrosis is discussed with a review of the literature on cyclophosphamide-associated pulmonary fibrosis.

Case Report

A 20-year-old man began to experience cough, chest pain, and mild exertional dyspnea. He was admitted to the hospital at 23 years of age with respiratory failure. He had been successfully treated for acute lymphoblastic leukemia (ALL) at 3 years of age, with chemotherapy that included a cumulative dose of cyclophosphamide of 15.6 g/m². His ALL relapsed six years later, when he was 9-years-old, and he was treated again with cyclophosphamide and underwent a second and complete remission. During chemotherapy for ALL, he did not experience pulmonary adverse events, including pneumonia, and chest X-ray at the time of cessation of chemotherapy at 11 years of age was normal (Figure 1A). He was never treated with radiotherapy. Unfortunately, he was lost to follow-up for several years, until he presented to our hospital at the age of 20 years, due to a one-week history of non-productive cough.

On this most recent hospital admission, at the age of 23 years, he was in respiratory failure, and chest imaging showed pleural thickening and platythorax, or flattening of the chest with a reduction in the anteroposterior (AP) diameter, was prominent (Figure 1B). His respiratory rate was 52/min with 75% SpO₂. No respiratory infections were identified. Chest computed tomography (CT) showed diffuse infiltrates and bilateral pleural thickening (Figure 1C). His pulmonary vital capacity was 0.56 L (13.3%) of the predicted value. No physical findings, blood tests, or family history suggested the presence of collagen or autoimmune diseases. Non-invasive positive pressure ventilation (PPV) with oxygen was commenced for respiratory failure. He developed severe dyspnea with New York Heart Association (NYHA) class IV heart failure, secondary to pulmonary fibrosis, which gradually worsened.

At 25 years of age, he died of cardiopulmonary failure, five years after the onset of respiratory symptoms. Permission for an autopsy was not obtained. It was assumed that his platythorax, or reduced AP diameter of the chest, might have been secondary to pulmonary hypoplasia with pulmonary fibrosis because the diaphragm in his chest X-ray films had been elevated. He had previously received a moderate dose of cyclophosphamide (cumulative dose, 15.6 g/m²) for the treatment of ALL. Finally, based on the clinical course and exclusion of other diseases, a clinical diagnosis was made of cyclophosphamide-related late-onset pulmonary fibrosis resulting in platythorax, or reduced AP diameter of the chest.

Discussion

Platythorax, or flattening of the chest with a reduction in the anteroposterior (AP) diameter, is rare and the mechanisms involved in the development of this condition remain unknown. Drug-induced pulmonary fibrosis is one of the pulmonary hypoplasia-related disorders associated with acquired platythorax. However, pulmonary fibrosis has many causes, including scleroderma (systemic sclerosis), sarcoidosis, infection, and exposure to drugs, toxins, or radiation, and the most common and most fatal type of idiopathic interstitial pneumonia is idiopathic pulmonary fibrosis (IPF). Cyclophosphamide pulmonary toxicity is a rare cause of pulmonary fibrosis and is usually a diagnosis of exclusion, as blood examinations, bronchoalveolar lavage (BAL), or lung biopsy may not be diagnostic [7].

There have been 15 reported cases, including six children and nine adults, of late-onset pulmonary disease associated with cyclophosphamide therapy, including this case (Table 1) [5,7–13]. In many of these cases, late-onset pulmonary toxicity developed in patients who had received prolonged treatment over several months to years with relatively low doses of cyclophosphamide, and the prognosis was poor [5,7–13]. The interval

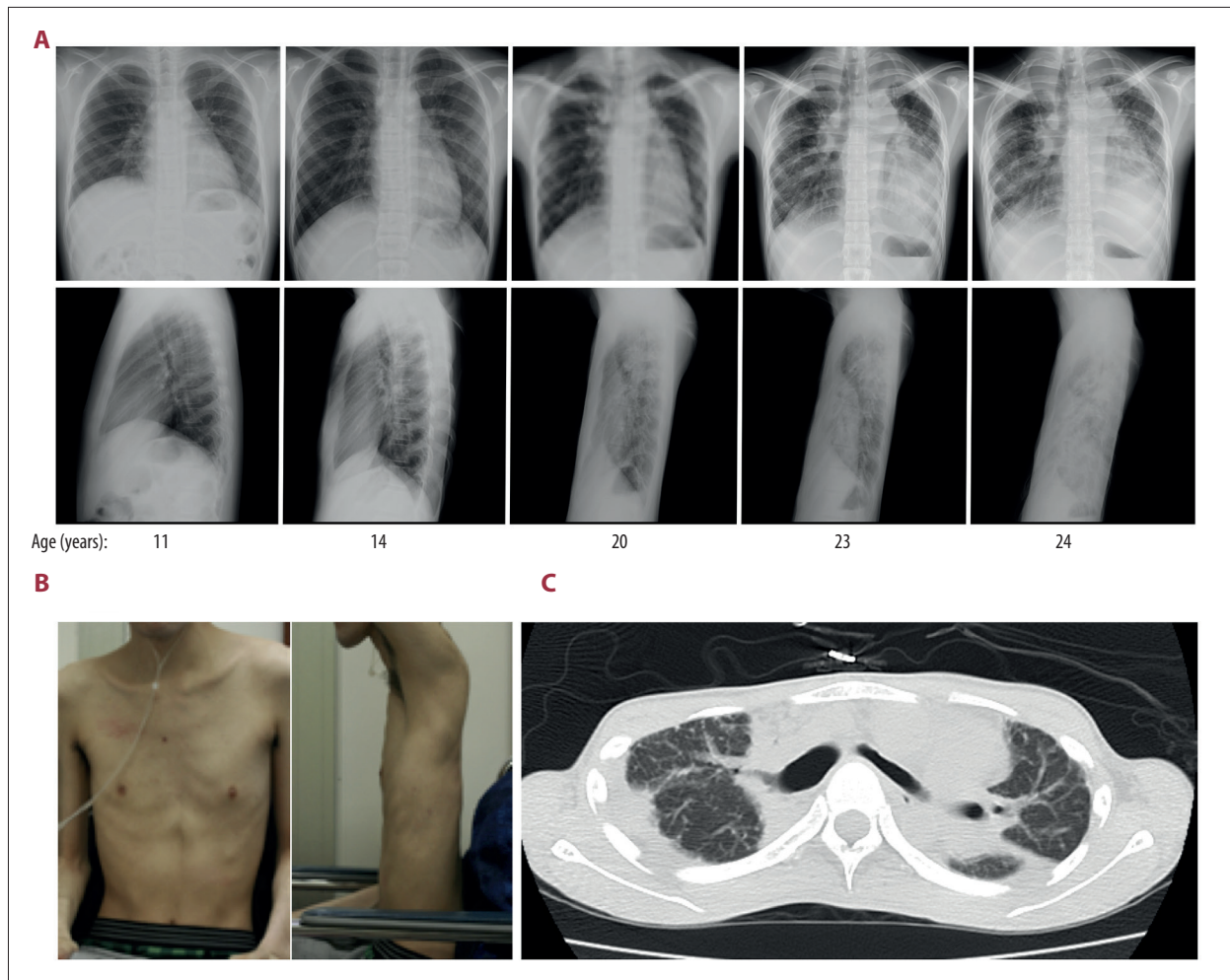


Figure 1. Chest imaging in acquired platythorax, or anteroposterior flattening of the chest wall, as a late complication of cyclophosphamide treatment for acute leukemia in a 23-year-old man who was admitted to hospital with respiratory failure. **(A)** The time course of the chest radiograph appearance in this case. **(B)** The anteroposterior (AP) and lateral view of the chest. **(C)** A chest computed tomography (CT) scan showed pleural thickening, and pulmonary fibrosis distributed in both subpleural regions, and around bronchovascular bundles.

from initiation of cyclophosphamide treatment to the onset of respiratory symptoms varied from 0.4–19 years (median, seven years), and the cumulative dose of cyclophosphamide ranged from 3.4–91 g/m² [5,7–13]. Initial symptoms were nonspecific, including a cough and exertional dyspnea. Pulmonary function tests showed a severe restrictive ventilation defect and chest X-ray showed pleural thickening in most of the cases [5,7–13]. The major pathologic feature was pulmonary fibrosis [5,7–13]. Severe chest deformity developed only in the cases that received chemotherapy in childhood (cases 1 and 4).

Therefore, severe platythorax due to cyclophosphamide-related pulmonary fibrosis may occur predominantly in children. The patient in the present report received a moderate dose of cyclophosphamide intermittently (cumulative dose, 15.6 g/m²). Although the pathogenesis of pulmonary fibrosis due to

cyclophosphamide is poorly understood, there may be genetic differences in local pulmonary drug metabolism that could be risk factors, but these remain to be identified. Among the cytochrome P450 (CYP) superfamily, CYP2B6 is a major enzyme that metabolizes cyclophosphamide and is expressed in lung tissues [14]. However, cyclophosphamide is also a substrate of other CYPs (including CYP2A6, CYP2C19, CYP2C9, and CYP3A4). Because platythorax, or flattening of the chest wall, with pulmonary fibrosis associated with cyclophosphamide treatment is very rare, it is possible to speculate that CYP polymorphism may have a role in the development of this condition.

Currently, there are few available treatments for pulmonary fibrosis and treatment is of limited efficacy. The profibrotic signaling inhibitors, pirfenidone and nintedanib, have been shown to slow the decline in lung function in patients with IPF,

Table 1. High mortality in cyclophosphamide-related late-onset lung disease with platythrax.

Case No.	Associated diseases	Age (yrs)/ Gender at start of cyclophosphamide (CPA) treatment	Age (yrs) at onset of lung disease	Duration and cumulative dose of cyclophosphamide (CPA)	Chest deformity*	Initial symptoms of lung disease	Chest imaging studies	Outcome	Reference No.
1	ALL	3/M	20	1.5 yrs ±2 yrs (15.6 g/m ²)	Severe platythrax (flat chest)	Non-productive cough, exertional dyspnea	Pleural thickening, diffuse infiltrates	Died	This case
2	ALL	3/M	22	12 yrs (35 g/m ²)	n.d.	Exertional dyspnea	Extensive bilateral interstitial infiltrates, pleural thickening, loss of lung volume	Died	11
3	Pylocytic astrocytoma	5/F	13	n.d.	no	n.d.	Pleuroparenchymal fibroelastosis	Deteriorated in two yrs	13
4	ALL	6/F	13	2.5 yrs ×50 mg/day (60 g/m ²)	Extreme platythrax.	Cough, tachypnea, anorexia, weight loss	Prominent interstitial markings, pleural thickening, apical intrapleural accumulation of fluid	Died	5
5	ML	13/F	26	13 yrs ×50–100 mg/day	Extreme platythrax.	Non-productive cough, dyspnea	Hilar and mediastinal lymph node enlargement with interstitial infiltrates extending from both hilae	n.d.	8
6	ALL	14/M	22	(>3.6 g/m ²)	No platythrax (+/-)	n.d.	Pleuroparenchymal fibroelastosis	Deteriorated in nine yrs	13
7	WG	26/F	29	4 yrs (91 g/m ²)	Reduction of AP diameter	Non-productive cough, dyspnea	severe fibrous scarring of the upper lobes, bilateral reticulonodular infiltration and pleural thickening	Stable for six months	10
8	Hodgkin's lymphoma	34/F	37	(3.4 g/m ²)	Platythrax	n.d.	Pleuroparenchymal fibroelastosis.	Died	13
9	Ovarian cancer	40/F	40	1.4 yrs ×100 mg/day (53 g/m ²)	No platythrax	Productive cough, exertional dyspnea, palpitations	Increased linear and reticular changes in the right upper and left upper-middle lung fields, pleural thickening in the left upper lung	Died	9

Table 1 continued. High mortality in cyclophosphamide-related late-onset lung disease with platythrax.

Case No.	Associated diseases	Age (yrs)/ Gender at start of cyclophosphamide (CPA) treatment	Age (yrs) at onset of lung disease	Duration and cumulative dose of cyclophosphamide (CPA)	Chest deformity*	Initial symptoms of lung disease	Chest imaging studies	Outcome	Reference No.
10	WG	42/M	42	2 yrs ×150 mg/day	n.d.	Non-productive cough, progressive dyspnea	Coarse, bilateral reticulo-nodular infiltrates, marked bilateral pleural thickening	Died	7
11	WG	46/F	58	4 yrs	n.d.	Cough, exertional dyspnea	Bilateral nodular infiltrates with associated volume loss and marked bilateral pleural thickening	n.d.	7
12	Breast cancer	50/F	56	2 yrs ×50 mg/day (36 g/m ²)	no	Non-productive cough, exertional dyspnea	Infiltrates predominantly in the upper lung of both lungs, volume loss of the right lung, bilateral pleural thickening	Died	12
13	WG	52/M	65	5 yrs ×100 mg/day	n.d.	Non-productive cough, exertional dyspnea	Bilateral reticular infiltrates in both upper lobes with prominent pleural thickening	Died	7
14	ML	52/M	56	1200 mg ×8 doses (9.6 g/m ²)	n.d.	Non-productive cough, dyspnea.	Bilateral reticulo-nodular infiltrates sparing both costphrenic angles	Died	7
15	Multiple myeloma	73/M	77	4 yrs ×50 mg/day	No	Non-productive cough, exertional dyspnea	Unremarkable	n.d.	7

ALL – acute lymphoblastic leukemia; AP – anteroposterior; CPA – cyclophosphamide; ML – malignant lymphoma; n.d. – not described; T/W – thickness/width ratio on chest radiographs; WG – Wegener’s granulomatosis. * As described in the original papers; Cases that required chest radiation therapy, craniospinal irradiation, and total body irradiation are excluded.

measured by forced vital capacity (FVC) and to reduce all-cause mortality [15,16]. However, the ability of pirfenidone and nintedanib to resolve fibrosis in IPF has not been demonstrated. Reddy et al. reported that depletion of the transcription factor PPAR γ in lung fibroblasts induced a profibrotic phenotype, and that activation of PPAR γ promoted dedifferentiation in lung myofibroblasts in an animal model *in vivo* [17].

The underlying mechanism for the development of platythrax, or flattening of the chest with a reduction in the AP diameter, and the association with pulmonary fibrosis has not been

investigated. It is possible to hypothesize that pulmonary fibrosis that occurs at an early age has an adverse effect on the development of the thorax. The development of the chest wall occurs at the same time as the development of the lungs, including alveolarization with the expansion of the lungs, which continues from childhood to young adulthood [18]. Therefore, chemotherapeutic damage to the lungs may result in interruption of alveolar development and impaired pulmonary function followed by chest deformity in some children. Recently, Beynat-Mouterde et al. reported that platythrax, or flattening of the chest, with pleuroparenchymal fibroelastosis was a late

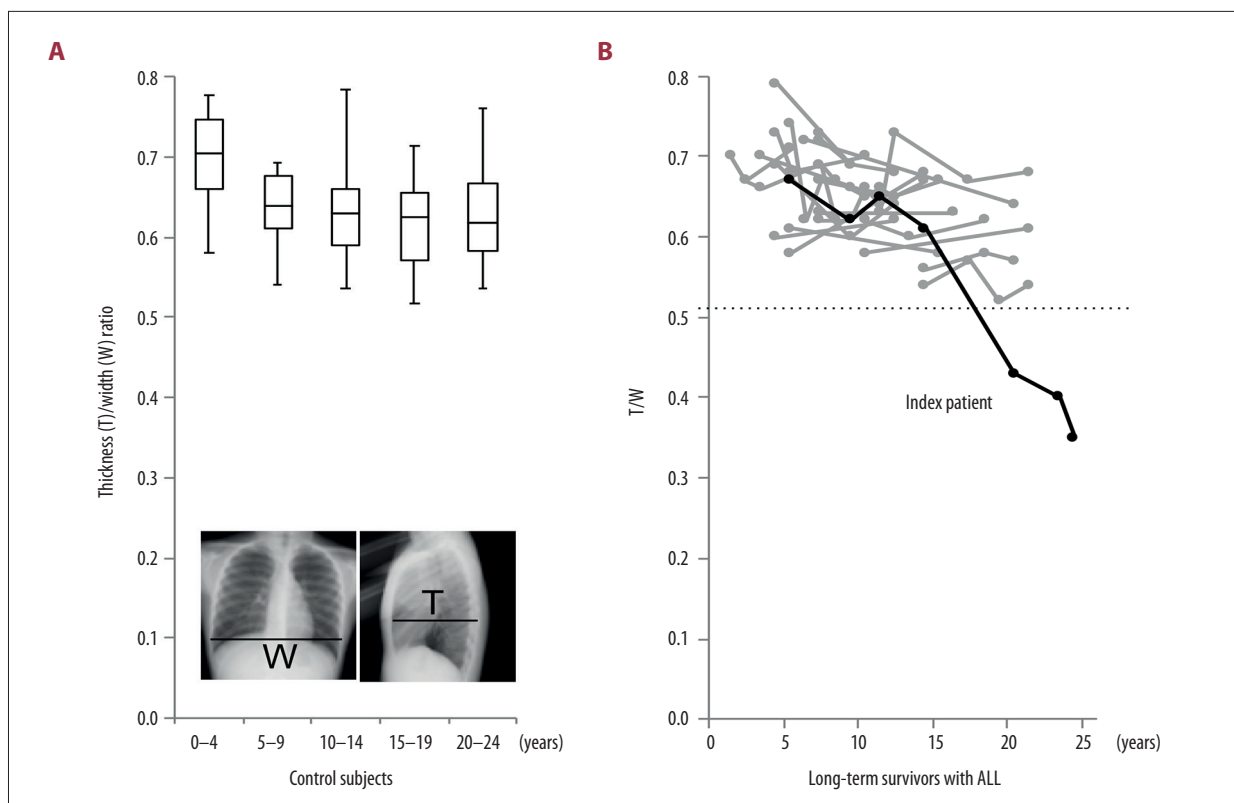


Figure 2. Analysis of thickness (T)/width (W) ratio on chest radiographs in a case of acquired platythrax. **(A)** Box plot analysis of thickness/width ratio on chest radiographs in the control subjects. Box plots of the T (thickness)/W (width) ratio of chest radiographs (inset) are shown in each age group among 10 men and 10 women (from a total of 100 subjects in all age groups among 50 men and 50 women). The central horizontal line in the box plots shows the median quartile, and the top and bottom of each box represent the upper and lower quartile of the values for the sample. The bars extend above and below each box to the maximal and minimal values in the sample. **(B)** Time course of T/W ratio of chest radiographs in 21 long-term survivors with acute lymphoblastic leukemia (ALL). The T/W ratios were within the normal range in 20 long-term survivors (gray lines). This case in this case report developed severe platythrax, or flattening of the chest (black line). A dashed horizontal line indicates a cut-off line for platythrax for the age group of 20–24 years.

complication of treatment with chemotherapy agents, similar to the case in this report [13].

We conducted a retrospective analysis of chest radiographs from two cohorts of children that included control subjects and patients with acute lymphoblastic leukemia (ALL). Control subjects included a total of 100 children and young adults (age range, 0–24 years). These control subjects were admitted to the hospital for various surgical procedures and preoperative chest radiographs were taken. Subjects with congenital anomalies and airway disorders were excluded from this study, and the remaining subjects were subdivided into five groups. Box plots analysis of the T (thickness)/W (width) ratio on chest radiographs were performed for 10 men and 10 women in each age group, which included 0–4 years, 5–9 years, 10–14 years, 15–19 years, and 20–24 years. Platythrax was defined as $T/W < 0.60$ (0.703 ± 0.103 , mean ± 2 SD), 0.55 (0.638 ± 0.086), 0.50 (0.631 ± 0.127), 0.50 (0.614 ± 0.115), 0.51 (0.627 ± 0.119), respectively (Figure 2A). There was no sex variation among all

age groups (men, 0.654 ± 0.128 ; women, 0.632 ± 0.120 , mean ± 2 SD). Among each age group, an inter-patient variation of T/W ratio was seen. Mild, moderate, and severe platythrax were tentatively defined as, $-3 \text{ SD} \leq T/W < -2 \text{ SD}$, $-4 \text{ SD} \leq T/W < -3 \text{ SD}$, and $T/W < -4 \text{ SD}$, respectively.

In the ALL cohort, the T/W ratio in 21 long-term child survivors of ALL, with a median follow-up of eight years after cessation of chemotherapy (range, 2–12 years) was serially plotted. In this case report of a patient with platythrax, the T/W ratio gradually decreased from 0.61 (normal) to 0.43 (moderate), and to 0.35 (severe platythrax) over ten years (Figure 2B). The remaining patients with ALL had normal chest radiographs.

Conclusions

This report described a rare case of acquired platythrax, or flattening of the chest wall, in a young adult. The use of the

ratio of the chest wall AP diameter to lateral diameter (the T/W ratio) may be used in the early detection of this chemotherapy-induced complication in children and adults. This case was also reported to draw attention to this rare but potentially lethal complication of cyclophosphamide treatment.

Acknowledgments

The authors thank Dr. A. A. Fokin (Heekin Institute for Research, Charlotte, NC, USA) and Dr. Sadashige Uemura (Kawasaki Medical School Hospital, Kawasaki, Japan) and Dr. Hiroo Uchida (Nagoya University Hospital, Nagoya, Japan) for advice about chest deformity, and Dr. Shiro Ikegawa (Japanese

Skeletal Dysplasia Consortium, Laboratory for Bone and Joint Diseases, RIKEN Center for Integrative Medical Sciences) for advice about skeletal dysplasia.

Department and Institution where work was done

The Department of Pediatrics, Toyohashi Municipal Hospital, Aichi, Japan.

Conflict of interest

None.

References:

1. Obermeyer RJ, Goretsky MJ: Chest wall deformities in pediatric surgery. *Surg Clin North Am*, 2012; 92: 669–84, ix
2. Fokin AA, Steuerwald NM, Ahrens WA, Allen KE: Anatomical, histologic, and genetic characteristics of congenital chest wall deformities. *Semin Thorac Cardiovasc Surg*, 2009; 21: 44–57
3. Doi T, Harimaya K, Matsumoto Y, Iwamoto Y: Aortic location and flat chest in scoliosis: A prospective study. *Fukuoka Igaku Zasshi*, 2011; 102: 14–19
4. Edwards DK 3rd, Hilton SW: Flat chest in chronic bronchopulmonary dysplasia. *Am J Roentgenol*, 1987; 149: 1213–16
5. Alvarado CS, Boat TF, Newman AJ: Late-onset pulmonary fibrosis and chest deformity in two children treated with cyclophosphamide. *J Pediatr*, 1978; 92: 443–46
6. Frankel SK, Cool CD, Lynch DA, Brown KK: Idiopathic pleuroparenchymal fibroelastosis: description of a novel clinicopathologic entity. *Chest*, 2004; 126: 2007–13
7. Malik SW, Myers JL, DeRemee RA, Specks U: Lung toxicity associated with cyclophosphamide use. Two distinct patterns. *Am J Respir Crit Care Med*, 1996; 154: 1851–56
8. Abdel Karim FW, Ayash RE, Allam C, Salem PA: Pulmonary fibrosis after prolonged treatment with low-dose cyclophosphamide. A case report. *Oncology*, 1983; 40: 174–76
9. Tsukamoto N, Matsukuma K, Matsuyama T et al: Cyclophosphamide-induced interstitial pneumonitis in a patient with ovarian carcinoma. *Gynecol Oncol*, 1984; 17: 41–51
10. Stenoft J: Progressive pulmonary fibrosis complicating cyclophosphamide therapy. *Acta Med Scand*, 1987; 221: 403–7
11. Santamauro JT, Stover DE, Jules-Elysee K, Maurer JR: Lung transplantation for chemotherapy-induced pulmonary fibrosis. *Chest*, 1994; 105: 310–12
12. Hamada K, Nagai S, Kitaichi M et al: Cyclophosphamide-induced late-onset lung disease. *Intern Med*, 2003; 42: 82–87
13. Beynat-Mouterde C, Beltramo G, Lezmi G et al: Pleuroparenchymal fibroelastosis as a late complication of chemotherapy agents. *Eur Respir J*, 2014; 44: 523–27
14. Leclerc J, Tournel G, Courcot-Ngoubo Ngangue E et al: Profiling gene expression of whole cytochrome P450 superfamily in human bronchial and peripheral lung tissues: Differential expression in non-small cell lung cancers. *Biochimie*, 2010; 92: 292–306
15. Karimi-Shah BA, Chowdhury BA: Forced vital capacity in idiopathic pulmonary fibrosis – FDA review of pirfenidone and nintedanib. *N Engl J Med*, 2015; 372: 1189–191
16. Lederer DJ, Martinez FJ: Idiopathic pulmonary fibrosis. *N Engl J Med*, 2018; 378: 1811–23
17. Reddy AT, Lakshmi SP, Zhang Y, Reddy RC: Nitrated fatty acids reverse pulmonary fibrosis by dedifferentiating myofibroblasts and promoting collagen uptake by alveolar macrophages. *FASEB J*, 2014; 28: 5299–310
18. Burri PH: Structural aspects of postnatal lung development – alveolar formation and growth. *Biol Neonate*, 2006; 89: 313–22