

Suture clamping of intraocular lenses without a scleral flap: A new implantation method for patients with an aphakic capsule

Yan-Ming Tian, Jun-Jun Li, Wen Gao

We aim to describe a technique for intraocular lens (IOL) implantation with suture clamping for aphakic capsules. This prospective, noncomparative, interventional case study included three eyes of three patients with an aphakic capsule after vitrectomy, in which the IOL was clamped by suturing. The suturing procedure was transconjunctival or subconjunctival performed without scleral flaps. The IOLs were implanted without difficulty, and visual acuity improved after IOL implantation. There were no severe complications, and the position of each IOL remained correct through 18 months of follow-up. The present technique is straightforward and effective in the treatment of eyes with an aphakic capsule.

Key words: Aphakia, implantation, intraocular lens, retention suture

Video Available on:
www.ijo.in

Access this article online

Website:
www.ijo.in

DOI:
10.4103/ijo.IJO_689_21

Quick Response Code:



The treatment methods for aphakic patients reported in the literature mainly include interlayer fixation of intraocular lens (IOL) haptic and IOL scleral suture fixation. The former does not require sutures, but this method is challenging to operate and requires a doctor's rich experience. In 1986, Malbran *et al.*^[1] introduced lens suture fixation, a surgical technique that has undergone many improvements over the years. However, most suture fixation procedures require the preparation of a scleral flap, the suture ligation of the IOL haptic, and the burying of the suture under the scleral flap. In 2010, Dr. Zhang Zongduan^[2] of Wenzhou Medical College improved this surgical procedure. In the new method, the sutures are placed first between the scleral flap and the incision, and then the IOL is injected with an IOL bolus device. This surgical method reduces intraocular pressure fluctuations caused by a large amount of fluid flowing when the IOL is implanted and reduces the risk of eyeball collapse and expulsive choroidal hemorrhage. These surgical methods are effective, but the surgeon must be experienced. When the suture method is used to inject leading haptic of the IOL, and the haptic is stitched, the assistant needs to provide good support, which requires training. In response to the above problems, our department has devised a more uncomplicated IOL implantation technique for clinical practice, which is suitable for patients with aphakia after a vitrectomy. The method is as follows.

Eye Center, General Hospital of Chinese PLA, Urumchi, Xinjiang Uygur Autonomous Region, China

Correspondence to: Dr. Yan-ming Tian, Department of Ophthalmology, General Hospital of Chinese PLA, Urumchi 830011, Xinjiang Uygur Autonomous Region, China. E-mail: tianyanming@163.com

Received: 11-Apr-2021

Revision: 13-Jun-2021

Accepted: 07-Jul-2021

Published: 26-Nov-2021

Surgical Technique

All of the operations were performed under retrobulbar anesthesia. Straight needles with 10-0 polypropylene were used in this technique (PC-9 suture; Alcon Surgical). Place the perfusion; sectoral conjunctival peritomy was performed before inserting the needle at 1, 2, 4, 5, 7, 8, and 11 o'clock of the right eye. The long needle of the IOL fixation suture was inserted 2 mm posterior to the limbus on the side of the globe at 11 o'clock, parallel to the iris, and retrieved on the opposite side at 7 o'clock, within the bore of a 27-gauge needle that was attached to a 1 ml syringe. The guided long needle was inserted into the conjunctival incision at 7 o'clock and closely attached to the sclera under the conjunctiva and then led out through the 8 o'clock conjunctival incision. Then, the long needle was punctured into the eye from the scleral surface, 2 mm behind the limbus at 8 o'clock, and led out from the 4 o'clock position. In the same way, the direction of the arrows provided in Fig. 1 were followed to complete the IOL septum suture. Finally, the long needle was drawn out from the 10 o'clock position, entered through the 10 o'clock conjunctival incision, and then drawn out from the 11 o'clock conjunctival incision. When threading, it is important to ensure that the A and B threads go behind the C and D threads. After each

This is an open access journal, and articles are distributed under the terms of the Creative Commons Attribution-NonCommercial-ShareAlike 4.0 License, which allows others to remix, tweak, and build upon the work non-commercially, as long as appropriate credit is given and the new creations are licensed under the identical terms.

For reprints contact: WKHLRPMedknow_reprints@wolterskluwer.com

Cite this article as: Tian YM, Li JJ, Gao W. Suture clamping of intraocular lenses without a scleral flap: A new implantation method for patients with an aphakic capsule. Indian J Ophthalmol 2021;69:3745-7.

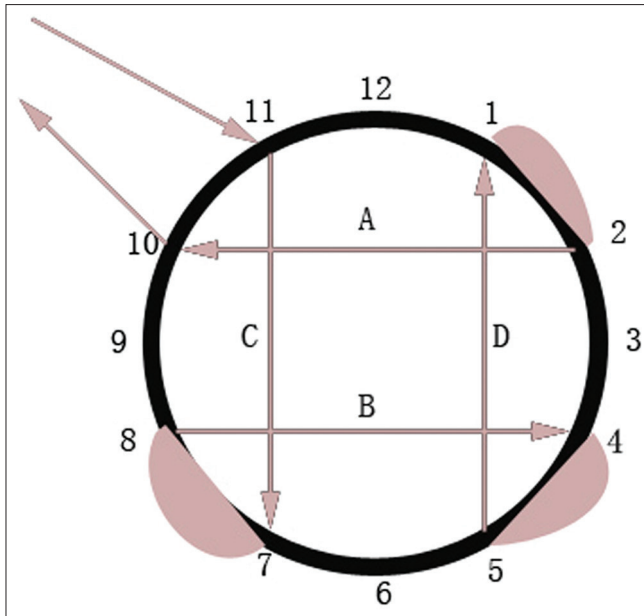


Figure 1: Schematic representation of the procedure for suturing

puncture, we carefully tightened the sutures and kept the tension of the sutures in the eye [Fig. 1].

Folding IOL was implanted from a transparent corneal incision. Then an auxiliary incision at 1 o'clock point of the limbus was made; the intraocular forceps were used with the left hand to help hold the IOL, the right hand was used to enter the adjustment hook through the main incision, and the IOL optics between the upper and lower sutures in the central area were adjusted and clamped [Figs. 2 and 3].

Next, the 11 o'clock suture slipknot was opened, the suture was tightened again to keep the suture in the eye under proper tension, after the IOL is centered, to use two adjustment hooks to adjust the edge of the optical zone between the two pairs of sutures. Last step, the 11 o'clock suture is knotted (E and F are knotted). It is also possible to use a 1-point curved needle to pass through the scleral surface three times in a Z-shape and then pass the lamellar layer of the long needle through the sclera at 1 point and ligate. The knot is buried under the conjunctiva at the incision, and the conjunctival incision does not need to be sutured. Operations on the left eye were performed the same way, at the corresponding clock points [Supplemental Digital Content 1. mp4].

Results

This type of operation was completed on one eye of each of three patients. One patient had a macular hole and retinal detachment; he underwent a vitrectomy. The silicone oil was removed 3 months later, and a cataract developed after 6 months. During phacoemulsification, the posterior lens capsule was torn, so no IOL was implanted. After implantation of an IOL, using the suture clamping technique, the patient's visual acuity, which was 0.02 preoperatively, improved to 0.1. Of the other two patients, one had a traumatic lens dislocation after vitrectomy and one had an IOL dislocation. The preoperative visual acuity for those two eyes was hand motion, and the visual acuities after IOL implantation were 0.2

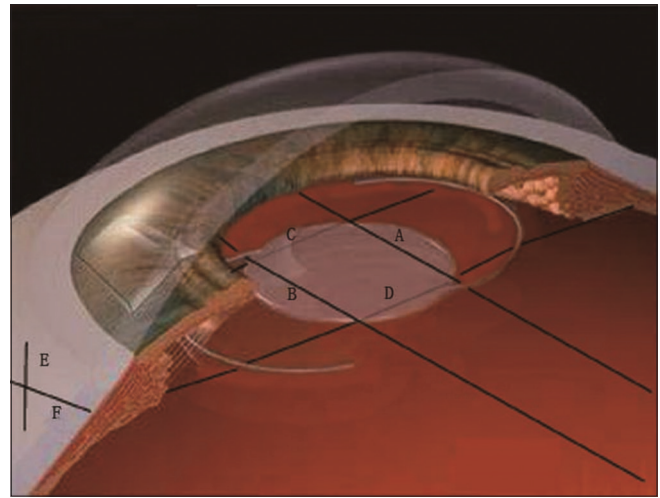


Figure 2: Schematic representation of the intraocular lens clamping. The sutures are adjusted, ensuring that sutures A and B are in front of the optical part of the intraocular lens, and sutures C and D are located behind the optical part of the intraocular lens

and 0.3, respectively. The three patients underwent 18 months of follow-up; at the end of that, the position of each IOL was correct.

One patient had occasional eye soreness when he lowered his head and often had symptoms of dry eye. The symptoms, considered to be related to his multiple operations, were relieved with hot compresses and artificial tears. The other two patients had no other symptoms. If the ciliary body is accidentally injured, it causes ciliary body bleeding; however, the bleeding will be absorbed without treatment within 3 days after the operation. Owing to the presence of conjunctival incisions, patients will experience the sensation of foreign bodies in the short term. If the suture position is too far forward, it will cause iris depigmentation and temporary elevation of intraocular pressure. However, the intraocular pressure will return to normal after intraocular pressure reduction treatment.

Discussion

Some scholars have used intraocular sutures to block the influx of silicone oil into the anterior chamber in aphakic eyes with iris defects. The suture placement does not cause a significant risk of complications.^[3,4] Inspired by that method, we developed our method of holding the IOL with the sutures inside the eye. This surgical technique is especially suitable for aphakia after vitrectomy surgery. With the process of puncturing, the contents of the eye remain enclosed. Only when the IOL is injected there is a small amount of intraocular fluid outflow, which maintains the stable intraocular pressure, avoiding the risk of eyeball collapse and explosive choroidal hemorrhage caused by severe fluctuations in intraocular pressure. In addition, as the surgical technique is mainly a long-needle puncture process, there is no need to make a scleral flap; the operation is simple, with virtually no learning curve, and it is easy to promote the technique's application widely in primary district hospitals. As there is no need to suture the IOL, no assistant is needed when injecting it. This operation is suitable for three-piece IOLs. First, the two haptic of this IOL are long enough to be fixed in the ciliary sulcus; second, the suture is

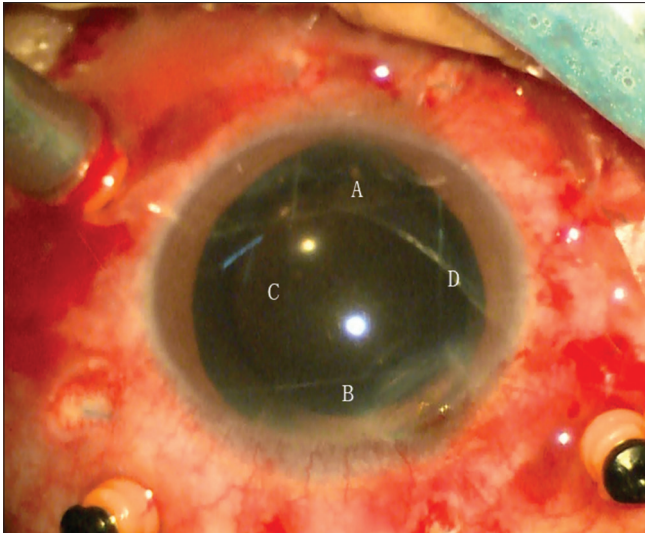


Figure 3: The suturing is complete, and the intraocular lens has been implanted. The black arrow indicates the conjunctival peritomy

clamped to the edge of the optical zone. These two factors keep the IOL stable and centered.

As sutures are passing through the pupillary area in the eye during the operation, some surgeons may worry about affecting the vision of the patient; however, after the examination, the patient will have no apparent sense of visual obscuration. There are two possible reasons for this: the light is transmitted in a fluctuating state, and the suture is very thin, so the suture has little effect on the passage of light; the other is that patients after vitrectomy do not have normal visual sensitivity. This technology requires no suturing of the IOL, no scleral flap, and no need to clamp the suture during the entire operation repeatedly, so the possible complications, such as suture breakage, are significantly reduced. In addition, the surgical suture runs smoothly under the conjunctiva, avoiding postoperative foreign body sensation. It is necessary during the operation to pay attention to the accuracy of the needle insertion

positions to prevent the suture grid and the clamped IOL from being eccentric. A live knot should be made to maintain the suture tension after the suture is completed, and then the suture should be tightened after the adjustment of the IOL is complete. Otherwise, because of intraocular pressure fluctuations, it is easy for the sutures to loosen. Finally, this operation can also be applied to the fixation of a dislocated IOL.

As this is a new surgical method, we only selected three patients for the operation. At present, we have followed those patients for 24 months without any particular complications. Questions that remain about the long-term surgical effect of this operation, whether the position of IOL will change and whether there is any interaction between the IOL and the suture still need long-term study.

Conclusion

The described technique of suture clamping of IOLs without a scleral flap is a straightforward and an effective in the management of eyes with an aphakic capsule.

Financial support and sponsorship

Nil.

Conflicts of interest

There are no conflicts of interest.

References

1. Malbran ES, Malbran E Jr, Negri I. Lens guide suture for transport and fixation in secondary IOL implantation after intracapsular extraction. *Int Ophthalmol* 1986;9:151-60.
2. Zhang ZD, Shen LJ, Liu XQ, Chen YQ, Qu J. Injection and suturing technique for scleral fixation foldable lens in the vitrectomized eye. *Retina* 2010;30:353-6.
3. Gentile RC, Elliott D. Silicone oil retention sutures in aphakic eyes with iris loss. *Arch Ophthalmol* 2010;128:1596-9.
4. Yüksel K, Pekel G, Alagöz N, Alagöz C, Baz Ö, Yazc AT. Silicone oil barrier sutures in aphakic eyes with iris defects. *Retina* 2016;36:1222-6.