





## ORIGINAL STUDIES

# Comparison of 6-month vascular healing response after bioresorbable polymer versus durable polymer drug-eluting stent implantation in patients with acute coronary syndromes: A randomized serial optical coherence tomography study

Masahiko Noguchi MD<sup>1,2,3</sup>  | Tomotaka Dohi MD, PhD<sup>1</sup>  | Shinya Okazaki MD<sup>1</sup> | Mitsuaki Matsumura BS<sup>2</sup>  | Mitsuhiro Takeuchi MD<sup>1</sup> | Hirohisa Endo MD, PhD<sup>1</sup> | Yoshiteru Kato MD<sup>1</sup> | Iwao Okai MD<sup>1</sup> | Hiroki Nishiyama MD<sup>1</sup> | Shinichiro Doi MD, PhD<sup>1</sup> | Hiroshi Iwata MD, PhD<sup>1</sup> | Kikuo Isoda MD, PhD<sup>1</sup> | Eisuke Usui MD, PhD<sup>2,3</sup> | Tatsuhiro Fujimura MD, PhD<sup>2,3</sup> | Fumiyasu Seike MD, PhD<sup>2,3</sup> | Gary S. Mintz MD<sup>2</sup> | Katsumi Miyauchi MD<sup>1</sup> | Hiroyuki Daida MD<sup>1</sup> | Tohru Minamino MD, PhD<sup>1,4</sup> | Akiko Maehara MD<sup>2,3</sup> 

<sup>1</sup>Department of Cardiovascular Biology and Medicine, Juntendo University Graduate School of Medicine, Tokyo, Japan

<sup>2</sup>Clinical Trials Center, Cardiovascular Research Foundation, New York, New York, USA

<sup>3</sup>Division of Cardiology, Center for Interventional Vascular Therapy, NewYork-Presbyterian Hospital/Columbia University Irving Medical Center, New York, New York, USA

<sup>4</sup>Japan Agency for Medical Research and Development-Core Research for Evolutionary Medical Science and Technology (AMED-CREST), Japan Agency for Medical Research and Development, Tokyo, Japan

## Correspondence

Tomotaka Dohi, Department of Cardiovascular Biology and Medicine, Juntendo University Graduate School of Medicine, 2-1-1, Hongo, Bunkyo-ku, Tokyo 113-0033, Japan.  
Email: tdohi@juntendo.ac.jp

## Funding information

Boston Scientific Japan

## Abstract

**Objectives:** This study was conducted to use optical coherence tomography (OCT) to compare vascular healing between bioresorbable polymer (BP) and durable polymer (DP) everolimus-eluting stents (EES) in patients with acute coronary syndromes (ACS).

**Background:** Whether BP-EES induce better vascular healing compared to contemporary DP-EES remains controversial, especially for ACS.

**Methods:** In this prospective, randomized, non-inferiority trial, we used OCT to compare 6-month vascular healing in patients with ACS randomized to BP versus DP-EES: percent strut coverage (primary endpoint, non-inferiority margin of 2.0%) and neointimal thickness and percent neointimal hyperplasia (NIH) volume. As an exploratory analysis, morphological factors related to the endpoints and the effect of underlying lipidic plaque on stent healing were evaluated.

**Results:** A total of 104 patients with ACS were randomly assigned to BP-EES (n = 52) versus DP-EES (n = 52). Of these, 86 patients (40 BP-EES and 46 DP-EES) were included in the final OCT analyses. Six-month percent strut coverage of BP-EES (83.6 ± 11.4%) was not non-inferior compared to those of DP-EES (81.6 ± 13.9%), difference 2.0% (lower 95% confidence interval-2.6%),  $p_{\text{non-inferiority}} = 0.07$ . There were no differences in neointimal thickness 70.0 ± 33.9 μm versus 67.2 ± 33.9 μm,  $p = 0.71$ ; and percent NIH volume 7.5 ± 4.7% versus 7.3 ± 5.3%,  $p = 0.85$ . By multivariable linear regression analysis, stent type was not associated

with percent strut coverage or percent NIH volume; however, percent baseline embedded struts or stent expansion was positively associated with percent NIH volume. Greater NIH volume was observed in lipidic compared with non-lipidic segments ( $8.7 \pm 5.6\%$  vs.  $6.1 \pm 5.2\%$ ,  $p = 0.005$ ).

**Conclusions:** Six-month strut coverage of BP-EES was not non-inferior compared to those of DP-EES in ACS patients. Good stent apposition and expansion were independently associated with better vascular healing.

#### KEYWORDS

acute coronary syndrome, bioresorbable polymer, durable polymer, everolimus-eluting stents, optical coherence tomography

## 1 | INTRODUCTION

First-generation drug-eluting stents (DES) dramatically reduced restenosis compared with bare metal stents (BMS); however, very late stent thrombosis (VLST) has emerged as an important concern.<sup>1</sup> Histopathological studies have confirmed that delayed arterial healing, lack of endothelialization characterized by uncovered stent struts, as well as inflammatory response and hypersensitivity reaction to the durable polymer (DP) were all associated with VLST.<sup>2,3</sup> Several studies using optical coherence tomography (OCT) have observed a higher rate of uncovered stent struts and malapposed struts in patients at the time of VLST.<sup>4–7</sup> Over the last decade, DES technology has improved and modified to have thinner metallic struts and more biocompatible DP (second-generation DES). Strut thickness is one of the key features of vascular healing. In vivo and ex vivo experimental studies have shown that thinner struts induced less flow disturbance and less thrombogenicity compared to thicker struts.<sup>8</sup> In fact, a human pathological study confirmed that second-generation DES, such as everolimus-eluting stents (EES), demonstrated greater strut coverage with less inflammation, equivalent to BMS and superior to first-generation DES.<sup>9</sup> Recently, bioresorbable polymers (BP) have been introduced based on the assumption that any DP is potentially harmful; however, it is unclear whether new-generation DES with BP is effective with respect to vascular healing compared to contemporary second-generation DES with DP. Moreover, strut coverage after implantation can be affected by underlying plaque morphology, especially lipid-rich plaque in patients with acute coronary syndromes (ACS).<sup>10,11</sup> On this background, we used OCT to compare mid-term (6-month) vascular healing responses between new-generation DES (BP-EES) and second-generation DES (DP-EES) in patients presenting with ACS.

## 2 | MATERIALS AND METHODS

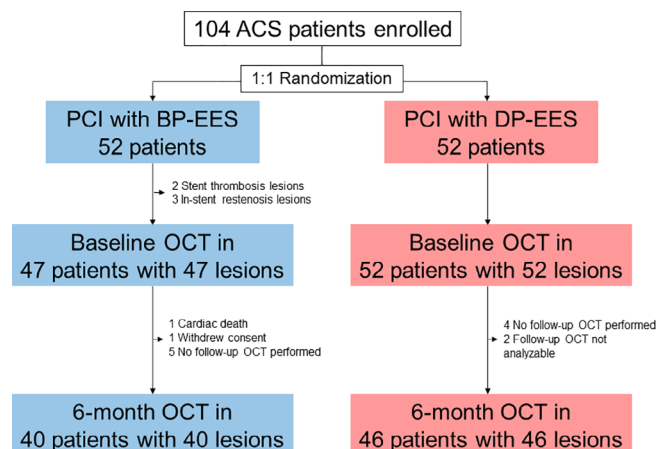
### 2.1 | Study design

The comparison of the healing response of bioresorbable polymer versus durable polymer DES in patients with acute coronary

syndrome (HR-ACS) study is a prospective, single-center (Juntendo University Hospital, Tokyo, Japan), single-blind, active-treatment-controlled, non-inferiority randomized trial comparing stent healing at 6 months between BP-EES versus DP-EES. This trial is registered with the University Hospital Medical Information Network (UMIN000028967). We prospectively screened patients with ACS undergoing percutaneous coronary intervention (PCI) for de novo native coronary artery lesions responsible for ACS. ACS was diagnosed based on clinical symptoms, electrocardiographic changes compatible with acute myocardial ischemia, and elevation of cardiac biomarkers. Patients with evidence of ACS including ST-segment elevation myocardial infarction (STEMI), non-STEMI, and unstable angina were eligible for inclusion. Exclusion criteria were cardiogenic shock, acute decompensated heart failure, indications for coronary artery bypass graft surgery, target lesion within a coronary bypass graft, or need for non-cardiac surgery within 6 months. Eligible patients were randomly assigned 1:1 to BP-EES (Synergy, 74  $\mu\text{m}$  strut thickness; Boston Scientific Corporation, Marlborough, MA) versus DP-EES (XIENCE Alpine, 81  $\mu\text{m}$  strut thickness; Abbott Vascular, Santa Clara, CA) using a web-based randomization system after restoration of TIMI 3 flow, but before stent implantation during primary PCI. Primary PCI was performed using standard techniques and intravascular ultrasound (IVUS)-guidance by experienced interventional cardiologists. OCT was performed at the end of the PCI procedure and at 6-month ( $\pm 30$  days) follow-up. Information from intravascular imaging either at baseline or follow-up was not blinded to the operators. Patient clinical follow-up data was prospectively collected by hospital visits until 6 months. The institutional review board approved this study protocol, and written informed consent was obtained from all patients before the index procedure.

### 2.2 | Study endpoints and sample size

The primary endpoint was percent strut coverage at 6 months measured by OCT. Secondary endpoints includes thickness of neointimal hyperplasia (NIH) and percent NIH volume. As an exploratory



**FIGURE 1** Study flow chart. ACS, acute coronary syndromes; BP-EES, bioresorbable polymer everolimus-eluting stent; DP-EES, durable polymer everolimus-eluting stent; OCT, optical coherence tomography

analysis, morphological factors (underlying lipidic plaque behind stent and stent expansion indices) potentially related to the primary and secondary endpoints were evaluated. Absorption of the polymer (poly-lactide-co-glycolide) of BP-EES has been reported to be nearly completed by 4 months in normal coronary arteries in a swine model.<sup>12</sup> In consideration of variations in healing in atherosclerotic coronary arteries among different patients, we set the follow-up OCT at 6 months.

Although BP-EES is expected to have superior strut coverage compared to DP-EES, previous data showed excellent strut coverage of DP-EES. In a meta-analysis including stable patients, the weighted average of percent strut uncoverage of DP-EES in 498 lesions from 7 studies was 3.3% at 6 months.<sup>13</sup> Thus, we thought that the most realistic hypothesis was that the strut coverage of BP-EES would be non-inferior compared with that of DP-EES at 6 months after stent implantation in ACS patients; and the 2.0% non-inferiority margin was based on prior observations. Ino et al. reported that DP-EES

**TABLE 1** Baseline clinical characteristics

	BP-EES (n = 52)	DP-EES (n = 52)	p-value
Age, years	64.3 ± 12.3	69.1 ± 11.7	0.046
Male sex	41 (78.8)	41 (78.8)	0.99
Body mass index, kg/m <sup>2</sup>	24.4 ± 4.3	24.8 ± 4.5	0.70
Hypertension	32 (61.5)	37 (71.2)	0.30
Dyslipidemia	42 (80.8)	37 (71.2)	0.25
Diabetes mellitus	20 (38.5)	16 (30.8)	0.41
Insulin-treated	5 (9.6)	4 (7.7)	0.99
Current smoker	17 (32.7)	14 (26.9)	0.52
Chronic kidney disease <sup>a</sup>	8 (15.4)	10 (19.2)	0.60
Prior percutaneous coronary intervention	10 (19.2)	9 (17.3)	0.80
Prior myocardial infarction	4 (7.7)	6 (11.5)	0.51
Prior coronary bypass grafting	1 (1.9)	1 (1.9)	0.99
Clinical presentation			0.30
ST-segment elevation myocardial infarction	26 (50.0)	25 (48.1)	
Non-ST-segment elevation myocardial infarction	12 (23.1)	7 (13.5)	
Unstable angina	14 (26.9)	20 (38.5)	
Lipid profile at admission			
Low-density lipoprotein, mg/dl	126.4 ± 38.4	114.3 ± 33.8	0.09
High-density lipoprotein, mg/dl	46.7 ± 11.2	49.0 ± 10.7	0.29
Triglycerides, mg/dl	147.0 ± 80.9	129.6 ± 81.7	0.28
Statin at admission	20 (38.5)	22 (42.3)	0.69
DAPT at discharge	51/51 (100)	52/52 (100)	0.99
DAPT at 6 months	41/47 (87.2)	37/49 (75.5)	0.14

Note: Values are n (%) or mean ± SD.

Abbreviations: BP-EES, bioresorbable polymer everolimus-eluting stent; DAPT, dual antiplatelet therapy; DP-EES, durable polymer everolimus-eluting stent.

<sup>a</sup>Estimated glomerular filtration rate ≤ 60 ml/min/1.73m<sup>2</sup> using the modification of diet in renal disease formula.

had similar percent strut uncoverage compared with bare metal stent ( $2.1 \pm 2.8\%$  vs.  $1.7 \pm 2.7\%$ ) as assessed by OCT at 10 months after stent implantation in STEMI patients.<sup>14</sup> Won et al. reported that the association between the percent strut uncoverage and subsequent definite stent thrombosis or cardiac death in 489 patients who underwent 6–18 months follow-up OCT was  $14.4 \pm 10.8\%$  in 6 patients with events (4 patients suffered definite stent thrombosis and 2 patients died due to cardiac cause) versus  $6.8 \pm 11.6\%$  in 483 patients without events.<sup>15</sup> Chieffo et al. reported that the median percent strut uncoverage of DP-EES in 29 ACS patients (24% of STEMI) at 6-months was 6.4% (first quartile, third quartile: 3.27, 9.57).<sup>16</sup> Thus, 6.4% strut uncoverage of DP-EES (control) and 8.4% strut uncoverage of BP-EES (i.e., 2.0% of non-inferiority margin) seemed to be clinically acceptable. A total of 88 patients were required assuming a SD of 2.8% (based on the data by Ino et al.), a non-inferiority margin of 2.0%, 1-sided alpha risk of 5%, and 80% power. To account for loss of non-qualified OCT images and clinical

follow-up attrition, a 20% failure rate was estimated. Thus, a total of 110 patients was required.

## 2.3 | Angiographic and OCT imaging and analysis

The ILUMIEN OPTIS imaging system with Dragonfly DUO Imaging Catheter (Abbott Vascular) was used. The OCT catheter was introduced distal to the lesion, and contrast was injected via the guiding catheter at a rate of 4–5 ml/s during motorized pullback (at 0.2 mm of frame interval) during imagine acquisition.

Angiograms and OCT images were analyzed at an independent core laboratory (Cardiovascular Research Foundation, New York, NY) without knowledge of randomized allocation or clinical information. Quantitative coronary angiography (QCA) analysis including lesion length, reference vessel diameter, minimum lumen diameter, and diameter stenosis was performed pre-PCI, post-PCI, and at 6-month

	BP-EES (n = 52)	DP-EES (n = 52)	p-value
Target vessel, LAD/LCX/RCA	30/4/18	30/11/11	0.08
Proximal lesion location	20 (38.5)	17 (32.7)	0.54
ACC/AHA classification B <sub>2</sub> /C lesion	34 (65.4)	36 (69.2)	0.68
Calcification moderate/severe	10 (19.2)	13 (25.0)	0.48
Thrombus	13 (25.0)	13 (25.0)	0.99
Pre-PCI TIMI flow 0/1	18 (34.6)	13 (25.0)	0.28
Post-PCI TIMI flow 3	49 (94.2)	50 (96.2)	1.00
Lesion length, mm	17.0 ± 9.4	17.3 ± 11.4	0.90
Reference vessel diameter, mm	2.69 ± 0.64	2.77 ± 0.67	0.54
Number of stents per lesion	1.1 ± 0.3	1.1 ± 0.3	0.76
Total stent length, mm	24.8 ± 9.5	25.2 ± 13.0	0.85
Maximum stent diameter, mm	3.0 ± 0.5	2.9 ± 0.5	0.21
Post-dilatation performed	46 (88.5)	51 (98.1)	0.11
Post-dilatation maximum pressure, atm	18.7 ± 3.4	18.2 ± 3.5	0.47
Minimum lumen diameter, mm			
Pre-PCI	0.54 ± 0.39	0.51 ± 0.38	0.65
Post-PCI, in-stent	2.50 ± 0.48	2.46 ± 0.46	0.59
Acute gain, in-stent	1.96 ± 0.52	1.94 ± 0.50	0.87
6-month follow-up, in-stent	2.61 ± 0.57	2.46 ± 0.54	0.19
Late loss, in-stent	−0.09 ± 0.41	−0.03 ± 0.42	0.48
Diameter stenosis, %			
Pre-PCI	80.6 ± 12.8	82.0 ± 13.5	0.60
Post-PCI, in-stent	14.8 ± 6.3	14.4 ± 7.2	0.72
6-month follow-up, in-stent	15.2 ± 7.5	15.4 ± 7.5	0.90
Binary restenosis, in-stent <sup>a</sup>	2/47 (4.3)	0/49 (0.0)	0.24

Note: Values are n (%) or mean ± SD.

Abbreviations: ACC, American College of Cardiology; AHA, American Heart Association; BP-EES, bioresorbable polymer everolimus-eluting stent; DP-EES, durable polymer everolimus-eluting stent; LAD, left anterior descending artery; LCX, left circumflex artery; PCI, percutaneous coronary intervention; RCA, right coronary artery; TIMI, thrombolysis in myocardial infarction.

<sup>a</sup>≥50% luminal narrowing in-stent at follow-up angiography.

**TABLE 2** Angiographic and procedural findings

follow-up using QAngio XA 7.3 (Medis Medical Imaging Systems, Leiden, the Netherlands).<sup>17</sup>

Baseline OCT images were analyzed first, and the follow-up OCT was matched for each analyzed frame using fiducial landmarks and off-line proprietary software (Abbott Vascular). At baseline, each strut was categorized as either apposed, embedded, tissue protruded, malapposed, or located at a side branch orifice (Figure S1). At follow-up, a strut was considered to be covered if there was smooth continuous tissue on the strut surface and on both sides of the strut (Figure S2).<sup>18</sup> Percent strut coverage was defined as total number of covered struts divided by the total number of analyzed struts. Lumen, stent, and NIH (stent minus lumen) area and diameter and neointimal thickness (distance between the center of strut blooming and the lumen surface) were analyzed every 1 mm. Percent NIH volume (NIH/stent volume) per lesion was calculated. For stent expansion, we adopted the new method defined by Huo-Kassab (H-K) in addition to conventional definitions. The H-K model defined stent expansion by considering vessel tapering due to side branches.<sup>19,20</sup> Further details are provided in the Supplement S1.

## 2.4 | Statistical analysis

All analyses were performed in the intention-to-treat population. Continuous variables were reported as mean  $\pm$  SD or median (first quartile, third quartile) and compared with the Student *t* test for normally distributed data or the Wilcoxon rank-sum test for non-normally distributed data between two randomized groups. Categorical variables were described as frequency and compared using the  $\chi^2$  test between two randomized groups. For comparison of NIH thickness (strut level), continuous variables were compared using generalized estimating

equations to account for the clustering effect within each lesion. Multivariable linear regression analysis was performed to determine the factors associated with vascular healing including all lesions with stent type as a covariate. A *p*-value  $<$  0.05 was considered a significant. All statistical analyses were performed with SAS version 9.4 (SAS Institute, Cary, NC).

## 3 | RESULTS

### 3.1 | Study population and baseline clinical characteristics

Between August 2016 and August 2018 (pre-specified enrollment period), a total of 104 patients were randomly assigned to BP-EES or DP-EES. After exclusion of non-qualified OCT images or missing follow-up OCT images, a total of 86 lesions in 86 patients were included in the primary endpoint analysis (40 BP-EES vs. 46 DP-EES) (Figure 1). Follow-up OCT was performed at  $188 \pm 9$  days with no difference between the groups. Baseline clinical characteristics have been given in Table 1. There were no significant differences between groups except for patient age. In addition, there were no differences in baseline lesion, procedural, or QCA details (Table 2).

### 3.2 | OCT findings

As given in Table 3, at baseline there were no significant differences between groups in stent expansion indices. Almost all patients (91.6%) had lipid behind the implanted stent. At baseline, percent embedded struts was higher (20.8% vs. 13.5%) and percent apposed

**TABLE 3** Optical coherence tomography entire stent segment findings

	BP-EES	DP-EES	<i>p</i> -value
Baseline post-PCI	38 lesions	45 lesions	
Minimum stent area, mm <sup>2</sup>	6.46 $\pm$ 2.53	5.82 $\pm$ 2.19	0.22
Mean stent area, mm <sup>2</sup>	8.04 $\pm$ 2.68	7.50 $\pm$ 2.32	0.32
Conventional stent expansion, %	77.5 $\pm$ 14.1	71.8 $\pm$ 12.9	0.06
Minimum H-K stent expansion, %	81.2 $\pm$ 14.0	74.9 $\pm$ 12.5	0.052
Eccentricity index	0.81 $\pm$ 0.07	0.81 $\pm$ 0.08	0.96
Asymmetry index	0.28 $\pm$ 0.10	0.31 $\pm$ 0.10	0.27
Lipidic plaque behind stent	35 (92.1)	41 (91.1)	1.00
Follow-up	40 lesions	46 lesions	
Minimum lumen area, mm <sup>2</sup>	5.92 $\pm$ 2.43	5.27 $\pm$ 2.24	0.20
Percent NIH area at MLA site, %	15.2 $\pm$ 11.5	13.2 $\pm$ 12.2	0.45
Percent NIH volume, %	7.5 $\pm$ 4.7	7.3 $\pm$ 5.3	0.85
NIH thickness, $\mu$ m	70.0 $\pm$ 33.9	67.2 $\pm$ 33.9	0.71 <sup>a</sup>

Note: Values are n (%), mean  $\pm$  SD.

Abbreviations: BP-EES, bioresorbable polymer everolimus-eluting stent; DP-EES, durable polymer everolimus-eluting stent; H-K, Huo-Kassab; MLA, minimum lumen area; NIH, neointimal hyperplasia; PCI, percutaneous coronary intervention.

<sup>a</sup>Strut level comparison using each individual strut with clustering adjusting.

struts (median, 59.9% vs. 68.9%) was lower in BP-EES compared with DP-EES (Table 4).

Six-month percent strut coverage (primary endpoint) of BP-EES ( $83.6 \pm 11.4\%$ ) was not non-inferior compared to those of DP-EES ( $81.6 \pm 13.9\%$ ), difference 2.0% [lower 95% confidence interval  $-2.6\%$ ],  $p_{\text{non-inferiority}} = 0.07$  (Table 4). There were no significant differences in neointimal thickness ( $70.0 \pm 33.9 \mu\text{m}$  vs.  $67.2 \pm 33.9 \mu\text{m}$ ,  $p = 0.71$ ) or percent NIH volume ( $7.5 \pm 4.7\%$  vs.  $7.3 \pm 5.3\%$ ,  $p = 0.85$ ) between BP-EES versus DP-EES (Table 3). The cumulative frequency for stent strut coverage and the distribution of strut-level neointimal thickness was also quite similar between the two stents (Figure 2). When we used the definition of healthy strut coverage ( $\geq 40 \mu\text{m}$  by OCT) derived using histopathological healthy neointima as the gold standard,<sup>21</sup> percent healthy strut coverage was also similar between BP-EES ( $69.7 \pm 15.4\%$ ) versus DP-EES ( $68.0 \pm 18.9\%$ ).

### 3.3 | Morphologic factors associated with vascular healing

By multivariable linear regression models, there was no association between stent type and stent healing (percent strut coverage or percent NIH volume) (Table 5). Both percent embedded struts and minimum H-K stent expansion at baseline were positively associated with %NIH volume at follow-up. Using a conventional definition of stent expansion (minimum stent area/average reference lumen area) there was a similar trend, but a less clear association compared with the H-K definition of stent expansion (Table S1).

### 3.4 | Comparison between segments with versus without lipidic plaque behind the stent in the same patients

There were 72 lesions with both lipidic plaque and non-lipidic plaque somewhere behind the stent at baseline. In order to clarify the effect of underlying lipidic plaque on stent healing, stent healing parameters between the stent segment with underlying lipidic plaque versus the stent segment without underlying lipidic plaque within the same lesion were compared including all lesions with lipidic plaque at baseline (Table 6). At baseline, embedded struts were more frequently observed within the segment containing lipidic plaque compared with the segment without lipid; and at follow-up percent strut coverage and percent NIH volume were significantly greater in segments with lipidic plaque.

### 3.5 | Clinical outcomes

Six-month follow-up data after the index procedure were available for a total of 103 patients excluding one patient who withdrew from the study. One patient in the BP-EES group died due to a cardiac cause at 5 months after the index procedure. Target lesion revascularization was necessary in 2 patients with BP-EES and 1 patient with DP-EES at 6 months, but OCT images at 6 months were obtained before revascularization; and OCT revealed that the cause of in-stent restenosis was neointimal hyperplasia in all three cases. There were no instances of myocardial infarction.

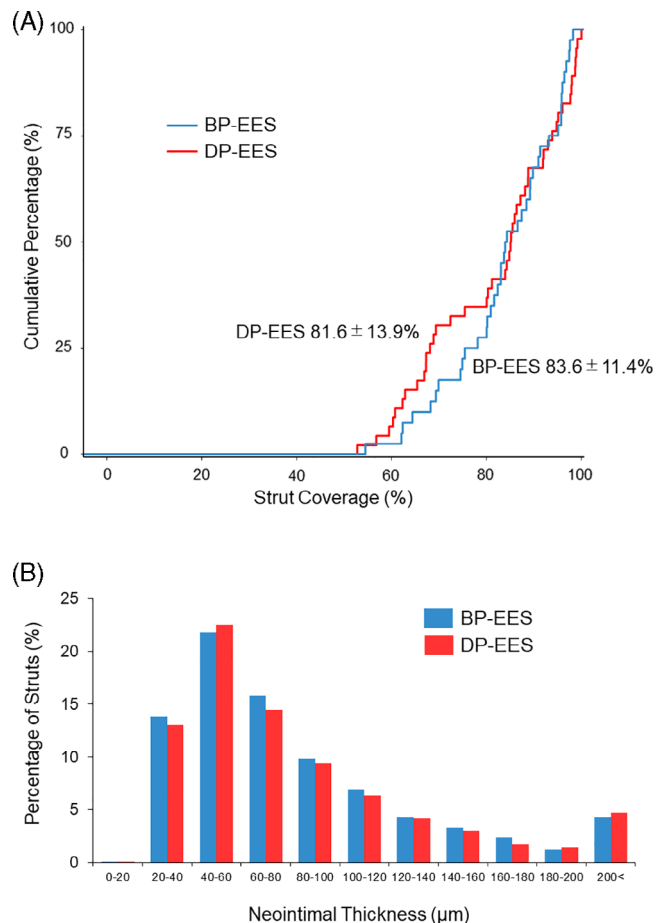
	BP-EES (n = 40)	DP-EES (n = 46)	p-value
Baseline post-PCI			
Total number of stent struts analyzed	7838	9791	
Embedded struts, %	20.8 (13.0–25.1)	13.5 (10.0–18.5)	0.006
Apposed struts, %	59.9 (45.4–68.5)	68.9 (62.8–76.5)	<0.0001
Malapposed struts, %	0.7 (0.0–1.9)	1.7 (0.3–4.1)	0.047
Struts with tissue on the top, %	16.8 (7.8–26.7)	10.3 (4.7–16.7)	0.006
Struts at side branch orifice, %	0.7 (0.0–2.1)	0.9 (0.0–2.0)	0.83
Follow-up			
Total number of stent struts analyzed	8306	9962	
Percent strut coverage (D + E), %	$83.6 \pm 11.4$	$81.6 \pm 13.9$	0.47
A, definitely uncovered, %	0.0 (0.0–2.2)	0.9 (0.0–3.0)	0.13
B, uncovered, abnormal tissue on strut, %	0.8 (0.0–1.6)	1.6 (0.2–5.3)	0.02
C, partially uncovered, %	11.8 (4.8–16.3)	10.6 (4.9–20.4)	0.76
D, covered, protruding, %	22.4 (13.9–25.4)	25.0 (15.0–31.8)	0.25
E, covered, embedded, %	65.1 (56.4–73.5)	57.0 (42.3–74.7)	0.26
Malapposed struts, %	0.0 (0.0–0.2)	0.0 (0.0–0.6)	0.06

**TABLE 4** Optical coherence tomography strut level findings

Note: Values are n (%), mean  $\pm$  SD, or median (first quartile, third quartile).

Abbreviations: BP-EES, bioresorbable polymer everolimus-eluting stent; DP-EES, durable polymer everolimus-eluting stent; PCI, percutaneous coronary intervention.





**FIGURE 2** Strut coverage and neointimal thickness. (A) Cumulative frequency curve for strut coverage (primary endpoint). (B) Distribution of neointimal thickness on each struts. BP-EES, bioresorbable polymer everolimus-eluting stent; DP-EES, durable polymer everolimus-eluting stent

## 4 | DISCUSSION

This study assessed strut coverage at 6-month follow-up comparing BP-EES versus DP-EES in patients with ACS. The findings of the present study are as follows. (a) Six-month strut coverage of BP-EES was not non-inferior compared to DP-EES in ACS patients. (b) Percent baseline embedded struts or stent expansion calculated by the H-K model was independently associated with percent NIH volume. (c) More neointimal hyperplasia was observed at the site of lipidic plaque versus the site of non-lipidic plaque without difference of MLA at 6-month follow-up.

Strut coverage is one of the key features of vascular healing. Inadequate strut coverage has been reported to increase the risks of DES failure such as VLST.<sup>4-7</sup> To reduce such risks, biocompatible and bioresorbable polymers have been developed with new-generation DES. The TRiple Assessment of Neointima Stent FOrmation to Reabsorbable polyMer With Optical Coherence Tomography (TRANSFORM-OCT) trial has reported that a comparable vascular healing response at 3 months

defined as the rates of DES uncoverage between BP-EES versus DP zotarolimus-eluting stents (DP-ZES).<sup>22</sup> On the other hand, a recent meta-analysis assessing vascular healing with OCT imaging at 7 months showed that the prevalence of lesions with any uncovered strut was higher in BP-DES compared to DP-DES, mainly due to thicker strut BP-DES (strut thickness > 100 μm).<sup>23</sup> Thus, whether BP-DES induce better vascular healing compared to contemporary DP-DES remains controversial and must be compared using stents with similar strut thickness and incorporating the same drug so that the only difference is the polymer, which we have done in the current ACS cohort and we confirmed that the vascular healing was comparable between BP-EES and DP-EES.

Won et al. reported that the percent uncovered stent strut associated with definite stent thrombosis or sudden death ( $n = 6$ ) was  $14.4 \pm 10.8\%$ , greater than in patients without events ( $6.8 \pm 11.6\%$ )<sup>15</sup>; and Guagliumi et al. reported that the percent uncovered stent struts at the time of definite late stent thrombosis ( $n = 18$ ) was  $12.3\%$  [ $5.5-23.3$ ], greater than in patients without late stent thrombosis ( $4.1\%$  [ $3.0-6.2$ ]).<sup>4</sup> In an autopsy study, Finn et al. reported a greater percent of uncovered struts/total struts per section in DES lesions with thrombus ( $n = 28$ ) compared to DES lesions without thrombus ( $50 \pm 23\%$  vs.  $19 \pm 25\%$ ); and DES lesions with or without thrombus has a much greater percent uncovered struts than in vivo OCT studies.<sup>3</sup> These reports were mostly in the first-generation DES and in a very small number of stent thrombosis cases. Thus, it is hard to speculate on the future risk of adverse events in the current study or the influence of the current data on DAPT cessation.

In the current study we adopted a 5-level category classification for baseline stent strut apposition and examined the factors contributing to vascular healing. The results showed that better stent expansion and percent embedded struts at baseline were independent predictors of 6-month percent NIH volume. Better stent expansion may be related to more embedded struts; and more embedded struts at baseline may enhance strut coverage at follow-up. Thus, our results suggest that aggressive stenting or good stent expansion plays a useful role in vascular healing. Of note, in the current study, BP-EES showed greater percent embedded or apposed struts and less percent malapposed struts compared to DP-EES at baseline, which may be related to better stent performance of BP-EES. However, 6-month strut coverage of BP-EES was not non-inferior compared to DP-EES in this relatively small cohort. The recent randomized BIOSTEMI trial including 1300 STEMI patients showed that BP-sirolimus-eluting stents were superior to DP-EES with respect to 1-year target lesion failure.<sup>24</sup>

The effect of underlying plaque on stent strut coverage has not been well characterized. Some previous studies reported that neointima or stent strut coverage was less on a thin-cap fibroatheroma.<sup>25,26</sup> In contrast, a recent OCT study demonstrated that percent covered struts and percent neointima were significantly greater and thicker on a lipidic plaque.<sup>27</sup> In the present study, we compared lipid versus non-lipid segments within the same lesions in the same patients because this allowed each patient to serve as his or her own control; and we observed more NIH and better stent strut coverage in a lipidic segment compared with a nonlipidic segment

**TABLE 5** Association between patient and lesion characteristics and endpoints in the multivariable models

Covariates	Endpoints			
	Follow-up %strut coverage		Follow-up %NIH volume	
	Regression coefficient (95% confidence interval)	p-value	Regression coefficient (95% confidence interval)	p-value
BP-EES compared with DP-EES (reference)	-1.2 (-8.0, 5.7)	0.74	-1.4 (-3.5, 0.8)	0.21
Baseline percent embedded struts, per 10%	3.4 (-0.6, 7.4)	0.09	1.4 (0.2, 2.6)	0.02
Baseline minimum H-K stent expansion, per 10%	1.6 (-0.8, 3.9)	0.19	0.9 (0.1, 1.6)	0.02
Baseline stent asymmetry index	-3.0 (-38.1, 32.2)	0.87	4.8 (-6.0, 15.6)	0.38
Baseline total stent length, per 10 mm	-0.8 (-4.6, 3.0)	0.69	0.2 (-1.0, 1.4)	0.76
Baseline presence of lipidic plaque behind stent	-2.9 (-13.8, 8.1)	0.61	2.1 (-1.3, 5.5)	0.22
Age, per 10 years	-2.2 (-4.7, 0.3)	0.09	-0.6 (-1.4, 0.2)	0.12
Female sex	1.3 (-6.0, 8.5)	0.73	1.3 (-0.9, 3.6)	0.24
Diabetes mellitus	-5.7 (-12.6, 1.3)	0.11	0.9 (-1.3, 3.0)	0.42
Chronic kidney disease	-4.5 (-12.9, 4.0)	0.30	-1.6 (-4.2, 1.0)	0.22
Baseline STEMI presentation	2.2 (-4.0, 8.4)	0.49	0.5 (-1.4, 2.4)	0.63
Follow-up, days	0.08 (-0.30, 0.46)	0.67	0.00 (-0.11, 0.12)	0.97

Abbreviations: BP-EES, bioresorbable polymer everolimus-eluting stent; DP-EES, durable polymer everolimus-eluting stent; H-K, Huo-Kassab; NIH, neointimal hyperplasia; STEMI, ST-segment elevation myocardial infarction.

	Segment with lipid	Segment without lipid	p-value
Number of segments analyzed	72	72	
Baseline OCT findings			
Minimum lumen area, mm <sup>2</sup>	6.08 ± 2.18	6.08 ± 2.31	0.99
Minimum stent area, mm <sup>2</sup>	6.68 ± 2.38	6.10 ± 2.46	0.15
Percent embedded struts, %	20.3 (14.9–31.6)	13.3 (6.9–20.3)	<0.0001
Follow-up OCT findings			
Minimum lumen area, mm <sup>2</sup>	6.03 ± 2.33	5.75 ± 2.52	0.49
Minimum stent area, mm <sup>2</sup>	6.86 ± 2.44	6.15 ± 2.46	0.10
Maximum NIH area, %	17.0 ± 9.8	14.3 ± 8.9	0.09
Percent NIH volume, %	8.7 ± 5.6	6.1 ± 5.2	0.005
Percent covered struts, %	91.3 (74.9–97.1)	84.1 (68.1–94.2)	0.04

Note: Values are mean ± SD, or median (first quartile, third quartile).

Abbreviations: NIH, neointimal hyperplasia; OCT, optical coherence tomography.

**TABLE 6** Comparison between the segments with versus without lipid behind stent

without difference of MLA at 6-month follow-up. This may be related to the finding that baseline embedded struts were significantly more common in the lipid segment compared those in non-lipidic segment. In support of this, pathology data has showed that stent struts overlying lipid had increased neointimal thickness.<sup>28</sup> From the results of this study, proper stent expansion and lipid behind stent have positive correlation with endothelialization rather than type of polymer which appears less relevant.

## 5 | LIMITATIONS

This present study had several limitations. First, our study included a relatively small number of patients. The sample size calculation

required 88 cases which was not met (total available number for primary endpoint analysis was 86 cases). Additionally, the SD of percent strut coverage was very large compared with prior studies.<sup>14,29,30</sup> Thus, we have less power to detect a difference than estimated. Second, there were five cases with either stent thrombosis or in-stent restenosis who have been randomized by error, because their old stent was not well visualized angiographically and firstly detected during IVUS-guided PCI after randomization. Third, baseline final OCT was not blinded to the operators which may lead the further PCI and may bias the strut coverage at follow-up. Fourth, the stents in this study had different platform designs that might have impacted the results. Fifth, there was no data on thrombus or fibrous cap thickness prior to stent implantation. Finally, assessment of lipidic plaque was done using post-PCI OCT, not pre-PCI OCT. One previous pathology



study has shown that plaques attenuated by IVUS correspond to lipid-rich plaques.<sup>31</sup> In the present study, post-hoc validation of post-PCI OCT lipid rich plaque using pre-PCI IVUS attenuated plaque as the reference had a sensitivity of 94% and a positive predictive value of 89%. This result supported our contention that post-PCI OCT assessment was consistent with lipid rich plaque.

## 6 | CONCLUSIONS

Six-month strut coverage of BP-EES was not non-inferior compared to those of DP-EES in ACS patients. Aggressive stenting or good stent expansion were independently associated with better vascular healing.

### ACKNOWLEDGMENTS

The authors acknowledge Zhipeng Zhou, MA, Dominic P. Francese, MPH, and Yumi Nozawa for their help in this study. This study was supported by Boston Scientific Japan.

### CONFLICT OF INTEREST

Mitsuaki Matsumura: Consultant - Terumo Corporation. Gary S. Mintz: Honoraria - Boston Scientific, Philips, Terumo, and Medtronic. Akiko Maehara: Grant support from Abbott Vascular and Boston Scientific, consultant for Conavi Medical Inc. Other authors: None.

### DATA AVAILABILITY STATEMENT

The data that support the findings of this study are available from the corresponding author upon reasonable request.

### ORCID

Masahiko Noguchi  <https://orcid.org/0000-0003-4501-3449>

Tomotaka Dohi  <https://orcid.org/0000-0002-6646-468X>

Mitsuaki Matsumura  <https://orcid.org/0000-0002-2082-0247>

Akiko Maehara  <https://orcid.org/0000-0002-1910-8447>

### REFERENCES

- Stone GW, Moses JW, Ellis SG, et al. Safety and efficacy of sirolimus- and paclitaxel-eluting coronary stents. *N Engl J Med*. 2007;356:998-1008.
- Joner M, Finn AV, Farb A, et al. Pathology of drug-eluting stents in humans: delayed healing and late thrombotic risk. *J Am Coll Cardiol*. 2006;48:193-202.
- Finn AV, Joner M, Nakazawa G, et al. Pathological correlates of late drug-eluting stent thrombosis: strut coverage as a marker of endothelialization. *Circulation*. 2007;115:2435-2441.
- Guagliumi G, Sirbu V, Musumeci G, et al. Examination of the in vivo mechanisms of late drug eluting stent thrombosis: findings from optical coherence tomography and intravascular ultrasound imaging. *JACC Cardiovasc Interv*. 2012;5:12-20.
- Souteyrand G, Amabile N, Mangin L, et al. PESTO investigators mechanisms of stent thrombosis analysed by optical coherence tomography: insights from the national PESTO French registry. *Eur Heart J*. 2016;37:1208-1216.
- Taniwaki M, Radu MD, Zaugg S, et al. Mechanisms of very late drug-eluting stent thrombosis assessed by optical coherence tomography. *Circulation*. 2016;133:650-660.
- Adriaenssens T, Joner M, Godschalk TC, et al. Optical coherence tomography findings in patients with coronary stent thrombosis: a report of the PRESTIGE consortium (prevention of late stent thrombosis by an interdisciplinary global European effort). *Circulation*. 2017;136:1007-1021.
- Kolandaivelu K, Swaminathan R, Gibson WJ, et al. Stent thrombogenicity early in high-risk interventional settings is driven by stent design and deployment and protected by polymer-drug coatings. *Circulation*. 2011;123:1400-1409.
- Mori H, Atmakuri DR, Torii S, et al. Very late pathological responses to cobalt-chromium everolimus-eluting, stainless steel sirolimus-eluting, and cobalt-chromium bare metal stents in humans. *J Am Heart Assoc*. 2017;6:e007244.
- Gonzalo N, Barlis P, Serruys PW, et al. Incomplete stent apposition and delayed tissue coverage are more frequent in drug-eluting stents implanted during primary percutaneous coronary intervention for ST-segment elevation myocardial infarction than in drug-eluting stents implanted for stable/unstable angina: insights from optical coherence tomography. *JACC Cardiovasc Interv*. 2009;2:445-452.
- Räber L, Zanchin T, Baumgartner S, et al. Differential healing response attributed to culprit lesions of patients with acute coronary syndromes and stable coronary artery after implantation of drug-eluting stents: an optical coherence tomography study. *Int J Cardiol*. 2014;173:259-267.
- Wilson GJ, Marks A, Berg KJ, et al. The SYNERGY biodegradable polymer everolimus eluting coronary stent: porcine vascular compatibility and polymer safety study. *Catheter Cardiovasc Interv*. 2015;86:E247-E257.
- Lee KS, Lee JZ, Hsu CH, et al. Temporal trends in strut-level optical coherence tomography evaluation of coronary stent coverage: a systematic review and meta-analysis. *Catheter Cardiovasc Interv*. 2016;88:1083-1093.
- Ino Y, Kubo T, Tanaka A, et al. Comparison of vascular response between everolimus-eluting stent and bare metal stent implantation in ST-segment elevation myocardial infarction assessed by optical coherence tomography. *Eur Heart J Cardiovasc Imaging*. 2015;16:513-520.
- Won H, Shin DH, Kim BK, et al. Optical coherence tomography derived cut-off value of uncovered stent struts to predict adverse clinical outcomes after drug-eluting stent implantation. *Int J Cardiovasc Imaging*. 2013;29:1255-1263.
- Chieffo A, Buchanan GL, Parodi G, et al. Drug-eluting stent implantation in patients with acute coronary syndrome - the activity of platelets after inhibition and cardiovascular events: optical coherence tomography (APICE OCT) study. *EuroIntervention*. 2014;10:916-923.
- Popma JT, Almonacid A, Burke D. Qualitative and quantitative coronary angiography3. In: Topol EJ, ed. *Textbook of Interventional Cardiology*. 6th ed. W.B. Saunders; 2011;757-775.
- Lee SW, Lam SC, Tam FC, et al. Evaluation of early healing profile and neointimal transformation over 24 months using longitudinal sequential optical coherence tomography assessments and 3-year clinical results of the new dual-therapy endothelial progenitor cell capturing sirolimus-eluting combo stent: the EGO-combo study. *Circ Cardiovasc Interv*. 2016;9:e003469.
- Huo Y, Finet G, Lefevre T, Louvard Y, Moussa I, Kassab GS. Which diameter and angle rule provides optimal flow patterns in a coronary bifurcation? *J Biomech*. 2012;45:1273-1279.
- Nakamura D, Wijns W, Price MJ, et al. New volumetric analysis method for stent expansion and its correlation with final fractional flow reserve and clinical outcome: an ILUMIEN I substudy. *JACC Cardiovasc Interv*. 2018;11:1467-1478.
- Jinnouchi H, Otsuka F, Sato Y, et al. Healthy strut coverage after coronary stent implantation: an ex vivo human autopsy study. *Circ Cardiovasc Interv*. 2020;13:e008869.

22. Guagliumi G, Shimamura K, Sirbu V, et al. Temporal course of vascular healing and neoatherosclerosis after implantation of durable- or biodegradable-polymer drug-eluting stents. *Eur Heart J*. 2018;39:2448-2456.
23. Cassese S, Xhepa E, Ndrepepa G, et al. Vascular response to percutaneous coronary intervention with biodegradable-polymer vs. new-generation durable-polymer drug-eluting stents: a meta-analysis of optical coherence tomography imaging trials. *Eur Heart J Cardiovasc Imaging*. 2018;19:1294-1301.
24. Iglesias JF, Muller O, Heg D, et al. Biodegradable polymer sirolimus-eluting stents versus durable polymer everolimus-eluting stents in patients with ST-segment elevation myocardial infarction (BIOSTEMI): a single-blind, prospective, randomised superiority trial. *Lancet*. 2019;394:1243-1253.
25. Kubo T, Imanishi T, Kitabata H, et al. Comparison of vascular response after sirolimus-eluting stent implantation between patients with unstable and stable angina pectoris: a serial optical coherence tomography study. *JACC Cardiovasc Imaging*. 2008;1:475-484.
26. Ueda T, Uemura S, Watanabe M, et al. Thin-cap fibroatheroma and large calcification at the proximal stent edge correlate with a high proportion of uncovered stent struts in the chronic phase. *Coron Artery Dis*. 2016;27:376-384.
27. Kakizaki R, Minami Y, Hashikata T, et al. Impact of underlying plaque type on strut coverage in the early phase after drug-eluting stent implantation. *Coron Artery Dis*. 2018;29:624-631.
28. Farb A, Weber DK, Kolodgie FD, Burke AP, Virmani R. Morphological predictors of restenosis after coronary stenting in humans. *Circulation*. 2002;105:2974-2980.
29. Abhyankar A, Abizaid A, Chamié D, Rathod M. Comparison of neointimal coverage between ultrathin biodegradable polymer-coated sirolimus-eluting stents and durable polymer-coated everolimus-eluting stents: 6 months optical coherence tomography follow-up from the TAXCO study. *Catheter Cardiovasc Interv*. 2021;97:423-430.
30. Kobayashi T, Sotomi Y, Suzuki S, et al. Neointimal characteristics comparison between biodegradable-polymer and durable-polymer drug-eluting stents: 3-month follow-up optical coherence tomography light property analysis from the RESTORE registry. *Int J Cardiovasc Imaging*. 2020;36:205-215.
31. Pu J, Mintz GS, Biro S, et al. Insights into echo-attenuated plaques, echolucent plaques, and plaques with spotty calcification: novel findings from comparisons among intravascular ultrasound, near-infrared spectroscopy, and pathological histology in 2,294 human coronary artery segments. *J Am Coll Cardiol*. 2014;63:2220-2233.

#### SUPPORTING INFORMATION

Additional supporting information may be found online in the Supporting Information section at the end of this article.

**How to cite this article:** Noguchi M, Dohi T, Okazaki S, Matsumura M, Takeuchi M, Endo H, et al. Comparison of 6-month vascular healing response after bioresorbable polymer versus durable polymer drug-eluting stent implantation in patients with acute coronary syndromes: A randomized serial optical coherence tomography study. *Catheter Cardiovasc Interv*. 2021;98:E677-86. <https://doi.org/10.1002/ccd.29892>