

# Research on the Influence of the Allogeneic Bone Graft in Postoperative Recovery After MOWHTO: A Retrospective Study

Rui Zhong\*, Gang Yu\*, Yingming Wang\*, Chao Fang, Shuai Lu, Zhilin Liu, Jingyu Gao, Chengyuan Yan, Qichun Zhao

Department of Sports Medicine, The Affiliated Provincial Hospital of Anhui Medical University, Hefei, 230001, People's Republic of China

\*These authors contributed equally to this work

Correspondence: Qichun Zhao, Department of Sports Medicine, The Affiliated Provincial Hospital of Anhui Medical University, No. 17 Lujiang Road, Luyang District, Hefei, 230001, People's Republic of China, Tel/Fax +86 13965050622, Email qichzhao@163.com

**Purpose:** To compare the effects of an allogeneic bone graft and a non-filled bone graft on the rate of osteotomy gap union in medial opening wedge high tibial osteotomy (MOWHTO) with an opening width less than 10 mm.

**Methods:** A total of 65 patients undergoing MOWHTO between January 2018 and December 2020 were enrolled in this retrospective study. The patients were divided into two groups: the allograft group (MOWHTO with allogeneic bone grafting, 30 patients) and the non-filling group (MOWHTO without bone void fillers, 35 patients). The clinical outcomes, including the Western Ontario and McMaster Universities Osteoarthritis index (WOMAC), Lysholm score, and post-operative complications, were compared. The radiographic evaluation included changes in hip-knee-ankle angle (HKA), medial proximal tibial angle (MPTA), femorotibial angle (FTA), and weight-bearing line ratio (WBLR) at pre-operation, at two-day post-operation, and the last follow-up. Radiographs were obtained at three, six and twelve months post-surgery, and at the time of the last follow-up to assess the fill area of the osteotomy gap. The union rate of the osteotomy gap was calculated and compared, and risk factors that may affect the rate of osteotomy gap union were also discussed.

**Results:** The rate of osteotomy gap union at 3 and 6 months after the operation in the allograft group was significantly higher compared with the non-filling group (all  $P < 0.05$ ), while no significant difference was found after the 1-year post-operative and at the last follow-up. Also, the WOMAC and Lysholm scores of the allograft group were significantly higher than those of the non-filling group (all  $P < 0.05$ ), and there was no significant difference between the two groups at the last follow-up.

**Conclusion:** Filling the gaps with the allograft bones may accelerate the union of osteotomy gap, improve clinical outcomes, and have important implications for patient rehabilitation in the early post-operative course. Bone grafting did not affect the final rate of osteotomy gap union and the clinical score of patients.

**Keywords:** MOWHTO, osteotomy gap, bone union, allogenic bone graft

## Introduction

Medial Opening wedge high tibial osteotomy (MOWHTO) is an effective therapy for treating mild-to-moderate osteoarthritis (OA) of the medial compartment of the knee combined with varus deformity. Previous study indicated that MOWHTO, different from simple arthroscopic joint clearance and Unicompartmental Knee Arthroplasty (UKA), is characterized by the preservation of medial compartment of the knee joint, and can preserve the, correct lower limb joint angles and adjust the weight-bearing line to the lateral tibial plateau.<sup>1</sup> In the follow-up studies, MOWHTO retarded the degeneration of cartilage by reducing weight-bearing on the medial cartilage of knee, which offers possibilities for the cartilage regeneration. Meanwhile, MOWHTO avoids complications such as fibular osteotomy, peroneal nerve palsy, and

tibiofibular shortening after lateral closed wedge osteotomy and exhibit satisfactory medium-term and long-term curative effects.<sup>2-4</sup>

With the development of biomechanics research, the preoperative planning of MOWHTO has become increasingly accurate and perfect. Early studies suggested correcting the mechanical axis of the affected limb to within 60–70% of the tibial plateau measured from the medial.<sup>5,6</sup> Fujisawa identified this anchor point accurate to 62.5% (range 62%–66%) in later study.<sup>7</sup> Moreover, this point is widely used in the calculation of preoperative correction degree. The results of countless biomechanical studies in the later period proved once again that Fujisawa point is an excellent positioning point for correcting mechanical axis, which can effectively improve the stability of the lower limbs and reduce the incidence of delayed union.<sup>8,9</sup> On the other hand, a recent application of locking compression plates and the locking screw provided sufficient support for the axial stress and torsional stability of the osteotomy site after MOWHTO, which can reduce friction between the plate and the bone tissue lateral to the osteotomy site and helps to maintain the blood supply required for the osteotomy to heal itself from the inside out.<sup>10,11</sup> In addition, MOWHTO can also reduce post-operative complications such as delayed union, lateral hinge fractures, and loss of correction.

In order to accelerate the union and filling of the gap in the osteotomy area and further prevent unwanted complications, various research teams have used bone tissue graft filling. However, the choice of graft type and the indications for filling therapy are still unclear.<sup>12-15</sup> At present, the clinical application of the graft scheme is represented by autogenous iliac bone, allogeneic bone, and synthetic materials.<sup>13-15</sup> The trifacial cortical iliac bone derived from the autogenous anterior superior iliac spine has become the “gold standard” of grafts because of its excellent osteogenic ability, bone induction, and bone conduction characteristics. Allogeneic bone blocks are preserved by freeze-drying without autologous materials, which can avoid donor complications. Because of their good bone conductivity and absorption rate, allogeneic bone blocks are the most widely used fillers in OWHTO.  $\beta$ -tricalcium phosphate ( $\beta$ -TCP) and hydroxyapatite (HA) are the main products of synthetic materials whose clinical efficacy has been verified.<sup>13-15</sup> Although bone formation and induction ability are slightly lower than in the former ones, they are easy to obtain, and their treatment cost is more acceptable.

Previous studies favored graft filling in patients with large osteotomy gaps and high risk. It was widely accepted that the implantation of bone tissue could provide the induction and conduction required for bone healing of large defect gaps during self-absorption and share the stress load borne by internal fixation. Nevertheless, bone grafting is usually unnecessary in patients without serious comorbidities, such as diabetes and osteoporosis.<sup>13,16,17</sup> Moreover, the perspectives of clinicians are also divided. There have also been opinions that bone tissue filling in the gap with less distraction height could improve the union rate and shorten the rehabilitation period.<sup>2,18</sup>

This study aimed to compare the clinical efficacy and radiographic bone union rate of filling with or without allogeneic freeze-dried bone chips in the osteotomy gap with an osteotomy gap size of < 10 mm. Furthermore, we intend to explore the important factors affecting gap union in different periods after surgery by referring to the results of previous studies.

## Methods

### Study Design

In this study, a total of 108 patients who received MOWHTO treatment in our hospital were collected, and 65 patients were enrolled in this study. By comparing clinical function scores and radiographic data of patients in the two groups at different time points postoperatively, the effects of bone allograft on postoperative functional recovery and bone healing speed were analyzed. In addition, multiple regression analysis was used to evaluate the effects of several reported high risk factors on the rate of postoperative bone union in the two groups.

### Patients

A total of 65 patients who underwent MOWHTO in the First Affiliated Hospital of the University of Science and Technology of China from January 2018 to December 2020 were enrolled.

Inclusion criteria were as follows: (1) patients who failed conservative therapy for mild to medial unicompartmental osteoarthritis with varus deformity; (2) age < 65 years; (3) MPTA < 85° or FTA > 175°; (4) angle for knee flexion contractures < 15°; (5) the opening width of osteotomy gap was < 10 mm as confirmed by post-operative computed tomography (CT) measurement; (6) intraoperative internal fixation with TomoFix™ plate (Synthes, Oberdorf, Switzerland) and locking screw; (7) follow-up > 1 year.

Exclusion criteria were the following: (1) moderate to severe patellofemoral arthritis, rheumatoid arthritis, or active knee infection; (2) varus deformity > 15° (3) knee instability or associated ligament injury; (4) body mass index (BMI) ≥ 30; (5) Ahlbäck grade ≥ III; (6) cartilage degeneration of lateral compartment; (7) lateral meniscus injury.

Finally, 30 patients in the allograft group (MOWHTO with allogeneic bone grafting) and 35 patients in the non-filling group (MOWHTO without bone void fillers) were included. The study was conducted according to the principles of the Declaration of Helsinki, and approved by the Ethics Committee of The Affiliated Provincial Hospital of Anhui Medical University (2022-RE-080). All patients provided informed consent and signed informed consent forms, and the same surgeon performed all operations.

As shown in Table 1, there were no statistically significant differences in age, gender, height, weight, BMI, the opening width of the osteotomy gap, medial meniscus, and medial cartilage damage between the two groups. The opening width of the osteotomy gap of the allograft group was 7.39±1.24mm, and the non-filling group was 7.19 ±1.62mm (P=0.777). In the allograft group, 21 patients had medial meniscus injury, while 27 had medial meniscus injury in the non-filling group. There were 22 and 8 patients with medial meniscus injury grade III and IV in the allograft group and 24 and 11 patients with medial meniscus injury grade III and IV in the non-filling group, respectively. The mean cartilage defect area of the allograft group was 5.04±1.94 cm<sup>2</sup>, and that of the non-filling group was 4.88±1.99cm<sup>2</sup> (Table 1). Moreover, there were no significant differences in pre-operative clinical scores and pre-operative imaging indicators (HKA, MPTA, TFA, and WBLR) between the two groups (Table 2).

**Table 1** Analysis of Differences in Baseline Data Between Patients with and without Bone Grafting (n=65)

	Allograft Group (n=30)	Non-Filling Group (n=35)	Test Statistic	p-Value
Age (years)	53.27±5.24	50.86±8.56	1.390 <sup>a</sup>	0.170
Side			0.453 <sup>b</sup>	0.501
Left	20	26		
Right	10	9		
Gender			0.258 <sup>b</sup>	0.612
Male	17	22		
Female	13	13		
Height (m)	1.62±0.06	1.65±0.08	-1.480	0.144
Weight (kg)	68.35±8.89	71.26±13.93	-1.017	0.314
BMI	25.99±3.27	26.03±3.69	-0.050	0.960
Opening width	7.39±1.24	7.19±1.62	0.561 <sup>a</sup>	0.577
Medial meniscus injury			0.015 <sup>b</sup>	0.901
Yes	21	27		
No	9	8		
Outerbridge grade			0.177	0.674
III grade	22	24		
IV grade	8	11		
Cartilage defect area (cm <sup>2</sup> )	5.04±1.94	4.88±1.99	0.323	0.748
Follow-up time (months)	18.53±1.66	18.46±2.28	0.152 <sup>a</sup>	0.880

**Notes:** Values are presented as mean±SD; <sup>a</sup>Derived with Student's *t*-test; <sup>b</sup>Derived with Pearson chi-square test.

**Table 2** Changes in Clinical and Radiological Outcomes

	<b>Allograft Group</b>	<b>Non-Filling Group</b>	<b>t-text</b>	<b>p-value</b>
<b>FTA</b>				
Preoperative	179.70±2.79	179.09±1.25	1.103	0.277
Postoperative	172.88±2.14	172.87±1.53	0.030	0.976
Last follow-up	172.96±2.00	173.73±2.25	-1.441	0.154
<b>HKA</b>				
Pre-operative	-5.08±1.68	-4.74±1.34	-0.905	0.369
Post-operative	1.35±0.94	1.50±1.05	-0.614	0.541
Last follow-up	1.06±1.08	0.98±1.32	0.265	0.792
<b>WBLR</b>				
Pre-operative	38.24±5.06	37.79±8.79	0.259	0.797
Post-operative	59.23±4.60	58.06±5.73	0.908	0.367
Last follow-up	59.43±4.83	58.03±5.07	1.133	0.262
<b>MPTA</b>				
Pre-operative	83.33±1.76	83.81±1.76	-1.108	0.272
Post-operative	89.98±1.57	89.38±1.78	1.434	0.156
Last follow-up	89.68±1.64	88.51±5.12	1.204	0.233
<b>WOMAC</b>				
Pre-operative	53.20±4.43	52.91±4.00	0.273	0.785
Post-operative 6 months	23.53±2.16	34.17±3.27	-15.673	<0.001*
Last follow-up	20.77±2.01	21.09±2.56	-0.552	0.583
<b>Lysholm</b>				
Pre-operative	56.87±4.70	58.49±4.70	-1.385	0.171
Post-operative 6 months	86.00±1.89	78.34±4.48	9.201	<0.001*
Last follow-up	90.63±1.83	89.69±3.17	1.501	0.139

**Notes:** Values are presented as mean±SD; \*Stands for a statistically significant.

## Surgical Technique

Under general anesthesia, all patients were placed in a supine position on the operating table. A high thigh tourniquet was applied and conventionally disinfected using a spread towel. The arthroscope was connected into and out of the water, and the imaging system and the tourniquet were inflated. Subsequently, the injury of the medial cartilage and the medial meniscus were inspected (Table 1). Patients with medial meniscus injury were with medial meniscus with intact lateral compartment cartilage and meniscus and normal anterior and posterior cruciate ligaments. The arthroscopic instruments were removed after exploration. The anteromedial approach of the upper tibia was taken, and a longitudinal incision of about 6 cm was made, followed by an incision of the subcutaneous skin and fascia to expose the cortex of the upper tibia and the insertion point of the upper border of the pes anserinus, which was defined as the starting point of the osteotomy. Next, the periosteum was stripped, two Kirschner wires were inserted under fluoroscopy, and the tibia was scored with an oscillating saw. The outermost 10 mm of the tibia was kept intact which used as a hinge for the osteotomy. This “hinge” is the center of the rotation of the angulation (CORA), and coronal osteotomy behind the tibial tubercle was performed. The osteotomy opening was opened by inserting the osteotomy in layers, and a spreader was used instead of the osteotomy to expand.

In the opened osteotomy gap, 30 cases were implanted with allogeneic freeze-dried bone strips and 35 cases were without bone void fillers. The TomoFix plate was placed on the medial tibia, followed by drilling, sounding, tapping, and then screwing 8 locking screws of appropriate length. During the operation, C-arm X-ray fluoroscopy was performed to check the force line of the lower extremity and the internal fixation of the steel plate. After washing, a drainage tube was placed, and the incision was sutured layer by layer.

## Postoperative Rehabilitation

Ankle pump training and straight leg raising were performed immediately after surgery. The drainage tube was removed 2–3 days post-surgery, and patients began knee flexion exercises and partial weight bearing with crutches. The range of

motion (ROM) progressed to 120 degrees after 4 weeks; the affected limb was equipped with a chuck-type brace until it was fully able to bear weight.

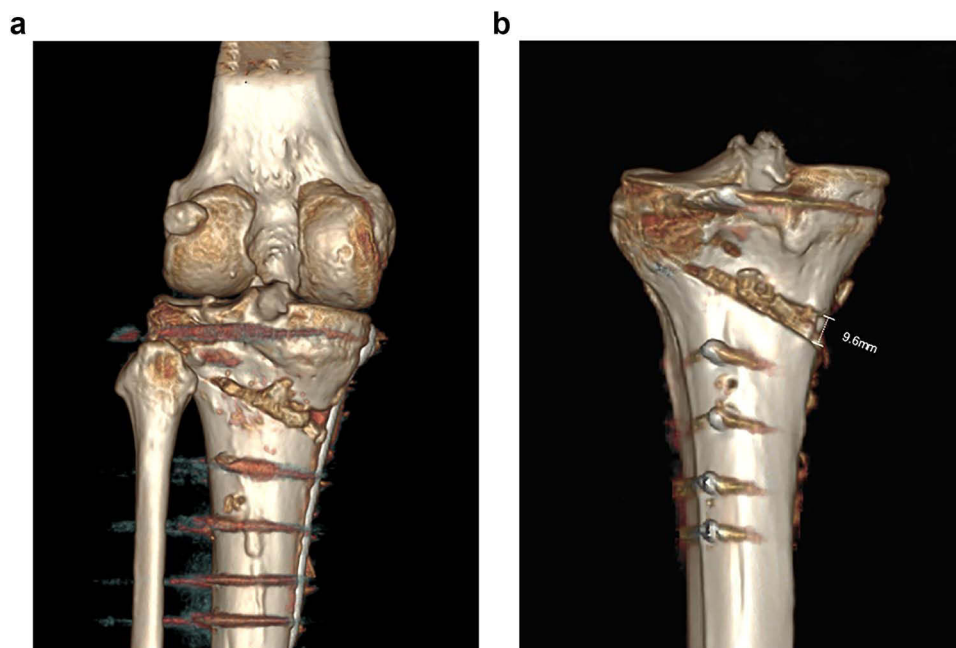
## Clinical and Radiographic Evaluation

The clinical evaluation consisted of the Western Ontario and McMaster Universities Osteoarthritis index (WOMAC), Lysholm score, and post-operative complications. Statistical analysis was conducted to find differences in variable values before surgery, 6 months after surgery, and at the last follow-up.

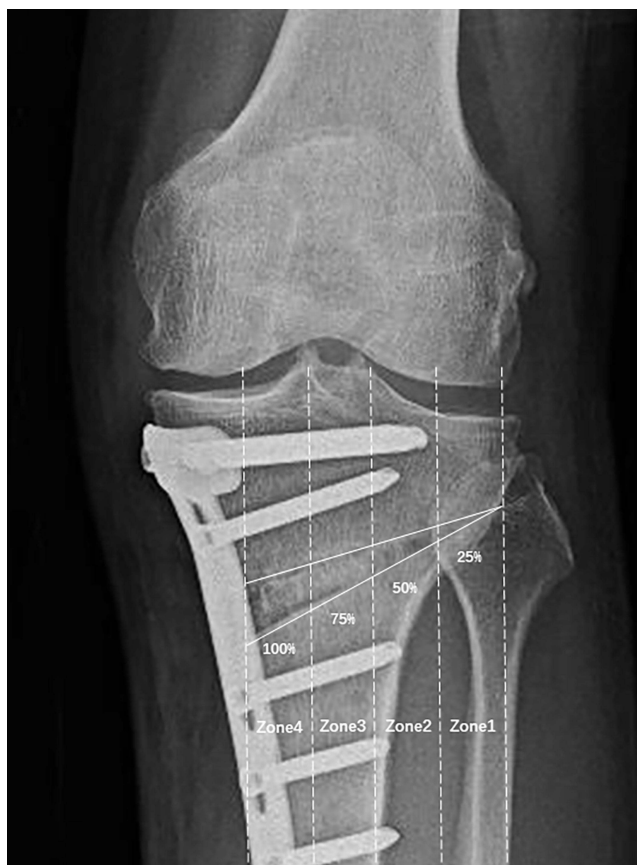All patients underwent pre-operative and post-operative three-dimensional CT (Figure 1a). Full-length radiographs of the affected lower limb and positive lateral radiographs of the knee joint were done before the operation, after the operation, and during the follow-up (one, three, six, and twelve months post-surgery). Opening width was measured on the three-dimensional CT imaging (Figure 1b). The radiographic evaluation included changes in hip–knee–ankle angle (HKA), medial proximal tibial angle (MPTA), femorotibial angle (FTA), and weight-bearing line ratio (WBLR) before surgery, at one-day post-operation, and the last follow-up. If the knee had varus deformity, HKA was negative; if the knee was valgus, HKA was positive. Correction loss was defined as the difference between the HKA degree measured at the last follow-up and the measurement on the second post-operative day  $\geq 2^\circ$ ; delayed union was defined as lack of bridging callus formation in the osteotomy gap within 3 months post-operatively.

## Union Zone and the Rate of Osteotomy Gap Union

The method was adopted from the modified method by Goshima and Jung et al, which was described in previously published reports.<sup>19–21</sup> The osteotomy space was divided into the lateral hinge and four equally spaced intervals on the anteroposterior radiograph of the knee joint. Then, the bone union in the osteotomy space in 65 knee joints at different follow-up periods was evaluated and compared, and the continuous area of the posterolateral cortical bone observed was located on the X-ray film (Figure 2). Finally, the union rate of the osteotomy gap was calculated with the help of reading software (Figure 3).



**Figure 1** Display of osteotomy area in anterior and posterior position by three-dimensional CT after operation. (a) Postoperative CT showed that the osteotomy space was filled with allograft bone. (b) The opening width of the osteotomy gap was  $< 10$ mm confirmed by postoperative CT measurement.



**Figure 2** The osteotomy space was divided into the lateral hinge and four equally spaced intervals on the medial-lateral radiograph of the knee joint.

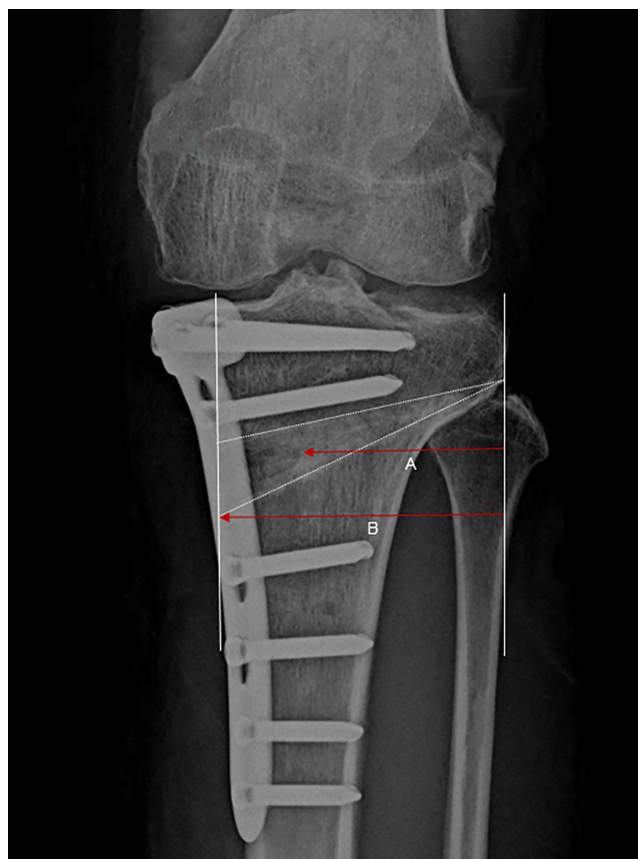## Influencing Factors of Gap Union Rate

The present study was inspired by a previous study.<sup>18</sup> The following variables were selected as potential confounders: gender, age, operation side, the opening width of intraoperative osteotomy gap, bone grafting, BMI, smoking history, hypertension history, and diabetes history. Linear multiple regression models were built at 6 months follow-up and the last follow-up to analyze the relationship between each factor and gap union rate. Bone densitometry was not considered an influencing factor for the union rate of a gap as it was not routinely detected in this study.

## Statistical Analysis

IBM SPSS Statistics 25.0 software was used for data analysis. The Kolmogorov–Smirnov test established the normality of quantitative data, and data were expressed as mean  $\pm$  standard deviation (SD), median or interquartile range. The independent samples *t*-test or Wilcoxon rank sum test was used for comparisons. For qualitative data such as operation side and gender,  $\chi^2$  test was used to analyze the differences. When comparing the imaging indicators, clinical scores, osteotomy gap union rate, and other indicators between the allograft group and non-filling group at different follow-up times, analysis of variance with repeated measures design were used to analyze whether the data obeyed the spherical assumption. If the spherical assumption was obeyed, the multivariate analysis of variance was used. If the spherical assumption was not obeyed, the within-subject effect test (one-way analysis of variance) was used and was then corrected by the Greenhouse–Geisser correction. The effects of gender, age, surgical side, BMI, smoking history, hypertension history, diabetes history, and other variables on the union rate of the osteotomy gap at the last follow-up time after surgery were analyzed using multiple linear regression models and modeled using stepwise regression methods.  $P < 0.05$  was considered statistically significant.





**Figure 3** The result of (Line A/ Line B)  $\times$  100 was the rate of osteotomy gap union.

## Results

### Clinical Outcomes

As shown in [Table 2](#), the WOMAC score in the allograft group decreased from  $53.20 \pm 4.43$  to  $23.53 \pm 2.16$  ( $P < 0.001$ ), and the Lysholm score increased from  $56.87 \pm 4.70$  to  $86.00 \pm 1.89$  at 6 months after the operation compared to pre-operative values ( $P < 0.0010$ ). Additionally, the WOMAC score in the non-filling group decreased from  $52.91 \pm 4.00$  to  $34.17 \pm 3.27$  ( $P < 0.001$ ), while the Lysholm score increased from  $58.49 \pm 4.70$  to  $78.34 \pm 4.48$  at 6 months after the operation ( $P < 0.001$ ). The two scores of the allograft group were significantly better than those of the non-filling group 6 months post-operatively (WOMAC score of the allograft group was  $23.53 \pm 2.16$ , WOMAC score of the non-filling group was  $34.17 \pm 3.27$ ,  $P < 0.001$ ; Lysholm score of allograft group was  $86.00 \pm 1.89$ , and Lysholm score of the non-filling group was  $78.34 \pm 4.48$ ,  $P < 0.001$ ). The WOMAC score at the last follow-up in the allograft group ( $20.77 \pm 2.01$ ) was slightly lower than the non-filling group ( $21.09 \pm 2.56$ ), but the difference was not statistically significant ( $P = 0.583$ ). Additionally, the Lysholm score at the last follow-up in the allograft group ( $90.63 \pm 1.83$ ) was slightly increased compared to the non-filling group ( $89.69 \pm 3.17$ ), but the difference was not statistically significant ( $P = 0.139$ ). Furthermore, these results suggested that the WOMAC score and Lysholm score in both groups were significantly improved at the last follow-up compared to 6 months post-operatively.

### Radiological Outcomes

As shown in [Table 2](#), the post-operative measurements of HKA, MPTA, and WBLR in the two groups were significantly improved compared to pre-operative measurements (all  $P < 0.05$ ). The mean WBLR measurement in the allograft group increased on the second post-operative day ( $61.23 \pm 4.60\%$ ) compared to the pre-operative measurement ( $38.24 \pm 5.06\%$ ) ( $P < 0.001$ ). The mean WBLR measurement in the non-filling group increased on the second post-operative day ( $61.06$

±5.73%) compared to the pre-operative measurement (37.79±8.79%) (P<0.001). The weight-bearing lines of the two groups were effectively adjusted to the lateral platform after surgery, and no significant difference was found between the two groups on the second post-operative day (P =0.367). Moreover, the weight-bearing lines of the two groups were effectively adjusted to the lateral platform after surgery. In addition, there were no significant changes in the radiological indicators between the two groups at the last follow-up compared with the second post-operative day (all P>0.05) (Table 2).

### Location of Union Zone and Calculation of Union Rate of the Osteotomy Gap

At 3 months post-operatively, the union zone of all patients in the allograft group reached zone 1 (100.00%), where 25 patients reached zone 2 (83.3%). In addition, 33 patients in the non-filling group reached zone 1 (94.3%), and 15 patients reached zone 2 (42.9%). At 6 months post-operatively, 20 patients in the allograft group (66.7%) and 8 patients in the non-filling group (22.9%) reached zone 3. At 12 months post-operatively, 18 patients in the two groups reached zone 4 (allograft group: 60.0%, non-filling group: 51.4%). At the last follow-up, 28 patients in the allograft group reached zone 4 (93.3%), and 30 patients in the non-filling group (85.7%) (Table 3).

Two independent samples *t*-test was used to compare the rates of osteotomy gap union at 3 months, 6 months, 12 months, and the last follow-up in the allograft group and the non-filling group, respectively. As shown in Table 4, the union rate of the allograft group was significantly higher than that of the non-filling group at 3 months and 6 months postoperatively (all P < 0.001). However, there was no significant difference in the union rate of the osteotomy gap between the two groups at 12 months post-operatively and the last follow-up.

**Table 3** Location of Union Zone of Osteotomy Gap at Different Follow-Up Time Post-Operatively

	Zone 1	Zone 2	Zone 3	Zone 4
Postoperative 3 months				
Allograft group	30	25	1	0
Non-filling group	33	15	0	0
Postoperative 6 months				
Allograft group	30	30	20	0
Non-filling group	35	35	8	0
Postoperative 12 months				
Allograft group	30	30	30	18
Non-filling group	35	35	31	18
Last follow-up				
Allograft group	30	30	30	28
Non-filling group	35	35	35	30

**Table 4** Differences in Rates of Osteotomy Gap Union Between the Two Groups at Different Follow-Up Times After Surgery (n=65)

Group	The Rate of Osteotomy Gap Union (%)			
	Postoperative 3 Months	Postoperative 6 Months	Postoperative 12 Months	Last Follow-Up
Allograft group	37.23±5.28	56.39±7.01	81.72±8.89	93.08±5.93
Non-filling group	25.29±6.66	41.03±9.13	77.64±8.77	90.33±8.27
<i>t</i> -text	7.915	7.513	1.404	1.517
<i>p</i> -value	<0.001*	<0.001*	0.165	0.134

**Notes:** Values are presented as mean±SD deviation; \*Stands for a statistically significant difference.



**Table 5** Multiple Linear Regression Analysis of Factors Influencing Union Rate of Osteotomy at 6 Months Post-Operatively

Variable	Regression Coefficient	Standardized Coefficient b	t-text	p-value	Coefficient (95% CI)	
					Lower	Upper
Quantity	83.966	–	14.195	<0.001	72.137	95.794
Bone grafting ( $X_1$ )	–16.097	–0.72	–8.37	<0.001	–19.942	–12.251
Distraction height ( $X_2$ )	–1.66	–0.214	–2.496	0.015	–2.99	–0.33
Diabetes ( $X_3$ )	5.984	0.201	2.344	0.022	0.88	11.089

**Notes:** Assignment of qualitative variables: with or without bone void fillers (allogeneic bone grafting=1, non-filling=2); Diabetes (with diabetes=1, without diabetes=0); Quantitative variables are entered as original values.

**Table 6** Multiple Linear Regression Analysis of Factors Influencing Union Rate of Osteotomy at the Last Follow-Up

Variable	Regression Coefficient	Standardized Coefficient b	t-text	p-value	Coefficient (95% CI)	
					Lower	Upper
Quantity	114.884	–	19.279	<0.001	102.964	126.803
Diabetes history ( $X_1$ )	–9.954	–0.328	–3.138	0.003	–16.298	–3.610
BMI ( $X_2$ )	–0.650	–0.307	–3.052	0.003	–1.076	–0.224
Smoking history ( $X_3$ )	–4.273	–0.246	–2.404	0.019	–7.828	–0.717

**Notes:** Assignment of qualitative variables: Diabetes (with diabetes =1, without diabetes =0); Smoking history (smoking history = 1, no smoking history = 0); Quantitative variables are entered as original value.

## Influencing Factors of Gap Union Rate

Gender, age, surgical side, intraoperative osteotomy distraction height, BMI, smoking history, bone grafting, hypertension, and diabetes were independent variables, and a stepwise regression analysis was performed.

At 6 months post-operatively, the analysis of variance (ANOVA) revealed that the  $F$  value was 25.309 ( $P < 0.001$ ),  $R^2$  was 0.555, and the adjusted  $R^2$  was 0.533, indicating the model was statistically significant. Additionally, statistically significant effects of bone grafting ( $X_1$ ), distraction height ( $X_2$ ), and diabetes ( $X_3$ ) were shown on the rate of the osteotomy gap union. According to the regression coefficient, osteotomy healing of patients receiving allograft bone graft was faster than in patients without filling while holding all else constant. The greater the height of the osteotomy gap while holding all else constant, the lower the gap union rate. Furthermore, the union rate of patients with diabetes was worse compared to ordinary patients (Table 5).

At the last follow-up, the  $F$  value was 10.979 ( $P < 0.001$ ),  $R^2$  was 0.592, the adjusted  $R^2$  was 0.319, and the model was also statistically significant. In addition, statistically significant effects of BMI ( $X_1$ ), smoking history ( $X_2$ ), and diabetes history ( $X_3$ ) were also shown. According to the regression coefficient, the greater the BMI while holding all else constant, the smaller the union rate of the osteotomy gap. In addition, the union rate of patients with a history of smoking was relatively slow. The union rate of diabetic patients was also worse than that of ordinary patients, which was consistent with the results at 6 months post-operatively (Table 6).

## Discussion

Patients with varus knee deformity of the lower limb are prone to mild to moderate osteoarthritis in medial compartment of the knee joint due to the long-term shift of the weight-bearing line to the medial side. Under the premise of preserving the original structure of the knee joint, MOWHTO can accurately correct the lower limb alignment, adjust the main weight-bearing area to the lateral compartment of the knee joint, reduce the load-bearing burden of the medial cartilage, and delay the progression of osteoarthritis. In contrast, simple cleaning of knee joint is less traumatic, but it only limited relief of

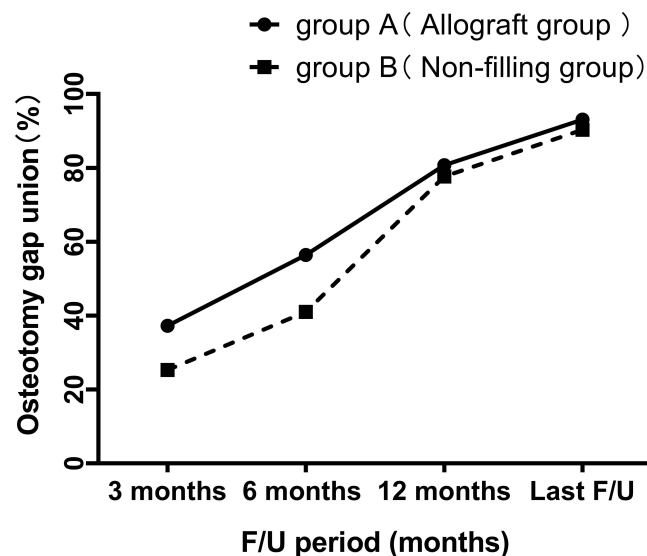
symptoms for a short period of time and could not solve the problem at its roots. Young and middle-aged patients often have higher requirements for daily knee activities and functions. UKA not only cannot preserve the original structure of the knee compartment, but also needs to consider that the prosthesis may require revision and restricts joint movement after surgery.<sup>21,22</sup> Although the postoperative recovery process is still longer than UKA and arthroscopic knee debridement. Patients with severe OA in the later stage of disease require total knee arthroplasty (TKA) to relieve symptoms and ensure quality of life. Previous follow-up studies have showed that TKA after MOWHTO not only has a lower probability of revision, but also has a higher long-term survival rate, compared to UKA after TKA.<sup>5</sup> UKA not only cannot preserve the original structure of the knee compartment, the possibility of prosthesis revision and the limitation of joint motion after surgery. This has become a major advantage of OWHTO in the later stages of OA.

In order to reduce the incidence of postoperative complications, improve the union speed of post-operative osteotomy gap and speed up the rehabilitation process, the improvements of bone graft filling treatment and graft type on union speed of post-operative osteotomy gap have attracted increasing attention. It has been reported that graft filling provides additional stability around the gap while altering the biomechanical mechanism of bone healing in the osteotomy gap, which increases the risk of delayed union.<sup>17,23</sup> Van Genechten et al showed that the graft provides additional stability to the osteotomy site, redistributes the axial load, shares the pressure on the locking screw and plate, and reduces post-operative pain.<sup>24</sup> Previous studies recommended bone graft filling for high-risk patients with large correction angles, severe obesity, heavy smoking history, and low bone mineral density.<sup>16,17,25</sup> In this study, we found that allogeneic bone graft, opening width, and history of diabetes were independent factors affecting the progress of early post-operative healing at 6 months post-surgery. At the last follow-up, the later post-operative union rate was delayed by higher BMI, smoking history, and diabetes history in both groups, which was consistent with the previous point. In contrast, the effect of allogeneic bone grafting on the later union rate was significantly decreased and failed to enter the model.

In order to improve the union speed of post-operative osteotomy gap and speed up the rehabilitation process, the improvements of bone graft filling treatment and graft type on union speed of post-operative osteotomy gap have attracted increasing attention. It has been reported that graft filling provides additional stability around the gap while altering the biomechanical mechanism of bone healing in the osteotomy gap, which increases the risk of delayed union.<sup>17,23</sup> Van Genechten et al showed that the graft provides additional stability to the osteotomy site, redistributes the axial load, shares the pressure on the locking screw and plate, and reduces post-operative pain.<sup>24</sup> Previous studies recommended bone graft filling for high-risk patients with large correction angles, severe obesity, heavy smoking history, and low bone mineral density.<sup>16,17,25</sup> In this study, we found that allogeneic bone graft, opening width, and history of diabetes were independent factors affecting the progress of early post-operative healing at 6 months post-surgery. At the last follow-up, the later postoperative union rate was delayed by higher BMI, smoking history and diabetes history in both groups, which was consistent with the previous point. In contrast, effect of allogeneic bone grafting on the later union rate was significantly decreased and failed to enter the model.

As far as the influencing factor of intraoperative distraction height is concerned, the number of existing studies focusing on low opening width is relatively small, which brings certain difficulties to the argumentation of this study. Aryee et al and Slevin et al concluded that bone grafting in the osteotomy gap with an opening width of < 10 mm could not improve clinical efficacy and union speed.<sup>17,26</sup> Zorzi et al hypothesized that the use of autologous bone graft in MOWHTO less than 12.5 mm is unnecessary.<sup>13</sup> Contrary, Meidinger et al suggested that filling of bone grafts in osteotomies with a height of < 10 mm for patients with high-risk factors (smoking, alcohol abuse, obesity, advanced age, etc.) might prevent delayed union, lateral hinge fractures, and loss of correction.<sup>18</sup> In this study, graft filling was performed at a height of < 10 mm, and the clinical efficacy (affected limb function and pain) and radiological union rate at 3 and 6 months post-operatively in the allograft groups were significantly better than those without bone grafting (Figure 4). Patients in the allogeneic group experienced less pain and had a faster union in the early post-operative period. In terms of post-operative complications, due to the small sample size and the influence of high-risk factors that cannot be excluded, it cannot be directly concluded that allograft filling can reduce the occurrence probability of lateral hinge fracture, correction loss and delayed union.

At present, autologous iliac bone, allogeneic bone block, and artificial synthetic bone represented by  $\beta$ -tricalcium phosphate ( $\beta$ -TCP) and porous hydroxyapatite (HA) are the main types of bone grafts. The tricortical iliac crest bone



**Figure 4** The radiological union rate between group A and group B at different periods.

derived from the anterior superior iliac spine is currently considered the “gold standard” for filling grafts due to its osteoconduction, osteoinduction, and osteogenesis-inducing properties.<sup>17,27</sup> However, a series of donor complications and prolonged duration of surgery caused by the collection of materials also brings additional concerns. Synthetic bone and allogeneic bone block have been associated with fewer donor complications.<sup>2,14,27</sup> However, the synthetic bone may retard healing due to the inconsistent absorption rates of different raw materials. Although allogeneic bone has potential risks of immune response and disease transmission, it is still widely used in OWHTO due to its excellent osteoconductivity and resorption rate.<sup>28</sup>

Although allogeneic bone increases the burden of surgical costs, it might help patients to carry out weight training immediately after surgery without worrying about the delayed union of lateral hinge fracture or internal plant fracture of plate screw compared with the scheme without using a graft to fill the gap. In addition, the allogeneic bone may allow for full weight bearing, prevent post-operative complications, improve post-operative clinical efficacy and the union speed of osteotomy gap, and minimize pain and discomfort associated with post-operative rehabilitation.<sup>29–32</sup> Notably, the volume of the long compression locking plate is larger than that of the internal fixation.<sup>23</sup> Some patients were more likely to develop symptoms of internal fixation irritation due to the thin coverage of the anteromedial tibia soft tissue and required removal of the plate in advance.<sup>10,20</sup> Accelerating the union progress of the osteotomy gap in the early stage also provides the possibility for removing internal fixation in the later stage.

This study has several limitations. Firstly, this is a retrospective cohort study with a small sample size. Second, the location of the union zone in the osteotomy gap and the measurement of the union rate could not be confirmed by comparison with sagittal CT radiographs. Finally, this study merely analyzed the mid-term follow-up results, and the long-term follow-up, including removal of internal fixation, remains to be observed.

## Conclusion

MOWHTO was used to treat medial compartment osteoarthritis of the knee with varus deformity (the opening width of the osteotomy gap was less 10 mm). Filling the gaps with the allograft bones may accelerate the union speed of the osteotomy gap, improve clinical outcomes at 3 months and 6 months post-operatively, promote early functional exercise and rehabilitation of patients, and reduce the impact of osteotomy on patients. However, bone grafting could not affect the final rate of osteotomy gap union and clinical scores.

## Acknowledgments

This work was supported by “the Fundamental Research Funds for the Central Universities” (WK9110000143).

## Disclosure

The authors report no conflicts of interest in this work.

## References

- Liu X, Chen Z, Gao Y, Zhang J, Jin Z. High tibial osteotomy: review of techniques and biomechanics. *J Healthc Eng.* 2019;2019:8363128. doi:10.1155/2019/8363128
- Santic V, Tudor A, Sestan B, Legovic D, Sirola L, Rakovac I. Bone allograft provides bone healing in the medial opening high tibial osteotomy. *Int Orthop.* 2010;34(2):225–229. doi:10.1007/s00264-009-0916-9
- Ollivier B, Berger P, Depuydt C, Vandenneucker H. Good long-term survival and patient-reported outcomes after high tibial osteotomy for medial compartment osteoarthritis. *Knee Surg Sports Traumatol Arthrosc.* 2021;29(11):3569–3584. doi:10.1007/s00167-020-06262-4
- DeMeo PJ, Johnson EM, Chiang PP, Flamm AM, Miller MC. Midterm follow-up of opening-wedge high tibial osteotomy. *Am J Sports Med.* 2010;38(10):2077–2084. doi:10.1177/0363546510371371
- Cho WJ, Kim JM, Kim WK, Kim DE, Kim NK, Bin SI. Mobile-bearing unicompartmental knee arthroplasty in old-aged patients demonstrates superior short-term clinical outcomes to open-wedge high tibial osteotomy in middle-aged patients with advanced isolated medial osteoarthritis. *Int Orthop.* 2018;42(10):2357–2363. doi:10.1007/s00264-018-3880-4
- Belsey J, Yaseen SK, Jobson S, Faulkner J, Wilson AJ. Return to physical activity after high tibial osteotomy or unicompartmental knee arthroplasty: a systematic review and pooling data analysis. *Am J Sports Med.* 2021;49(5):1372–1380. doi:10.1177/0363546520948861
- Lee SH, Seo HY, Lim JH, Kim MG, Seon JK. Higher survival rate in total knee arthroplasty after high tibial osteotomy than that after unicompartmental knee arthroplasty. *Knee Surg Sports Traumatol Arthrosc.* 2021. doi:10.1007/s00167-021-06641-5
- Cofaru II, Oleksik M, Cofaru NF, et al. A computer-assisted approach regarding the optimization of the geometrical planning of medial opening wedge high tibial osteotomy. *Applied Sciences.* 2022;12(13):6636. doi:10.3390/app12136636
- Cofaru NF, Oleksik V, Cofaru II, et al. Geometrical planning of the medial opening wedge high tibial osteotomy—an experimental approach. *Applied Sciences.* 2022;12(5):2475. doi:10.3390/app12052475
- Sidhu R, Moatshe G, Firth A, Litchfield R, Getgood A. Low rates of serious complications but high rates of hardware removal after high tibial osteotomy with tomofix locking plate. *Knee Surg Sports Traumatol Arthrosc.* 2021;29(10):3361–3367. doi:10.1007/s00167-020-06199-8
- Brosset T, Pasquier G, Migaud H, Gougeon F. Opening wedge high tibial osteotomy performed without filling the defect but with locking plate fixation (TomoFix) and early weight-bearing: prospective evaluation of bone union, precision and maintenance of correction in 51 cases. *Orthop Traumatol Surg Res.* 2011;97(7):705–711. doi:10.1016/j.otsr.2011.06.011
- Kim SC, Kim DH, Lee JI, Kim TW, Lee YS. Comparative analysis of serial union patterns after opening-wedge high tibial osteotomy with and without bone-void fillers. *Journal of Bone and Joint Surgery American.* 2021;103(19):1788–1797. doi:10.2106/JBJS.20.00778
- Zorzi AR, da Silva HG, Muszkat C, Marques LC, Cliquet A Jr, de Miranda JB. Opening-wedge high tibial osteotomy with and without bone graft. *Artif Organs.* 2011;35(3):301–307. doi:10.1111/j.1525-1594.2010.01058.x
- Lee OS, Lee KJ, Lee YS. Comparison of bone healing and outcomes between allogeneous bone chip and hydroxyapatite chip grafts in open wedge high tibial osteotomy. *J Mater Sci Mater Med.* 2017;28(12):189. doi:10.1007/s10856-017-5998-0
- Kim HJ, Seo I, Shin JY, Lee KS, Park KH, Kyung HS. Comparison of bone healing in open-wedge high tibial osteotomy between the use of allograft bone chips with autologous bone marrow and the use of allograft bone chips alone for gap filling. *J Knee Surg.* 2020;33(6):576–581. doi:10.1055/s-0039-1681093
- Fucentese SF, Tscholl PM, Sutter R, Brucker PU, Meyer DC, Koch PP. Bone autografting in medial open wedge high tibial osteotomy results in improved osseous gap healing on computed tomography, but no functional advantage: a prospective, randomised, controlled trial. *Knee Surg Sports Traumatol Arthrosc.* 2019;27(9):2951–2957. doi:10.1007/s00167-018-5285-8
- Slevin O, Ayeni OR, Hinterwimmer S, Tischer T, Feucht MJ, Hirschmann MT. The role of bone void fillers in medial opening wedge high tibial osteotomy: a systematic review. *Knee Surg Sports Traumatol Arthrosc.* 2016;24(11):3584–3598. doi:10.1007/s00167-016-4297-5
- Meidinger G, Imhoff AB, Paul J, Kirchoff C, Sauerschnig M, Hinterwimmer S. May smokers and overweight patients be treated with a medial open-wedge HTO? Risk factors for non-union. *Knee Surg Sports Traumatol Arthrosc.* 2011;19(3):333–339. doi:10.1007/s00167-010-1335-6
- Goshima K, Sawaguchi T, Shigemoto K, et al. Large opening gaps, unstable hinge fractures, and osteotomy line below the safe zone cause delayed bone healing after open-wedge high tibial osteotomy. *Knee Surg Sports Traumatol Arthrosc.* 2019;27(4):1291–1298. doi:10.1007/s00167-018-5334-3
- Goshima K, Sawaguchi T, Shigemoto K, Iwai S, Fujita K, Kataoka T. Plate removal without loss of correction after open-wedge high tibial osteotomy is possible when posterior cortex bone union reaches osteotomy gap center even in incompletely filled gaps. *Knee Surg Sports Traumatol Arthrosc.* 2020;28(6):1827–1834. doi:10.1007/s00167-019-05615-y
- Jung WH, Takeuchi R, Kim DH, Nag R. Faster union rate and better clinical outcomes using autologous bone graft after medial opening wedge high tibial osteotomy. *Knee Surg Sports Traumatol Arthrosc.* 2020;28(5):1380–1387. doi:10.1007/s00167-019-05463-w
- Takeuchi R, Ishikawa H, Kumagai K, et al. Fractures around the lateral cortical hinge after a medial opening-wedge high tibial osteotomy: a new classification of lateral hinge fracture. *Arthroscopy.* 2012;28(1):85–94. doi:10.1016/j.arthro.2011.06.034
- Stoffel K, Stachowiak G, Kuster M. Open wedge high tibial osteotomy: biomechanical investigation of the modified arthrex osteotomy plate (puddu plate) and the TomoFix plate. *Clin Biomech.* 2004;19(9):944–950. doi:10.1016/j.clinbiomech.2004.06.007
- Van Genechten W, Van den Bempt M, Van Tilborg W, et al. Structural allograft impaction enables fast rehabilitation in opening-wedge high tibial osteotomy: a consecutive case series with one year follow-up. *Knee Surg Sports Traumatol Arthrosc.* 2020;28(12):3747–3757. doi:10.1007/s00167-019-05765-z
- Cho SW, Kim DH, Lee GC, Lee SH, Park SH. Comparison between autogenous bone graft and allogeneous cancellous bone graft in medial open wedge high tibial osteotomy with 2-year follow-up. *Knee Surg Relat Res.* 2013;25(3):117–125. doi:10.5792/ksrr.2013.25.3.117
- Aryee S, Imhoff AB, Rose T, Tischer T. Do we need synthetic osteotomy augmentation materials for opening-wedge high tibial osteotomy. *Biomaterials.* 2008;29(26):3497–3502. doi:10.1016/j.biomaterials.2008.05.027

27. Haghpanah B, Kaseb MH, Espandar R, Mortazavi SMJ. No difference in union and recurrence rate between iliac crest autograft versus allograft following medial opening wedge high tibial osteotomy: a randomized controlled trial. *Knee Surg Sports Traumatol Arthrosc.* 2021;29(10):3375–3381. doi:10.1007/s00167-020-06240-w
28. Lee DY, Lee MC, Ha CW, et al. Comparable bone union progression after opening wedge high tibial osteotomy using allogeneous bone chip or tri-calcium phosphate granule: a prospective randomized controlled trial. *Knee Surg Sports Traumatol Arthrosc.* 2019;27(9):2945–2950. doi:10.1007/s00167-018-5254-2
29. Takeuchi R, Ishikawa H, Aratake M, et al. Medial opening wedge high tibial osteotomy with early full weight bearing. *Arthroscopy.* 2009;25(1):46–53. doi:10.1016/j.arthro.2008.08.015
30. Takeuchi R, Aratake M, Bito H, et al. Clinical results and radiographical evaluation of opening wedge high tibial osteotomy for spontaneous osteonecrosis of the knee. *Knee Surg Sports Traumatol Arthrosc.* 2009;17(4):361–368. doi:10.1007/s00167-008-0698-4
31. Lee OS, Ahn S, Lee YS. Effect and safety of early weight-bearing on the outcome after open-wedge high tibial osteotomy: a systematic review and meta-analysis. *Arch Orthop Trauma Surg.* 2017;137(7):903–911. doi:10.1007/s00402-017-2703-1
32. Schroter S, Mueller J, van Heerwaarden R, Lobenhoffer P, Stockle U, Albrecht D. Return to work and clinical outcome after open wedge HTO. *Knee Surg Sports Traumatol Arthrosc.* 2013;21(1):213–219. doi:10.1007/s00167-012-2129-9

## Therapeutics and Clinical Risk Management

Dovepress

### Publish your work in this journal

Therapeutics and Clinical Risk Management is an international, peer-reviewed journal of clinical therapeutics and risk management, focusing on concise rapid reporting of clinical studies in all therapeutic areas, outcomes, safety, and programs for the effective, safe, and sustained use of medicines. This journal is indexed on PubMed Central, CAS, EMBase, Scopus and the Elsevier Bibliographic databases. The manuscript management system is completely online and includes a very quick and fair peer-review system, which is all easy to use. Visit <http://www.dovepress.com/testimonials.php> to read real quotes from published authors.

Submit your manuscript here: <https://www.dovepress.com/therapeutics-and-clinical-risk-management-journal>