

The Effect of Internal Mesh Fixation and External Fixation (Inguinal Hernia Truss) on Postoperative Complications in Patients with Inguinal Hernia Undergoing Totally Extraperitoneal Laparoscopic Hernioplasty

Abstract

Background: The present study evaluated the effect of internal mesh fixation and external fixation (inguinal hernia truss) on postoperative complications in patients with inguinal hernia. **Materials and Methods:** This randomized clinical trial was performed on 64 patients that were candidates for inguinal hernia repair by laparoscopic method following the totally extraperitoneal procedure. These patients were randomly divided into two groups. In the first group, the mesh was fixed with a maximum of three absorbable tacks. In the second group, the inguinal hernia truss was used as the external fixation for 6 weeks immediately after the surgery. **Results:** The results revealed that seroma, neuralgia, and recurrence were observed with the values of 6.4%, 19.4%, and 3.2% in Group A and 3.3%, 13.3%, and 3.3% in Group B ($P > 0.05$). Moreover, patients' pain scores 1 week and 1 month after the surgery in Group B were significantly lower than those of Group A ($P < 0.05$). However, the mean pain score of patients was not different between the two groups 3 and 6 months after the surgery ($P > 0.05$). Furthermore, the duration of return to work in Group B with an average of 8.07 ± 3.09 days was less than that of Group A with the average of 9.65 ± 5.34 days ($P > 0.05$). **Conclusion:** The mentioned findings can trigger the use of external fixation and an inguinal hernia truss as a support for the abdominal wall to make the dream of not using a foreign body in the human body come true.

Keywords: Fixation, Hernioplasty, Inguinal Hernia, Laparoscopy, Mesh

Masoud Sayadi
Shahraki,
Mohsen
Mahmoudieh,
Behrooz Keleidari,
Hamid Melali,
Zakaria Sharbu

Department of Surgery and
Laparoscopic Surgery, School of
Medicine, Isfahan University of
Medical Sciences, Isfahan, Iran

Introduction

Hernia is one of the most common surgeries. Approximately one million hernia repair surgeries, of which about 800,000 are for inguinal hernia repair, are performed annually in the United States.^[1,2] It is estimated that 70% of abdominal wall defects are due to inguinal hernia, which has a risk of 27% in men and 3% in women throughout life.^[3]

Various techniques have been introduced to repair inguinal hernias since about 1887. However, at present, there are only three methods of tissue – suture repair, flat mesh repair, and laparoscopic methods with transabdominal preperitoneal approach or totally extraperitoneal procedure (TEP) approach using mesh, which are acceptable in terms of the evidence-based treatments.^[4-7]

Two issues should be considered in this regard as follows: The first is the use or

nonuse of the mesh and the second is the fixation or nonfixation of the mesh. Certainly, the use of mesh can be more effective and successful than the nonuse of mesh from many surgeons' perspective as the mesh hernia repair strengthens the tissues of the abdominal wall and can also be absorbed in the body. First, the nonmesh hernia repair requires an extensive training and experience to achieve an accurate and successful closure of the abdominal wall tissue. Secondly, the nonuse of mesh increases the likelihood of its recurrence.^[8-10] In addition, although the nonfixation of the mesh can reduce pain in patients, it can lead to infection and increase the recurrence due to the possibility of mesh displacement.^[11,12] Furthermore, the hernia recurrence in mesh fixation method is significantly less than the nonfixation method; however, mesh fixation increases pain after surgery and is associated with the risk of nerve damage. Therefore, one of the challenges during

Address for correspondence:

Dr. Zakaria Sharbu,
Department of Laparoscopic
Surgery, Isfahan University of
Medical Sciences, Isfahan, Iran.
E-mail: dr.zsharbu82@gmail.
com

Received: 26 May 2021
Revised: 08 June 2021
Accepted: 16 June 2021
Published: 29 June 2022

Access this article online

Website: www.advbiores.net

DOI: 10.4103/abr.abr_140_21

Quick Response Code:



How to cite this article: Sayadi Shahraki M, Mahmoudieh M, Keleidari B, Melali H, Sharbu Z. The effect of internal mesh fixation and external fixation (inguinal hernia truss) on postoperative complications in patients with inguinal hernia undergoing totally extraperitoneal laparoscopic hernioplasty. *Adv Biomed Res* 2022;11:49.

This is an open access journal, and articles are distributed under the terms of the Creative Commons Attribution-NonCommercial-ShareAlike 4.0 License, which allows others to remix, tweak, and build upon the work non-commercially, as long as appropriate credit is given and the new creations are licensed under the identical terms.

For reprints contact: WKHLRPMedknow_reprints@wolterskluwer.com

surgery is mesh fixation, which should be strong enough to prevent the recurrence and have the lowest risk of tissue and nerve damage.^[13]

Now, one question may pop on in surgeons' mind regarding the possibility of supporting the abdominal wall and compensating for the lack of internal mesh fixation using an external support or fixer such as a inguinal hernia truss. In this regard, one of the external tools supporting the abdominal wall is the inguinal hernia truss, which is mostly used in cases where there is a long waiting time before the date of surgery. In fact, as the inguinal hernia truss has been used before surgery, the patient is entirely acquainted with its use, which will probably be associated with less pain.

To put in a nut shell, it should be taken into consideration that surgical techniques and surgeon's skills are influential in performing mesh fixation appropriately; fixation method in comparison with the nonfixation method can be more painful for the patient; there is still no effective material for the mesh; there is no correct method of using and fixing the mesh; and the nonuse of abdominal wall support such as mesh or inguinal hernia truss can be associated with the high recurrence rate of the hernia. Therefore, it may be possible to achieve a method that is as effective as the mesh fixation method without mesh fixation and with the help of the inguinal hernia truss as an external fixer after surgery. The mentioned point has received Iranian surgeons' due attention for the first time in the world. Therefore, the present study was performed with the aim of examining the effect of internal mesh fixation and the use of external fixation (inguinal hernia truss) on postoperative complications in patients with inguinal hernia undergoing laparoscopic hernioplasty.

Materials and Methods

The present study was a single-blind randomized clinical trial. The study population included all patients that were candidates for inguinal hernia repair using the laparoscopic methods in Al-Zahra Hospital during April 2020 to April 2021. The sample size of 64 patients (32 patients in each group) were selected from the mentioned population using the simple random sampling at the confidence level of 95%, the test power of 80%, the recurrence probability of 2.9%,^[9] and the error level of 0.2. Inclusion criteria were patients with inguinal hernia that were aged 18–50 years, had no history of hernia repair surgery and history of laparotomy, had no strangulated, incarcerated scrotal or femoral hernia, and consented to participate in the study. In addition, the patients were excluded from the study in case of the cancellation of surgery for any reasons or the occurrence of unwanted complications during surgery that might lead to serious complications or the death of the patient, the patient's nonreferral for follow-up after surgery for various reasons, or the patients' dissatisfaction to continue their cooperation in the present study.

After obtaining the code of ethics from the Ethics Committee of Isfahan University of Medical Sciences (IR.MUI. MED. REC.1399.825), the clinical trial code (IRCT20200825048515N25), and written consent from eligible patients, their demographic information such as age, weight, the past drug history, the past medical history, the type of hernia, the side of hernia (unilateral, bilateral), the duration of surgery (from skin incision to skin suture), and the length of hospital stay were recorded. Then, the patients were divided into two groups of 32 using random allocation software.

Both groups underwent hernioplasty surgery following the TEP under general anesthesia. In the TEP repair, first a 2 cm skin incision was performed in the lateral umbilicus toward the hernia. Then, the subcutaneous tissue was gently dissected with a clamp. In case of necessity, a Foley catheter balloon was used for dissection. A no. 11 bisturi was used to incise the fascia on the rectus muscle, and the dissection was performed. The muscle was placed on the posterior fascia after dissection. Muscle dissection was continued to the pubic symphysis to provide adequate space for other trocars. Moreover, the pressure of CO₂ gas was not more than 12 mmHg. A 10-mm trocar was placed in this area, and a 5 mm trocar was placed 4–5 cm above the pubic symphysis. In addition, another 5 mm trocar was placed in the midline between the mentioned two trocars. At this stage, the lower part of the rectus fascia was examined, and the fascial defect, which is related to the extraperitoneal space, was examined as well. The hernia sac along with its contents was pushed into the abdomen and placed in the defective mesh area, and the trocar was removed with air.

In the first group (Group A), the mesh was fixed with a maximum of three absorbable tacks (above pubic symphysis, lateral epigastric vessels, and near anterior superior iliac spine such that an extralarge mesh (Bard 3D Max) was used in the inguinal hernia repair based on the hernia defect, hernia space, and dissection of the hernia site. In the second group (Group B), the mesh was not fixed; however, the inguinal hernia truss (Paksaman company) was used as the external fixation immediately after surgery. After surgery, the patient was advised to use the inguinal hernia truss continuously for 6 weeks. Moreover, patients in both groups were recommended to avoid moving objects weighing more than 5 kg.

It should be mentioned that one patient in Group A was excluded from the study due to the nonreferral for the follow-up, and two patients in Group B (one due to the nonuse of external hernia truss continuously and one due to the nonreferral for follow-up) were excluded from the study [Figure 1].

Patients' pain level in both groups was assessed according to the visual analog scale criteria in the first 24 h after the surgery, 1 week, and 1, 3, and 6 months after the surgery.

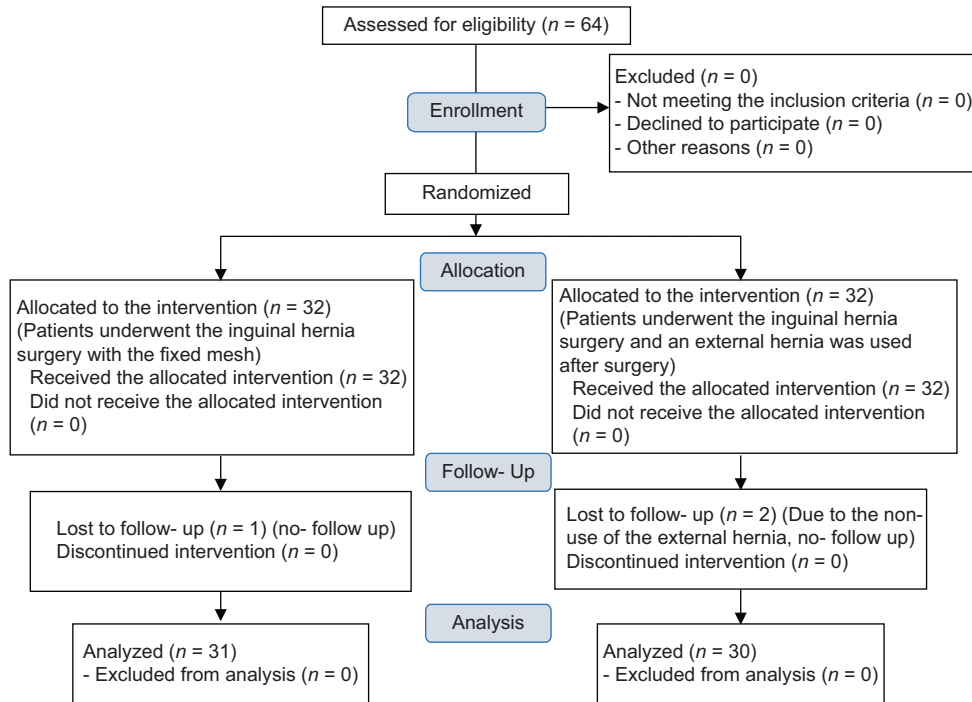


Figure 1: Consort flowchart of patients

In addition, the incidence of early and late complications including seroma, hematoma, urinary tract infection, wound infection, mesh infection, urinary retention, neuralgia, and recurrence were examined as well.

Finally, the collected data were entered into SPSS software (version 26; SPSS Inc., Chicago, Ill., USA). According to the result of Kolmogorov–Smirnov test indicating the normal distribution of data, the independent samples *t*-test, repeated measures ANOVA, Chi-square test, and Fisher’s exact test were used. The significance level of <0.05 was considered in all analyses.

Results

In the present study, the mean age of patients in the mesh fixation Group (A) and the external fixation Group (B) was equal to 42.23 ± 12.43 and 47.63 ± 14.27 years, respectively (*P* > 0.05). The mentioned groups did not differ significantly in terms of the type of hernia, side of hernia involvement, comorbidities, surgery duration, and length of hospital stay (*P* > 0.05) [Table 1].

Intraoperative and postoperative complications

Intraoperative complications, complications of hematoma, urinary retention, and wound infection 1 week and 1 month after the surgery, and the mesh infection in long-term follow-up were not observed in either group. In contrast, early (1 week after the surgery) and late (1, 3, and 6 months after the surgery) complications included seroma 6.4%, neuralgia 19.4%, and recurrence 3.2% in Group A and seroma 3.3%, neuralgia 13.3%, and recurrence 3.3% in Group B. There was no significant

Characteristics	Group A (n=31)	Group B (n=30)	<i>P</i>
Age (year)	42.23±12.43	47.63±14.27	0.120
Weight (kg)	49.51±9.02	50.87±8.30	0.189
Past medical history, <i>n</i> (%)			
DM	2 (6.5)	1 (3.3)	0.291
HLP	1 (3.2)	0	
IHD	1 (3.2)	4 (13.3)	
HTN	2 (6.5)	3 (10)	
BPH	0	1 (3.3)	
Past drug history, <i>n</i> (%)			
ASA	1 (3.2)	3 (10)	0.306
Losartan	3 (9.7)	1 (3.3)	
Metformin	2 (6.5)	0	
Clonazepam	0	1 (3.3)	
Insulin	0	1 (3.3)	
Side of hernia			
Unilateral	20 (64.5)	20 (66.7)	0.860
Bilateral	11 (35.5)	10 (33.3)	
Sub-classification of inguinal hernias, <i>n</i> (%)			
Direct	6 (19.4)	9 (30)	0.334
Indirect	25 (80.6)	21 (70)	
Surgery duration, (min)	50.00±19.58	51.50±28.86	0.182
Length of hospital stay, (day)	1.06±0.25	1.10±0.55	0.745

DM: Diabetes mellitus, HLP: Hyperlipidemia, IHD: Ischemic heart disease, HTN: Hypertension, BPH: Benign prostatic hyperplasia, ASA: Acetylsalicylic acid

difference in the incidence of complications between the two groups (*P* > 0.05) [Table 2].

Postoperative pain, chronic pain, and return to work

The first 24-h postoperative pain score had no significant difference between the two groups ($P = 0.082$); however, the pain scores 1 week and 1 month after the surgery in Group A with the means of 5.29 ± 1.99 and 3.45 ± 2.85 were significantly higher than those of Group B with the means of 3.90 ± 2.34 and 1.93 ± 2.42 , respectively ($P < 0.05$). However, the level of pain intensity did not differ significantly between the two Groups 3 and 6 months after the surgery ($P > 0.05$). In fact, generally, it can be stated that the pain score in Group A was higher than that of Group B; however, a significant decrease was observed in patient's pain score over time in both groups ($P < 0.001$). Moreover, the mean duration of return to work in Groups A and B was equal to 9.65 ± 5.34 and 8.07 ± 3.09 days, respectively ($P > 0.05$) [Table 3].

Discussion

In the present study, the mean age of patients in both groups was more than 40 years. Moreover, the frequency of indirect inguinal hernia was more than the direct type. In addition, the two groups did not differ significantly in terms of basic and clinical characteristics such as age, past drug history, past medical history, subclassification of inguinal hernia, and the side of hernia.

In this regard, previous reports have stated that this disorder is more common in childhood and over 50 years of age.^[14] Furthermore, the indirect inguinal hernia is also two to three times more common than the direct type.^[15]

In addition, no complications occurred during the surgery, and no postoperative complications such as hematoma, urinary retention, and wound infection were reported.

Table 2: Postoperative complications in two groups

Postoperative complication	Group A (n=31), n (%)	Group B (n=30), n (%)	P
Seroma	2 (6.4)	1 (3.3)	0.524
Wound infection	0	0	-
Hematoma	0	0	-
Neuralgia	6 (19.4)	4 (13.3)	0.525
Recurrence	1 (3.2)	1 (3.3)	0.981

Table 3: Comparison of the mean of postoperative pain, chronic pain, and return to work between the two groups

Pain and return to work	Group A (n=31)	Group B (n=30)	P
Return to work, day	9.65 ± 5.34	8.07 ± 3.09	0.163
At 1 st day	6.74 ± 2.53	5.50 ± 2.94	0.082
At 1 st week	5.29 ± 1.99	3.90 ± 2.34	0.015
At 1 st month	3.45 ± 2.85	1.93 ± 2.42	0.029
At 3 rd month	2.06 ± 2.42	1.00 ± 1.86	0.059
At 6 th month	1.03 ± 1.58	0.53 ± 1.27	0.181
P	<0.001	<0.001	

Similarly, mesh infection was not reported in the long-term follow-up in either group. In contrast, neuralgia and seroma had the highest frequency as the early and late complications of this surgery, respectively. Moreover, both groups had about 3% of recurrence. It should be mentioned that although the mesh fixation method was not used for Group B, the incident rates of seroma and neuralgia in Group B were lower than those of Group A using the mesh fixation method. In fact, it can be stated that the use of external fixation (hernia truss) can be associated with less complications than internal mesh fixation, although this difference was not significant between the two groups and no difference was observed between the two groups in terms of the hernia recurrence.

According to previous studies, surgical treatments for inguinal hernia are not without complications and one of the most common and serious complications after surgery is the hernia recurrence.^[16] Previous studies have reported the recurrence rate of hernia after surgery to be 11%–33% and the recurrence rate after the hernia recurrence repair to be 11.7%–30%.^[17-19]

In addition, the results of Singhal *et al.*'s study revealed that the recurrence rate of inguinal hernia following mesh fixation is much lower than open hernia repair methods.^[20] Many previous studies have indicated that one of the factors that can reduce the recurrence rate is the appropriate mesh fixation, and the most reported morbidity after the surgery is related to the displacement of the mesh and its infection.^[13] In contrast, many previous studies have reported that the incidence of postoperative complications was not significant between the two methods of mesh fixation and nonfixation.^[8,9,21,22] Moreover, some other studies have reported that the rate risk of the incidence of complications in the fixation group was far more than that of the nonfixation group.^[11] Therefore, it seems that there is still no consensus on the use of mesh or its fixation and the mentioned point has remained a controversial issue.

Furthermore, Desarda used the no-mesh inguinal hernia repair with continuous absorbable sutures, followed-up the patients for 6–42 months, and revealed that more than 94% of patients had mild pain for 2 days. In addition, only four minor complications were reported, and patients had no recurrent hernia or chronic pain. In fact, they indicated that a satisfactory result without recurrence can be obtained in open surgeries without the use of mesh following the method of continuous absorbable sutures. In the mentioned study, they made the dream of every surgeon regarding the inguinal hernia repair without recurrence without leaving a foreign body inside the patients' body come true.^[23]

Although they have used open surgery, what is certain is that laparoscopic surgeries have many advantages over open surgeries. Moreover, we used an external abdominal wall support tool as an external fixation in our study. It is worth noting that, as the inguinal hernia truss is usually

used before surgery, patients are completely cognizant of how to use it and their encouragement to its correct and consistent use is not impossible or challenging. Therefore, the results of this study may be considered as a flip for other surgeons in using and evaluating this approach.

After a hernia recurrence, another important factor that surgeons seek to minimize is the patients' pain because patients' return to work and daily life happens faster by reducing their pain. In the present study, a significant decrease in the level of pain intensity was observed in both groups over time. Moreover, the comparison between groups indicated that there was not a significant difference between the two groups in terms of the pain in the first 24 h after the surgery. However, the pain score in Group B was significantly lower than that of Group A 1 week and 1 month after the surgery. Moreover, the two groups' pain scores did not differ significantly 3 and 6 months after surgery. In addition, the mean duration of return to work in Group B was significantly less than that of Group A.

Factors that cause postoperative pain include the stimulation of the femoral nerve by the mesh or stitches, inflammatory reactions around the mesh, or fibrosis in the thigh area, into which the femoral nerves also enter. This problem may be due to the inflammation of the regional tissue against the foreign body, biological incompatibility.^[24] Therefore, the nonfixation of the mesh can reduce the pain, but theoretically, it is a predisposing factor for hernia recurrence due to the nonuse or nonfixation of mesh. Therefore, we tried to avoid using the mesh and its fixation by employing the inguinal hernia truss as an external fixation and a support for the abdominal wall and achieved satisfactory results so that the patients' pain in the nonfixation group was significantly lower than the mesh fixation group 1 week and 1 month after the surgery.

It should be noted that inguinal hernia truss has various types, and their applications are different in men and women. As all patients in this study were male, a bilateral inguinal hernia belt was used. The mentioned belt is most commonly used for men and is used to remove the protrusions seen in the groin area as well as inside the scrotum. Therefore, it should be taken into consideration that the selection of a suitable inguinal hernia truss can also play a significant role in the results of the study. Hence, the different and new perspective of this study regarding this surgery and the use of external postoperative fixation can be regarded as the strengths of the present study although this study was conducted as an initial and pilot study. It is essential to conduct further studies with larger samples to present more reliable results that are generalizable to the population.

Conclusion

According to the results of the present study, although the incidence of complications such as seroma and neuralgia

in the internal mesh fixation group was higher than the external fixation (inguinal hernia truss) group after surgery, in general, the two groups did not differ significantly in terms of the incidence of complications. Moreover, the incidence rate of recurrence was the same in the two groups. In addition, the patients' pain scores 1 week and 1 month after the surgery as well as the duration of return to work in the external fixation (inguinal hernia truss) group was significantly less than those of the internal mesh fixation group.

Financial support and sponsorship

Nil.

Conflicts of interest

There are no conflicts of interest.

References

1. Bruns NE, Glenn IC, McNinch NL, Rosen MJ, Ponsky TA. Treatment of routine adolescent inguinal hernia vastly differs between pediatric surgeons and general surgeons. *Surg Endosc* 2017;31:912-6.
2. Howard R, Thompson M, Fan Z, Englesbe M, Dimick JB, Telem DA. Costs associated with modifiable risk factors in ventral and incisional hernia repair. *JAMA Netw Open* 2019;2:e1916330.
3. Castorina S, Luca T, Privitera G, El-Bernawi H. An evidence-based approach for laparoscopic inguinal hernia repair: Lessons learned from over 1,000 repairs. *Clin Anat* 2012;25:687-96.
4. Majeed LQ, Surriah MH, Bakkour AM, Saaid AM. The use of prosthetic mesh in adult inguinal hernia repair. *Int Surg J* 2019;6:1745-9.
5. Białocki JT, Myszka W, Wysocka E, Sowier S, Pyda P, Antkowiak R, *et al.* A comparison of the oxidative stress response in single-incision laparoscopic versus multi-trocar laparoscopic totally extraperitoneal inguinal hernia repair. *Wideochir Inne Tech Maloinwazyjne* 2020;15:567-73.
6. Scheuermann U, Niebisch S, Lyros O, Jansen-Winkeln B, Gockel I. Transabdominal Preperitoneal (TAPP) versus Lichtenstein operation for primary inguinal hernia repair – A systematic review and meta-analysis of randomized controlled trials. *BMC Surg* 2017;17:55.
7. Darwish AA, Hegab AA. Tack fixation versus nonfixation of mesh in laparoscopic transabdominal preperitoneal hernia repair. *Egypt J Surg* 2016;35:327.
8. Lockhart K, Dunn D, Teo S, Ng JY, Dhillon M, Teo E, *et al.* Mesh versus non-mesh for inguinal and femoral hernia repair. *Cochrane Database Syst Rev* 2018;9:CD011517.
9. Abd-Raboh OH, Hablus MA, Elshora AA, Saber SA. Comparative study between mesh fixation vs. non-fixation in totally extraperitoneal hernioplasty for inguinal Hernia. *J Surg* 2018;6:23-8.
10. Elango S, Perumalsamy S, Ramachandran K, Vadodaria K. Mesh materials and hernia repair. *BioMedicine* 2017;7:14-23.
11. Sajid MS, Ladwa N, Kalra L, McFall M, Baig MK, Sains P. A meta-analysis examining the use of tacker mesh fixation versus glue mesh fixation in laparoscopic inguinal hernia repair. *Am J Surg* 2013;206:103-11.
12. Köckerling F, Jacob DA, Chowbey P, Lomanto D. A meta-analysis examining the use of tacker fixation versus

- no-fixation of mesh in laparoscopic inguinal hernia repair. *Int J Surg* 2012;10:325.
13. Andresen K, Fenger AQ, Burcharth J, Pommergaard HC, Rosenberg J. Mesh fixation methods and chronic pain after transabdominal preperitoneal (TAPP) inguinal hernia surgery: a comparison between fibrin sealant and tacks. *Surgical endoscopy*. 2017;31:4077-84.
 14. Zinner MJ, Ashley SW. *Maingot's Abdominal Operations*. New York: McGraw Hill Professional; 2012.
 15. Tavassoli A, Ghamari MJ, Esmaily H. Repair of inguinal hernia: A comparison between extraperitoneal laparoscopy and Lichtenstein open surgery. *Tehran Univ Med J* 2010;68:168-174.
 16. Nienhuijs S, Staal E, Strobbe L, Rosman C, Groenewoud H, Bleichrodt R. Chronic pain after mesh repair of inguinal hernia: A systematic review. *Am J Surg* 2007;194:394-400.
 17. Bisgaard T, Bay-Nielsen M, Kehlet H. Re-recurrence after operation for recur-rent inguinal hernia. A nationwide 8-year follow-up study on the role of type of repair. *Ann Surg* 2008;247:707-11.
 18. Li J, Ji Z, Li Y. Comparison of laparoscopic versus open procedure in the treat-ment of recurrent inguinal hernia: A meta-analysis of the results. *Am J Surg* 2014;207:602-12.
 19. Magnusson N, Nordin P, Hedberg M, Gunnarsson U, Sandblom G. The time profile of groin hernia recurrences. *Hernia* 2010;14:341-4.
 20. Singhal V, Szeto P, VanderMeer TJ, Cagir B. Ventral hernia repair: Outcomes change with long-term follow-up. *JLS* 2012;16:373-9.
 21. Kalidarei B, Mahmoodieh M, Sharbu Z. Comparison of mesh fixation and nonfixation in laparoscopic transabdominal preperitoneal repair of inguinal hernia. *Formos J Surg* 2019;52:212.
 22. Tam KW, Liang HH, Chai CY. Outcomes of staple fixation of mesh versus nonfixation in laparoscopic total extraperitoneal inguinal repair: A meta-analysis of randomized controlled trials. *World J Surg* 2010;34:3065-74.
 23. Desarda MP. No-mesh inguinal hernia repair with continuous absorbable sutures: A dream or reality? (A study of 229 patients). *Saudi J Gastroenterol* 2008;14:122-7.
 24. Bona S, Rosati R, Opocher E, Fiore B, Montorsi M, SUPERMESH Study Group. Pain and quality of life after inguinal hernia surgery: A multicenter randomized controlled trial comparing lightweight vs heavyweight mesh (Supermesh Study). *Updates Surg* 2018;70:77-83.