

# Infliximab-Induced Acute Liver Failure in a Patient With Crohn's Disease Requiring Orthotopic Liver Transplantation

Muhammed Mustafa Alikhan, MD<sup>1</sup>, Emad Mansoor, MD<sup>2</sup>, Sagarika Satyavada, MD<sup>2</sup>, Katarina Greer, MD<sup>2</sup>, Wei Xin, MD<sup>3</sup>, Stanley Cohen, MD<sup>2</sup>, Gregory Cooper, MD<sup>2</sup>, and Jeffrey Katz, MD<sup>2</sup>

<sup>1</sup>Department of Internal Medicine, University Hospitals Cleveland Medical Center, Case Western Reserve University, Cleveland, OH

<sup>2</sup>Division of Gastroenterology and Liver Disease, University Hospitals Cleveland Medical Center, Case Western Reserve University, Cleveland, OH

<sup>3</sup>Department of Pathology, University Hospitals Cleveland Medical Center, Case Western Reserve University, Cleveland, OH

## ABSTRACT

Tumor necrosis factor- $\alpha$  inhibitors are not known to have significant liver toxicity; however, a few case reports state otherwise. We report the case of a 25-year-old man with Crohn's disease who was initiated on infliximab. The patient developed severe mixed hepatocellular and cholestatic liver injury that progressed into acute liver failure. Based on clinical history, laboratory findings, and histology, this was presumed because of the development of autoimmune hepatitis secondary to infliximab. He underwent liver transplantation. The mainstay of treatment in this rare condition involves steroid therapy and possible transplantation. Patients must then avoid anti-tumor necrosis factor- $\alpha$  therapy for life.

## INTRODUCTION

Among potential adverse effects attributable to drugs of the tumor necrosis factor- $\alpha$  (TNF- $\alpha$ ) class, hepatotoxicity is rarely cited. One report suggests 35 postmarketing incidents of severe hepatic reactions reported to the Food and Drug Administration, the majority of which are attributable to infliximab.<sup>1</sup> The degree of hepatic insult seems to be variable, with a group reporting transaminase elevation up to 6 times the upper limit while another demonstrates the development of autoimmune hepatitis (AIH) necessitating transplant.<sup>2,3</sup> We present the case of a patient with a history of Crohn's disease (CD) who was started on infliximab and subsequently developed acute liver failure (ALF), ultimately necessitating a transplant.

## CASE REPORT

A 25-year-old man with no history of liver disease presented to a clinic with perianal abscess and fistula in ano. Colonoscopy with biopsies revealed ulcerations, focal active ileitis, and colitis at the ileocecal valve. He was diagnosed with ileocolonic and perianal CD and started on intravenous infliximab 400 mg every 8 weeks and oral methotrexate 10 mg once weekly.

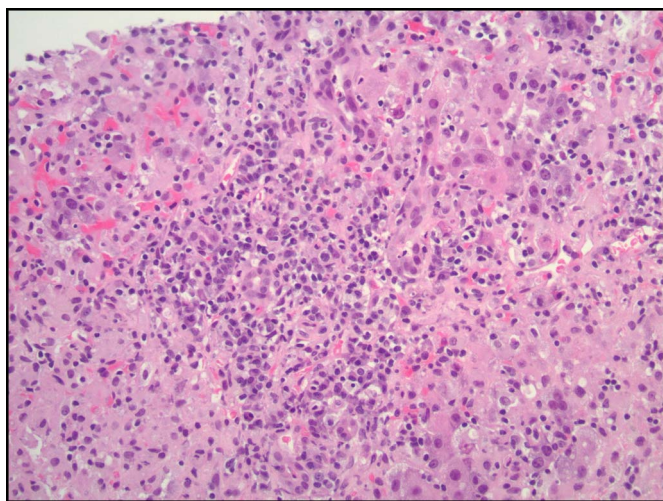
Two months after initiation of CD therapy, the patient reported anorexia and weight loss, after which methotrexate was discontinued. A few weeks later, while still receiving infliximab, he developed acute-onset pruritus, pale stools, and dark urine and was admitted for further evaluation. Physical examination was notable for scleral icterus and jaundice without asterixis. Laboratory evaluation was remarkable for new mixed hepatocellular and cholestatic liver injury with a total bilirubin of 10.7 mg/dL, alkaline phosphatase of 257 IU/L, aspartate aminotransferase of 2776 IU/L, alanine transaminase (ALT) of 499 IU/L, and international normalized ratio of 1.6.

The patient underwent acute liver disease evaluation; along with an unrevealing medication reconciliation, infectious and vascular etiologies were ruled out. The serologic evaluation revealed antinuclear antibody (ANA) positive at a dilution of 1:80 and anti-smooth muscle antibody (ASMA) positive at a dilution of 1:40. Liver biopsy revealed acute on chronic hepatitis with extensive hepatocellular necrosis (Figures 1 and 2). Given the significant predominance of plasma cells along with mildly positive ANA and ASMA and exclusion of other etiologies, hepatic pathology was attributable to severe AIH likely induced by infliximab and empiric methylprednisolone was initiated.

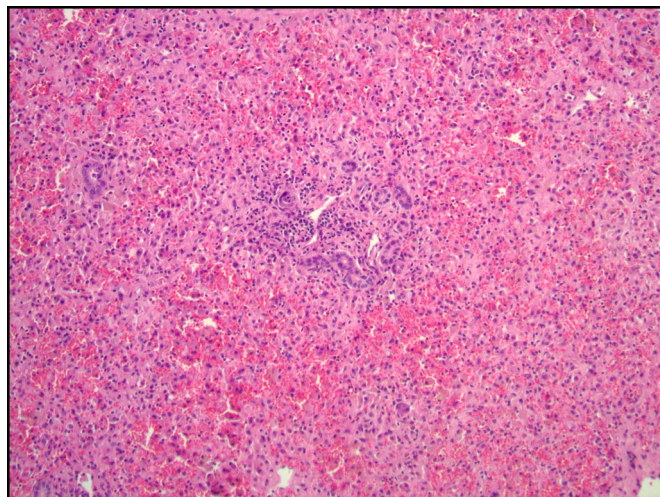
The patient's clinical course deteriorated with the development of encephalopathy and worsening coagulopathy, and he progressed to ALF after 1 week. At this point, his model for end-stage liver disease-sodium score was above 40, and he underwent orthotopic liver transplant (OLT). The postoperative course was complicated by fevers, acute renal failure, pancytopenia, and encephalopathy which resolved with the initiation of immunosuppression. The patient is now doing well on cyclosporine 125 mg twice a day and prednisone 10 mg daily. He reports a stable course of his CD. It was decided to avoid infliximab and other TNF- $\alpha$  inhibitors in this patient's management.

## DISCUSSION

ALF secondary to infliximab has been reported in the literature; yet, it remains a rare occurrence. Although numerous case reports have cited this toxicity, the exact prevalence remains unknown.<sup>2-4</sup> Per phase 3 clinical trial of infliximab prescribed for CD, a greater than 5 times the upper limit of ALT was reported in 2% of patients receiving infliximab as compared to 0% in the placebo arm at a median follow-up of 54 weeks.<sup>1</sup> Compared with other drugs from the TNF- $\alpha$  class, infliximab has been noted to have a much more frequent correlation to ALF.<sup>4-6</sup>



**Figure 1.** Massive hepatocellular necrosis with infiltration of portal lymphocytic and lymphoplasmacytic cells.



**Figure 2.** Acute hepatitis with massive hepatocellular necrosis.

The diagnosis of AIH is made by history, laboratory, and histological features.<sup>7</sup> These include typical symptoms of liver injury, the nonspecific elevation of ALT and aspartate aminotransferase, an elevation of gammaglobulins (typically immunoglobulin G), and autoantibodies such as ANA and ASMA, and typical histologic findings such as interface hepatitis and lymphoplasmacytic infiltrates.<sup>7</sup> Although methotrexate has also been reported to cause hepatotoxicity, infliximab was considered to be etiology for AIH in our patient given the significantly longer half-life of infliximab and the more acute nature of hepatotoxicity. Per our review of the literature, there are no reports of ALF induced by methotrexate. Instead, chronic liver fibrosis progressing into cirrhosis is well known.<sup>8</sup> It is hypothesized that individuals with no history of liver disease may develop ALF secondary to infliximab because of an underlying genetic susceptibility, selective activity of T-helper cells resulting in immune complex formation, or perhaps cytokine blockade.<sup>9</sup>

The diagnosis of ALF can be made in the setting of elevated aminotransferases, hepatic encephalopathy, and prolonged international normalized ratio.<sup>10</sup> All patients should have a thorough evaluation for toxicities, viral serologies, and thorough history to assess for medication-induced ALF.<sup>10</sup> Initial treatment of infliximab-induced AIH involves stopping the offending agent and initiation of immunosuppressive therapy with high-dose corticosteroids such as methylprednisolone or prednisone.<sup>2,11</sup> In intractable cases, a transplant may be indicated.

Regarding alternative medical management of CD after OLT, the interleukin 12/23 antagonist ustekinumab has also shown favorable activity. Martínez-Montiel et al have studied its use in a post-OLT patient in whom a favorable clinical course of CD was observed after TNF- $\alpha$  inhibitors failed.<sup>12</sup> Similarly, the integrin  $\alpha 4\beta 7$  antagonist vedolizumab has been shown to be relatively safe in liver transplant patients in a study by

Spadaccini et al, although caution is recommended in patients with unstable graft function.<sup>13</sup> Vedolizumab has been shown to be a safe and effective steroid-sparing therapy for the treatment of moderate to severe CD among liver transplant recipients.<sup>14</sup>

In summary, although infliximab-induced ALF is a rare event, it is an important one that must be acknowledged as a risk during the initiation of infliximab therapy, especially in CD patients. The mechanism of action likely involves the development of AIH, characterized by typical clinical history, laboratory findings, and distortions in histological architecture. The mainstay of treatment involves steroid therapy, and if this fails, then liver transplantation must be considered. Patients must then avoid anti-TNF- $\alpha$  therapy for life to prevent recurrence of ALF. Other treatment options can include ustekinumab and vedolizumab. Further studies are needed to risk stratify patients with inflammatory bowel disease for the development of ALF.

## DISCLOSURES

Author contributions: M. Alikhan and E. Mansoor are cofirst authors and wrote the manuscript. S. Satyavada, K. Greer, S. Cohen, G. Cooper, and J. Katz revised the manuscript for intellectual content. W. Xin provided the histological images. E. Mansoor is the article guarantor.

Financial disclosure: None to report.

Informed consent was obtained for this case report.

Received May 28, 2020; Accepted November 22, 2020

## REFERENCES

1. Highlights of prescribing information. n.d. ([https://www.accessdata.fda.gov/drugsatfda\\_docs/label/2013/103772s5359lbl.pdf](https://www.accessdata.fda.gov/drugsatfda_docs/label/2013/103772s5359lbl.pdf)). Accessed March 30, 2020.

2. Zhang HC, Luo W, Wang Y. Acute liver injury in the context of immune checkpoint inhibitor-related colitis treated with infliximab. *J Immunother Cancer* 2019;7:47.
3. Wong F, Ibrahim BA, Walsh J, Qumosani K. Infliximab-induced autoimmune hepatitis requiring liver transplantation. *Clin Case Rep* 2019;7(11):2135–9.
4. Kok B, Lester ELW, Lee WM, et al; for the United States Acute Liver Failure Study Group. Acute liver failure from tumor necrosis factor- $\alpha$  antagonists: Report of four cases and literature review. *Dig Dis Sci* 2018;63(6):1654–66.
5. Björnsson ES, Gunnarsson BI, Gröndal G, et al. Risk of drug-induced liver injury from tumor necrosis factor Antagonists. *Clin Gastroenterol Hepatol* 2015;13(3):602–8.
6. Shelton E, Chaudrey K, Sauk J, et al. New onset idiosyncratic liver enzyme elevations with biological therapy in inflammatory bowel disease. *Aliment Pharmacol Ther* 2015;41(10):972–9.
7. Manns MP, Lohse AW, Vergani D. Autoimmune hepatitis—Update 2015. *J Hepatol* 2015;62(1):S100–11.
8. *LiverTox: Clinical and Research Information on Drug-Induced Liver Injury [Internet]*. National Institute of Diabetes and Digestive and Kidney Diseases: Bethesda, MD, 2012. Methotrexate [Updated 2020 Feb 19]. (<https://www.ncbi.nlm.nih.gov/books/NBK548219/>). Accessed March 30, 2020.
9. Rodrigues S, Lopes S, Magro F, et al. Autoimmune hepatitis and anti-tumor necrosis factor alpha therapy: A single center report of 8 cases. *World J Gastroenterol* 2015;21(24):7584–8.
10. Bernal W, Wendon J. Acute liver failure. *N Engl J Med* 2013;369:2525–34.
11. Weber JS, Postow M, Lao CD, Schadendorf D. Management of adverse events following treatment with anti-programmed death-1 agents. *Oncologist* 2016;21(10):1230–40.
12. Martínez-Montiel M, Piedracoba-Cadahia P, Gómez-Gómez C, Gonzalo J. Ustekinumab is effective and safe in the treatment of Crohn's disease refractory to anti-TNF $\alpha$  in an orthotopic liver transplant patient. *J Crohns Colitis* 2015;9(9):816–7.
13. Spadaccini M, Aghemo A, Caprioli F, et al. Safety of vedolizumab in liver transplant recipients: A systematic review. *United Eur Gastroenterol J* 2019;7(7):875–80.
14. Wright AP, Fontana RJ, Stidham RW. Vedolizumab is safe and effective in moderate to severe inflammatory bowel disease following liver transplantation. *Liver Transplant* 2017;23(7):968–71.

**Copyright:** © 2021 The Author(s). Published by Wolters Kluwer Health, Inc. on behalf of The American College of Gastroenterology. This is an open access article distributed under the terms of the Creative Commons Attribution-Non Commercial-No Derivatives License 4.0 (CCBY-NC-ND), where it is permissible to download and share the work provided it is properly cited. The work cannot be changed in any way or used commercially without permission from the journal.