



Case Report

# Unique imaging appearance of neurosarcoidosis as a solitary cystic mass with mural enhancement

Girish Bathla<sup>1</sup>, Sedat Giray Kandemirli<sup>1</sup>, Sarika Gupta<sup>2</sup>, Amit Agarwal<sup>3</sup>

Departments of <sup>1</sup>Radiology and <sup>2</sup>Pathology, University of Iowa, Iowa, <sup>3</sup>Department of Radiology, University Texas Southwestern, Dallas, Texas, United States.

E-mail: Girish Bathla - girishmamc@gmail.com; Sedat Giray Kandemirli - gskandemirli@yahoo.com; Sarika Gupta - sarika-gupta@uiowa.edu; \*Amit Agarwal - amitmamc@gmail.com



**\*Corresponding author:**

Amit Agarwal,  
Department of Radiology,  
University Texas Southwestern,  
5323 Harry Hines, Dallas -  
75390, Texas, United States.

[amitmamc@gmail.com](mailto:amitmamc@gmail.com)

Received : 18 November 2020

Accepted : 05 December 2020

Published : 22 December 2020

DOI

10.25259/SNI\_830\_2020

Quick Response Code:



## ABSTRACT

**Background:** Sarcoidosis is an idiopathic, granulomatous, and multi-system inflammatory disorder that can also involve the central nervous system in the form of meningeal, parenchymal, or cranial nerve involvement. Imaging findings can be non-specific and may overlap with other inflammatory, infectious and neoplastic processes, and posing diagnostic challenges. Parenchymal involvement in neurosarcoidosis (NS) predominantly manifests as either non-enhancing white matter lesions or as enhancing parenchymal granulomas. Granulomas usually manifest as multiple solid lesions with nodular enhancement.

**Case Description:** A 72-year-old man presented with right-eye visual field changes with the non-contrast head computed tomography showing a large cystic lesion in the left frontoparietal lobe. Subsequent contrast-enhanced magnetic resonance imaging study revealed a large cystic mass with irregular rim enhancement and mural nodule concerning for glial neoplasm. Cyst decompression with biopsy and histopathological analysis revealed gliosis and prominent perivascular granulomatous inflammation with mixed picture of CD4 and CD8-positive cells suggestive of sarcoidosis. Further subsequent work-up showed mediastinal and cervical lymphadenopathy which on biopsy showed non-necrotizing granulomatous inflammation, consistent with sarcoidosis.

**Conclusion:** Herein, we report unique imaging findings of a NS case manifesting as a solitary cystic intraparenchymal lesion with an enhancing nodular component, mimicking primary intra-cranial tumor. This appearance is highly atypical and rarely been reported earlier.

**Keywords:** Cystic, Magnetic resonance imaging, Neurosarcoidosis

## INTRODUCTION

Sarcoidosis is an idiopathic, granulomatous, multi-system inflammatory disorder, and characterized histologically by non-caseating granuloma formation. Sarcoidosis has a bimodal age distribution with initial peak in 3<sup>rd</sup> decade and a later peak after 50 years of age and a predilection for African Americans.<sup>[6,12]</sup> Any organ system may be affected, but most common sites of involvement are the lungs, skin, and lymph nodes.<sup>[2]</sup> Central nervous system (CNS) involvement is reported in 10% of sarcoidosis patients on imaging studies and 14–27% in postmortem series.<sup>[11]</sup> CNS involvement can be seen in the form of meningeal, parenchymal, or cranial nerve findings. Parenchymal involvement in neurosarcoidosis (NS) predominantly manifests either as non-enhancing white matter lesions or as enhancing parenchymal granulomas. The latter are invariably solid and often show nodular enhancement.<sup>[11]</sup>

This is an open-access article distributed under the terms of the Creative Commons Attribution-Non Commercial-Share Alike 4.0 License, which allows others to remix, tweak, and build upon the work non-commercially, as long as the author is credited and the new creations are licensed under the identical terms.

©2020 Published by Scientific Scholar on behalf of Surgical Neurology International

Imaging findings in NS, however, are non-specific and may overlap with other inflammatory, infectious, and neoplastic processes. However, neurologic manifestations as initial clinical presenting symptom (seen in 52% of cases) and absence of systemic imaging at the time of CNS imaging can pose diagnostic challenges.<sup>[1,4]</sup> Recognition of imaging findings of NS is important to guide appropriate further imaging and laboratory studies.

Herein, we report unique imaging findings of a NS case manifesting as a solitary cystic intraparenchymal lesion with an enhancing nodular component, mimicking primary intracranial tumor. This appearance is highly atypical and rarely been reported earlier.

### CASE REPORT

A 72-year-old man with a medical history of hypertension, glaucoma, and left retinal vein occlusion presented with right-eye visual field changes. Non-contrast head computed tomography showed a large intraparenchymal cystic lesion in the left frontoparietal region. Subsequent contrast-enhanced magnetic resonance imaging study revealed a large cystic mass lesion measuring 7.0 × 3.8 cm (transaxial) in the left frontoparietal lobe, following cerebrospinal fluid signal intensity on T1- and T2-weighted images with incomplete suppression of fluid signal fluid attenuation inversion recovery (FLAIR) sequence and no diffusion restriction [Figure 1]. On post contrast images, there was irregular rim enhancement and nodular mural enhancement in the anterior portion of the lesion. There was mild perilesional edema and mass effect on the posterior horn of the left lateral ventricle. There was scalloping of the overlying bone cortex. Nodular enhancement was concerning for a primary intracranial mass lesion, and decompression of the cyst with biopsy of the enhancing lesion was performed.

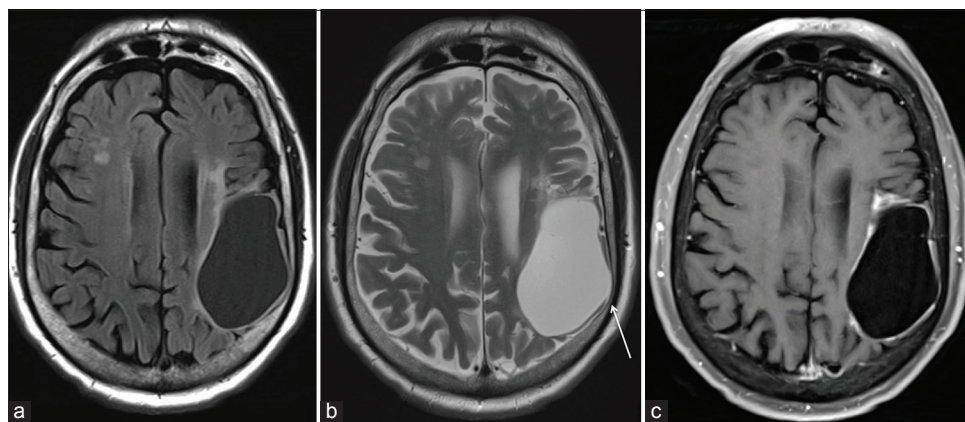
Histopathological analysis showed fragments of brain parenchyma with gliosis and prominent perivascular granulomatous inflammation with mixed picture of CD4 and CD8-positive cells [Figure 2]. Immunostains were negative for Isocitrate Dehydrogenase-1, Beta-Amyloid, Varicella Zoster Virus and Epstein-Barr Virus. Acid-fast bacilli, Gomori Methenamine-Silver stains did not show microorganisms. No malignant cells were identified. The findings were suggestive of sarcoidosis.

Further subsequent work-up including chest computed tomography and whole-body 2-[18F]-fluoro-2-deoxy-D-glucose-positron emission tomography showed mediastinal and cervical lymphadenopathy [Figure 3]. Cervical lymph node biopsy again showed non-necrotizing granulomatous inflammation, consistent with sarcoidosis [Figure 4]. In light of these findings, treatment for NS with high dose oral prednisolone was initiated.

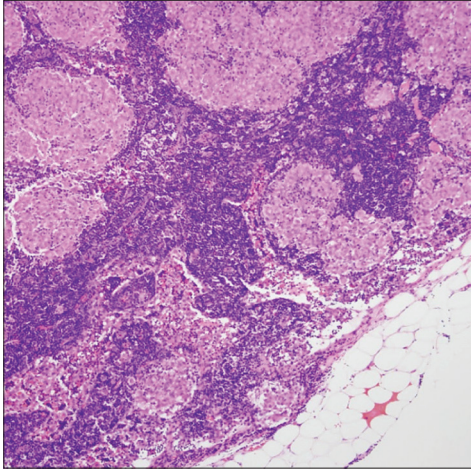
### DISCUSSION

Parenchymal involvement in NS may manifest as non-enhancing white matter lesions, enhancing granulomas, ischemic, or hemorrhagic lesions. The reported prevalence of parenchymal granulomas varies between 22% and 57%. Most of these lesions are supratentorial, sub-centimeter and show solid nodular enhancement on post contrast images.<sup>[3,11]</sup> These may coalesce and at times mimic a neoplastic process. Rarely, the granulomas may develop hemorrhage or cystic degeneration.

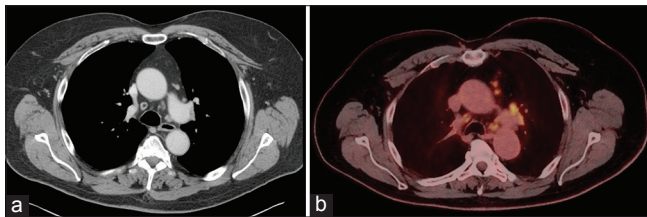
A review of the medical literature revealed only few case reports of NS with cystic parenchymal lesion. In the case reported by Al Hajri *et al.*, there was a peripherally enhancing cystic lesion in the right temporal lobe.<sup>[1]</sup> However, in this case, there was accompanying multiple enhancing



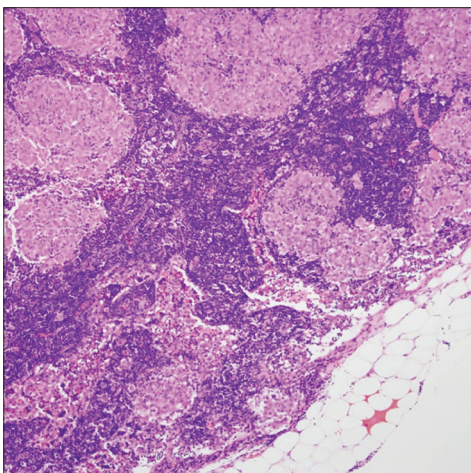
**Figure 1:** Axial fluid attenuation inversion recovery (FLAIR) (a) T2-weighted images (b) show a large cystic mass in the left frontoparietal region. Note incomplete suppression of fluid signal on FLAIR and mild perilesional edema and mass effect on the posterior horn of the left lateral ventricle. On post contrast image (c) there is complete rim enhancement and irregular, peripheral nodular enhancement in the anterior portion of the lesion. There is scalloping of the overlying bone cortex (arrow).



**Figure 2:** Decompression of the cyst with biopsy of the enhancing lesion was performed. Hematoxylin and eosin stained section ( $\times 20$ ) of left temporal lobe showing perivascular granulomatous inflammation within unremarkable background brain parenchyma.



**Figure 3:** (a) Subsequent chest CT and (b) whole-body 2-[ $^{18}\text{F}$ ]-fluoro-2deoxy-D-glucose-positron emission tomography showed mediastinal lymphadenopathy.



**Figure 4:** Hematoxylin and eosin stained section ( $\times 10$ ) of right level V cervical lymph node demonstrating non-necrotizing compact epithelioid granulomas.

parenchymal nodules with surrounding edema, meningeal thickening and enhancement, and abnormal pituitary stalk thickening with enhancement along with enhancement

of optic chiasm. There are also few cases reporting cystic pituitary involvement mimicking a Rathke's cleft cyst or craniopharyngioma on imaging.<sup>[5,10]</sup> Unlike the previously reported cases, our case had a few unique features that are worth highlighting. These include the large size, lack of any other lesion, or other associated imaging findings supporting a diagnosis of NS and relative lack of clinical symptoms. In addition, there was scalloping of the cortical table, which would support a gradually progressive nature of the lesion.

One of the plausible explanations for the granulomatous inflammation on pathology in the brain lesion could be a reactive granulomatous response to underlying neoplasm, as has been previously reported with seminomas.<sup>[8]</sup> However, no malignant cells were identified. In addition, the presence of systemic sarcoidosis on the supraclavicular lymph node biopsy further supports sarcoidosis as the underlying etiology for the brain lesion.

The mechanism of cystic degeneration in the current case remains uncertain. Ischemic necrosis or cystic degeneration of granuloma has been suggested as the cause of cyst formation in NS.<sup>[11]</sup> However, since granulomas in NS are often small, it is possible that they rarely outgrow their vascular supply to become necrotic. Similarly, hemorrhage in NS granulomas is rare. Regardless of the underlying pathophysiology, a large, isolated, predominantly cystic granuloma presenting as the sole imaging manifestation of NS has not been previously described, to the best of authors' knowledge. Even though the patient had some non-enhancing white matter lesions, give the age and medical comorbidities, these could also be secondary to leukoaraiosis and may be incidental.

Intracranial cysts and cystic-appearing masses have a broad imaging spectrum.<sup>[9]</sup> On imaging, presence of septations, wall morphology, perilesional edema, internal diffusion restriction, FLAIR signal characteristics, and enhancement can provide helpful clues to narrow differential diagnosis. In the presence of enhancing components, differential diagnosis includes malignancies such as cystic metastasis, cystic glioblastoma or lesions such as hemangioblastoma, pilocytic astrocytoma, pleomorphic xanthoastrocytoma or infectious etiology such as abscesses, toxoplasmosis, neurocysticercosis or hydatid cysts.<sup>[9]</sup> Parenchymal metastatic lesions have a predilection for central necrosis and hemorrhage, especially with increased size. This is more prominent in melanomas, choriocarcinomas, and carcinomas of the lung, kidney, and thyroid.<sup>[7]</sup> Rim enhancement with irregular walls is helpful to differentiate from brain abscess in capsular stage. Glioblastoma can have substantial cystic component secondary to necrosis.<sup>[13]</sup> Necrosis develops when tumor growth rate outstrips its blood supply. Pilocytic astrocytomas typically involve the cerebellum or optic chiasm/hypothalamus with mixed solid/cystic lesion, typically seen in the pediatric population. Otherwise involvement of



supratentorial system is rare. Hemangioblastomas commonly (95%) involve the posterior fossa with an avidly enhancing nodular lesion at pial surface, surrounded by cystic component.<sup>[9]</sup> Flow-voids in nodular component are helpful in differential diagnosis. Pleomorphic xanthoastrocytoma is a cortically based, round to oval shaped mass, most commonly involving the temporal lobe. Enhancing dural-tail is a helpful clue in differential diagnosis.

In the current case, searching for underlying systemic sarcoidosis was helpful in confirming the diagnosis once the brain biopsy suggested NS. Fritz *et al.*, in their meta-analysis, noted that neurological symptoms were the initial clinical manifestation in 52% of patients. In fact only 31% of patients had known sarcoidosis outside CNS at the time of diagnosis, even though 84% had systemic manifestations at any time during the course of the disease.<sup>[4]</sup> Thus, searching for underlying systemic disease helped further establish the diagnosis unequivocally.

## CONCLUSION

We present a rare case of NS manifesting as an isolated large cystic lesion with enhancing mural nodule. Even though cystic degeneration may rarely occur in a sarcoid granuloma, it has not been previously described as an isolated finding. The presence of asymptomatic systemic sarcoidosis helped establish the correct diagnosis, given the highly atypical neuroimaging findings.

## Declaration of patient consent

Patient's consent not required as patients identity is not disclosed or compromised.

## Financial support and sponsorship

Nil.

## Conflicts of interest

There are no conflicts of interest.

## REFERENCES

1. Al Hajri FA, Muqim AT, Muttikkal TJ. Neurosarcoidosis with intraparenchymal cystic lesions. A case report. *Neuroradiol J* 2009;21:810-6.
2. Bathla G, Singh AK, Policeni B, Agarwal A, Case B. Imaging of neurosarcoidosis: Common, uncommon, and rare. *Clin Radiol* 2016;71:96-106.
3. Fels C, Riegel A, Javaheripour-Otto K, Obenauer S. Neurosarcoidosis: Findings in MRI. *Clin Imaging* 2004;28:166-9.
4. Fritz D, van de Beek D, Brouwer MC. Clinical features, treatment and outcome in neurosarcoidosis: Systematic review and meta-analysis. *BMC Neurol* 2016;16:220.
5. Guoth MS, Kim J, de Lotbiniere AC, Brines ML. Neurosarcoidosis presenting as hypopituitarism and a cystic pituitary mass. *Am J Med Sci* 1998;315:220-4.
6. Nowak DA, Widenka DC. Neurosarcoidosis: A review of its intracranial manifestation. *J Neurol* 2001;248:363-72.
7. Oprisan A, Popescu BO. Intracranial cysts: An imagery diagnostic challenge. *Sci World J* 2013;2013:172154.
8. Peebles DM, Stern BJ, Jiji V, Sahni KS. Germ cell tumors masquerading as central nervous system sarcoidosis. *Arch Neurol* 1991;48:554-6.
9. Raz E, Zagzag D, Saba L, Mannelli L, di Paolo PL, D'Ambrosio F, *et al.* Cyst with a mural nodule tumor of the brain. *Cancer Imaging* 2012;12:237-44.
10. Sato N, Sze G, Kim JH. Cystic pituitary mass in neurosarcoidosis. *AJNR Am J Neuroradiol* 1997;18:1182-5.
11. Shah R, Roberson GH, Cure JK. Correlation of MR imaging findings and clinical manifestations in neurosarcoidosis. *AJNR Am J Neuroradiol* 2009;30:953-61.
12. Statement on sarcoidosis. joint statement of the American thoracic society (ATS), the European respiratory society (ERS) and the world association of sarcoidosis and other granulomatous disorders (WASOG) adopted by the ATS board of directors and by the ERS executive committee, February 1999. *Am J Respir Crit Care Med* 1999;160:736-55.
13. Utsuki S, Oka H, Suzuki S, Shimizu S, Tanizaki Y, Kondo K, *et al.* Pathological and clinical features of cystic and noncystic glioblastomas. *Brain Tumor Pathol* 2006;23:29-34.

**How to cite this article:** Bathla G, Kandemirli SG, Gupta S, Agarwal A. Unique imaging appearance of neurosarcoidosis as a solitary cystic mass with mural enhancement. *Surg Neurol Int* 2020;11:463.