

Pemetrexed-associated Ischemic Colitis in Nonsmall Cell Lung Cancer

Liang Ye, Zhen-Hua Yang, Su-Rong Fang, Wei Gu

Department of Respiration, Nanjing First Hospital, Nanjing Medical University, Nanjing, Jiangsu 210006, China

To the Editor: The most frequently reported adverse event of pemetrexed was myelosuppression. Here, we reported a patient with advanced lung adenocarcinoma showing pemetrexed-associated ischemic colitis.

A 56-year-old female patient was admitted to our department due to the presence of a right lung mass and ipsilateral pleural effusion. Transbronchial biopsy and subsequent sequence analysis of the right lower bronchus showed poorly differentiated adenocarcinoma with no mutations in the epidermal growth factor receptor gene. Pleural biopsy revealed a metastatic lung adenocarcinoma, which suggested that radical treatment would not be beneficial. The patient was initially treated with six cycles of a first-line chemotherapy using pemetrexed (500 mg/m², day 1) and carboplatin (area under the curve 5, day 1). Thereafter, partial remission was gained, and maintenance single-substance therapy with pemetrexed was given leading to stabilization of tumor growth. The patient was transferred to the emergency department as she showed severe, diffuse abdominal pain with hematochezia 3 days after administration of pemetrexed during the 17th maintenance therapy.

Physical examination revealed direct tenderness on the left lower quadrant of the abdomen. Complete blood count revealed a hematocrit of 26.3%, hemoglobin of 9.2 g/dl, platelets of 120,000/ μ l, and white blood cell count of 4800/ μ l within the normal range. Colonoscopic examination revealed acute hyperemic mucosal changes with edema, erosion, and ulcerations. Meanwhile, acute inflamed, friable mucosal changes were noticed from the sigmoid colon [Figure 1a] to the proximal descending colon [Figure 1b]. Colonic mucosal biopsy revealed acute exudative colitis compatible with ischemic colitis [Figure 1c]. Bacteriologic culture tests in the stool and colonic fluid were negative for *Mycobacterium*, *Salmonella*, and *Shigella*, respectively. Then, pemetrexed therapy was terminated, and bowel rest and total parenteral nutrition were initiated. Afterward, the abdominal pain and hematochezia were attenuated. One week later, improvement was noticed in ulceration and mucosal edema as revealed by colonoscopy. Thus, folate (1 mg/d, p.o.) was given. Besides, a Vitamin B12 injection was given before initiation of pemetrexed.

The most frequently observed adverse effects include myelosuppression, fatigue, and mucositis, and cellulitis of lower

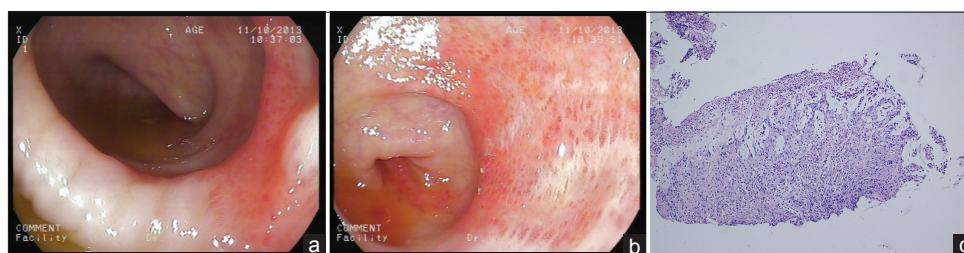


Figure 1: Colonoscopy images and pathological findings. (a) Mucosal hyperemic change with edema, erosion, and ulcerations and hemorrhagic friable mucosa were observed on the sigmoid colon. (b) Segmental ulceration was seen on the proximal descending colon. (c) Pathological examination of the descending colon showed acute exudative colitis. Epithelial detachment was observed after H and E staining, original magnification, $\times 40$.

limbs has rarely been reported as an adverse event induced by pemetrexed.^[1] To date, the diagnosis in clinical practice is possible by excluding the other conditions that may cause ischemic colitis including inflammatory bowel disease, atrial fibrillation, valvular heart disease, and hypercoagulable conditions. Moreover, the diagnosis of adverse events should take the duration of drug

Address for correspondence: Dr. Wei Gu,
Department of Respiration, Nanjing First Hospital, Nanjing Medical
University, Nanjing, Jiangsu 210006, China
E-Mail: guwei_101@163.com

Access this article online

Quick Response Code:



Website:
www.cmj.org

DOI:
10.4103/0366-6999.209887

This is an open access article distributed under the terms of the Creative Commons Attribution-NonCommercial-ShareAlike 3.0 License, which allows others to remix, tweak, and build upon the work non-commercially, as long as the author is credited and the new creations are licensed under the identical terms.

© 2017 Chinese Medical Journal | Produced by Wolters Kluwer - Medknow

Received: 05-01-2017 **Edited by:** Limin Chen

How to cite this article: Ye L, Yang ZH, Fang SR, Gu W. Pemetrexed-associated Ischemic Colitis in Nonsmall Cell Lung Cancer. Chin Med J 2017;130:1757-8.

infusion and attenuation of symptoms after termination of infusion into consideration. In the present case, all possible causes of ischemic colitis were ruled out. More importantly, the patient recovered with pemetrexed cessation. Thus, we confirm that the ischemic colitis was induced by pemetrexed.

To the best of our knowledge, only two cases of colitis have been reported after the appliance of pemetrexed.^[2,3] We reported a patient with advanced lung adenocarcinoma showing pemetrexed-associated ischemic colitis. In future, attention should be paid to the pemetrexed-associated colitis—a rare but serious complication as pemetrexed is increasingly prescribed for advanced nonsmall cell lung cancer.

Declaration of patient consent

The authors certify that they have obtained all appropriate patient consent forms. In the form the patient(s) has/have given his/her/their consent for his/her/their images and other clinical information to be reported in the journal. The patients understand that their names and initials will not be published and due efforts will be made to conceal their identity, but anonymity cannot be guaranteed.

Financial support and sponsorship

This study was supported by a grant from the Nanjing Medical Scientific Development Program (No. YKK13104).

Conflicts of interest

There are no conflicts of interest.

REFERENCES

1. D'Angelo SP, Kris MG, Pietanza MC, Rizvi NA, Azzoli CG. A case series of dose-limiting peripheral edema observed in patients treated with pemetrexed. *J Thorac Oncol* 2011;6:624-6. doi: 10.1097/JTO.0b013e318207f788.
2. Buchinger K, Stahel R, Niggemeier V, Gubler C, Franzen D. Pemetrexed-induced neutropenic enteritis and severe cutaneous hyperpigmentation in a patient with malignant pleural mesothelioma. *Lung Cancer* 2013;80:347-9. doi: 10.1016/j.lungcan.2013.02.019.
3. Shvartsbeyn M, Edelman MJ. Pemetrexed-induced typhlitis in non-small cell lung cancer. *J Thorac Oncol* 2008;3:1188-90. doi: 10.1097/JTO.0b013e318187490c.