

Preliminary Results on Radiological Hypermobility at Upper Adjacent Disc Level in Posterior Lumbar Interbody Fusion Compared to Advanced Dynamic Stabilization

Tatsuya OHTONARI,¹ Takehiro KITAGAWA,^{1,2} Taisei OTA,¹
and Nobuharu NISHIHARA¹

¹Department of Spinal Surgery, Brain Attack Center, Ota Memorial Hospital, Fukuyama, Hiroshima, Japan

²Department of Neurosurgery, University of Occupational and Environmental Health, Kitakyushu, Fukuoka, Japan

Abstract

Whether posterior lumbar interbody fusion (PLIF) is effective in patients older than 55 years remains questionable because of the high prevalence of adjacent segment disease. We retrospectively investigated early clinical outcomes and radiological changes at upper adjacent disc (UAD) level in such age-group patients who underwent advanced dynamic stabilization (ADS) or PLIF. ADS or PLIF were performed in patients with grade 1 spondylolisthesis or disc degeneration complicated by apparent vacuum phenomenon. All patients suffered from neurological symptoms in lower limbs with/without low back pain. In all, 16 patients (six females; mean age, 69.0 ± 8.5 years) who underwent ADS and 14 patients (seven females; mean age, 67.8 ± 9.3 years) who underwent PLIF were followed-up, and preoperative and postoperative final disc height (DH) and range of motion (ROM) were investigated retrospectively using dynamic radiography at the operated and UAD levels. Clinical data of patients who underwent ADS and PLIF were as follows: postoperative follow-up, 459.3 ± 263.5 and 507.7 ± 288.3 days; preoperative Japanese Orthopaedic Association (JOA) score, 14.4 ± 4.1 and 13.4 ± 4.5 ; and recovery rate of JOA score, 67.5 ± 18.5 and $50.1 \pm 23.4\%$, respectively. Recovery rate of JOA score in ADS group was significantly high compared to PLIF group ($P = 0.044$). At UAD level, ROM decreased from $4.7 \pm 2.9^\circ$ preoperatively to $3.6 \pm 2.6^\circ$ postoperatively in the ADS group and increased from $3.4 \pm 4.1^\circ$ preoperatively to $5.6 \pm 2.8^\circ$ postoperatively with significant hypermobility ($P = 0.020$) in the PLIF group. ADS has the advantage in clinical outcomes even in the postoperative early stage, avoiding the early hypermobility at UAD level, compared to PLIF in patients older than 55 years.

Keywords: dynamic stabilization, posterior lumbar interbody fusion, adjacent segment disease, pedicle screw, dynamization

Introduction

Posterior lumbar interbody fusion (PLIF) is widely employed in active age-group patients with lumbar spondylolisthesis or concerns regarding postoperative instability because of the stable long-term outcomes.¹⁻³⁾ In contrast, whether PLIF is as efficient

in patients older than 55 years remains questionable because of the high prevalence of adjacent segment disease (ASD).⁴⁻⁸⁾ Indeed, rigid fusion does not appear mandatory in patients older than 55 years because their activity levels are generally inferior to those of active-age patients. The minimally invasive decompression alone is not yet sufficient in resolving postoperative progression of deformity. A report revealed that 70% of patients with grade 1 degenerative spondylolisthesis treated with decompression alone appeared to do well.²⁾ However, it also revealed that 30% and greater of patients suffered from the progression of spondylolisthesis and needed revision fusion surgery. Especially in elderly patients, the surgical strategy avoiding revision fusion surgery

Received November 5, 2019; Accepted April 21, 2020

Part of this study was presented in symposium held on October 11, 2019 in the 78th annual meeting of the Japan Neurosurgical Society, Osaka, Japan.

Copyright© 2020 by The Japan Neurosurgical Society This work is licensed under a Creative Commons Attribution-NonCommercial-NoDerivatives International License.

due to the progression of slip and delaying ASD is hoped. We therefore developed a novel dynamic stabilization technique following decompression using pedicle screws, connectors, and rods to resolve this problem.

In 2014, we reported the short- to mid-term clinical and radiological outcomes about our previous dynamic stabilization.⁹⁾ In that report, as a concept of dynamization, two types of dynamization were introduced as dynamic stabilization mechanisms for different types of pathophysiology. One is dynamic stabilization that allows perpendicular movement for lumbar degenerative spondylolisthesis, and the other is that allowing sagittal movement for lumbar disc herniation in which postoperative instability is a concern because of an apparent vacuum phenomenon. We have never experienced severe progression of instability among patients who underwent our previous dynamic stabilization techniques, so we recently advanced a dynamization that allowed perpendicular and sagittal movements by combining both dynamization mechanisms regardless of the different types of pathophysiology. Eventually, this novel dynamic stabilization was termed “advanced dynamic stabilization (ADS).”

Herein, we retrospectively investigated the early clinical and radiological outcomes in patients older than 55 years who underwent ADS and PLIF, and compared radiological changes at upper adjacent disc (UAD) levels between PLIF and ADS groups.

Methods

Patients, indications for operation, and assessment factors

Participants in this retrospective study were 18 patients who underwent ADS and 16 patients who underwent PLIF ≥ 55 years old between March 2016 and April 2018, and in whom spondylolisthesis showed percentage slip (% slip) $< 25\%$ or showed disc degeneration for which postoperative instability was a concern because of an apparent vacuum phenomenon. All patients suffered from intermittent claudication or radiculopathy in the lower limbs with or without low back pain. Of the 18 patients in the ADS group, one had a psychological disorder and one had a neurodegenerative disorder. Of the 16 patients in the PLIF group, one had cerebral infarction and one showed the complication of back-out of the intervertebral spacer. Finally, 16 patients (6 females, 10 males; mean age, 69.0 ± 8.5 years) in the ADS group and 14 patients (7 females, 7 males; mean age, 67.8 ± 9.3 years) in the PLIF group showed sufficient

clinical and radiographic follow-up for analysis. Diseases of operated levels in ADS and PLIF were as follows: degenerative spondylolisthesis, 7 and 10; and disc degeneration with severe vacuum phenomenon, 11 and 4, respectively (Table 1). In all, 12 of 16 patients in ADS group suffered from low back pain preoperatively, while all of 14 patients in PLIF group had low back pain before surgery. All patients provided informed consent prior to the operations, and this study was organized according to the STROBE statement. Regarding the factors for assessment, preoperative and postoperative final disc height (DH) and range of motion (ROM) were investigated using lateral dynamic radiography in the standing position, at ADS or PLIF levels and UAD levels. The change in % slip was also measured in patients with spondylolisthesis. Each radiological parameter was independently measured by two spinal surgeons (T.O. and T.K.) and was averaged.

Implants and concept regarding ADS

The implant system utilized was KAPSS® (Robert Reid, Tokyo, Japan). Dynamization was obtained using the combination of a titanium-alloy multi-axial pedicle screw, specialized connector, and rod with a stopper at the end on the rostral side (Fig. 1). The connector invented by Suda et al. has a mechanism that allows sagittal rotation of 20° each way. Furthermore, perpendicular movement was also allowed by abandoning rigid fixation between the rod and the connector on the rostral side. In contrast, this system can strongly control rotational movement in the axial direction, allowing mild sagittal and perpendicular dynamization.

Surgeries

All patients in both types of operation were operated on the prone position under general anesthesia. Regarding ADS, a midline skin incision was made and fenestration with/without hernia excision was performed under a spinous process-splitting approach. In operations, we intended to preserve facet-joints as much as possible to prevent the progress of instability even under dynamic stabilization. Pedicle screws were generally installed at the superior articular process under the support of a navigation system. The rod was fixed to the pedicle screw via the connector by abandoning rigid fixation between the rod and rostral connector (Fig. 2). Regarding PLIF, a 12-cm longitudinal midline skin incision was made over the lesion, and posterior lumbar muscles were then stripped subperiosteally until the outer-line of the articular facets. Thereafter, partial removal of the

Table 1 Preoperative and postoperative clinical data

	Advanced dynamic stabilization	Posterior lumbar interbody fusion	P
Number of cases	16	14	NA
Sex	10 males, 6 females	7 males, 7 females	0.491
Age (years)	69.0 ± 8.5	67.8 ± 9.3	0.647
Disease	(Number of stabilized or fused levels)		NA
LDS	7	10	NA
LDD	11	4	NA
Operated level			NA
L2/3	1	1	NA
L3/4	3	1	NA
L4/5	12	9	NA
L5/S1	2	3	NA
Postop. follow-up period (days)	459.3 ± 263.5	507.7 ± 288.3	0.633
Preop. JOA score	14.4 ± 4.1	13.4 ± 4.5	0.660
Postop. JOA score	24.1 ± 3.4	21.5 ± 3.7	0.042*
Recovery rate of JOA score (%)	67.5 ± 18.5	50.1 ± 23.4	0.044*

SPSS ver. 24, χ^2 test and Mann–Whitney U test. NA: not applicable, LDS: lumbar degenerative spondylolisthesis, LDD: lumbar disc degeneration with apparent vacuum phenomenon, L: lumbar, S: sacral, Postop.: postoperative, Preop.: preoperative, JOA: Japanese Orthopaedic Association



Fig. 1 KAPSS system (Robert Reid, Tokyo, Japan) for ADS using titanium-alloy pedicle screws, connectors, and rod with a stopper is shown. Perpendicular movement is allowed on the rostral connector site (double-headed arrows) and sagittal movement with 20° each way is allowed on the both connector sites (arrows). ADS: advanced dynamic stabilization.

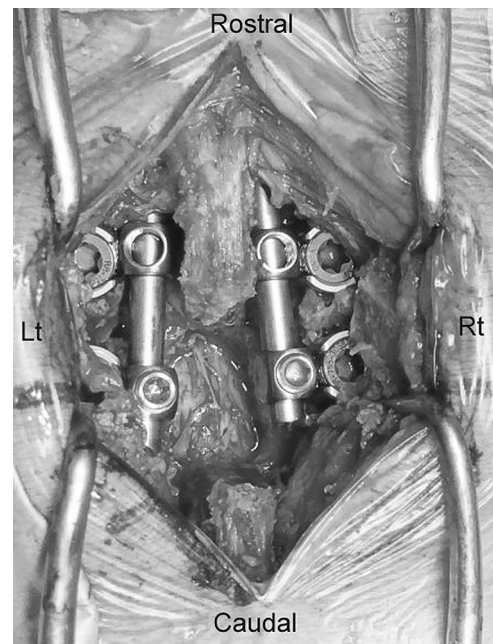


Fig. 2 Representative figure of the placed ADS system in the surgical field is shown. ADS: advanced dynamic stabilization, Lt.: left, Rt.: right.

lamina as decompression, disc removal, and the parallel insertion of intervertebral spacer filled with removed partial bone were performed according to conventional PLIF techniques. In cases with spondylolisthesis, a policy of strict slippage reduction was not applied, even if mild reduction was often intended. Porous titanium-coated polyetheretherketone spacers (ProSpace XP; Aesculap AG, Tuttlingen,

Germany) were used in all cases except the most recent case, in which porous tantalum spacers (TM Ardis; Zimmer, Warsaw, IN, USA) were used.

Table 2 Preoperative and postoperative radiological findings at stabilized or fused levels

	Advanced dynamic stabilization	Posterior lumbar interbody fusion	<i>P</i>
Number of spondylolistheis	7	10	NA
Preop. % Slip (%)	14.2 ± 4.3	16.7 ± 4.6	0.242
Postop. % Slip (%)	16.8 ± 2.5	7.1 ± 4.3	0.001*
Number of stabilized or fused levels	18	14	
Preop. disc angle (°)			
<i>Flexion</i>	1.4 ± 6.3	3.0 ± 5.0	0.286
<i>Extension</i>	7.5 ± 5.0	6.4 ± 3.9	0.531
<i>Range of motion</i>	6.1 ± 3.6	3.3 ± 3.9	0.055
Postop. disc angle (°)			
<i>Flexion</i>	3.7 ± 6.4	NA	NA
<i>Extension</i>	7.6 ± 5.9	NA	NA
<i>Range of motion</i>	4.0 ± 3.0	NA	NA
Preop. disc height (mm)	6.8 ± 2.3	5.0 ± 2.4	0.038*
Postop. disc height (mm)	5.9 ± 2.1	6.9 ± 2.3	0.189

SPSS ver. 24, Mann–Whitney U test. Postop.: postoperative, Preop.: preoperative, NA: not applicable

Statistical analysis

Continuous variables are expressed as mean ± standard deviation, and intergroup differences were compared using the χ^2 test or Mann–Whitney *U* test. Two-sided *P* < 0.05 was considered statistically significant. Statistical analyses were performed using SPSS version 24.0 (IBM Corp., Armonk, NY, USA).

Ethics

The analysis was approved by the ethics committee in our hospital (registration number: 164) and was performed in accordance with the Declaration of Helsinki.

Results

Clinical data

Preoperative and postoperative clinical data of patients who underwent ADS and PLIF were as follows (Table 1): postoperative follow-up, 459.3 ± 263.5 days and 507.7 ± 288.3 days; preoperative Japanese Orthopaedic Association (JOA) score (full score: 29), 14.4 ± 4.1 and 13.4 ± 4.5; postoperative JOA score, 24.1 ± 3.4 and 21.5 ± 3.7; and recovery rate of JOA score, 67.5 ± 18.5% and 50.1 ± 23.4%, respectively. Recovery rate of JOA score in ADS group was significantly high compared to PLIF group (*P* = 0.044). Preoperative low back pain in both groups relieved in all cases after surgery. Four patients without preoperative low back pain in ADS group also did not suffer from postoperative additional low back pain.

Radiological findings at dynamic stabilized and fused levels

ADS and PLIF were performed in 7 and 10 disc levels with spondylolisthesis, respectively, and % slip was 14.2 ± 4.3% and 16.7 ± 4.6% preoperatively; and 16.8 ± 2.5% and 7.1 ± 4.3% postoperatively (Table 2). Significant reduction of slip was achieved in the PLIF group, while no symptomatic deterioration was confirmed in the ADS group with postoperative mild progression of slippage.

In the ADS and PLIF groups, DH changed from 6.8 ± 2.3 mm and 5.0 ± 2.4 mm preoperatively to 5.9 ± 2.1 mm and 6.9 ± 2.3 mm postoperatively, respectively. DH was significantly increased in the PLIF group, while no marked loss was confirmed in the ADS group. ROM in the ADS group was suppressed from 6.1 ± 3.6° preoperatively to 4.0 ± 3.0° postoperatively (Table 2). ROM in the PLIF group, on the other hand, was not examined because the ideal intervertebral condition for PLIF should be complete fixation and the investigation of ROM appeared meaningless.

Radiological findings at UAD levels in both groups

In the ADS and PLIF groups, DH changed from 7.6 ± 2.3 mm and 7.8 ± 3.1 mm preoperatively to 7.1 ± 2.3 mm and 6.6 ± 3.3 mm postoperatively, respectively, with no significant changes. ROM was suppressed from 4.7 ± 2.9° preoperatively to 3.6 ± 2.6° postoperatively in the ADS group, but increased from 3.4 ± 4.1° preoperatively to 5.6 ± 2.8°

Table 3 Preoperative and postoperative radiological findings at upper adjacent disc level

	Advanced dynamic stabilization	Posterior lumbar interbody fusion	<i>P</i>
Preop. disc angle (°)			
<i>Flexion</i>	4.2 ± 4.3	5.5 ± 4.2	0.360
<i>Extension</i>	9.0 ± 4.5	8.9 ± 4.9	0.950
<i>Range of motion</i>	4.7 ± 2.9	3.4 ± 4.1	0.406
Postop. disc angle (°)			
<i>Flexion</i>	5.3 ± 4.8	5.6 ± 5.2	0.647
<i>Extension</i>	8.8 ± 5.0	11.2 ± 5.4	0.253
<i>Range of motion</i>	3.6 ± 2.6	5.6 ± 2.8	0.020*
Preop. disc height (mm)	7.6 ± 2.3	7.8 ± 3.1	0.819
Postop. disc height (mm)	7.1 ± 2.3	6.6 ± 3.3	0.429

SPSS ver. 24, Mann–Whitney U test. Preop.: preoperative, Postop.: postoperative

postoperatively, with significant hypermobility ($P = 0.029$) in the PLIF group (Table 3).

Additional analysis focused on patients with spondylolisthesis treated with either ADS or PLIF

As a reference, additional analysis focused on patients with spondylolisthesis was performed in an ADS group with 7 patients and a PLIF group with 10 patients. Regarding clinical data and radiological findings at fixed and upper UAD levels in the selected cases, almost all statistical results were similar to them in all cases. However, in the ADS and PLIF groups, different results compared with all cases were confirmed only for age (74.6 ± 6.7 and 66.1 ± 9.8 years, respectively; $P = 0.04$), and postoperative ROM at the UAD levels ($3.0 \pm 2.0^\circ$ and $5.2 \pm 3.1^\circ$, respectively; $P = 0.09$). Accurate comparison was impossible because of the small number of patients with spondylolisthesis in both groups and the difference in age between the groups, but the distinct tendency of postoperative hypermobility at the UAD level in the PLIF group compared with ADS group was still confirmed even if statistical significance was not achieved.

Discussion

Why is dynamic stabilization necessary?

In patients with lumbar spondylolisthesis or instability, PLIF is widely accepted as a management option in young or active age-groups because of the stable long-term outcome.¹⁻³⁾ In contrast, PLIF sometimes appears too destructive and invasive for patients more than 55 years with such pathophysiology. Furthermore, they often suffer from ASD with high prevalence in the early postoperative stage before receiving the benefits of PLIF.

Less-invasive decompression techniques might suppress the postoperative progression of instability to within a certain rate, but even such techniques could not resolve this problem completely.^{2,10)} In fact, we have encountered some patients who suffered from severe deformity several years after less-invasive decompression surgeries and needed revision fusion surgery.

In April 2016, two randomized clinical trials examined the utility of adding fusion when performing decompressive laminectomy for lumbar stenosis with grade 1 lumbar spondylolisthesis, reporting opposing conclusions.^{1,11)} Peter et al. reported on 247 randomized patients with lumbar stenosis with or without 1 or 2 level spondylolisthesis, and concluded that decompression surgery plus fusion surgery did not result in better clinical outcomes at 2 and 5 years compared to decompression surgery alone using the Oswestry Disability Index 2 years after surgery as the primary outcome.¹¹⁾ In contrast, Ghogawala et al.¹⁾ revealed that the fusion group had superior SF-36 physical-component summary scores as the primary outcomes compared to the decompression-alone group at 2–4 years postoperatively in patients with nonmobile, single-level, grade 1 spondylolisthesis. The origin of these conflicting results is still mysterious despite the comparison of randomized surgical interventions for a similar pathophysiology, so further debate and analysis are needed in future. However, decompression surgery plus fusion and decompression surgery alone including less-invasive decompression for lumbar spondylolisthesis or instability are poles apart as surgical concepts. In this respect, various types and mechanisms of dynamic stabilization should be considered more seriously.

Concept and variety of dynamic stabilization

As described above, the development of dynamic stabilization should be accelerated in terms of factors such as materials, concepts, mechanisms, and direction of dynamization. Actually, unfavorable data regarding prevention of ASD in a few former dynamic stabilization systems have been reported.¹²⁻²³⁾ Graf artificial ligament (SEM; Mountrouge, France) dynamic stabilization with bands connected to pedicle screws applied to the operated segment with lordosis force ultimately proved unsuccessful in terms of long-term preservation of motion at the operated level and prevention of ASD.^{16,18,19,23)} Dynesis (Zimmer) was designed as a second-generation dynamic stabilization system based on experience with Graf ligament-plasty, but again could not achieve the key expected purpose, that is, prevention of ASD.^{12-15,17,20-22)} However, even if these types of dynamic stabilization could not achieve the intended goal, other concepts and mechanisms of dynamic stabilization still have the possibility of achieving favorable final outcomes regarding ASD. The weakness of these previous dynamizations seemed to be the absence of movement in the perpendicular direction as a shock-absorber and the lack of a mechanism to stop rotatory movements at the operated level. Recently, reoperation rates and risk factors for revision 4 years after dynamic stabilizations allowing small movements in the sagittal plane (Ulrich Cosmic; Ulrich Medical, Ulm, Germany) for the lumbar spine have been reported.²⁴⁾ This large cohort and considerably long follow-up study demonstrated that revision rates for this dynamic stabilization via screw loosening and clinical ASD were compatible with the literature for conventional rigid instrumentation with spinal fusion. However, this dynamic stabilization system again does not include direct vertical movement. Furthermore, dynamic stabilization systems that allow only sagittal movements do not work as planned when the axes of rods are set unparallelled. This negative feature of dynamic stabilization only allowing for sagittal movements might be one of reasons that this study could not reveal any superiority regarding the prevention of ASD compared to conventional spinal fusion. Because our evolved dynamic stabilization readily allowed for movements in both perpendicular and sagittal directions, this feature appeared to share the increase in loading to UAD level in the ADS group compared with the PLIF group even in the short term, more than 1 year after operation.

Our dynamic stabilization is not intended to achieve the concept of arthroplasty, representing constant and permanent movements in conjunction with motion of the spine. As a concept of ADS, the share

of increased load at UAD level is expected.⁹⁾ We therefore tolerate long-term final fusion at the dynamically stabilized level, but patients more than 50 years who undergo ADS will receive benefits from delayed ASD compared to those who undergo PLIF.

Limitations

Our study was a retrospective analysis and the sample size was relatively small. Proper comparison of rates of clinical and radiological ASD in the mid-term and long term between ADS and conventional PLIF require further case-control studies using a matched cohort of selected patients who underwent ADS or PLIF, or, ideally, a prospective randomized control trial in a larger population. Furthermore, we have not understood yet why recovery rate of JOA score in ADS group was significantly high compared to PLIF group. However, our study suggests the important information that hypermobility in UAD level is already confirmed in the PLIF group compared to the ADS group even in the early stage more than 1 year postoperatively in patients more than 55 years.

Our study emphasized the rapid increase in loading at UAD levels in PLIF in the early stage more than 1 year after operation, so the follow-up period was properly short. In this short period, cases needing re-operation due to clinical ASD or increased instability because of screw loosening were not detected in ADS group. True analysis of re-operation rates and risk factors for revision after ADS or PLIF would need a minimum of 2-4 years after surgery.²⁴⁾ Our study should therefore be continued in future to present mid- and long-term outcomes, adding new patients.

Incidental statistical preoperative differences of DH at operated levels between groups might have been a certain degree of bias. As no significant differences in age, sex, JOA score, % slip, or ROM at the operated and upper adjacent level before surgery were evident between groups, we were not sure whether incidental preoperative lower DH at operated levels affected postoperative radiological changes at UAD level in the PLIF group. The distribution of preoperative pathophysiology in both groups might have included some bias. Actually, the distribution of diseases might not have affected outcomes at UAD level because the preoperative condition of the UAD level showed no significant differences between groups, at least in terms of ROM and DH.

Conclusion

Radiological hypermobility at UAD level was confirmed in the PLIF group compared to the ADS

group, even in the early stage more than 1 year after surgery in patients more than 55 years. ADS also revealed significantly good clinical outcomes without special complications compared to PLIF in the same period.

Previous dynamic stabilization has not yet proven to prevent ASD in the long term, but challenges with various types of dynamic stabilizations should be continued to resolve mid- to long-term clinical ASD in lumbar interbody fusion.

Acknowledgement

We are grateful to the radiologists of my hospital for their prompt preoperative radiological examinations and image processing work. The authors would like to thank FORTE for the English language review.

Conflicts of Interest Disclosure

All authors have no conflict of interest.

References

- 1) Ghogawala Z, Dziura J, Butler WE, et al.: Laminectomy plus fusion versus laminectomy alone for lumbar spondylolisthesis. *N Engl J Med* 374: 1424–1434, 2016
- 2) Ghogawala Z, Resnick DK, Glassman SD, Dziura J, Shaffrey CI, Mummaneni PV: Achieving optimal outcome for degenerative lumbar spondylolisthesis: randomized controlled trial results. *Neurosurgery* 64(CN_suppl_1): 40–44, 2017
- 3) Trouillier H, Birkenmaier C, Rauch A, Weiler C, Kauschke T, Refior HJ: Posterior lumbar interbody fusion (PLIF) with cages and local bone graft in the treatment of spinal stenosis. *Acta Orthop Belg* 72: 460–466, 2006
- 4) Cheh G, Bridwell KH, Lenke LG, et al.: Adjacent segment disease following lumbar/thoracolumbar fusion with pedicle screw instrumentation: a minimum 5-year follow-up. *Spine* 32: 2253–2257, 2007
- 5) Kaito T, Hosono N, Mukai Y, Makino T, Fuji T, Yonenobu K: Induction of early degeneration of the adjacent segment after posterior lumbar interbody fusion by excessive distraction of lumbar disc space. *J Neurosurg Spine* 12: 671–679, 2010
- 6) Nakai S, Yoshizawa H, Kobayashi S: Long-term follow-up study of posterior lumbar interbody fusion. *J Spinal Disord* 12: 293–299, 1999
- 7) Park P, Garton HJ, Gala VC, Hoff JT, McGillicuddy JE: Adjacent segment disease after lumbar or lumbosacral fusion: review of the literature. *Spine* 29: 1938–1944, 2004
- 8) Seitsalo S, Schlenzka D, Poussa M, Osterman K: Disc degeneration in young patients with isthmic spondylolisthesis treated operatively or conservatively: a long-term follow-up. *Eur Spine J* 6: 393–397, 1997
- 9) Ohtonari T, Nishihara N, Suwa K, Ota T, Koyama T: Dynamic stabilization for degenerative spondylolisthesis and lumbar spinal instability. *Neurol Med Chir (Tokyo)* 54: 698–706, 2014
- 10) Chang HS, Fujisawa N, Tsuchiya T, Oya S, Matsui T: Degenerative spondylolisthesis does not affect the outcome of unilateral laminotomy with bilateral decompression in patients with lumbar stenosis. *Spine* 39: 400–408, 2014
- 11) Försth P, Ólafsson G, Carlsson T, et al.: A randomized, controlled trial of fusion surgery for lumbar spinal stenosis. *N Engl J Med* 374: 1413–1423, 2016
- 12) Bothmann M, Kast E, Boldt GJ, Oberle J: Dynesys fixation for lumbar spine degeneration. *Neurosurg Rev* 31: 189–196, 2008
- 13) Cakir B, Carazzo C, Schmidt R, Mattes T, Reichel H, Käfer W: Adjacent segment mobility after rigid and semirigid instrumentation of the lumbar spine. *Spine* 34: 1287–1291, 2009
- 14) Chou D, Lau D, Skelly A, Ecker E: Dynamic stabilization versus fusion for treatment of degenerative spine conditions. *Evid Based Spine Care J* 2: 33–42, 2011
- 15) Grob D, Benini A, Junge A, Mannion AF: Clinical experience with the Dynesys semirigid fixation system for the lumbar spine: surgical and patient-oriented outcome in 50 cases after an average of 2 years. *Spine* 30: 324–331, 2005
- 16) Guigui P, Chopin D: Assessment of the use of the Graf ligamentoplasty in the surgical treatment of lumbar spinal stenosis. Apropos of a series of 26 patients. *Rev Chir Orthop Reparatrice Appar Mot* 80: 681–688, 1994
- 17) Haddad B, Makki D, Konan S, Park D, Khan W, Okafor B: Dynesys dynamic stabilization: less good outcome than lumbar fusion at 4-year follow-up. *Acta Orthop Belg* 79: 97–103, 2013
- 18) Hadlow SV, Fagan AB, Hillier TM, Fraser RD: The Graf ligamentoplasty procedure. Comparison with posterolateral fusion in the management of low back pain. *Spine* 23: 1172–1179, 1998
- 19) Kanayama M, Hashimoto T, Shigenobu K, Togawa D, Oha F: A minimum 10-year follow-up of posterior dynamic stabilization using Graf artificial ligament. *Spine* 32: 1992–1996; discussion 1997, 2007
- 20) Kelly MP, Mok JM, Berven S: Dynamic constructs for spinal fusion: an evidence-based review. *Orthop Clin North Am* 41: 203–215, 2010
- 21) Korovessis P, Papazisis Z, Koureas G, Lambiris E: Rigid, semirigid versus dynamic instrumentation for degenerative lumbar spinal stenosis: a correlative radiological and clinical analysis of short-term results. *Spine* 29: 735–742, 2004

- 22) Kumar A, Beastall J, Hughes J, et al.: Disc changes in the bridged and adjacent segments after Dynesys dynamic stabilization system after two years. *Spine* 33: 2909–2914, 2008
- 23) Rigby MC, Selmon GP, Foy MA, Fogg AJ: Graf ligament stabilisation: mid- to long-term follow-up. *Eur Spine J* 10: 234–236, 2001
- 24) Rienmüller AC, Krieg SM, Schmidt FA, Meyer EL, Meyer B: Reoperation rates and risk factors for revision 4 years after dynamic stabilization of the lumbar spine. *Spine J* 19: 113–120, 2019

Address reprint requests to: Tatsuya Ohtonari, MD, PhD,
Department of Spinal Surgery, Brain Attack Center,
Ota Memorial Hospital, 3-6-28 Okinogami,
Fukuyama, Hiroshima 720-0825, Japan
e-mail: ohtonari@shouwa.or.jp