

A comparative study on anti-hyperalgesia effect of MTA and Ketoprofen in inflammatory pain

Fatemeh Abbasipour¹, Hengameh Bakhtiar², Mehdi Vatanpour³, Habib Khalilkhani⁴, Hassan Torabzadeh⁵, Mahyar Janahmadi^{6*}

1. Dental Student, Neuroscience Research Centre and Department of Physiology, Medical School, Shahid Beheshti University of Medical Sciences and Endodontic Department, Dental School, Islamic Azad University of Medical Sciences, Tehran, Iran.

2. Department of Endodontics, Dental School, Islamic Azad University of Medical Sciences, Tehran, Iran.

3. Department of Endodontics, Dental School, Islamic Azad University of Medical Sciences, and Member of Iranian Center for Endodontic Research, Tehran, Iran.

4. Endodontist, Neuroscience Research Centre and Department of Physiology, Medical School, Shahid Beheshti University of Medical Sciences, Tehran, Iran.

5. Department of Dental Material Science, Dental School, Shahid Beheshti University of Medical Sciences, Tehran, Iran.

6. Department of physiology, Neuroscience Research Centre, Medical School, and Iranian Centre for Endodontic Research, Shahid Beheshti University of Medical Sciences, Tehran, Iran.

ABSTRACT

INTRODUCTION: Mineral trioxide aggregate (MTA) is an endodontic material with different clinical applications *e.g.* root-end filling, pulp capping and perforation repair. It has been reported to possess antimicrobial and antifungal activities. The aim of this study was to examine the effect of White MTA on formalin-induced hyperalgesia in a rat with inflammatory pain.

MATERIALS AND METHODS: Inflammatory pain was induced by subcutaneous (SC) injection of formalin (40 μ L, 2.5%) into the rat upper lip. The nociceptive behavioral responses *i.e.* shaking of the lower jaw and face rubbing were quantified. 40 μ L of eugenol (50 mg/kg), WMTA (20 mg/0.2 mL) or ketoprofen were injected solely or in combination with formalin 2.5% and the behavioral responses were compared with those observed after formalin treatment alone. One-way ANOVA, Tukey were used for analysis of data.

RESULTS: Formalin 2.5% provoked a biphasic nociceptive response, with an early and short lasting first tonic phase followed by a second phase. Solely SC injection of either WMTA or ketoprofen (a non steroidal anti-inflammatory drug) did not stimulate any significant nociceptive behaviour. However, injection of eugenol (a pain relieving agent) induced the early phase not the tonic phase of nociceptive response. WMTA, eugenol or ketoprofen injection 20 min before formalin injection attenuated the first phase but somehow prevented the induction of the second phase of nociceptive responses which were produced by formalin. Behavioural nociceptive responses including shaking of the lower jaw and face rubbing were significantly reduced when the subject was pretreated with either WMTA or ketoprofen ($P < 0.001$).

CONCLUSION: In this study, WMTA induced pain reduction by suppression of the formalin-induced nociceptive response.

Keywords: Formalin test, Inflammatory pain, Ketoprofen, Mineral trioxide aggregate, Orofacial

Received: 29 Oct 2008; **Revised:** 18 Feb 2009; **Accepted:** 02 Apr 2009

*Corresponding author at: Mahyar Janahmadi, Neuroscience Research Center, Faculty of Medicine, Shahid Beheshti University of Medical Sciences, Evin, Tehran, Iran, PO Box 19615-1178. Tel: +98-9121483513. E-mail: Janahmadi@sbmu.ac.ir

INTRODUCTION

Orofacial pain may be a result of endodontic pathology (1,2). Tissue acidification occurring after dental pulp inflammation with/without periapical lesions may result into orofacial pain (3). It can also significantly contribute to postoperative pain (4). Dental materials in

direct contact with the oral tissues may also cause inflammatory reactions. Mineral trioxide aggregate (MTA) is a dental material commonly used for root-end fillings, pulp capping and perforation repairs (5-11). MTA possess adequate physical (12,13), chemical (14,15) and biological (16) properties. It has been also reported to be a non-cytotoxic

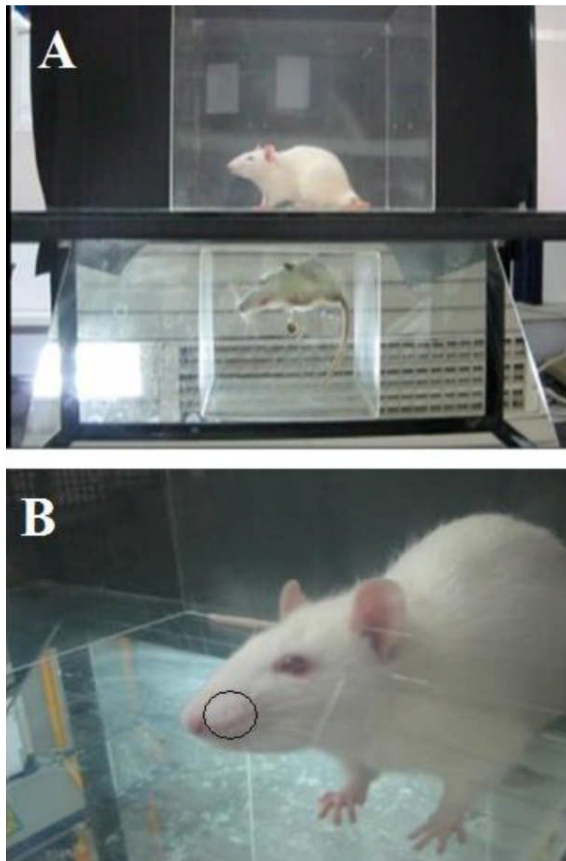


Figure 1. A) Observation box: After injection of each drug, the rat was placed in a plexiglass observation box. B) Injection site: Each drug was injected into the upper lip ipsilaterally, just lateral to the nose. Formalin induced inflammation at the injection site.

(15,17-19) and non-genotoxic (20,22,23) dental material. The antibacterial (23,24) and antifungal (25-27) activities of MTA have also been documented. In orofacial formalin tests on animal models, nociception was mediated by craniofacial sensory afferent neurons; assessments of the magnitude of nociceptive sensations were elicited by long-lasting supra-threshold chemical stimulus (28,29). Trigeminal nerve innervates the orofacial regions. It also carries the pain impulses of this region *i.e.* teeth and surrounding structures (30). Subcutaneous (SC) injection of dilute formalin has been shown to activate unmyelinated polymodal nociceptors (31) and produce inflammatory pain. Tissue inflammation results in release of inflammatory mediators such as prostaglandins causing hyperalgesia (32). Ketoprofen (KP) is a nonsteroidal anti-inflammatory drug (NSAID); it has inhibitory effect on inflammatory mediators (33) and provides effective analgesia in the

presence of tissue inflammation. Eugenol, a phenolic dental medicament, has been widely used as a topical sedative of pain and inflammation for pulpitis and dentine hyperalgesia (34). In the present study, the suppressive effect of WMTA against formalin-induced inflammatory pain in the orofacial region of rats was investigated and compared with the analgesic effects of ketoprofen and eugenol.

MATERIALS AND METHODS

This study was approved by Ethical committee of Shahid Beheshti Medical University. Experiments were performed on male Sprague-Dawley rats ($n=69$, 180–200 g) housed at $23 \pm 1^\circ\text{C}$ and 12-h light/dark cycles, acclimatized to the laboratory conditions for at least 72 h before use, with free access to food and water. Tests were carried out during the light phase (between 10:00 am and 5:00 pm) in a silent room. Animals were tested once and were then sacrificed at the end of experiments.

All solutions were administered by SC injection ($40 \mu\text{L}$). Drug doses were chosen based on pilot or preliminary experiments using values from the literature and our previous work (35). The 2.5% formalin was prepared by diluting the stock aqueous 37% formaldehyde solution (Sigma, UK) in 0.9% isotonic saline. MTA was prepared according to the manufacturer's instruction.

Animals were assigned to five treatment groups: (1) formalin 2.5% ($n=10$); (2) injections of eugenol alone (50 mg/kg, $n=10$) or eugenol followed by formalin 2.5% ($n=10$) 20 min later; (3) WMTA (20 mg dissolved in 0.2 mL saline, $n=10$) alone or injection of WMTA ($n=10$) 20 min prior to formalin treatment; (4) ketoprofen (30 mg/kg, $n=3$) alone or ketoprofen followed by formalin ($n=10$) 20 min later and (5) saline $40 \mu\text{L}$ ($n=3$), as a vehicle or no treatment (needle insertion only $n=3$).

The orofacial formalin test was performed according to Clavelou *et al.* (29) and Raboisson and Dallel (30). That is, before the injection, each rat was placed in a transparent plexiglass observation chamber ($30 \times 30 \times 30 \text{ cm}^3$ with a mirror placed at an angle of 45°) for 30 min, in order to minimize stress-related behaviours Figure 1A. They received a SC $40 \mu\text{L}$ injection

of test materials into the upper lip, just lateral to the nose Figure 1B, using a 30-gauge sterile needle. The rats were immediately returned to the transparent box for a 45-min observation. Rubbing of the injected area was regarded as the parameter of nociceptive response. Duration of nociceptive response was cumulatively recorded using a stopwatch, in consecutive 5-min intervals over a 45-min period, and was considered as an index of nociception. The nociceptive response was clearly biphasic with the first-neurogenic-phase peak occurring at approximately 5 mins after formalin injection and subsiding transiently over the next 5 mins. The second-inflammatory-phase peaked between 20-25 min. Responses that occurred during the first 5-10 min period following formalin injection were recorded as the first phase of nociception, and those occurring between 20 and 35 min as the second phase. Response scoring was performed according to Clavelou *et al.* (29). This score was based on four scales including 0 for normal behaviour *e.g.* grooming; 1, abnormal head movements; 2, abnormal continuous shaking of the lower jaw; 3, excessive rubbing of the mouth. Nociceptive scores were calculated with 5-min intervals at the end of observation, according to the following formula (T=time): Nociceptive score = [(1×T in scale 1) + (2×T in scale 2) + (3×T in scale 3)]/ 300 s (31,36).

The nociceptive behavioural responses were averaged into 5-min intervals to decrease minute by minute variability.

The results were expressed as mean ± S.E.M. Parametric tests [two tailed student *t*-test and ANOVA (analysis of variance with post hoc comparisons via Tukey's HSD test)] and appropriate statistical software (Version 6, StatSoft, Tulsa, USA) were used. $P < 0.05$ was considered significant.

RESULTS

SC injection of 40 µL of formalin 2.5% elicited a typical biphasic nociceptive time course with early or short lasting phase (5-10 min) followed by a second prolonged tonic phase (20-30 min) that subsided after 45 minutes Figure 2. Rats showed shaking of the lower jaw Figures 3A and B and then sustained face rubbing episodes Figures 3C and D. Administration of

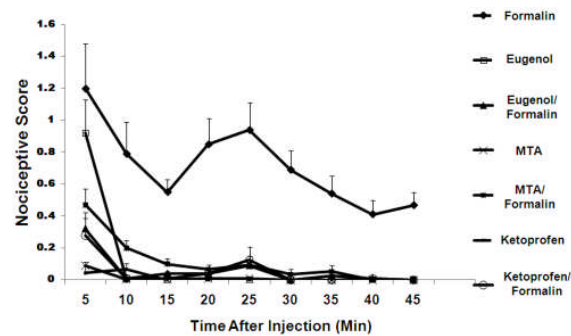


Figure 2. Effect of different treatments on nociceptive scores recorded in different conditions.

WMTA, Eugenol and Ketoprofen before the formalin injections all statistically reduced pain.

Injection with WMTA alone did not cause nociceptive response (Figures 2 and 3). Also the injection of WMTA 20 min prior to formalin resulted in a decrease in nociceptive score (Figure 2) and significant reduction in lower jaw shaking and face rubbing in both behavior phases ($P < 0.001$) (Figure 3). Eugenol injections either alone or 20 min before formalin treatment induced less persistent behavioral score. Injection of eugenol alone did not completely eliminate the first phase of pain behaviour but caused a significant decrease in the related face rubbing compared to formalin injection alone, while almost completely abolished the face rubbing in the second phase of nociceptive behaviour (Figures 3A and B). Ketoprofen, a NSAID, when administered 20 min before formalin injection elicited a strong inhibitory effect on the hyperalgesic reaction caused by formalin during the both phases of pain responses (Figures 2 and 3). Interestingly, no significant difference was observed between the suppressive effects of ketoprofen and WMTA (with or without formalin) both on the lower jaw shaking and face rubbing. Here, saline did not induce statistically significant nociceptive responses *per se*.

DISCUSSION

The orofacial region is one of the most densely innervated areas of the body; this region is involved in nociceptive signalling (30,38). Formalin SC injection into the bilateral upper lip causes a biphasic nociceptive response which is useful for clinical pain studies (28).

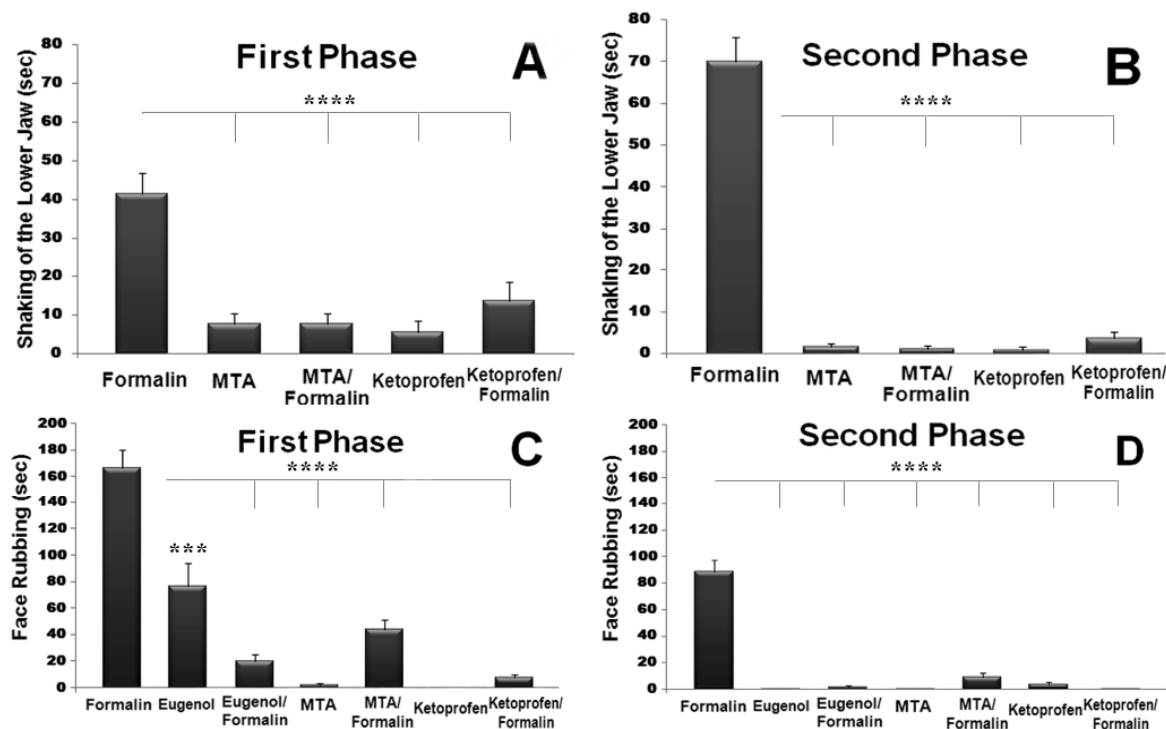


Figure 3. Effect of different treatments on the first (A) and the second (B) phases of shaking of the lower jaw and (C) the first phase (5-10 min post injection) and (D) the second phase (20-35 min post injection) of face rubbing nociceptive responses. Asterisks represent a significant difference as compared to formalin response.

The primary phases after formalin application has been attributed to a direct activation of C-fiber nociceptors; while the second and more persisted inflammatory phase is generally believed to be due to the local release of inflammatory mediators (37,39).

Information about physiological and biological aspects of root-end filling materials such as MTA is important for their clinical use. MTA has become a popular material to seal communication between the root canal system and external environment (40,41). It has also been recommended for root perforations, root end filling and apexification (42,43). MTA is commercially available in two different versions: grey-colored (GMTA) and white-colored. Both have been reported to consist of fine hydrophilic particles, but with slightly different composition (15). Both gray MTA and white MTA have been reported to produce effective antifungal (25-27) and antimicrobial (24) activities, which could be attributed to calcium hydroxide release or presumably be due to its high pH. These two factors have been reported to be responsible for the biocompatibility of MTA (8,44). It has been shown that Ca^{2+} release from MTA could be the

main factor that contributed to pulp repair (45).

In the present study the exact mechanism responsible for the anti-inflammatory pain reduction of MTA has not been determined; but we can speculate that the high pH induced by MTA may be contributory. It has been shown that protons can evoke pain through acid-sensing ion channel (ASICs) activation (46), which is present in primary sensory neurons of the trigeminal nerve (47). Therefore, high pH produced by MTA may eliminate the low pH induced by inflammatory mediators.

It is suggested that tissue injury caused by direct formalin injection in the orofacial area might be as a result of the production of prostaglandin, which in turn induces inflammatory pain (32). Ketoprofen is a non-steroidal anti-inflammatory drug which effectively kills inflammatory pain in different animal models as well as humans (46,47). Our findings showed that the anti-inflammatory pain activity of white ProRoot MTA is almost comparable to ketoprofen, as an anti-inflammatory pain reducing agent. Injection of a pain relieving agent (eugenol) produced the early short-lasting pain behaviour, but not the second tonic response.

CONCLUSION

This study suggests that white MTA does not appear to have any irritant effect on the nerve tissue and its anti-inflammatory pain reduction is comparable to ketoprofen, more effective than eugenol. MTA behaved as a palliative agent in this experimental animal model, further research is required to confirm the anti-inflammatory and analgesic properties of MTA.

ACKNOWLEDGEMENT

This work was supported by a grant from Neuroscience Research Center of Shahid Beheshti Medical University.

Conflict of Interest: 'None declared'.

REFERENCES

1. Campbell RL, Parks KW, Dodds RN. Chronic facial pain associated with endodontic therapy. *Oral Surg Oral Med Oral Pathol.* 1990;69:287-90.
2. Matwychuk MJ. Diagnostic challenges of neuropathic tooth pain. *J Can Dent Assoc.* 2004;70:542-6.
3. Rukwied R, Chizh BA, Lorenz U, Obreja O, Margarit S, Schley M, Schmelz M. Potentiation of nociceptive responses to low pH injections in humans by prostaglandin E₂. *J Pain.* 2007;8:443-51.
4. Woo YC, Park SS, Subieta AR, Brennan TJ. Changes in tissue pH and temperature after incision indicate acidosis may contribute to postoperative pain. *Anesthesiology.* 2004;101:468-75.
5. Lee SJ, Monsef M, Torabinejad M. Sealing ability of a mineral trioxide aggregate for repair of lateral root perforations. *J Endod.* 1993;19:541-4.
6. Torabinejad M, Chivian N. Clinical applications of mineral trioxide aggregate. *J Endod.* 1999;25:197-205.
7. Schwartz RS, Mauger M, Clement DJ, Walker WA 3rd. Mineral trioxide aggregate: a new material for endodontics. *J Am Dent Assoc.* 1999;130:967-75.
8. Holland R, de Souza V, Murata SS, Nery MJ, Bernabé PF, Otoboni Filho JA, Dezan Júnior E. Healing process of dog dental pulp after pulpotomy and pulp covering with mineral trioxide aggregate or Portland cement. *Braz Dent J.* 2001;12:109-13.
9. Aeinehchi M, Eslami B, Ghanbariha M, Saffar AS. Mineral trioxide aggregate (MTA) and calcium hydroxide as pulp-capping agents in human teeth: a preliminary report. *Int Endod J.* 2003;36:225-31.
10. Main C, Mirzayan N, Shabahang S, Torabinejad M. Repair of root perforations using mineral trioxide aggregate: a long-term study. *J Endod.* 2004;30:80-3.
11. Accorinte ML, Loguercio AD, Reis A, Bauer JR, Grande RH, Murata SS, Souza V, Holland R. Evaluation of two mineral trioxide aggregate compounds as pulp-capping agents in human teeth. *Int Endod J.* 2009;42:122-8.
12. Roberts HW, Toth JM, Berzins DW, Charlton DG. Mineral trioxide aggregate material use in endodontic treatment: a review of the literature. *Dent Mater.* 2008;24:149-64.
13. Bidar M, Moradi S, Jafarzadeh H, Bidad S. Comparative SEM study of the marginal adaptation of white and grey MTA and Portland cement. *Aust Endod J.* 2007;33:2-6.
14. Torabinejad M, Hong CU, McDonald F, Pitt Ford TR. Physical and chemical properties of a new root-end filling material. *J Endod.* 1995;21:349-53.
15. Camilleri J, Montesin FE, Brady K, Sweeney R, Curtis RV, Ford TR. The constitution of mineral trioxide aggregate. *Dent Mater.* 2005;21:297-303.
16. Economides N, Pantelidou O, Kokkas A, Tziafas D. Short-term periradicular tissue response to mineral trioxide aggregate (MTA) as root-end filling material. *Int Endod J.* 2003;36:44-8.
17. Torabinejad M, Hong CU, Pitt Ford TR, Kettering JD. Cytotoxicity of four root end filling materials. *J Endod.* 1995;21:489-92.
18. Torabinejad M, Pitt Ford TR, McKendry DJ, Abedi HR, Miller DA, Kariyawasam SP. Histologic assessment of mineral trioxide aggregate as a root-end filling in monkeys. *J Endod.* 1997;23:225-8.
19. Keiser K, Johnson CC, Tipton DA. Cytotoxicity of mineral trioxide aggregate using human periodontal ligament fibroblasts. *J Endod.* 2000;26:288-91.
20. Huang TH, Ding SJ, Hsu TC, Kao CT. Effects of mineral trioxide aggregate (MTA) extracts on mitogen-activated protein kinase activity in human osteosarcoma cell line (U2OS). *Biomaterials.* 2003;24:3909-13.
21. Braz MG, Camargo EA, Salvadori DM, Marques ME, Ribeiro DA. Evaluation of genetic damage in human peripheral lymphocytes exposed to mineral trioxide aggregate and Portland cements. *J Oral Rehabil.* 2006;33:234-9.
22. Ribeiro DA, Sugui MM, Matsumoto MA, Duarte MA, Marques ME, Salvadori DM. Genotoxicity and cytotoxicity of mineral trioxide aggregate and regular and white Portland cements on Chinese hamster ovary (CHO) cells in vitro. *Oral Surg Oral Med Oral Pathol Oral Radiol Endod.* 2006;101:258-61.
23. Eldeniz AU, Hadimli HH, Ataoglu H, Orstavik D. Antibacterial effect of selected root-end filling materials. *J Endod.* 2006;32:345-9.

24. Tanomaru-Filho M, Tanomaru JM, Barros DB, Watanabe E, Ito IY. In vitro antimicrobial activity of endodontic sealers, MTA-based cements and Portland cement. *J Oral Sci.* 2007;49:41-5.
25. Al-Nazhan S, Al-Judai A. Evaluation of antifungal activity of mineral trioxide aggregate. *J Endod.* 2003;29:826-7.
26. Al-Hezaimi K, Naghshbandi J, Oglesby S, Simon JH, Rotstein I. Comparison of antifungal activity of white-colored and gray-colored mineral trioxide aggregate (MTA) at similar concentrations against *Candida albicans*. 2006 *J Endod.* 2006;32:365-7.
27. Al-Hezaimi K, Al-Hamdan K, Naghshbandi J, Oglesby S, Simon JH, Rotstein I. Effect of white-colored mineral trioxide aggregate in different concentrations on *Candida albicans* in vitro. *J Endod.* 2005;31:684-6.
28. Clavelou P, Pajot J, Dallel R, Raboisson P. Application of the formalin test to the study of orofacial pain in the rat. *Neurosci Lett.* 1989;103:349-53.
29. Clavelou P, Dallel R, Orliaguet T, Woda A, Raboisson P. The orofacial formalin test in rats: effects of different formalin concentrations. *Pain.* 1995;62:295-301.
30. Raboisson P, Dallel R. The orofacial formalin test. *Neurosci Biobehav Rev.* 2004;28:219-26.
31. Chidiac JJ, Rifai K, Hawwa NN, Massaad CA, Jurjus AR, Jabbur SJ, Saadé NE. Nociceptive behaviour induced by dental application of irritants to rat incisors: a new model for tooth inflammatory pain. *Eur J Pain.* 2002;6:55-67.
32. Padi SS, Naidu PS, Kulkarni SK. Involvement of peripheral prostaglandins in formalin-induced nociceptive behaviours in the orofacial area of rats. *Inflammopharmacology.* 2006;14:57-61.
33. Pinaridi G, Sierralta F, Miranda HF. Interaction between the antinociceptive effect of ketoprofen and adrenergic modulatory systems. *Inflammation.* 2001;25:233-9.
34. Abbasipour F, Rastqar A, Bakhtiar H, Khalilkhani H, Aeinehchi M, Janahmadi M. The nociceptive and anti-nociceptive effects of white mineral trioxide aggregate. *Int Endod J.* 2009;42:794-801.
35. Abbasipour F, Rastqar A, Bakhtiar H, Khalilkhani H, Aeinehchi M, Janahmadi M. The nociceptive and anti-nociceptive effects of white mineral trioxide aggregate. *Int Endod J.* 2009;42:794-801.
36. Dubuisson D, Dennis SG. The formalin test: a quantitative study of the analgesic effects of morphine, meperidine, and brain stem stimulation in rats and cats. *Pain.* 1997;4:161-74.
37. Franklin KB, Abbott FV. Techniques for assessing the effects of drugs on nociceptive responses. *Neuromethods.* 1989;13:145-8.
38. Jahnsen H. Responses of neurons in isolated preparations of the mammalian central nervous system. *Prog Neurobiol.* 1986;27:351-72.
39. Tjølsen A, Berge OG, Hunskaar S, Rosland JH, Hole K. The formalin test: an evaluation of the method. *Pain.* 1992;51:5-17.
40. Torabinejad M, Rastegar AF, Kettering JD, Pitt Ford TR. Bacterial leakage of mineral trioxide aggregate as a root-end filling material. *J Endod.* 1995;21:109-12.
41. Wu MK, Kontakiotis EG, Wesselink PR. Long-term seal provided by some root-end filling materials. *J Endod.* 1998;24:557-60.
42. Göhring KS, Lehnert B, Zehnder M. Uses of MTA, a review. Part 2: Clinical applications. *Schweiz Monatsschr Zahnmed.* 2004;114:222-34.
43. Parirokh M, Asgary S, Eghbal MJ, Stowe S, Eslami B, Eskandarizade A, Shabahang S. A comparative study of white and grey mineral trioxide aggregate as pulp capping agents in dog's teeth. *Dent Traumatol.* 2005;21:150-4.
44. Sarkar NK, Caicedo R, Ritwik P, Moiseyeva R, Kawashima I. Physicochemical basis of the biologic properties of mineral trioxide aggregate. *J Endod.* 2005;31:97-100.
45. Bortoluzzi EA, Broon NJ, Bramante CM, Consolaro A, Garcia RB, de Moraes IG, Bernadineli N. Mineral Trioxide Aggregate with or without Calcium Chloride in Pulpotomy. *J Endod.* 2008;34:172-5.
46. Chen CC, England S, Akopian AN, Wood JN. A sensory neuron-specific, proton-gated ion channel. *Proc Natl Acad Sci U S A.* 1998;95:10240-5.
47. Lingueglia E. Acid-sensing ion channels in sensory perception. *J Biol Chem.* 2007;282:17325-9.
48. Naito H, Okumura T, Inoue M, Suzuki Y. Ultrasonic vocalization response elicited in adjuvant-induced arthritic rats as a useful method for evaluating analgesic drugs. *Exp Anim.* 2006;55:125-9.
49. Zippel H, Wagenitz A. Comparison of the efficacy and safety of intravenously administered dexketoprofen trometamol and ketoprofen in the management of pain after orthopaedic surgery: A multicentre, double-blind, randomised, parallel-group clinical trial. *Clin Drug Investig.* 2006;26:517-28.