

THE EXTRACARDIAC ANASTOMOSES OF THE CORONARY ARTERIES

By CHARLES L. HUDSON, M.D., ALAN R. MORITZ, M.D., AND
JOSEPH T. WEARN, M.D.

(From the Department of Medicine and the Institute of Pathology of Western Reserve University, and the Department of Medicine of Lakeside Hospital, Cleveland)

PLATES 51 TO 53

(Received for publication, July 29, 1932)

In a series of experiments planned for the purpose of injecting the vessels in the heart valves, a colloidal suspension of carbon particles was injected into the coronary arteries of human hearts which had been excised at autopsy. When one came to study the injected specimens it was soon observed not only that the vessels in the heart were filled with the carbon particles but also that the arteries in attached flaps of the parietal pericardium contained the injection mass. Further observation showed that an extensive network of vessels in the adventitia of the aorta and pulmonary artery was also injected.

These observations led to a more thorough study of the extracardiac anastomoses of the coronary arteries. The results of this investigation are reported here.

The literature furnishes little if any detailed description of the extracardiac anastomoses of the coronary arteries. The most instructive paper is that of Langer (4) who, during a study of the Thebesian vessels by coronary artery injection, described branches of the coronary arteries anastomosing with vessels in the mediastinum, the parietal pericardium, the diaphragm and the hila of the lungs. Woodruff (10) in 1926 called attention to anastomoses of branches of the coronary arteries with the vasa vasorum of the ascending aorta. In 1928 Wearn (9) noted that on injecting the coronary arteries with India ink or Berlin blue the vessels in the ascending aorta were filled with the injection mass. Robertson (6) in 1930 pointed out the importance of the arteries of the fat pads of the heart in the presence of disease of the coronary arteries. He discussed also the anastomoses of branches of the coronary arteries with the periadventitial vessels of the ascending aorta and other vessels of the thorax. Several reviews of the literature including those of Gross, 1921 (2), Mönckeberg, 1924 (5), Spalteholz, 1924 (7),

Warburg, 1930 (8) and Karsner (3), have mentioned the extracardiac coronary anastomoses.

The exact extent and origin of the extracardiac anastomoses of the coronary arteries with the arteries of the nearby tissues and structures have not been clearly defined or described. Even their presence is not generally known. In view of this fact and with the possibility in mind that these anastomoses may be of important physiological and pathological significance, this investigation was undertaken.

EXPERIMENTAL

The injection method employed was that described by Bromer, Zschiesche and Wearn (1). Glass cannulae were inserted and tied into the coronary arteries from within the aorta through a longitudinal slit in the aortic wall. The injection mass used was a 3 per cent suspension of lamp black and 5 per cent acacia in distilled water. In some instances India ink diluted with an equal part of distilled water was used and found satisfactory. The injection mass was warmed to 40°C. and specimens were injected in a water bath at about the same temperature and massaged during injection. In a few experiments a suspension of 10 per cent bismuth oxychloride and 6 per cent acacia (approximately) in distilled water was used instead of the carbon suspension.

The cannulae were connected by short pieces of rubber tubing to a Keyes two-way stop-cock so that either negative or positive pressure could be used. At the beginning of the experiment, suction was applied for a few minutes while the heart was being massaged, to withdraw air and blood from the vessels. The mass was then injected under a positive pressure of 220 mm. of mercury for 5 minutes or longer.

The extent of the anastomoses demonstrated depended in some degree upon the type of specimen injected. In some cases the coronary arteries were injected with the heart *in situ*. This was accomplished after removal of the anterior thoracic wall by cannulating the coronary arteries through a small incision in the aorta. The surrounding structures were disturbed as little as possible. Satisfactory injections of specimens were obtained, however, in eviscerated preparations, where the thoracic organs, the diaphragm and the abdominal viscera were removed *en bloc*, and care was taken to keep the pericardium intact around the openings of the great veins. The presence of intact pericardium around the root of the aorta and pulmonary artery was not so essential to a satisfactory extracardiac injection as was the presence of undamaged pericardial reflections around the great veins.

After the injection was completed, the vessels were described and sketched and the entire specimen was placed in 10 per cent formalin for from 24 to 48 hours. Blocks were cut and sections prepared to demonstrate the presence of intravascular

injection mass microscopically. Thirty-one specimens were injected in this manner, of which number, twelve consisted of heart and parietal pericardium; eight of heart, parietal pericardium and diaphragm; and five of heart, parietal pericardium, lungs and diaphragm. Four others were the eviscerated thoracic organs without any dissection and two were injected *in situ*.

Careful study of the injected material revealed extensive anastomoses between the coronary arteries and the vessels of the neighboring organs and other structures. These extracardiac branches of the coronary arteries emerged from the heart in several regions and were constant in the material studied, no variations of moment being noted. Among the more common sites of emergence were (1) around the root of the aorta; (2) around the base of the pulmonary artery; (3) around the pulmonary veins; (4) around the ostia of the superior and inferior venae cavae, and (5) in the intervascular pericardial reflections. A more detailed description of these vessels follows:

1. The vessels emerging around the root of the aorta were direct branches of the coronary arteries arising near the aorta and extensions of the branches to the pericardial fat pads into the adventitia of the aorta. The largest injected vessels were found just above the aortic valve on the anterior surface of the aorta. The vasa vasorum within the wall of the aorta, as well as the arteries and arterioles in the adventitial and periadventitial connective tissue, were injected regularly from the aortic ring to the diaphragm and occasionally for a short distance below the diaphragm. These vasa vasorum were also injected in part through anastomoses with the pericardial, mediastinal and diaphragmatic vessels.

2. The vessels emerging at the base of the pulmonary artery were either within the wall of or closely adherent to the artery and its branches. They maintained these positions even after the branches were well within the substance of the lungs. It was noted that these vasa vasorum of the pulmonary artery received their injection mass from several sources; namely, directly through coronary branches from the conus (Fig. 4), from pericardial reflections around the pulmonary artery, from the injected mediastinal and bronchial arteries and from the arteries in the subpericardial fat pads at the base of the heart.

3. Many arteries were found leaving the heart around the pulmonary veins. They emerged as a rule at the site of the pericardial re-

flections around these veins. As shown by the injection mass they formed anastomoses with branches of the pericardial, bronchial and mediastinal arteries. Their importance was indicated by the fact that even when the parietal pericardium was cut away from the aorta, pulmonary artery and both venae cavae, an extensive mediastinal injection was obtained through these perivenous coronary anastomoses, while only a scant extracardiac injection was obtained after the pericardium was cut away from the great veins entering the heart.

4. Larger and more numerous injected vessels were found leaving the heart around the ostia of the superior and inferior venae cavae than were observed around the large arteries. Their course and number were not constant but they were usually closely applied to the adventitia of these veins. Some of the most direct and largest branches of the coronary arteries responsible for the passage of the injection mass to extracardiac structures were the auricular branches of the right coronary arteries. These usually consisted of two branches from the proximal portion of the right coronary artery which arborized in the vicinity of the ostia of the venae cavae, after supplying the right auricular wall. The larger and more constant of the two formed an annulus of fine branches around the ostium of the superior vena cava. The cardiac distribution of these auricular branches of the right coronary artery has been clearly described by Gross. In four hearts in this series in which a radiopaque injection mass was employed and roentgenograms of the hearts were made after injection, the course and origin of these vessels corresponded to Gross' description. Although these auricular branches were usually the largest direct vessels concerned in the extracardiac anastomoses, the arborization of many smaller auricular branches of the coronary arteries around the openings of the pulmonary veins and in the intervascular reflections of the parietal pericardium constituted a more important source for the extracardiac injection. The passage of the injection mass into the vasa vasorum of the aorta and pulmonary artery was principally by means of the rami telae adiposae, although an artery of larger calibre deep in the musculature of the conus and apparently representing a direct coronary branch occasionally supplied the walls of these vessels. Generally, the more complete extracardiac injections were obtained in specimens from persons of advanced years,

which is in accord with the observations of Gross and of Robertson. They found that the arterial branches to the pericardial fat increased with age.

5. No large branches of the coronary arteries were seen leaving the heart through the intervascular reflections of the parietal pericardium. Small vessels were injected, but it appeared that the significant extracardiac coronary branches emerged from the heart around the great vessels rather than between them.

The distribution of the vessels injected through the extracardiac coronary anastomoses was as follows:

There was an extensive network of injected vessels over the entire surface of the parietal pericardium. The largest arteries injected were the pericardiophrenic branches of the internal mammary arteries, which accompanied the phrenic nerves on either side. The small anterior branches of the thoracic aorta also contributed many branches to the lateral and posterior surfaces of the parietal pericardium and these were filled regularly with injection mass. The principal anastomoses of the pericardial vessels with branches of the coronary arteries appeared to be where the pulmonary veins and the venae cavae passed through the pericardium.

In the diaphragm, injected vessels spread out in a fan-shaped manner over each dome from the foramen quadratum. Their anastomoses with the coronary system were apparently through small vessels in the adventitia of the inferior vena cava and by means of the injected terminations of the pericardiophrenic arteries.

Injection mass entered vessels in the hila of the lungs through arteries originating from the auricular branches of both coronary arteries and the branches to the pericardial fat, and extending out along the pulmonary arteries and veins. The injected vessels were found over the pleural surfaces of the lungs and along the bronchi (Fig. 6) where they were seen in the mucosa, even after the second bifurcation.

The mediastinum, trachea and esophagus were richly supplied with vessels which were found to be filled with carbon particles after injection of the coronary arteries. These vessels were principally small anterior branches of the thoracic aorta which anastomosed freely with the bronchial, phrenic, intercostal and branches of the internal mammary arteries. Many vessels in the mediastinum and in sur-

rounding organs contributed branches which anastomosed with those from the coronary arteries. These were, in their usual order of prominence: the pericardiophrenic branches of the internal mammary arteries and the anterior mediastinal, pericardial, bronchial, superior and inferior phrenic, intercostal and esophageal branches of the aorta (Fig. 5).

In order to determine whether the heart could be injected directly through the thoracic branches of the aorta, a large glass cannula was inserted in the aorta above the coronary orifices. The aorta was tied between the cannula and the heart and also at the level of the diaphragm. The innominate, left common carotid and left subclavian arteries were tied. Injection of the aorta was then made. Microscopic examination of sections of the wall of the left auricle near the openings of the pulmonary veins showed injection mass in the coronary vessels (Fig. 3). The extent and capacity of these channels are now being studied in an attempt to determine the actual part they play in the circulation of the heart in normal and abnormal states.

SUMMARY

Widespread anastomoses of the auricular branches and the coronary branches to the pericardial fat with the pericardiophrenic branches of the internal mammary arteries and the anterior mediastinal, pericardial, bronchial, superior and inferior phrenic, intercostal and esophageal branches of the aorta have been described. The most extensive anastomoses between the cardiac and extracardiac vessels are around the ostia of the pulmonary veins. It was possible not only to demonstrate the passage of injection mass from the coronary arteries into the vessels of surrounding structures, but also to show vessels in the heart injected through the thoracic branches of the aorta.

This rich potential extracardiac coronary collateral circulation is probably of significance in compensating for sclerosis of the large trunks of the coronary arteries.

These experiments were carried out during the course of another study. The authors wish to express their thanks to Dr. E. S. Orgain for taking part in some of the experiments.

BIBLIOGRAPHY

1. Bromer, A. W., Zschiesche, L. J., and Wearn, J. T., Blood vessels of non-inflammatory origin in human heart valves, *J. Clin. Inv.*, 1929, **7**, 487.
2. Gross, L., The blood supply to the heart, New York, Hoeber, 1921.
3. Karsner, H. T., Coronary arteries, in Survey on arteriosclerosis, Josiah Macy, Jr., Foundation, New York, MacMillan, 1933, Chapter 15.
4. Langer, L., Die Foramina Thebesii im Herzen des Menschen, *Sitzungsber. k. Akad. Wissensch., Math.-naturwissensch. Cl., Wien*, 1880, **82**, 25.
5. Mönckeberg, J. G., Herz, in Henke, F., and Lubarsch, O., Handbuch der speziellen pathologischen Anatomie und Histologie, Berlin, Julius Springer, 1924, **2**.
6. Robertson, H. F., The vascularization of the epicardial and periaortic fat pads, *Am. J. Path.*, 1930, **6**, 209.
7. Spalteholz, W., Die Arterien der Herzwand, Leipsic, Hirzel, 1924.
8. Warburg, E. J., Ueber den Coronarkreislauf und ueber die Thrombose einer Coronararterie, *Acta med. Scand.*, 1930, **73**, 425.
9. Wearn, J. T., The extent of the capillary bed of the heart, *J. Exp. Med.*, 1928, **47**, 273.
10. Woodruff, C. E., Studies on the vasa vasorum, *Am. J. Path.*, 1926, **2**, 567.

EXPLANATION OF PLATES

PLATE 51

FIG. 1. Drawing of heart, lungs and diaphragm after injection of the coronary arteries with a colloidal suspension of carbon particles. A network of injected pericardial and mediastinal vessels is seen. There are large injected pleural and diaphragmatic vessels. About one-half natural size.

PLATE 52

FIG. 2. Drawing of the inner surface of the parietal pericardium and the inferior surface of the diaphragm. The coronary arteries were injected and the heart removed to expose the sites of anastomoses between coronary and extra-cardiac vessels. About one-half natural size.

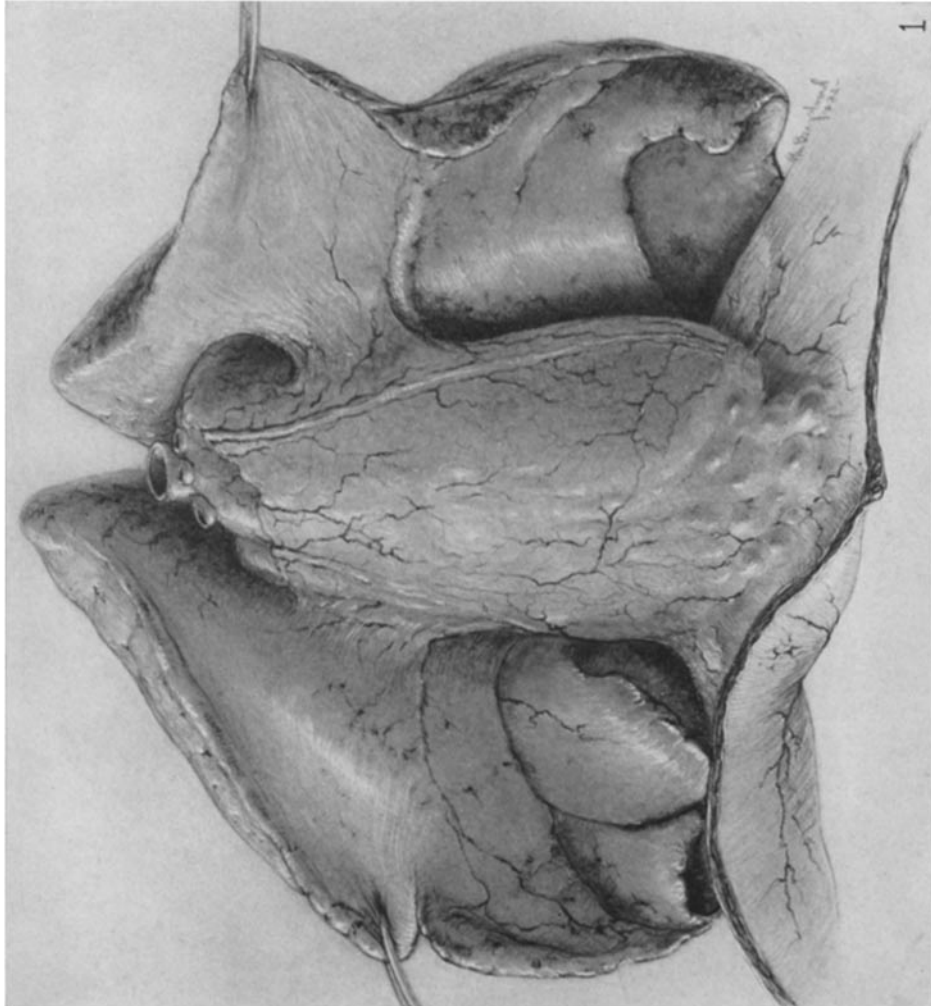
PLATE 53

FIG. 3. Wall of left auricle with vessels containing carbon particles. The injection was made into the thoracic branches of the aorta and the injection mass entered the heart through the anastomoses around the ostia of the pulmonary veins. $\times 14$.

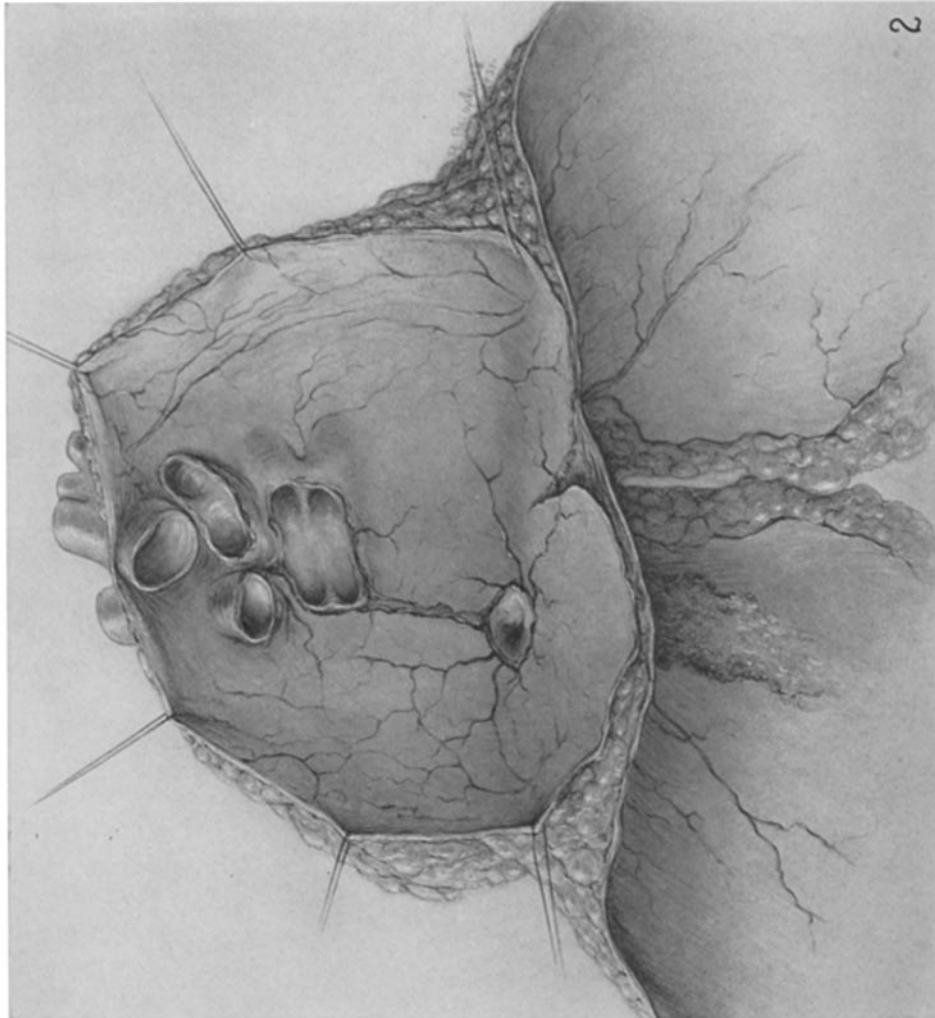
FIG. 4. Longitudinal section of the pulmonary artery and valve of a child. Many large adventitial vessels were injected from the coronary arteries. $\times 5$.

FIG. 5. Mucosa of esophagus containing vessels injected with carbon particles from the coronary arteries. $\times 70$.

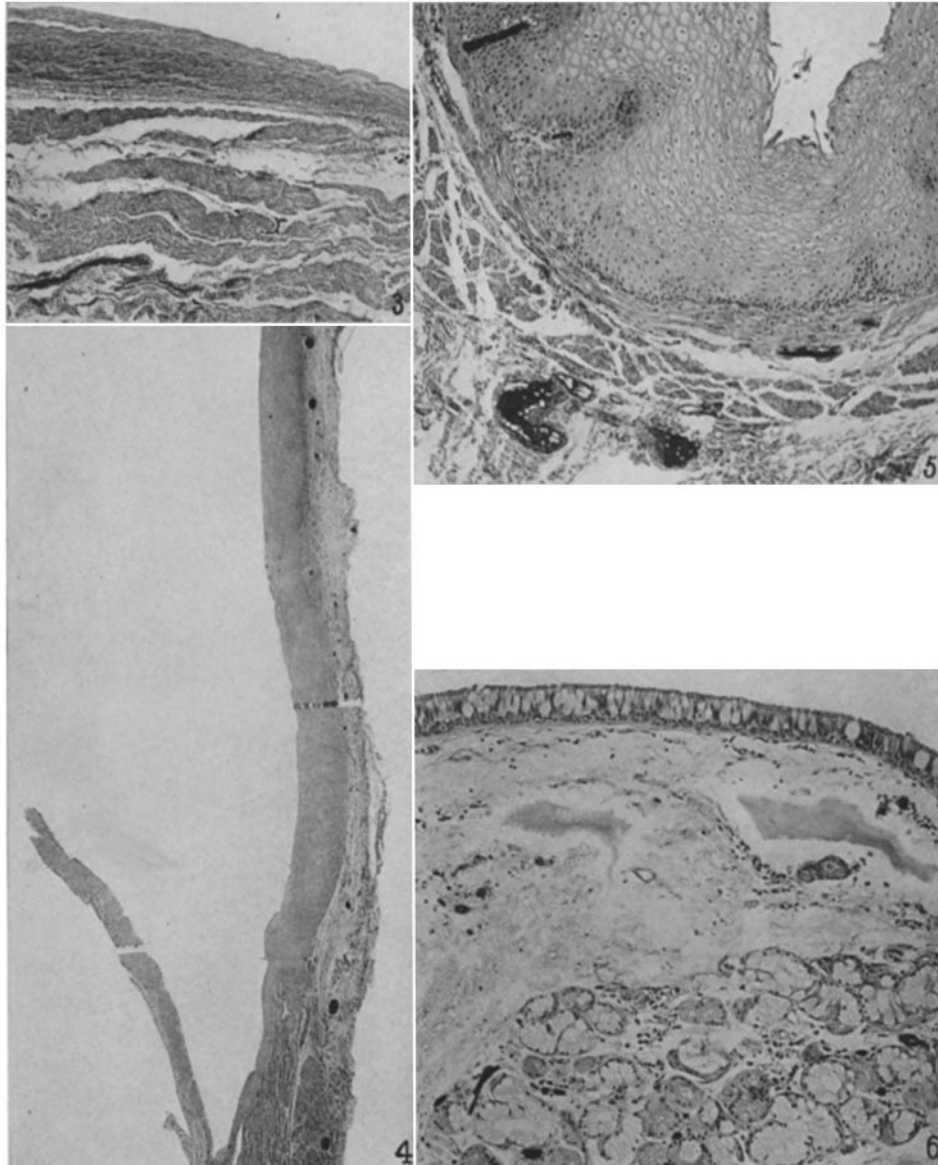
FIG. 6. Mucosa of trachea containing vessels injected with carbon particles from the coronary arteries. $\times 90$.



(Hudson *et al.*: Anastomoses of the coronary arteries)



(Hudson *et al.*: Anastomoses of the coronary arteries)



(Hudson *et al.*: Anastomoses of the coronary arteries)