



# Modified Pull-Through Technique for Hip Labral Reconstruction Using A Suture Suspension Bridge

Michael J. Huang, M.D., and Jennifer J. Wages, Ph.D., A.T.C

**Abstract:** Preservation of hip labral function is a primary goal in hip preservation surgery. Arthroscopic labral reconstruction in the hip is an alternative procedure for irreparable labrum in the nonarthritic hip population, with beneficial outcomes reported. Several challenges occur during labral reconstruction that make the procedure more difficult. The first is measuring the labral defect and matching the graft perfectly to the patient. The second is subsequent suture fixation and passage around the graft when it is loose within the joint. We propose a modification to the pull-through technique that both eliminates the inaccuracies in graft measurement and minimizes graft damage by eliminating the step of suture passage around the graft. This technique can be used for both segmental reconstruction or circumferential reconstruction of the hip labrum and can also accommodate knotless and knot-tied anchors. The advantages of this technique are increased procedure accuracy and efficiency.

Preserving labral integrity in the hip is a fundamental goal and guiding principle given the increasing understanding of the importance of the acetabular labral hydraulic seal.<sup>1-4</sup> Femoroacetabular impingement and an unsalvageable labrum have been reported as predisposing factors to the development of osteoarthritis.<sup>5</sup> An unsalvageable labrum has been defined by severe degenerative fraying, ossification, and flattening,<sup>5</sup> as well as labral tissue that cannot accommodate the passage of suture material.<sup>6</sup>

Labral reconstruction is a well-established treatment for irreparable labral tears in the hip,<sup>7-9</sup> with comparable postoperative clinical outcomes up to 6 years after surgery,<sup>5,7,10</sup> and is superior to debridement alone.<sup>11</sup> The technical difficulty of labral reconstruction limits its efficacy, increases traction time, and potentiates the risk of iatrogenic damage within the hip. Accurate measurement and placement of the labral

reconstruction graft is one of the most difficult aspects of the surgery. Without precise graft length match, there may be gaps in the reconstruction or excess graft in the joint, which may lead to poor outcomes. Once the graft is inserted into the joint, suture passage around the graft is difficult, as visualization can be diminished because the graft is still loose in the joint. Subsequent passage of multiple sutures around the graft can result in graft compromise.

Multiple techniques to address these difficult components of the surgery have been previously reported including the “kite” technique<sup>12</sup> and the “pull-through” technique.<sup>13</sup> This Technical Note presents a modification to the pull-through technique for labral reconstruction, which continues to eliminate the need for graft measurement but also simplifies and improves the efficiency of suture passage, as the graft is passed over a suture “suspension bridge,” obviating the need for individual and sequential suture passage. With this technique, there is minimal manipulation of the graft once it is passed, leading to a more reproducible and efficient procedure.

## Surgical Technique

The technique is shown in the [Video 1](#).

## Patient Preparation and Portal Placement

1. The patient is placed in a modified supine position, and general anesthesia is induced. The technique can be accomplished with a post or postless traction table. Joint distraction is confirmed with fluoroscopy.

From the Colorado Springs Orthopaedic Group, Colorado Springs, Colorado, U.S.A

The authors report that they have no conflicts of interest in the authorship and publication of this article. Full ICMJE author disclosure forms are available for this article online, as [supplementary material](#).

Received May 13, 2020; accepted August 29, 2020.

Address correspondence to Jennifer J. Wages, Ph.D., 4110 Briargate Parkway, Suite #300, Colorado Springs, CO 80920, U.S.A. E-mail: [jwages@csog.net](mailto:jwages@csog.net)

© 2020 by the Arthroscopy Association of North America. Published by Elsevier. This is an open access article under the CC BY-NC-ND license (<http://creativecommons.org/licenses/by-nc-nd/4.0/>).

2212-6287/20918

<https://doi.org/10.1016/j.eats.2020.08.027>

- The hip joint is accessed throughout the procedure using anterolateral, midanterior, and posterolateral portals and a modified distal lateral accessory portal.

### Diagnostic Arthroscopy, Labral Assessment, and Femoroacetabular Impingement Correction

- Diagnostic arthroscopy is performed to assess the labrum, chondral damage, and ligamentum teres.
- If diagnostic arthroscopy demonstrates an irreparable labrum (ossified, hypoplastic, truncated, etc.), the remaining labrum is debrided and the acetabular rim is decorticated.
- If acetabular overcoverage (pincer impingement) is identified, an acetabuloplasty is performed using a 4.5-mm curved mechanical bur (HPS-HB01; ConMed Linvatec, Largo, FL).
- Traction is released, and the hip is flexed to 45° to allow evaluation of the femoral head-neck junction. If decreased offset is identified (cam impingement), an osteoplasty is performed using the same curved mechanical bur.
- Dynamic assessment and fluoroscopic evaluation in multiple planes are used to confirm adequate bony correction.

### Labral Reconstruction

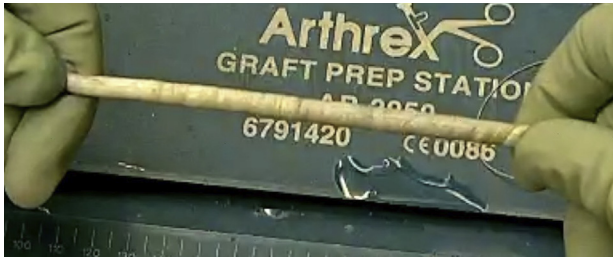- We use a tensor fasciae latae allograft (MTF Biologics, Edison, NJ) that is tubularized and secured using 2-0 vicryl suture. Careful attention is paid to burying all suture within the graft to minimize any external suture. A #2 FiberWire suture (AR-7242; Arthrex, Naples, FL) is placed on the anticipated lateral end of the graft. Graft or defect measurement is not necessary, as this technique involves use of as much graft as necessary for anatomic placement on the acetabular rim, with removal of any excess graft after securing the final anchor. While many various autograft and allograft tissues have been described as alternatives, we believe that this tissue graft produces the most uniform graft that does not swell or fray during preparation or insertion (Fig 1).
- A double-loaded knotted anchor (AR-1934BCF-2, 2.4, SutureTak; Arthrex) is first placed on the most medial aspect of the segmental defect. This is repeated with another double-knotted anchor at the most lateral aspect of the defect. Between these "bookend" anchors, we place knotless anchors every 6 to 8 mm (AR-1938D, 3.0, Knotless SutureTak or AR-3638, Knotless FiberTak anchors; Arthrex) (Fig 2).
- The articular-side suture limbs of all anchors are pushed deeper into the joint to create a suture suspension bridge (Fig 3).

- A suture shuttle, #2 FiberWire (Arthrex), is placed from the midanterior portal across the suture suspension bridge and exits through the posterolateral portal (Fig 4). This serves as a suture shuttle to advance the graft over the suture suspension bridge.
- The medial aspect of the graft is secured to one of the free limbs of the medial-most anchor.
- The #2 FiberWire suture previously placed at the lateral end of the graft is placed through the suture shuttle.
- The lateral end of the graft is introduced to the joint as the suture shuttle is advanced from the midanterior portal across the joint and out the posterolateral portal. During this process, the graft is advanced over the previously made suture suspension bridge (Fig 5).
- The medial aspect of the graft is advanced to the medial anchor by using the sutures as a pulley mechanism (Fig 6).
- The medial sutures are secured using a sliding-locking arthroscopic knot.
- The remaining central knotless anchor sutures are now secured using the internal mechanism of the anchor. There is no need for any further suture passage around the graft, as all appropriate suture limbs were been placed on the articular side of the graft when the suture suspension bridge was made and the graft passed on top of the suture limbs. This allows for minimal manipulation of the graft (Fig 7).
- The lateral-most anchor is a standard knot-tying anchor and is again secured using a sliding-locking arthroscopic knot.
- The graft is cut 1 cm distal to the final anchor using a radiofrequency wand, and the remaining graft material is removed out the posterolateral portal.
- Traction is released to allow evaluation of the suction seal (Fig 8).

The pearls and pitfalls for this technique are summarized in the Table 1.

### Discussion

The purpose of this technique is to restore the anatomy and function of an irreparable labrum with a method that eliminates multiple challenges throughout the technique. This technique avoids 2 critical challenges during the procedure. First, this method eliminates measurement of the graft and thereby removes the possibility of having a graft that is too short, which would compromise the function of the graft. Graft measurement has been dependent on estimates of labral defect segments with an arthroscopic measurement probe<sup>6</sup> or through measurement of a suture superimposed over the defect.<sup>11</sup> Second, this method avoids suture passage around the graft, which minimizes

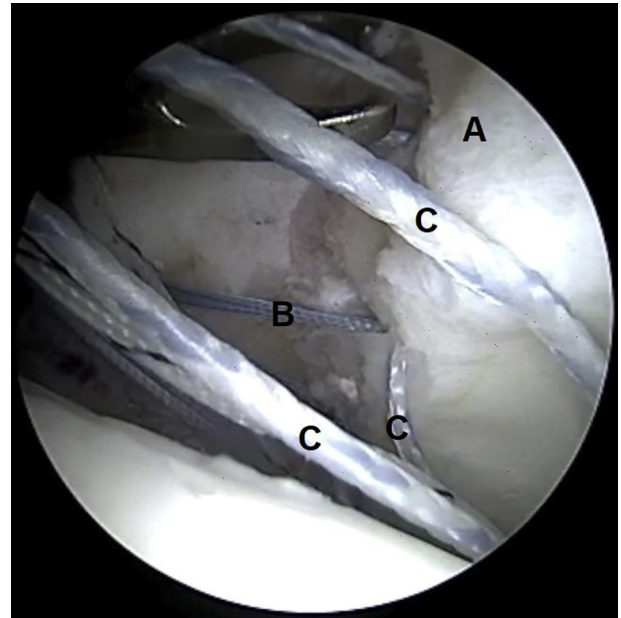


**Fig 1.** Completed tensor fasciae latae allograft tubularized with 2-0 vicryl suture and a #2 FiberWire suture at the anticipated lateral end of the graft.

iatrogenic injury to the graft within the joint. By avoiding multiple steps of suture passing, the procedure is more efficiently performed and can decrease overall procedure time and traction time (if traction is used).

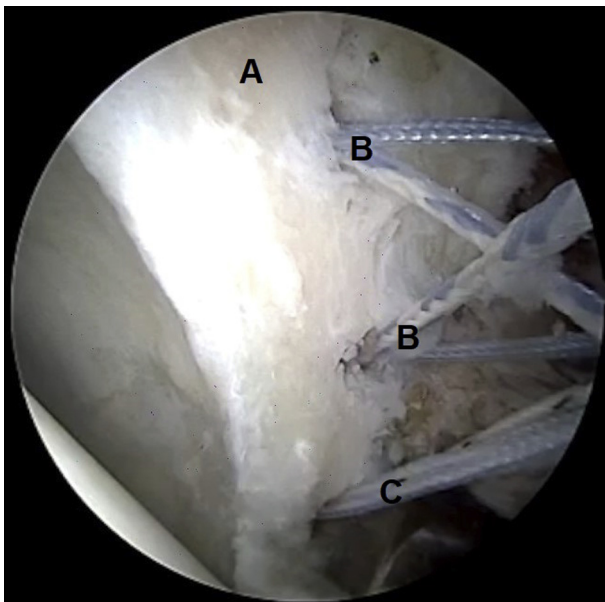
Over the past several years, multiple publications have demonstrated good clinical outcomes with arthroscopic hip labral reconstruction. Philippon et al.<sup>9</sup> followed 47 patients over 1 year with improved mean modified Harris hip score (mHHS) from 62 to 85 ( $P = .001$ ). Additionally, Geyer et al.<sup>7</sup> confirmed significant improvement in mHHS, 59 to 83, and also showed 76% survivor rate after arthroscopic labral reconstruction with follow-up of 3 to 6 years.

Recent publications have reported significant improvements in postoperative clinical outcomes after labral reconstruction, with retained outcomes  $\leq 5$  years after surgery. White et al.<sup>14</sup> reviewed 142 patients who underwent arthroscopic labral reconstruction using an iliotibial band allograft with front-to-back fixation, with

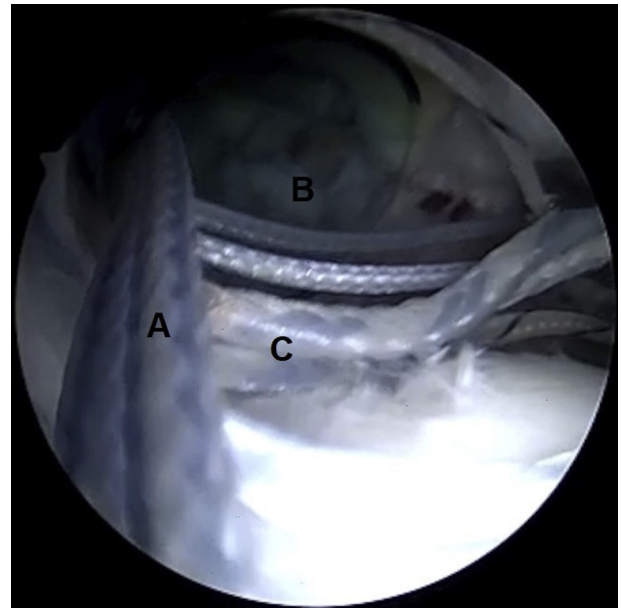


**Fig 3.** Viewing from anterolateral portal in a left hip with the patient in a modified supine position. (A) Prepared acetabulum rim. (B) Shuttling suture for knotless anchor docked out midanterior portal. (C) Main suture limbs from each knotless anchor placed into joint to create suture bridge.

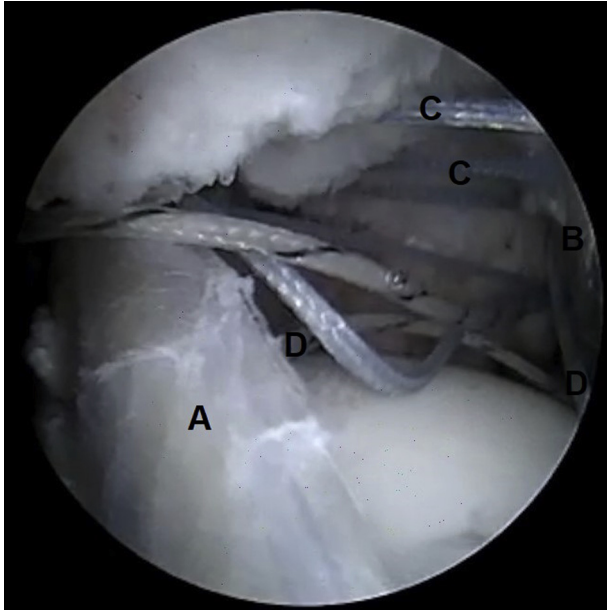
minimum 2-year follow-up, and found significant improvements in all outcome measures including mHHS, lower extremity function score, and visual analog scale (VAS). Mean satisfaction was 9.<sup>14</sup> Chandrasekaran et al.<sup>6</sup> investigated patient-reported outcomes (PROs) in



**Fig 2.** Viewing from midanterior portal in a left hip with the patient in a modified supine position. (A) Prepared acetabulum rim. (B) Knotless suture anchor along acetabular rim. (C) Standard knotted anchor at bookend.

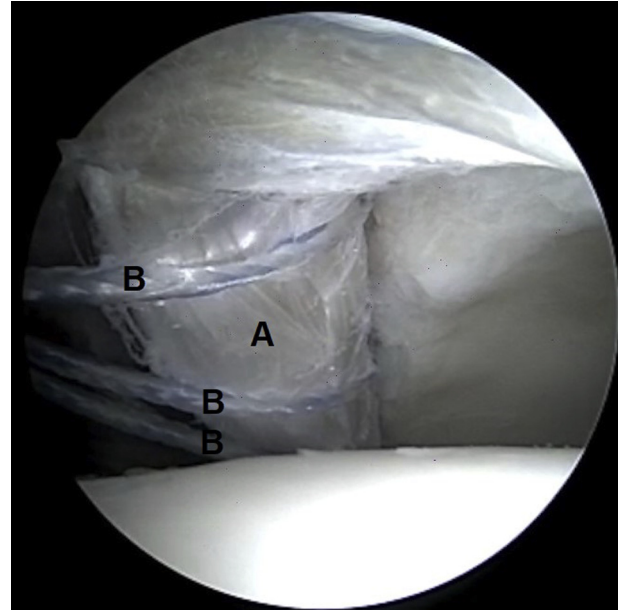


**Fig 4.** Viewing from anterolateral portal in a left hip with the patient in a modified supine position. (A) Shuttling suture attached to posterior/lateral end of graft. (B) 8.25-mm cannula in midanterior portal. (C) Main suture limbs from each knotless anchor placed into joint to create suture bridge.



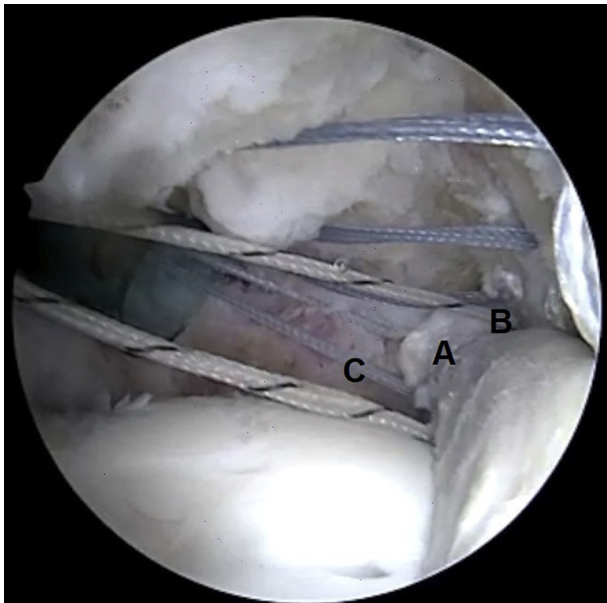
**Fig 5.** Viewing from anterolateral portal in a left hip with the patient in a modified supine position. (A) Graft passing from midanterior portal to posterolateral portal over suture bridge. (B) Acetabular rim. (C) Shuttling suture for knotless anchor docked at midanterior portal. (D) Main suture limbs from each knotless anchor under graft and already positioned correctly.

22 patients who underwent segmental labral reconstruction and found significant improvements in 2-year postoperative clinical outcomes compared with preoperative scores, including mHHS ( $P = .013$ ), hip outcome

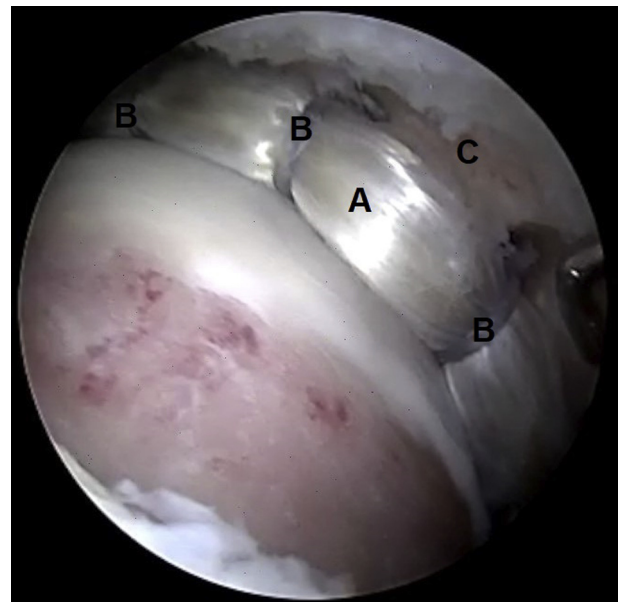


**Fig 7.** Viewing from anterolateral portal in a left hip with the patient in a modified supine position. (A) Labral reconstruction graft. (B) Main suture limbs from each knotless anchor. Slack in suture has been removed, which provisionally places graft along acetabular rim. Each of these limbs of suture is correctly positioned without need to pass them around the graft.

score—activities of daily living subscale (HOS-ADL) ( $P = .020$ ), hip outcome score—sports-specific subscale (HOS-SSS) ( $P = .002$ ), nonarthritic hip score (NAHS) ( $P = .001$ ), and pain VAS ( $P < .001$ ).<sup>6</sup>



**Fig 6.** Viewing from anterolateral portal in a left hip with the patient in a modified supine position. (A) Medial end of labral reconstruction graft. (B) Medial bookend anchor in acetabulum. (C) Sutures from most medial anchor already placed correctly around graft and ready for fixation.



**Fig 8.** Viewing from midanterior portal in a left hip with the patient in a modified supine position. (A) Labral reconstruction graft. (B) Main suture limbs from each knotless anchor, tensioned. (C) Acetabular rim.

**Table 1.** Pearls and pitfalls

Pearls
<ul style="list-style-type: none"> <li>• Use tensor fasciae lata graft to achieve a uniform 5.0- to 6.0-mm diameter cylindrical graft without need for measurement of length.</li> <li>• Place Vicryl sutures throughout the length of the graft and bury them to increase initial strength of graft without any external sutures, to avoid chondral irritation.</li> <li>• Place FiberWire suture at posterior end of graft to be used when pulling graft from midanterior portal through joint and out the posterolateral portal.</li> <li>• Place typical knotted anchors at each bookend of the labral defect.</li> <li>• In between knotted bookend anchors, place knotless anchors along acetabulum every 5 to 8 mm.</li> <li>• Manipulate appropriate sutures from all anchors into the central aspect of the joint to create the suture bridge for the graft to pass over.</li> <li>• Place a suture from the most medial anchor through the medial aspect of graft to be used as a pulley.</li> </ul>
Pitfalls
<ul style="list-style-type: none"> <li>• Improper placement of anchors</li> <li>• Improper suture management</li> </ul>

Nakashima et al.<sup>5</sup> also reported significant improvements ( $P < .001$ ) in 2-year postoperative clinical outcomes in patients who, underwent labral reconstruction ( $n = 25$ ) with no significant differences in PROs compared with patients with labral refixation ( $n = 126$ ). Higher mean age ( $\geq 45$  years), body mass index ( $\geq 23.1$  kg/m<sup>2</sup>), and vertical center edge angle ( $\geq 36^\circ$ ) were found to be significant predictors for labral reconstruction.<sup>5</sup>

Domb et al.<sup>10</sup> compared 5-year postoperative clinical outcomes between patients undergoing primary labral reconstruction ( $n = 17$ ) for irreparable labral tears with patients in a matched-pair control group ( $n = 51$ ) who underwent primary labral repair. They found significant improvements in all postoperative PROs at 5 years after surgery compared with preoperative PROs, including mHHS ( $P = .0017$ ), NAHS ( $P = .0003$ ), HOS-SSS ( $P = .003$ ), and pain VAS ( $P = .0005$ ). There were no significant differences in postoperative PROs between groups at a minimum of 5 years after surgery.<sup>10</sup>

We are aware of 2 main types of labral reconstruction techniques, segmental<sup>5,10</sup> and front-to-back (circumferential).<sup>13,14</sup> To date, there is no consensus on which technique is superior, but both techniques have identical challenges in terms of graft measurement and fixation. The specific surgical technique for labral reconstruction has been presented in previous investigations involving the use of various suture anchors and graft choices. However, to our knowledge, only one other technique centered around passage of the graft has been reported.<sup>13</sup>

Similar to previously reported techniques for labral reconstruction, our technique can be performed using the anterolateral and midanterior portals. In addition to these standard portals, we recommend the addition of a

posterolateral and a modified distal lateral accessory portal. Advancing the graft from the midanterior portal across the suture suspension bridge and out the posterolateral portal provides smooth passage with accurate positioning of the graft. Our technique involves the addition of a suture suspension bridge, which eliminates any further suture passage around the graft and minimizes manipulation of the graft.

The advantages of our technique include eliminating the measuring step for the graft and eliminating the suture passing around the graft once it is passed within the joint. From our experience, these advantages significantly reduce surgical time (including traction time) and iatrogenic injury to the joint chondral surfaces and graft once it is passed. If the surgeon uses knotless anchors, as is our preference, then there is also the added advantage of controlled suture tensioning and retensioning under direct visualization. The disadvantages of the technique include minor risk of infection due to allograft usage.

Labral reconstruction in the hip is still relatively new, but short-term clinical results show significant benefit to patients, and technique improvements to this highly complex procedure are paramount for patient benefit.

## References

1. Bedi A, Kelly B, Khanduja V. Arthroscopic hip preservation surgery: Current concepts and perspective. *Bone Joint J* 2013;95-B:10-19.
2. Philippon M, Nepple J, Campbell K, Dornan G, Jansson K, LaPrade R, Wijdicks C. The hip fluid seal—Part I: The effect of an acetabular labral tear, repair, resection and reconstruction on hip fluid pressurization. *Knee Surg Sports Traumatol Arthrosc* 2014;22:722-729.
3. Nepple J, Philippon M, Campbell K, Dornan G, Jansson K, LaPrade R, Wijdicks C. The hip fluid seal—Part II: The effect of an acetabular labral tear, repair, resection and reconstruction on hip stability to distraction. *Knee Surg Sports Traumatol Arthrosc* 2014;22:730-736.
4. Ferguson S, Bryant J, Ganz R, Ito K. An in vitro investigation of the acetabular labral seal in hip joint mechanics. *J Biomech* 2003;36:171-178.
5. Nakashima H, Tsukamoto M, Ohnishi Y, Utsunomiya H, Kanezaki S, Sakai A, Uchida S. Clinical and radiographic predictors for unsalvageable labral tear at the time of initial hip arthroscopic management for femoroacetabular impingement. *Am J Sports Med* 2019;47:2029-2037.
6. Chandrasekaran S, Darwish N, Close M, Lodhia P, Suarez-Ahedo C, Domb B. Arthroscopic reconstruction of segmental defects of the hip labrum: Results in 22 patients with mean 2-year follow-up. *Arthroscopy* 2017;33:1685-1693.
7. Geyer M, Philippon M, Fagrellius T, Briggs K. Acetabular labral reconstruction with an iliotibial band autograft: Outcome and survivorship analysis at minimum 3-year follow-up. *Am J Sports Med* 2013;41:1750-1756.
8. Matsuda D, Burchette R. Arthroscopic hip labral reconstruction with a gracilis autograft versus labral refixation: 2-year minimum outcomes. *Am J Sports Med* 2013;41:980-987.

9. Philippon M, Briggs K, Hay C, Kuppersmith D, Dewing C, Huang M. Arthroscopic labral reconstruction in the hip using iliotibial band autograft: Technique and early outcomes. *Arthroscopy* 2010;26:750-756.
10. Domb B, Battaglia M, Perets I, Lall A, Chen A, Ortiz-Declet V, Maldonado D. Minimum 5-year outcomes of arthroscopic hip labral reconstruction with nested matched-pair benchmarking against a labral repair control group. *Am J Sports Med* 2019;47:2045-2055.
11. Domb B, El Bitar Y, Stake C, Trenga A, Jackson T, Lindner D. Arthroscopic labral reconstruction is superior to segmental resection for irreparable labral tears in the hip: A matched-pair controlled study with minimum 2-year follow-up. *Am J Sports Med* 2014;42:122-130.
12. Bhatia S, Chahla J, Dean C, Ellman M. Hip labral reconstruction: The "kite technique" for improved efficiency and graft control. *Arthrosc Tech* 2016;5:e337-e342.
13. Perets I, Hartigan D, Chaharbahshi E, Walsh J, Close M, Domb B. Circumferential labral reconstruction using the knotless pull-through technique—Surgical technique. *Arthrosc Tech* 2017;6:e695-e698.
14. White B, Stapleford A, Hawkes T, Finger M, Herzog M. Allograft use in arthroscopic labral reconstruction of the hip with front-to-back fixation technique: Minimum 2-year follow-up. *Arthroscopy* 2016;32:26-32.