

Received: 2019.07.17 Accepted: 2019.09.04 Published: 2019.11.17

Severe Cobalamin Deficiency Disguised as Schistocytes: A Case Report

Authors' Contribution: Study Design A Data Collection B Statistical Analysis C Data Interpretation D Manuscript Preparation E Literature Search F Funds Collection G

ABDEF 1 Salwa A. Koubaissi ABDEF 2 Jad A. Degheili

1 Department of Internal Medicine, American University of Beirut Medical Center, Beirut, Lebanon 2 Department of Surgery, Division of Urology, American University of Beirut Medical Center, Beirut, Lebanon

Corresponding Author: Jad A. Degheili, e-mail: jdegheili@gmail.com Conflict of interest: None declared

Patient: Male, 53 Final Diagnosis: Non immune intravascular hemolytic anemia Symptoms: Dyspnea • fatigue Medication: — Clinical Procedure: — Specialty: Hematology

Objective: Challenging differential diagnosis Background: Vitamin B12, also known as cobalamin (Cbl), is a major player in both erythropoiesis and myelination of the central nervous system. The 2 main manifestations of vitamin B12 deficiency are bone marrow failure and demyelinating disease. These manifestations also depend on the severity and duration of the deficiency. In severe cases, ineffective erythropoiesis, with intramedullary destruction of erythrocytes has been reported, and increased homocysteine level was shown to be a cause of this hemolysis, in vitro. Case Report: We present the case of a middle-aged man presented with worsening fatigue, pallor, and dyspnea on moderate exertion. He was found to have a macrocytic anemia associated with intravascular hemolysis and clinical hypothyroidism in the setting of Hashimoto's thyroiditis. Vitamin B12 measured as part of his anemia investigation, was found to be markedly deficient (less than 100 pg/mL). Replacement was started and a reversal of his anemia and hemolysis was shown with improvement in his hemoglobin level upon follow-up. Conclusions: Although a rare presentation, severe vitamin B12 deficiency can lead to hemolysis and severe anemia that can be life threatening. Timely and appropriate diagnosis and replacement, lifelong in some cases, in addition to looking for the underlying cause of this deficiency, and excluding other concomitant hemolytic disorders, is crucial for the management of this reversible disease. Despite some in vitro early results, the exact underlying mechanism behind hemolysis is still unclear.

MeSH Keywords: Anemia, Hemolytic • Anemia, Pernicious • Homocysteine • Vitamin B 12 Deficiency

Full-text PDF: https://www.amjcaserep.com/abstract/index/idArt/918807

1657 — 1 12



Background

Vitamin B12 deficiency, also known as cobalamin (Cbl) deficiency can be caused by either low absorption secondary to gastric or small intestine surgeries or disorders (e.g., pernicious anemia, celiac disease, Crohn's disease) or by low intake for a prolonged period of time, as manifested in individuals on a vegan or strict vegetarian diet without adequate supplementation [1,2]. Hematological manifestations related to this deficiency occur in more than two-thirds of patients, with different frequencies. These include: macrocytosis (54%), anemia (37%), hyper-segmented neutrophils (32%), leukopenia (13.9%), and thrombocytopenia (9.9%). Life-threatening hematological manifestations occur in around 10% of affected patients, and these range from symptomatic pancytopenia (5%) to hemolytic anemia in rare cases (1.5%) [3].

Case Report

A 53-year-old white male, non-smoker or alcohol consumer, presented with a 2 days history of worsening fatigue that started 1 month prior to presentation, associated with 3 kg of nonintentional weight loss over the same period. He also complained of dizziness, pallor, occasional small joints arthralgia, and dyspnea on minimal exertion, relieved by rest noticed over the past 3 days. In addition, he reported having an upper respiratory tract infection 1 month prior, that lasted 4 to 5 days, and completely resolved afterwards. Upon further questioning, he admitted having a similar presentation in another hospital 1 year ago and was diagnosed with anemia with high mean corpuscle volume (MCV), but the laboratory results back then were not available. As a result, he received a blood transfusion, then was lost to follow-up.

On presentation to our clinic, he denied any melena or change in stools color or habit, abdominal pain or vomiting, cough, hemoptysis, easy bruising, hematuria or change in urine color, skin rash, jaundice, cold or heat intolerance, numbness or motor weakness, recent fever, chills or night sweats. There was no other significant medical, or social history, and no history of recent travel or remote stay in a foreign country. Also, his past surgical history was negative, and his family history was only remarkable for early coronary artery disease in his father who underwent percutaneous transluminal coronary angioplasty at the age of 40 years old.

On examination, the patient was alert and oriented but pale with mildly icteric sclera and his neurological examination was remarkable for generalized delayed deep tendon reflexes only, with normal sensory and motor examinations. There was no thyroid nodules, cervical lymphadenopathy, or jugular venous distention. His cardiac, lung, and abdominal examinations were all

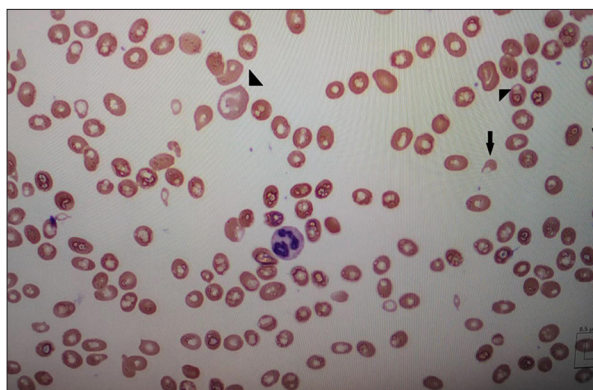


Figure 1. Peripheral smear showing schistocytes (arrows) and macrocytes (arrow heads).

within normal limits. No hepatosplenomegaly, lower extremity edema or rashes were noted, and a digital rectal examination performed did not reveal any melena. His vital signs were stable with a blood pressure of 121/74 mm Hg, pulse of 70 beats per minute, temperature of 36.7°C (oral), respiratory rate of 16 breaths per minute and oxygen saturation of 100% on room air.

Investigations on admission revealed the following: peripheral white blood cell (WBC) count 4800/mm³ with normal differential and an absolute neutrophil count of 283/mm³, hemoglobin 7.2 g/dL, hematocrit 20%, MCV 122 fl, red blood cell distribution width 13.9%, platelets 182000/mm³, reticulocyte count 6.5% with a low reticulocyte index of 1.44%. Hepatic panel showed the following: aspartate transaminase 186 IU/L, alanine transaminase 101 IU/L, total bilirubin 2.7 mg/dL, direct bilirubin 0.5 mg/dL, total protein 68 g/L, albumin 47 g/L, international normalized ratio (INR) 1.1, and an activated partial thromboplastin time (aPTT) of 24.6. Both his basic metabolic panel and coagulation profile were normal with fibrinogen of 3 g/L (1.70–4.00 g/L).

Review of his peripheral smear showed few reactive lymphocytes, moderate macrocytosis with few fragmented red blood cells (RBC), few tear-drop RBCs, few ovalocytes, and few polychromatic RBCs. Occasional large platelets were seen (Figure 1). Urine analysis showed 1 plus hemoglobin with rare RBCs. Despite the presence of fragmented RBCs or schistocytes, the suspicion of both hemolytic uremic syndrome (HUS) and thrombotic thrombocytopenic purpura (TTP) was clinically low in the setting of normal kidney function, neurologic status and platelets count.

Based on these initial results, additional workup was suggested and included a more extensive evaluation of his intravascular hemolytic anemia: lactate dehydrogenase (LDH) was markedly elevated 4896 IU/L (normal range 110–265 IU/L), haptoglobin <0.1 g/L (normal range 0.30–2.00 g/L), extensive direct coombs test including IgG, IgM, IgA, C3c, and C3d which

were negative for all tested elements, serum folate 7.3 ng/mL, with very low serum vitamin B12 <100 pg/mL (normal range 243–894 pg/mL). Normal iron studies were reflected by the following: iron level 139 ug/dL (normal range 37–160 ug/dL), iron binding capacity 328 ug/dL (normal range 270–450 ug/dL), and transferrin saturation of 42.4%.

In view of the clinical picture and despite a negative evaluation for autoimmune hemolytic anemia with an extensive direct coombs test that theoretically ruled both warm and cold types of the latter, the presence of reactive lymphocyte along with the recent history of upper respiratory tract infection pushed for further evaluation of infectious causes of this hemolytic anemia. Brucella titers, cytomegalovirus (CMV) IgM antibodies, Epstein-Barr virus (EBV) IgM antibodies, both hepatitis B and C serology and human immunodeficiency virus (HIV) 1 and 2 antibodies/p24 antigen were all negative. Thyroid function test evaluation revealed a very high thyrotropin stimulating hormone (TSH) of 41.3 μ U/mL (0.27–4.204 μ U/mL), a low free thyroxine (fT4) of 0.76 ng/dL (0.93–1.70 ng/dL), and markedly elevated anti-peroxidase antibodies of 575 IU/mL (\leq 10.0 IU/mL) suggestive of clinical hypothyroidism in the setting of Hashimoto's thyroiditis.

Finally, due to the presence of elevated liver enzymes, severe vitamin B12 deficiency and autoimmune thyroid dysfunction, both evaluation for autoimmune hepatitis and celiac disease was done with negative results for antinuclear antibody (ANA) titers and tissue transglutaminase IgA.

A dedicated computerized tomography (CT) scan of his chest, abdomen and pelvis done with intravenous contrast was also negative for any mass suggestive of malignancy or enlarged lymph nodes. The liver architecture was also unremarkable for any structural or ductal abnormalities.

Subsequent parietal cell antibodies titer was found to be >1: 10 (normal <1: 10), along with intrinsic factor antibodies exceeding 200 (normal <20 unit/mL), supporting the diagnosis of pernicious anemia.

The patient was transfused with 2 units of packed red blood cells and 1000 mcg intramuscular vitamin B12 daily was initiated for 2 weeks and his hemoglobin responded adequately upon clinic follow up. The dose was then decreased to once weekly for 4 weeks then monthly for life. Folate replacement was also started along with oral levothyroxine 100 mcg daily with repeat TSH in 6 weeks. He was also advised for age appropriate colorectal cancer screening with colonoscopy and repeat liver function tests in 3 months.

Upon follow-up visits, his hemoglobin level improved indicating a good response to vitamin B12 replacement.

Discussion

In a review of multiple case reports, vitamin B12 deficiency rarely causes hemolytic anemia in approximately 1.5% of cases [4–7], with cases of either immune and/or non-immune mediated hemolysis previously reported and affecting the same organ system concomitantly [8].

Despite hemolysis, the reticulocyte count in vitamin B12 deficiency is low (or normal), reflecting reduced blood cell production, as seen in our case. In addition, megaloblastic changes are caused by disproportionately slow nuclear division cycle relative to the cytoplasmic maturation cycle, or nuclear-cytoplasmic dyssynchrony. Nevertheless, the absence of megaloblasts on the peripheral smear in our case does not exclude their presence in the bone marrow, where nucleated precursor cells are higher in number.

Hematopoietic precursor cells are among the body cells with the highest mitotic activity and are very sensitive to abnormal DNA synthesis caused by vitamin B12, which can explain why our patient developed anemia in the absence of neurological symptoms. However, it is still unclear why some patients with the same deficiency can have predominantly neuropsychiatric rather than hematologic abnormalities, and vice versa, or the presence of either/or abnormality alone in the absence of the other, as in our case. Multiple investigations done previously have attributed this finding to the marked increase in methylmalonic acid (MMA) or homocysteine, both due to the blockade of cobalamin-dependent enzymes L-methylmalonyl-coenzyme A mutase and methionine synthetase, respectively [9,10].

The patient in this case presented with laboratory findings consistent with non-immune intravascular hemolytic anemia, along with Hashimoto's thyroiditis and very low vitamin B12 level. Historically, the association between pernicious anemia and thyroid antibodies, mainly Hashimoto's thyroiditis, was well demonstrated in multiple studies, with over 50% of patients with pernicious anemia found to have detectable thyroid antibodies. On the other hand, patients with primary Hashimoto's thyroiditis had 12% incidence of pernicious anemia and nearly 20% showed partial impairment in vitamin B12 absorption [11].

In the setting of negative investigations for other causes of intravascular hemolysis and presence of schistocytes, including auto-immune hemolytic anemia, the low clinical and laboratory suspicion of both TTP and HUS, the negative surgical and dietary history consistent with very low Cbl absorption or intake, normal folate level, no intake of drugs that cause hemolysis, absence of malignancy on imaging, and in view of the associated diagnosis of Hashimoto's thyroiditis along with the elevated intrinsic factor and parietal cell antibodies titer,

the diagnosis of pernicious anemia in our patient can thus be established without further investigations. In addition, the adequate response to vitamin B12 replacement therapy further proves our suspicion.

Finally, multiple possible mechanisms of hemolysis due to vitamin B12 deficiency were described. The effect of high homocysteine level that normally occurs is a possible etiology in previous studies [7]. In our case, both homocysteine and MMA were not measured in view of the very low Cbl level that allowed confirmation of the diagnosis. Another cause is the intramedullary hemolysis of fragile red blood cells [4,12]. Further studies are still needed for confirmation of its exact underlying etiology.

References:

1. Stabler SP: Clinical practice. Vitamin B12 deficiency. *N Engl J Med*, 2013; 368(2): 149–60
2. Green R: Vitamin B12 deficiency from the perspective of a practicing hematologist. *Blood*, 2017; 129(19): 2603–11
3. Andrés E, Affenberger S, Zimmer J et al: Current hematological findings in cobalamin deficiency. A study of 201 consecutive patients with documented cobalamin deficiency. *Clin Lab Haematol*, 2006; 28(1): 50–56
4. Cheema A, Bramson J, Bajwa R et al: Hemolytic anemia an unusual presentation of vitamin B12 deficiency. *J Hematol Thrombo Dis*, 2018; 6: 285
5. Waheed MA, Elzouki A: Vitamin B12 deficiency presenting as hemolytic anemia. *Libyan J Med Sci*, 2018; 2: 114–15
6. Prueksaritanond S, Barbaryan A, Mirrakhimov AE et al: A puzzle of hemolytic anemia, iron and vitamin B12 deficiencies in a 52-year-old male. *Case Rep Hematol*, 2013; 2013: 708489
7. Acharya U, Gau JT, Horvath W et al: Hemolysis and hyperhomocysteinemia caused by cobalamin deficiency: Three case reports and review of the literature. *J Hematol Oncol*, 2008; 1: 26
8. Rabinowitz AP, Sacks Y, Carmel R: Autoimmune cytopenias in pernicious anemia: A report of four cases and review of the literature. *Eur J Haematol*, 1990; 44(1): 18–23
9. Lindenbaum J, Healton EB, Savage DG et al: Neuropsychiatric disorders caused by cobalamin deficiency in the absence of anemia or macrocytosis. *N Engl J Med*, 1988; 318(26): 1720–28
10. Tangney CC, Tang Y, Evans DA, Morris MC: Biochemical indicators of vitamin B12 and folate insufficiency and cognitive decline. *Neurology*, 2009; 72(4): 361–67
11. Singer W, Sahay BM: Myasthenia gravis, Hashimoto's thyroiditis, and pernicious anaemia. *Br Med J*, 1966; 1(5492): 904
12. Poovathingal MA, George G, Panicker G, Abhilash S: A clinical Pandora: Unusual manifestations of Vitamin B12 deficiency. *Int J Adv Med Health Res*, 2015; 2: 106–8

Conclusions

Although rare, severe cobalamin deficiency (vitamin B12 deficiency) can lead to hemolysis and severe anemia that might be life threatening. Timely and appropriate diagnosis and treatment, along with exclusion of other possible concomitant disorders, mainly other auto-immune disorders as in our patient, allowed us to achieve appropriate treatment and disease reversibility.