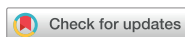

Case Report  
Neuroscience



# New-Onset Seizures in Patients With COVID-19: A Case Series From a Single Public Hospital in Korea

Yeo Jeong Cho and Hyun Kyung Kim

Department of Neurology, National Medical Center, Seoul, Korea

OPEN ACCESS

**Received:** Jan 16, 2022

**Accepted:** Mar 7, 2022

**Published online:** Mar 21, 2022

**Address for Correspondence:**

**Hyun Kyung Kim, MD**

Department of Neurology, National Medical Center, 245 Eulji-ro, Jung-gu, Seoul 04564, Korea.

Email: crespin97@gmail.com

© 2022 The Korean Academy of Medical Sciences.

This is an Open Access article distributed under the terms of the Creative Commons Attribution Non-Commercial License (<https://creativecommons.org/licenses/by-nc/4.0/>) which permits unrestricted non-commercial use, distribution, and reproduction in any medium, provided the original work is properly cited.

**ORCID iDs**

Yeo Jeong Cho

<https://orcid.org/0000-0003-1403-6824>

Hyun Kyung Kim

<https://orcid.org/0000-0002-2087-4851>

**Disclosure**

The authors have no potential conflicts of interest to disclose.

**Author Contributions**

Conceptualization: Kim HK. Data curation:

Cho YJ, Kim HK. Formal analysis: Kim HK.

Investigation: Cho YJ, Kim HK. Methodology:

Kim HK. Project administration: Kim HK.

Supervision: Kim HK. Validation: Kim HK.

Visualization: Kim HK. Writing - original draft:

Cho YJ, Kim HK.

## ABSTRACT

Seizure is an uncommon complication of coronavirus disease 2019 (COVID-19). The frequency and characteristics of new-onset seizures in hospitalized patients with COVID-19 were investigated. Of a total of 1,487 patients with confirmed COVID-19, six (0.4%) developed new-onset seizures. All six had severe or critical COVID-19 requiring intensive care and mechanical ventilation or high-flow oxygen therapy. Among COVID-19 patients admitted to the intensive care unit (n = 169), the incidence of new-onset seizures was 3.6%. Underlying structural lesions (acute infarction and remote hemorrhage), hypoxia, sepsis, and metabolic derangements were associated with the development of seizures. Of the six patients, three patients died, and, at the time of discharge, one patient had a severe disability, while the remaining two were well recovered.

**Keywords:** Seizure; COVID-19; SARS-CoV-2

## INTRODUCTION

The clinical spectrum of coronavirus disease 2019 (COVID-19) caused by severe acute respiratory syndrome coronavirus 2 (SARS-CoV-2) ranges from asymptomatic or mild disease with or without mild respiratory symptoms to critical disease with acute respiratory distress syndrome or sepsis.<sup>1,2</sup> In addition, reports of neurological manifestations in COVID-19 patients have increased rapidly since they were first described in Wuhan, China.<sup>3</sup> These manifestations may be due to the neurotropism of SARS-CoV-2 or collateral injury due to concurrent inflammatory cascades.<sup>4</sup>

Seizure is an uncommon complication of COVID-19 with a prevalence of less than 1%,<sup>2,3,5-7</sup> and may be caused by nonspecific mechanisms, such as fever, hypoxia, cytokine storm, and metabolic derangements.<sup>8</sup> Rarely, seizures may also occur due to meningoencephalitis associated with COVID-19.<sup>9-11</sup> Here, we describe the clinical characteristics of six hospitalized patients who developed new-onset seizures after SARS-CoV-2 infection at the National Medical Center in Seoul, South Korea.

## CASE DESCRIPTION

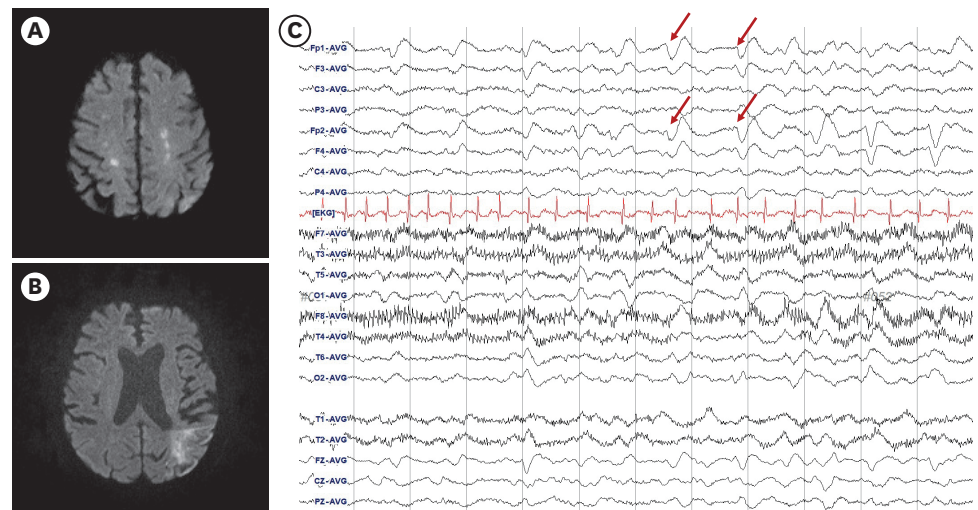
A total of 1,487 patients with confirmed COVID-19 were admitted to our hospital during the study period (June 2020 and August 2021). Out of these, six patients (0.4%) developed new-onset seizures during hospitalization. For the purpose of this study, patients with epilepsy (PWE) or a prior history of seizure were excluded. Patient demographics and clinical characteristics are summarized in **Table 1**. Patients' age ranged from 39 to 84 years, and four of the six patients were older than 60 years. Five patients were men. According to the COVID-19 disease severity classification, all patients had severe or critical COVID-19.<sup>1</sup> In

**Table 1.** Demographics and clinical characteristics of the six reported patients

Variables	Patient 1	Patient 2	Patient 3	Patient 4	Patient 5	Patient 6
Age, yr	84	45	63	72	73	39
Sex	Male	Male	Male	Male	Male	Female
Severity of COVID-19	Critical	Critical	Critical	Critical	Critical	Severe
Time from COVID-19 diagnosis to seizure (days)	44	13	41	7	56	9
Probable etiologies	Acute symptomatic : acute cerebral infarction : sepsis : uremia : drug (meropenem) : hypoxia	Remote symptomatic : prior history of SAH Acute symptomatic : hypoxia : sepsis : drug (meropenem)	Acute symptomatic : sepsis : hypoxia : other brain insults	Maybe acute symptomatic : hypoxia : sepsis : uremia	Maybe acute symptomatic : hypoxia : sepsis	Unknown : hypoxia?
Brain imaging	Acute multiple infarction, both MCA territory	Not performed	Not performed	Not performed	Not performed	Brain CT: Normal
Seizure type and frequency	Myoclonic seizures (Myoclonic status epilepticus)	Two focal to bilateral tonic-clonic seizures	Focal impaired aware seizures, multiple	Myoclonic seizure, generalized tonic-clonic seizures, multiple	Myoclonic seizures, multiple	Three generalized tonic-clonic seizures
Body temperature at the time of first seizure	36.8°C	37.1°C	36.8°C	37.6°C	37°C	38°C
Abnormal lab findings at the day of first seizure	WBC: 17,400/ $\mu$ L BUN: 63 mg/dL Cr: 1.4 mg/dL CRP: 11.1 mg/dL	WBC: 11,600/ $\mu$ L CRP: 129.6 mg/dL PO2: 61.3 mmHg O2Sat: 89.8%	WBC: 21,300/ $\mu$ L CRP: 71.5 mg/dL PO2: 67.6 mmHg O2Sat: 89.8%	WBC: 14,500/ $\mu$ L BUN: 38 mg/dL Cr: 1.3 mg/dL AST: 118 U/L ALT: 167 U/L	WBC: 21,300/ $\mu$ L CRP: 28.7 mg/dL Bilirubin: 2.2 mg/dL	WBC: 11,500/ $\mu$ L CRP: 17.6 mg/dL
Sedative drugs	Midazolam	Remifentanyl, Dexmedetomidine	Dexmedetomidine	Remifentanyl, Dexmedetomidine	Remifentanyl, Propofol	None
Treatment of COVID-19	Mechanical ventilator Hydroxychloroquine Antibiotics Steroid Enoxaparin	Mechanical ventilator Antibiotics Steroid Enoxaparin	Mechanical ventilator ECMO Remdesivir Antibiotics Steroid	Mechanical ventilator Remdesivir Antibiotics Steroid Enoxaparin	Mechanical ventilator ECMO Remdesivir Tocilizumab Steroid Antibiotics	High-flow oxygen therapy Remdesivir Antibiotics Steroid Enoxaparin
EEG	Low voltage generalized slowing Triphasic waves	Right temporal slowing	Low voltage delta Right temporal rhythmic theta	Not performed	Spindle coma Mixed generalized slowing	Normal EEG
ASM	Lorazepam Levetiracetam	Lorazepam Levetiracetam	Phenobarbital Levetiracetam Topiramate Perampamil	Levetiracetam Topiramate	Levetiracetam Valproic acid	Levetiracetam $\rightarrow$ stopping ASM
Modified Rankin Scale <sup>a</sup>	5	1	6	6	6	0

COVID-19 = coronavirus disease 2019, SAH = subarachnoid hemorrhage, MCA = middle cerebral artery, CT = computed tomography, WBC = white blood cell, BUN = blood urea nitrogen, Cr = creatinine, CRP = C-reactive protein, PO2 = partial pressure of oxygen, O2Sat = oxygen saturation, AST = aspartate aminotransferase, ALT = alanine transaminase, ECMO = extracorporeal membrane oxygenation, EEG = electroencephalography, ASM = antiseizure medication.

<sup>a</sup>Modified Rankin Scale: 0 (no symptom), 1 (no significant disability despite symptoms), 2 (slight disability), 3 (moderate disability), 4 (moderately severe disability, unable to walk unassisted), 5 (severe disability, requires constant nursing care and attention), 6 (dead).



**Fig. 1.** Brain imaging and EEG of patient 1. (A, B) Diffusion-weighted imaging shows multiple acute infarctions in both hemispheres (both internal borderzones and left posterior borderzone of middle cerebral artery territory). (C) EEG reveals diffuse slowing with triphasic waves (arrows). EEG = electroencephalography.

addition, all six patients were admitted to an intensive care unit (ICU), accounting for about 3.6% of all COVID-19 patients admitted to the ICU ( $n = 169$ ) during the study period.

The duration from COVID-19 diagnosis to seizure onset ranged from 7 to 56 days (mean duration:  $28 \pm 21$  days). Because most patients were receiving mechanical ventilation and/or extracorporeal membrane oxygenation therapy, only two patients underwent brain-imaging. Diffusion-weighted imaging in Patient 1 showed multiple acute infarctions in both hemispheres (Fig. 1). Patient 2 had a history of subarachnoid hemorrhage 2 years prior, but he experienced his first seizure after COVID-19 infection. All patients except Patient 6 had acute respiratory distress syndrome and sepsis. Patients 1 and 2 were receiving meropenem (seizure threshold-lowering antibiotics). Patient 6 was a postpartum woman (3 days after delivery), who had two generalized tonic-clonic seizures within 24 hours while receiving high-flow oxygen therapy in the ICU. She did not have symptoms suggestive of eclampsia, such as headache, elevated blood pressure, proteinuria, or peripheral edema. Her brain computed tomography (CT) scan and electroencephalography (EEG) were normal.

All five patients with critical disease were receiving mechanical ventilation and continuous intravenous sedation(s) (remifentanyl, dexmedetomidine, midazolam, or propofol). Five patients underwent EEG, and most findings showed nonspecific diffuse cerebral dysfunction and/or sedation effects, such as generalized slowing, spindle coma, or triphasic waves. Patient 3 had recurrent focal clonic seizures of the left face and arm. His EEG revealed electrographic seizures of intermittent rhythmic theta waves in the right temporal electrodes. However, there was no motor seizure (i.e., nonconvulsive seizure) during EEG monitoring.

All patients experienced multiple seizures, and seizures in Patient 1 met the criteria for status epilepticus (myoclonic seizures > 5 minutes). Patient 6 had two generalized tonic-clonic seizures, whereas the other three patients had myoclonic seizures. Focal seizures with or without bilateral tonic-clonic seizures were observed in two patients. In five patients, seizures responded to one or two antiseizure medications (ASMs). Patient 3 received four ASMs to reduce the electrographic seizures.

Three patients died due to COVID-19 pneumonia or sepsis, and one had a severe disability at discharge. Patients 2 had no significant disability, and Patient 6 was fully recovered at discharge.

## DISCUSSION

In select COVID-19 cases, neurological complications may manifest as seizures.<sup>12</sup> A prospective, multicenter study of neurological disorders in COVID-19 revealed that seizures occurred in 74 of 4,491 patients (1.6%).<sup>5</sup> Out of those 74 patients, 34 (46%, 0.76% of overall patients) had no prior history of seizure or epilepsy. In another observational study, the incidence of seizure was 5 out of 6,147 patients (0.08%).<sup>6</sup> A recent systematic review reported that 127 out of 15,467 patients (1%, 95% confidence interval:0–2%) experienced seizure as a complication of COVID-19.<sup>2</sup> In our study, the frequency of seizures was less than 1%, suggesting that seizures are a rare complication in patients with COVID-19.

The mechanisms behind the neurological manifestations of COVID-19, including seizures, are not yet fully understood. A postmortem analysis of brain samples from patients with COVID-19 demonstrated the presence of SARS-CoV-2 viral protein in 21 (53%) of the 40 examined patients.<sup>13</sup> Another study reported the presence of SARS-CoV-2 in cerebrospinal fluid (CSF) samples of 17 (6%) out of 304 patients.<sup>14</sup> SARS-CoV-2 enters human host cells via the spike (S) protein through angiotensin-converting enzyme 2 (ACE2) receptors, found on various endothelial cells, including those in the lung, blood vessels, kidneys, and small intestine.<sup>15</sup> The ACE2 receptor is also present on the pericytes of the blood-brain barrier, choroid plexus, neocortical neurons, glial cells, and olfactory epithelial cells, making these cells potential targets for SARS-CoV-2.<sup>10,16,17</sup> SARS-CoV-2 may invade the central nervous system through the olfactory epithelium/bulb or hematogenous spread across a destroyed blood-brain barrier.<sup>10,17</sup> However, detection of SARS-CoV-2 in the CSF of patients with seizures who have COVID-19 is uncommon (13%), and even when it is present, the significance of this finding is unknown.<sup>18</sup>

Various indirect mechanisms, such as fever, hypoxia, hypoperfusion, cytokine storm/septic encephalopathy, coagulation dysfunction, cardiovascular disturbance, metabolic derangement, and multiorgan failure, may also be associated with the development of seizures in patients with COVID-19.<sup>8,10,17</sup> Meningoencephalitis related to COVID-19 can cause seizures or status epilepticus.<sup>9-11</sup>

In this case series, most patients had structural lesions or medical illnesses that could affect the development of seizures. Several systemic insults (e.g., metabolic derangements and hypoxia), acute brain insults, and certain medications can lead to acute symptomatic seizures.<sup>19,20</sup> Patient 1 had myoclonic seizures, and his EEG showed triphasic waves associated with metabolic or toxic encephalopathy. Therefore, the etiology of his seizures was more likely to be sepsis, uremia, or seizure threshold-lowering drug (e.g., meropenem) than acute cerebral infarction. On the other hand, in the case of Patient 2, the remote subarachnoid hemorrhage was likely a major cause of seizures considering focal onset seizures. Patient 6, a postpartum woman with COVID-19, had no obvious cause of seizures, though hypoxia and fever may have contributed to her seizures. Additionally, as none of the patients underwent lumbar puncture, and brain imaging was performed only in two patients, encephalitis or encephalopathy due to direct invasion of SARS-CoV-2, or other brain structural etiologies could not be excluded.

Early systematic reviews described that the mean duration from the onset of initial COVID-19 symptoms to the development of seizure was 5 days.<sup>21</sup> The seizure was also described as an initial presenting symptom of COVID-19.<sup>6,22</sup> However, in half of our patients, seizures occurred late after COVID-19 onset. Late-onset seizures may be because the patients had severe or critical COVID-19 disease (that is, after COVID-19 disease had progressed). In another case report, seizures occurred 3 weeks after COVID-19 diagnosis in two patients with critical disease.<sup>23</sup>

Continuous EEG monitoring is an important tool for detecting seizures and assessing brain function in the critical care environment. In a case series of 100 non-postarrest patients with COVID-19 monitored with EEG, seven patients (7%) were positive for seizures.<sup>24</sup> This incidence is similar to or slightly lower than the incidence of seizures (10–11%) in other critically ill patients admitted to medical ICUs.<sup>25,26</sup> In addition, nonconvulsive seizure is an uncommon contributor to encephalopathy in patients hospitalized with COVID-19.<sup>24</sup> In our study, the incidence of seizures in COVID-19 patients admitted to ICU (3.6%) was much lower than in studies using continuous EEG monitoring, but similar to the incidence reported in a previous study investigating clinical seizures in medically ill patients admitted to ICU (3.47%).<sup>27</sup> Since only patients with clinical motor seizures underwent EEG, subtle seizures or nonconvulsive seizures may have been more prevalent in our cohort. In summary, seizures do not appear to occur more frequently in patients with severe/critical COVID-19 than in patients with other critical medical illnesses.

All our patients had severe or critical COVID-19 and half died. However, a recent systematic review found no association between seizure and severity of COVID-19.<sup>2</sup> Moreover, altered mentation or stroke were associated with higher in-hospital mortality in COVID-19, but not seizures.<sup>7</sup> Several previous studies included patients with a prior history of seizure or epilepsy.<sup>5,7,22</sup> Therefore, those studies may have included habitual or breakthrough seizures in PWE as well as seizures directly associated with COVID-19. In addition, fever is one of the seizure precipitants in PWE, and therefore the frequency of seizures in PWE may increase even in mild COVID-19 cases.<sup>28</sup> In other case series, most of the patients with COVID-19 who developed new-onset seizures were critically ill.<sup>23,29</sup>

New-onset seizures are a rare complication of COVID-19, but may occur more commonly in critically ill patients. Nonspecific mechanisms related to COVID-19 can trigger the development of acute symptomatic seizures. In addition, direct brain invasion of SARS-CoV-2 may be related to the occurrence of seizures in some COVID-19 patients with seizure.

### Ethics statement

The Institutional Review Board of the National Medical Center reviewed and approved the study protocol (Approval No. NMC-2022-01-001). The need to obtain informed consent was waived by the board.

## REFERENCES

1. World Health Organization. Living guidance for clinical management of COVID-19. <https://www.who.int/publications/i/item/WHO-2019-nCoV-clinical-2021-2>. Updated 2021. Accessed December 11, 2021.
2. Misra S, Kolappa K, Prasad M, Radhakrishnan D, Thakur KT, Solomon T, et al. Frequency of neurologic manifestations in COVID-19: a systematic review and meta-analysis. *Neurology* 2021;97(23):e2269-81.  
[PUBMED](#) | [CROSSREF](#)

3. Mao L, Jin H, Wang M, Hu Y, Chen S, He Q, et al. Neurologic manifestations of hospitalized patients with coronavirus disease 2019 in Wuhan, China. *JAMA Neurol* 2020;77(6):683-90.  
[PUBMED](#) | [CROSSREF](#)
4. Pizzi MA. Acute neurologic manifestations of respiratory viruses. *Continuum (Minneap Minn)* 2021;27(5):1365-81.  
[PUBMED](#) | [CROSSREF](#)
5. Frontera JA, Sabadia S, Lalchan R, Fang T, Flusty B, Millar-Verneti P, et al. A prospective study of neurologic disorders in hospitalized patients with COVID-19 in New York City. *Neurology* 2021;96(4):e575-86.  
[PUBMED](#) | [CROSSREF](#)
6. Emami A, Fadakar N, Akbari A, Lotfi M, Farazdaghi M, Javanmardi F, et al. Seizure in patients with COVID-19. *Neurol Sci* 2020;41(11):3057-61.  
[PUBMED](#) | [CROSSREF](#)
7. Eskandar EN, Altschul DJ, de la Garza Ramos R, Cezayirli P, Unda SR, Benton J, et al. Neurologic syndromes predict higher in-hospital mortality in COVID-19. *Neurology* 2021;96(11):e1527-38.  
[PUBMED](#) | [CROSSREF](#)
8. Vohora D, Jain S, Tripathi M, Potschka H. COVID-19 and seizures: is there a link? *Epilepsia* 2020;61(9):1840-53.  
[PUBMED](#) | [CROSSREF](#)
9. Bhagat R, Kwiecinska B, Smith N, Peters M, Shafer C, Palade A, et al. New-onset seizure with possible limbic encephalitis in a patient with COVID-19 infection: a case report and review. *J Investig Med High Impact Case Rep* 2021;9:2324709620986302.  
[PUBMED](#) | [CROSSREF](#)
10. Keyhanian K, Umeton RP, Mohit B, Davoudi V, Hajighasemi F, Ghasemi M. SARS-CoV-2 and nervous system: From pathogenesis to clinical manifestation. *J Neuroimmunol* 2020;350:577436.  
[PUBMED](#) | [CROSSREF](#)
11. Le Guennec L, Devianne J, Jalin L, Cao A, Galanaud D, Navarro V, et al. Orbitofrontal involvement in a neuroCOVID-19 patient. *Epilepsia* 2020;61(8):e90-4.  
[PUBMED](#) | [CROSSREF](#)
12. Narula N, Joseph R, Katyal N, Daouk A, Acharya S, Avula A, et al. Seizure and COVID-19: association and review of potential mechanism. *Neurol Psychiatry Brain Res* 2020;38:49-53.  
[PUBMED](#) | [CROSSREF](#)
13. Matschke J, Lütgehetmann M, Hagel C, Spherhake JP, Schröder AS, Edler C, et al. Neuropathology of patients with COVID-19 in Germany: a post-mortem case series. *Lancet Neurol* 2020;19(11):919-29.  
[PUBMED](#) | [CROSSREF](#)
14. Lewis A, Frontera J, Placantonakis DG, Lighter J, Galetta S, Balcer L, et al. Cerebrospinal fluid in COVID-19: a systematic review of the literature. *J Neurol Sci* 2021;421:117316.  
[PUBMED](#) | [CROSSREF](#)
15. Li YC, Bai WZ, Hashikawa T. The neuroinvasive potential of SARS-CoV2 may play a role in the respiratory failure of COVID-19 patients. *J Med Virol* 2020;92(6):552-5.  
[PUBMED](#) | [CROSSREF](#)
16. Yachou Y, El Idrissi A, Belapasov V, Ait Benali S. Neuroinvasion, neurotropic, and neuroinflammatory events of SARS-CoV-2: understanding the neurological manifestations in COVID-19 patients. *Neurol Sci* 2020;41(10):2657-69.  
[PUBMED](#) | [CROSSREF](#)
17. Tancheva L, Petralia MC, Miteva S, Dragomanova S, Solak A, Kalfin R, et al. Emerging neurological and psychobiological aspects of COVID-19 infection. *Brain Sci* 2020;10(11):E852.  
[PUBMED](#) | [CROSSREF](#)
18. Carroll E, Melmed KR, Frontera J, Placantonakis DG, Galetta S, Balcer L, et al. Cerebrospinal fluid findings in patients with seizure in the setting of COVID-19: A review of the literature. *Seizure* 2021;89:99-106.  
[PUBMED](#) | [CROSSREF](#)
19. Beghi E, Carpio A, Forsgren L, Hesdorffer DC, Malmgren K, Sander JW, et al. Recommendation for a definition of acute symptomatic seizure. *Epilepsia* 2010;51(4):671-5.  
[PUBMED](#) | [CROSSREF](#)
20. Karceski S. Acute symptomatic seizures and systemic illness. *Continuum (Minneap Minn)* 2014;20(3):614-23.  
[PUBMED](#) | [CROSSREF](#)
21. Chua TH, Xu Z, King NK. Neurological manifestations in COVID-19: a systematic review and meta-analysis. *Brain Inj* 2020;34(12):1549-68.  
[PUBMED](#) | [CROSSREF](#)

22. Anand P, Al-Faraj A, Sader E, Dashkoff J, Abdennadher M, Murugesan R, et al. Seizure as the presenting symptom of COVID-19: a retrospective case series. *Epilepsy Behav* 2020;112:107335.  
[PUBMED](#) | [CROSSREF](#)
23. Mithani F, Poursheykhi M, Ma B, Smith RG, Hsu SH, Gotur D. New-onset seizures in three COVID-19 patients: a case series. *J Clin Neurophysiol* 2021;38(2):e5-10.  
[PUBMED](#)
24. Pellinen J, Carroll E, Friedman D, Boffa M, Dugan P, Friedman DE, et al. Continuous EEG findings in patients with COVID-19 infection admitted to a New York academic hospital system. *Epilepsia* 2020;61(10):2097-105.  
[PUBMED](#) | [CROSSREF](#)
25. Oddo M, Carrera E, Claassen J, Mayer SA, Hirsch LJ. Continuous electroencephalography in the medical intensive care unit. *Crit Care Med* 2009;37(6):2051-6.  
[PUBMED](#) | [CROSSREF](#)
26. Gilmore EJ, Gaspard N, Choi HA, Cohen E, Burkart KM, Chong DH, et al. Acute brain failure in severe sepsis: a prospective study in the medical intensive care unit utilizing continuous EEG monitoring. *Intensive Care Med* 2015;41(4):686-94.  
[PUBMED](#) | [CROSSREF](#)
27. Bleck TP, Smith MC, Pierre-Louis SJ, Jares JJ, Murray J, Hansen CA. Neurologic complications of critical medical illnesses. *Crit Care Med* 1993;21(1):98-103.  
[PUBMED](#) | [CROSSREF](#)
28. Ferlisi M, Shorvon S. Seizure precipitants (triggering factors) in patients with epilepsy. *Epilepsy Behav* 2014;33:101-5.  
[PUBMED](#) | [CROSSREF](#)
29. Hepburn M, Mullaguri N, George P, Hantus S, Punia V, Bhimraj A, et al. Acute symptomatic seizures in critically ill patients with COVID-19: is there an association? *Neurocrit Care* 2021;34(1):139-43.  
[PUBMED](#) | [CROSSREF](#)