



Since January 2020 Elsevier has created a COVID-19 resource centre with free information in English and Mandarin on the novel coronavirus COVID-19. The COVID-19 resource centre is hosted on Elsevier Connect, the company's public news and information website.

Elsevier hereby grants permission to make all its COVID-19-related research that is available on the COVID-19 resource centre - including this research content - immediately available in PubMed Central and other publicly funded repositories, such as the WHO COVID database with rights for unrestricted research re-use and analyses in any form or by any means with acknowledgement of the original source. These permissions are granted for free by Elsevier for as long as the COVID-19 resource centre remains active.



ELSEVIER



Correspondence and Communications

The surgical burden of sebaceous naevus excision in childhood



Dear Sir,

Introduction

First described in 1895 by Jadassohn, naevus sebaceous refers to a benign, congenital hamartomatous lesion of the pilosebaceous follicular unit. Sebaceous naevi have a known three-stage evolution. In infancy, they present as a pink/orange waxy, alopecic plaque, with proliferation and hyperplasia during puberty, giving a verrucous appearance. The third phase occurs in ~20% of cases, with the development of secondary neoplasia. Benign neoplasms predominate, specifically trichoblastoma.^{1,2} While malignant transformation into basal cell carcinoma (BCC) is recognised, the originally quoted incidence of 20%³ has not been confirmed in several large cohort studies, and it is believed that many of these were trichoblastomas, misinterpreted as BCCs.^{2,4-6} The true incidence of BCC is probably closer to 0.8%.^{2,4-6} While it has been common practice to carry out prophylactic excision during childhood it is argued that this is not necessary for cancer prevention and that excision can be deferred until adulthood or if the lesions become problematic.⁴⁻⁶ The aim of this study was to investigate our experience of sebaceous naevus management and evaluate the surgical burden of care produced by the traditional approach of prophylactic excision in childhood.

Method

A retrospective analysis of all sebaceous naevi excised in a tertiary referral paediatric hospital, over a ten-year period (January 2007 to December 2017) was conducted. Microsoft Excel v16® was used to analyse the data. STROBE guidelines were employed.

Results

During this period, 189 paediatric patients had excision of a sebaceous naevus. Average age was 6.4 years (median

4.2 years, range 4 months to 18 years), with male predominance ($n = 103$, 55%). Lesions were primarily located in the head and neck ($n = 182$, 96%), with the remaining lesions located on the trunk (axilla: $n = 3$; back: $n = 2$; abdomen: $n = 1$; buttock: $n = 1$). General anaesthetic was administered for most procedures ($n = 187$, 99%), with two excisions performed under local anaesthetic (1%). Forty-three patients (23%) required more than one general anaesthetic with an average of 2.5 general anaesthetics (range 2–6) per patient.

The majority were closed primarily (98%, $n = 186$), with three patients requiring rotation flap (2%). No patient was grafted primarily. Staged-excision was required in 17% ($n = 33$), three of whom required tissue expansion. Of the remaining 30 patients, clearance was achieved with two excisions in 73% ($n = 22$), three excisions in 20% ($n = 6$) and four excisions in the minority ($n = 2$, 7%) (Table 1).

No case of malignancy was identified.

With regards to post-operative sequelae and complications, four patients developed post-operative alopecia (2%), four problematic scarring (2%), three required a further general anaesthetic for suture removal ($n = 3$, 1.6%), one evacuation of haematoma and one excision of post-operative pyogenic granuloma (Table 2).

For problematic scarring, under general anaesthetic, two patients required steroid injections for keloid scarring, one required excision of a hypertrophic scar and one required scar revision. For management of alopecia, one patient underwent serial excision in two stages, one patient excision with rotation flap and two patients had secondary reconstruction by tissue expansion. One of these subsequently experienced wound breakdown, requiring excision and split-thickness skin grafting.

Discussion

The traditional approach to management of naevus sebaceous has been to recommend excision before puberty, to minimise the risk of malignant transformation. In a retrospective review of 707 cases, Idriss and Elston² identified a malignant transformation rate of 2.5%, with almost all malignancies identified in adults. Tumours comprised BCC, squamous cell carcinoma, sebaceous carcinoma, apocrine carcinoma and microcystic adnexal carcinoma, none of which metastasised. A lower rate of 0.8% was identified by Rosen, Schmidt⁶ with five cases of BCC identified in a series of 631 patients. This incidence of 0.8% was also reported by Cribier, Scrivener⁴ in their study of 596 patients. There were no cases of malignant transformation in patients un-

Abbreviations: BCC, Basal Cell Carcinoma.

Presented at meeting: Irish Association of Plastic Surgeons, Dublin, Ireland, 2018.

Table 1 Staged-excision requirements.

| Excision | Number of patients (%) |
|----------|------------------------|
| 1 stage | 156 (83%) |
| 2 stage | 25 (13%) |
| 3 stage | 6 (3%) |
| 4 stage | 2 (1%) |

Table 2 Post-operative sequelae requiring general anaesthetic.

| Indication for general anaesthetic in post-operative setting | No of patients (n = 13) |
|--|-------------------------|
| Excision of alopecia | 4 |
| - Excision & Primary Closure | 2 |
| - Tissue Expander | 2 |
| Removal of sutures | 3 |
| Scar Management | 4 |
| - Steroid injection | 2 |
| - Scar Revision | 1 |
| - Excision of hypertrophic scar | 1 |
| Excision of pyogenic granuloma | 1 |
| Evacuation of haematoma | 1 |

der 16 years. This finding was also reported by Santibanez-Gallerani, Marshall,⁵ who did not identify any malignancy in their study of 757 paediatric cases (<16years).

The present study found no malignancy in 189 patients who underwent prophylactic excision during childhood. There was a significant surgical and anaesthetic burden of care. Post-operative sequelae requiring operative intervention occurred in 7% (n = 13). With most patients aged under ten years, general anaesthesia was required in 99%, with 23% of patients requiring more than one general anaesthetic. While general anaesthesia in children is generally safe, repeated anaesthetics can be distressing for young children and are not entirely without risk.

We no longer advise routine sebaceous naevus excision during childhood. The natural history and three-stage evolution is explained to parents, and we advise that excision can be performed when the patient is old enough to tolerate a local anaesthetic procedure, if the lesions become cosmetically troublesome during or after puberty or if they undergo changes suspicious of BCC. In cases where lesions are large and cosmetically disfiguring, consideration may be given to excision during childhood. In such cases, we advise delaying until the child is old enough to participate in decision-making regarding their management and co-operate without distress with procedures like post-operative wound care or tissue expansion.

Conclusion

Routine excision of sebaceous naevi during childhood carries a high burden of care and is not necessary for cancer prevention. Excision can be safely delayed until patients are old enough to participate in decision-making about their surgery.

Declaration of Competing Interest

Nothing to disclose.

Financial support

Nothing to disclose.

Ethical approval

Not required.

References

- Dinulos JGH. *Habif's Clinical Dermatology*. 7th ed. Elsevier Inc; 2020.
- Idriss MH, Elston DM. Secondary neoplasms associated with nevus sebaceus of Jadassohn: A study of 707 cases. *J Am Acad Dermatol* 2014;**70**(2):332-7.
- Michalowski R. Jadassohn's sebaceous nevus a precancerous state. *Dermatologica* 1962;**124**:326-40.
- Cribier B, Scrivener Y, Grosshans E. Tumors arising in nevus sebaceus: A study of 596 cases. *J Am Acad Dermatol* 2000;**42**(2 Pt 1):263-8.
- Santibanez-Gallerani A, Marshall D, Duarte AM, Melnick SJ, Thaller S. Should nevus sebaceus of Jadassohn in children be excised? A study of 757 cases, and literature review. *J Craniofac Surg* 2003;**14**(5):658-60.
- Rosen H, Schmidt B, Lam HP, Meara JG, Labow BI. Management of nevus sebaceus and the risk of Basal cell carcinoma: An 18-year review. *Pediatr Dermatol* 2009;**26**(6):676-81.

Máire-Caitlín Casey*

David JA Orr

Department of Plastic & Reconstructive Surgery, Our Lady's Children's Hospital and St. James's Hospital, Dublin, Ireland

*Corresponding author.

E-mail address: maireccasey@rcsi.ie (M.-C. Casey)

© 2022 British Association of Plastic, Reconstructive and Aesthetic Surgeons. Published by Elsevier Ltd. All rights reserved.

<https://doi.org/10.1016/j.bjps.2022.06.003>

Examining the prevalence and incidence of amelanotic melanoma in two Irish Hospitals



Dear Sir,

Amelanotic Melanoma (AM) represent a large proportion of difficult to diagnose melanoma, this is due to these lesions being partially or completely devoid of pigment. This occurs in two ways, either due to regression of pigment in the lesion or due to malignant melanocytes within the tumour, being unable to produce mature melanin granules¹ or a combination of both. AM commonly presents as white or 'skin coloured' lesions, with a variable percentage presenting as red, pink, or erythematous lesions.¹ Earlier lesions are asymmetrical macular lesions that are uniformly pink or red and may have a faint tan, brown or grey pigment in the periphery and with borders that may be well or ill defined.¹ Melanoma is staged using the Breslow Thickness (BT) scale which classifies stages of melanoma based on depth of invasion in millimeters, with thicker tumours being associated with worse outcomes.² Risk factors for develop-

ing AM are sun exposure and increasing age.² The true incidence of AM is difficult to quantify, as many hypopigmented lesions are incorrectly labelled as amelanotic.³ The prevalence of AM is not known in an Irish context but according to the National Cancer Registry of Ireland, less than 5 AM have been recorded during 2014-2016, representing 0.45% of all melanomas, based on a histological definition of AM (personal communication). A case series in primary care in Ireland identified 13 of 56 melanomas (23%) of that case series to be amelanotic⁴ and internationally the prevalence is estimated to be between 2 and 20% of all melanomas.⁵

A retrospective cohort study of patients with melanoma diagnoses was conducted in 2019 in two large Irish hospitals and records were re-examined, to determine how many lesions were amelanotic 'to the naked eye'. This required checking hospital records and histopathology reports. For each melanoma, thickness in mm as well as category (T1-4) and ulceration status (unknown, a or b) was recorded.

Of the 175 and 97 patients with melanoma in each hospital, 14.4% and 22% respectively were identified as amelanotic resulting in an overall prevalence of 16.9%. The patients' mean age was 68 (+/- 0.9) years and the melanomas had an average BT of 1.9 mm (+/- 0.1 mm) (Table 1). The extrapolated incidence was based on the size of the target population in the area covered by the two hospitals and calculated to be 5.41 per 100,000 population.

Age was significantly higher for AM patients (73 +/- 14 versus 66 +/- 15 years, $p = 0.004$) as was the BT (3.4 +/- 3.7 versus 1.6 +/- 1.8, $p = 0.004$) (Figure 1) and the

Abbreviations: BCC, Basal Cell Carcinoma.

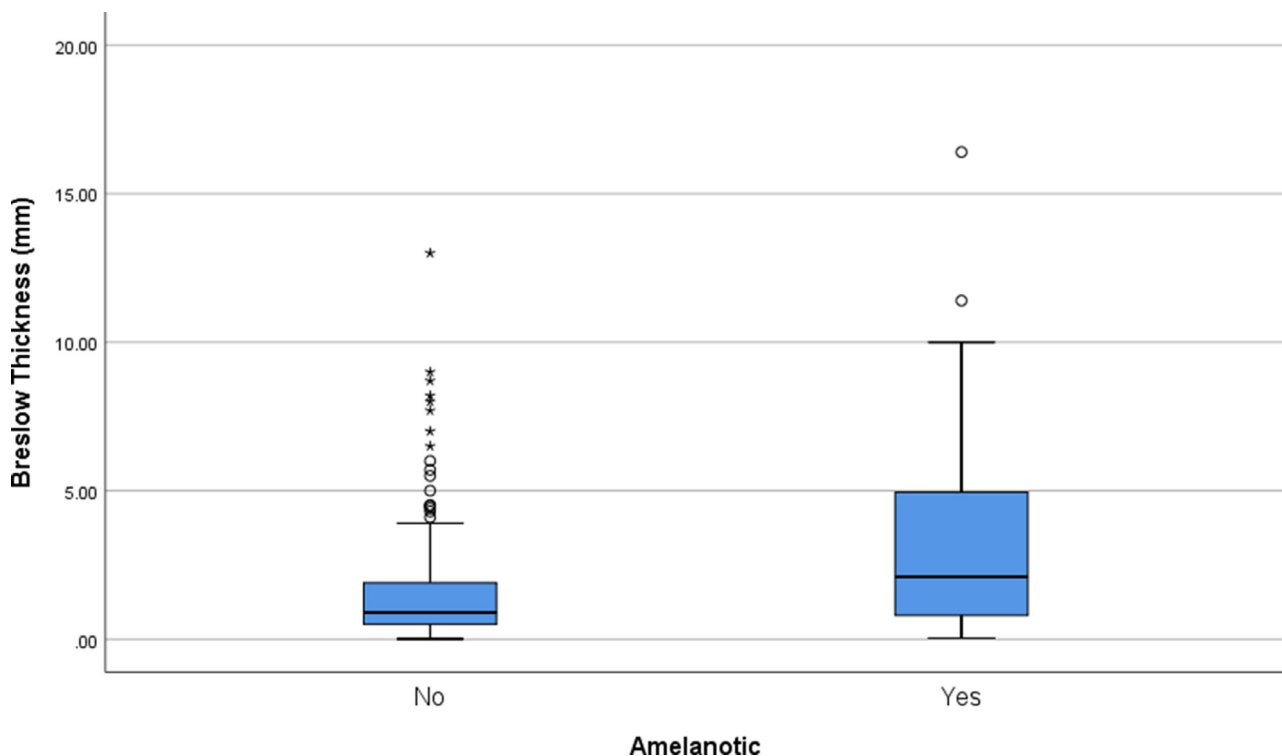


Figure 1 Boxplot of Breslow Thickness in mm of non-amelanotic (pigmented) compared to amelanotic melanomas (AM). Boxplot shows mean (line), the box represents 50% of values while the whiskers cover 95% of values.

Table 1 Comparison of depth of invasion according to the Breslow Thickness (T1 \leq 1 mm, T2 $>$ 0.1-2.0 mm, T3 $>$ 2.0-4.0 mm, T4 $>$ 4.0 mm) between amelanotic melanoma (AM) and non-AM (pigmented).

| Depth of Invasion | | T1 | T2 | T3 | T4 | Total |
|-------------------|----------|-------|-------|-------|-------|-------|
| AM | N | 6 | 6 | 9 | 22 | 43 |
| | % | 14.0% | 14.0% | 20.9% | 51.2% | |
| Non-AM | N | 106 | 50 | 37 | 27 | 220 |
| | % | 48.2% | 22.7% | 16.8% | 12.3% | |

depth of invasion (T1 to T4, $p = 0.000$). No difference in ulceration was observed.

Most lesions were identified on extremities (38%), face (16%) and Back/Shoulder (18%) but no differences could be identified between AM and non-AM lesion locations.

This study showed a major discrepancy between the estimates of the national cancer registry of Ireland, which calculated the rate of AM at 0.5% of all melanomas recorded over a four year period. This is in stark contrast to the findings of our study which calculate the rate of AM at 17% of all melanomas recorded in our population per year. AM is far more prevalent than reported in an Irish context, and our study has shown the prevalence is similar to other international reports.⁵

In our data, AM presented with an increased Breslow thickness which is known to be associated with worse outcomes and decreased overall survival. A melanoma with a Breslow thickness of > 4 mm has a less than 50% survival at 5 years compared with a $>90\%$ chance of survival for lesions <1 mm.⁶ Alerting healthcare professionals and the public to the prevalence of these lesions is extremely important. To improve the detection of AM in the community would require an increased awareness and focused training in both primary and secondary care and potentially have an impact on dermatology and plastic surgery services. We also identified a lack of a unified definition of AM, with no consensus on how much pigment a melanoma must contain before it is classified as an AM which also requires further investigation.

Funding

No financial support.

Declaration of Competing Interest

The authors declare that they have no conflict of interest.

Ethical statement

This retrospective chart review study involving human participants was in accordance with the ethical standards of the institutional and national research committee and with the 1964 Helsinki Declaration and its later amendments or comparable ethical standards. The Human Investigation Committee (IRB) of Beaumont Hospital and Cork University Hospital approved this study.

References

- McClain SE, Mayo KB, Shada AL, et al. Amelanotic melanomas presenting as red skin lesions: a diagnostic challenge with potentially lethal consequences. *Int J Dermatol* 2012;**51**: 420-426.
- Strazzulla LC, Li X, Zhu K, et al. Clinicopathologic, misdiagnosis, and survival differences between clinically amelanotic melanomas and pigmented melanomas. *J Am Acad Dermatol* 2019;**80**:1292-8.
- Pizzichetta MA, Talamini R, Stanganelli I, et al. Amelanotic/hypomelanotic melanoma: clinical and dermoscopic features. *Br J Dermatol* 2004;**150**:1117-24.
- Buckley D, McMonagle C. Melanoma in primary care. The role of the general practitioner. *Ir J Med Sci* 2014;**183**:363-8.
- Thomas NE, Krickler A, Waxweiler WT, et al. Comparison of clinicopathologic features and survival of histopathologically amelanotic and pigmented melanomas: a population-based study. *JAMA Dermatol* 2014;**150**:1306-14.
- Balch CM, Buzaid AC, Soong SJ, et al. Final version of the American Joint Committee on Cancer staging system for cutaneous melanoma. *J Clin Oncol* 2001;**19**:3635-48.

Darren McCormack

Department of Plastic Surgery, Beaumont Hospital,
Beaumont Road, Dublin 9, Ireland

Alexandra Frankel

School of Medicine, Royal College of Surgeons in Ireland,
Dublin, Ireland

Natasha Christodoulides

Department of Plastic Surgery, Cork University Hospital,
Wilton, Cork, Ireland

Akke Vellinga

School of Public Health, Physiotherapy and Sports
Science, University College Dublin, Dublin, Ireland

Dalal Alhassan

Department of Plastic Surgery, Cork University Hospital,
Wilton, Cork, Ireland

Jamie Martin-Smith

Department of Plastic Surgery, Beaumont Hospital,
Beaumont Road, Dublin 9, Ireland

Michael O'Shaughnessy, David Buckley

Department of Plastic Surgery, Cork University Hospital,
Wilton, Cork, Ireland

E-mail address: akke.vellinga@ucd.ie (A. Vellinga)

A study of the effects of pre-operative cutaneous BCC duration on tumour progression



Dear Sir,

Basal cell carcinoma (BCC) is the most common skin cancer type encountered globally (75%); despite relatively slow growth and negligible metastatic potential, untreated BCCs may cause local tissue destruction and significant morbidity.¹ This study investigates the effects of delayed BCC treatment; similar to our published squamous cell carcinoma (SCC) study, we anticipated a delay in patient presentation during the COVID-19 pandemic and sought to investigate whether this also had an effect on histopathological parameters.²

A cohort study of patients ($n=138$), who underwent cutaneous BCC excision in October 2020 (pandemic group, $n=85$) and October 2019 (pre-pandemic group, $n=53$) were included. Patient demographics and comorbidity data were collected. Histological parameters were collected from the hospital pathology database, as prospectively reported according to The Royal College of Pathologists histopathological reporting guidelines. BCC surface area size was calculated using the two reported axes on the basis that lesions were likely to be circular/elliptical in shape.³ Total lesion duration before surgery was calculated by com-

paring lesion duration before first GP presentation, and GP referral to excision time. Mann Whitney U tests were applied to continuous data, which were non-parametric; median (IQR) values are presented. Categorical variables were analysed using the Chi² test. Pooled data regression analyses were applied to multiple variables including total lesion duration, BCC surface area size, thickness, and depth.

The pandemic and pre-pandemic groups were well matched for median (IQR) age [80 years (76-85) vs. 83 years (75-86), $p=0.312$], sex ($M=44/F=41$ vs. $M=35/F=18$, $p=0.099$), previous cutaneous BCC history (19.7% (13/85) vs. 17.24% (8/53), $p=0.974$) and histological subtypes ($p>0.05$); there were no significant differences between total BCC duration prior to surgery (65 weeks (35-110) vs. 55.5 weeks (42-96), $p=0.401$), surface area size (50.3mm² (33.0-90.3) vs. 78.5mm² (29.5-148.0), $p=0.842$), thickness (2 mm (1.5-3.1) vs. 2.5 mm (2-3), $p=0.660$), complete excision rates (96.4% vs. 94.3%, $p=0.550$) and surgical reconstruction methodology (direct closure: 51.76% (44/85) vs. 62.26% (33/53), $p=0.227$; graft: 35.2% (30/85) vs. 39.6% (21/53), $p=0.608$; local flap: 12.9% (11/85) vs. 15% (8/53), $p=0.721$). Linear regression modelling indicated a direct correlation between total pre-operative lesion duration and surface area size ($p=0.013$), but not for thickness ($p=0.410$), or depth of penetration ($p=0.424$) (Figure 1).

An initial median 70.4% decline in urgent cancer referrals has been reported following the implementation of the first UK COVID-19 lockdown.⁴ Although our BCC data do not support a longer duration before surgery in the pandemic vs. pre-pandemic group, pooled regression analysis does demonstrate a correlation between longer BCC duration and surface area size, but not for thickness and depth of penetration; these findings support the concept that BCCs are more likely to grow larger over time but not become invasive and spread.⁵ Furthermore, these findings contrast to those recently published for SCC from our Centre, which indicated that a 57-day median treatment delay in the pandemic group, was associated with an increased Breslow depth (4 mm vs. 3 mm, $p=0.01$), and greater proportion of high and very high-risk SCCs (56.1% vs. 39.2%, $p=0.03$) according to British Association of Dermatologists (BAD) SCC diameter criteria.²

Abbreviations: BCC, Basal Cell Carcinoma.

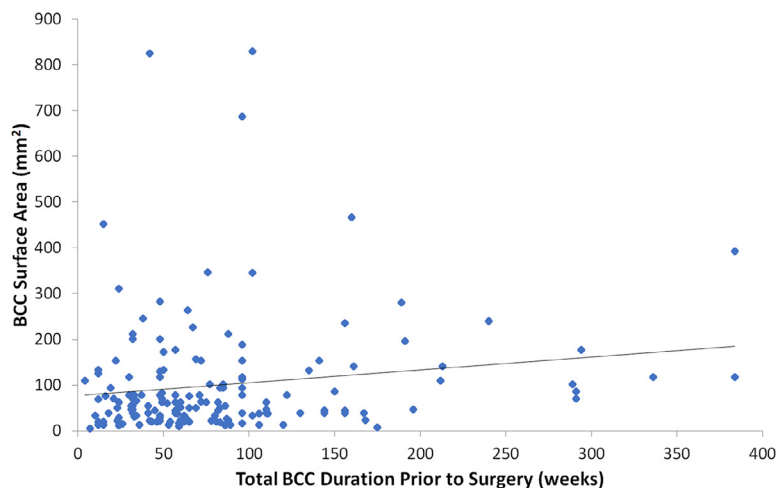


Fig. 1 Pooled Data Regression Analysis & Results: A direct correlation between total pre-operative lesion duration and surface area size ($p=0.013$) was observed, but not for thickness ($p=0.410$), or depth of penetration ($p=0.424$).

Future larger cohort studies are required to generate a like-for-like comparison of the impact of treatment delay on BCC and SCC progression, as well as the timing of surgery. However, our findings suggest that BCCs are at lower risk of invasive progression versus SCCs, and their differential management is justified. According to BAD guidelines, clinically high-risk BCCs include those with a diameter >20 mm (trunk/extremities) or >10 mm (cheeks/forehead/scalp/neck/pre-tibia), poorly differentiated borders or those that are recurrent.⁶ High-risk BCCs and those causing functional/cosmetic issues, should be assessed for early excision and, even in the context of a pandemic, patients should be encouraged to present early to their GP with any suspicious skin changes.⁶

Funding

None

Ethics

N/A

Declaration of Competing Interest

None

References

1. Koelblinger P, Lang R. New developments in the treatment of basal cell carcinoma: update on current and emerging treatment options with a focus on vismodegib. *Onco Targets Ther* 2018;11:8327-40.
2. Shahid S, Gao J, Corriero AC, Roszpopa J, Miranda BH. A study of the effects of delayed patient presentation on cutaneous SCC progression. *J Plast Reconstr Aesthet Surg* 2022;75(2):722-9.
3. Miranda BH, Herman KA, Malahias M, Juma A. When are circular lesions square? A national clinical education skin lesion audit and study. *Arch Plast Surg* 2014;41(5):500-4.
4. Lai AG, Pasea L, Banerjee A. Estimated impact of the COVID-19 pandemic on cancer services and excess 1-year mortality in people with cancer and multimorbidity: near real-time data on cancer care, cancer deaths and a population-based cohort study. *BMJ Open* 2020;10:e043828.
5. Wong CS, Strange RC, Lear JT. Basal cell carcinoma. *BMJ* 2003;327:794-8.
6. Nasr I, McGrath EJ, Harwood CA. British association of dermatologists guidelines for the management of adults with basal cell carcinoma 2021. *Br J Dermatol* 2021;185:899-920.

Chrysavgi Mavrokefalou
St Andrew's Centre for Plastic Surgery & Burns,
Broomfield Hospital, Chelmsford CM1 7ET, United Kingdom

Anna C Corriero
St Andrew's Anglia Ruskin (StAAR) Research Group, School
of Medicine, Faculty of Health, Education, Medicine, and
Social Care, Anglia Ruskin University, Chelmsford, United
Kingdom

Shahab Shahid
St Andrew's Centre for Plastic Surgery & Burns,
Broomfield Hospital, Chelmsford CM1 7ET, United Kingdom

Ben H Miranda*
St Andrew's Centre for Plastic Surgery & Burns,
Broomfield Hospital, Chelmsford CM1 7ET, United Kingdom
St Andrew's Anglia Ruskin (StAAR) Research Group, School
of Medicine, Faculty of Health, Education, Medicine, and
Social Care, Anglia Ruskin University, Chelmsford, United
Kingdom

*Corresponding author.
E-mail address: Ben.Miranda@nhs.net (B.H. Miranda)

© 2022 British Association of Plastic, Reconstructive and Aesthetic Surgeons. Published by Elsevier Ltd. All rights reserved.

<https://doi.org/10.1016/j.bjps.2022.04.076>

The impact of COVID19 on the presentation, diagnosis and management of cutaneous melanoma and squamous cell carcinoma in a single tertiary referral centre



Dear Sir,

Introduction

The SARS-CoV-2 pandemic has had a substantial impact on the provision of surgical services worldwide.¹ In the United Kingdom, staff redeployment and reduced staffing due to infection and self-isolation has reduced the availability of clinic slots and theatre lists. Additionally, there has been a substantial reduction in the volume of patients presenting to general practice and hospitals during the height of the pandemic.¹ The potential compounded effects of a reduction in referrals along skin cancer pathways and availability of specialist review and intervention has placed patients at risk of delayed investigation, diagnosis, and treatment, and incurred a possibility of adverse outcomes and an increase in morbidity and mortality.^{2,3} The aim of this study was to assess the impact of the pandemic upon patients presenting to a speciality skin cancer service.

Abbreviations: BCC, Basal Cell Carcinoma.
Data presented in part at the 10th World Congress of Melanoma
15th-17th April 2021

Table 1 Cutaneous melanoma results summary.

| Demographic | 2019 (n = 109) | 2020 (n = 74) | p = |
|---|---------------------|---------------------|-------|
| Age (\pm SD) | 64.3 (\pm 16.5) | 63.5 (\pm 17.0) | 0.769 |
| Gender | | | |
| Female (%) | 60 (55%) | 42 (57%) | 0.819 |
| Male (%) | 49 (45%) | 32 (43%) | |
| Location (%) | | | |
| Head and Neck | 20 (18.7%) | 12 (16.2%) | 0.850 |
| Upper Limb | 28 (26.2%) | 18 (24.3%) | |
| Lower Limb | 31 (29%) | 26 (35.1%) | |
| Trunk | 18 (26.2%) | 18 (24.3%) | |
| Stage | | | |
| T Stage (%) | | | |
| T1 | 52 (49.1%) | 33 (44.6%) | 0.381 |
| T2 | 26 (24.4%) | 13 (17.6%) | |
| T3 | 10 (9.4%) | 9 (12.2%) | |
| T4 | 18 (17.0%) | 19 (25.7%) | |
| N Stage (%) | | | |
| N0 | 94 (88.7%) | 59 (79.7%) | 0.098 |
| N1 | 8 (7.5%) | 10 (13.5%) | |
| N2 | 3 (2.8%) | 3 (4.1%) | |
| N3 | 1 (0.9%) | 2 (2.7%) | |
| M Stage (%) | | | |
| M0 | 104 (97.2%) | 72 (97.3%) | 0.967 |
| M1 | 3 (2.8%) | 2 (2.7%) | |
| PT Stage (%) | | | |
| PT1a | 43 (39.4%) | 21 (28.4%) | 0.168 |
| PT1b | 9 (8.3%) | 12 (16.2%) | |
| PT2a | 24 (22.0%) | 10 (13.5%) | |
| PT2b | 2 (1.8%) | 3 (4.1%) | |
| PT3a | 6 (5.5%) | 4 (5.4%) | |
| PT3b | 4 (3.7%) | 5 (6.8%) | |
| PT4a | 4 (3.7%) | 6 (8.1%) | |
| PT4b | 14 (12.8%) | 13 (17.6%) | |
| Measurement | | | |
| Lesion Diameter (mm) - Mean (\pm SD) | 13.33 (\pm 8.88) | 13.35 (\pm 8.44) | 0.952 |
| Breslow Thickness (mm) - Mean (\pm SD) | 2.3 (\pm 4.1) | 3.1 (\pm 3.7) | 0.205 |
| Clark's Level (%) | | | |
| I | 0 (0%) | 0 (0%) | <0.01 |
| II | 12 (12.2%) | 0 (0%) | |
| III | 24 (24.5%) | 22 (31.0%) | |
| IV | 57 (58.2%) | 39 (54.9%) | |
| V | 5 (5.1%) | 10 (14.1%) | |

Methods

This was a single-centre retrospective matched cohort study. All patients diagnosed with cutaneous melanoma or squamous cell carcinoma between April and October 2020 were included and compared to those diagnosed in the same time frame in 2019. Disease specific outcomes included Breslow thickness, Clark's level, pT and TNM staging at presentation. Service outcomes included referral source and time to referral, diagnosis, and treatment. Data analysis techniques are described in supplement 1.

Results

Malignant melanoma (MM)

There was a 32.1% overall reduction in MM diagnoses in 2020 compared to 2019 (74 vs 109). A summary of results is shown in [Table 1](#).

Time from referral to clinic review was not significantly different between the two cohorts. Time from clinic review to biopsy was significantly shorter in 2020 (17.4 days vs 27.1 days, $p = 0.03$), as was time from MDT discussion to subsequent treatment (35.2 days vs 47.3 days, $p < 0.01$). Breslow

Table 2 Squamous cell carcinoma results summary.

| Demographic | 2019 (n = 274) | 2020 (n = 198) | P = |
|---|----------------------|----------------------|--------|
| Age (\pm SD) | 80.0 (\pm 9.9) | 78.8 (\pm 11.2) | 0.234 |
| Gender | | | |
| Female (%) | 78 (28%) | 61 (30%) | 0.498 |
| Male (%) | 204 (72%) | 139 (70%) | |
| Stage (%) | | | |
| T1 | 112 (40.9%) | 137 (69.2%) | <0.001 |
| T2 | 154 (56.2%) | 31 (15.7%) | |
| T3 | 8 (2.9%) | 30 (15.2%) | |
| T4 | 0 | 0 | |
| N0 | 274 (100%) | 195 (98%) | 0.026 |
| N1 | 0 | 3 (1.5%) | |
| N2 | 0 | 1 (0.5%) | |
| M0 | 274 (100%) | 195 (98%) | 0.03 |
| M1 | 0 | 4 (2%) | |
| Measurement | | | |
| Lesion Diameter (mm) - Mean (\pm SD) | 17.37 (\pm 11.42) | 16.49 (\pm 10.33) | 0.413 |
| Complete Excision (%) | 95.8% | 94.4% | 0.924 |

thickness, TNM and pT staging trended towards an increase in 2020, however none of these achieved statistical significance. There was a significant increase in Clark's level in 2020 ($p < 0.01$).

Squamous cell carcinoma (SCC)

There was an overall reduction in SCC diagnoses of 27.7% in 2020 (198 vs 274). A summary of results is shown in Table 2.

Time from referral to clinic review was equivocal. There was no significant difference in time from clinic to first procedure (37.29 days vs 35.09 days, $p = 0.562$). Time from procedure to MDT discussion was significantly shorter in 2020 (21.60 days vs 26.50 days, $p < 0.0001$). There was a significant increase in MDT recommendations for further treatment in 2020 (19.5% vs 16.0%, $p = 0.034$). There was a significant increase in tumour, nodal, and metastatic stage at presentation in 2020 when compared to 2019.

In 2020, the proportion of diagnoses originating from primary care was significantly increased (76.5% vs 67.4% $p = 0.049$) and new lesions identified during secondary care follow up decreased (18.0% vs 27.7%). Routine GP referrals were similar across both groups (5.5% vs 5%).

Discussion

The findings of this study demonstrate both successes and concerns in the management of skin cancer during the pandemic. Evidence demonstrates that clinic wait times have reached record levels,⁴ and while the initial expectation is that this would slow progression through the cancer care pathway, this study demonstrates evidence to the contrary. During the pandemic there was no increase in time between GP referral and specialist clinic review for patients with suspected skin cancer, and once within the hospital pathway patients received accelerated care. This may be due

to an increased focus on higher risk cancers. A reduction in histological samples due to reduced theatre workload may have also reduced the wait time for samples to be analysed, thus decreasing time between surgery and MDT. Additionally, the implementation of "hot" clinics with same day excisions likely further reduced wait times.

Fewer patients were seen overall in the 2020 cohort, potentially reducing the strain on the service, and shortening wait times. This is reflected by a reduction in GP fast track referrals during the pandemic, estimated to be as high as 60% nationally,⁵ with a more modest reduction of 19.5% seen in this study. A reduction in primary care referrals suggests the existence of a cohort of patients who have not yet presented to general practice.

This study found a 53.8% reduction in new lesions diagnosed through secondary care follow up. A significant reduction in SCCs identified during follow up appointments demonstrates a possible explanation for part of this missing cohort of patients, with 'routine' follow-up cancellations likely leading to missed diagnoses. This same effect was not seen with MM, which may be due to clinical prioritisation, a younger cohort and lower risk of second primary lesions.

This study shows some evidence that patients are presenting at a later stage of disease. MMs demonstrated an increased Clark's level during the pandemic, with Breslow thickness trending towards an increase. The trend in SCC is more concerning, with significant increases in tumour, nodal, and metastatic stage at presentation. Treatment of metastatic SCC can involve additional surgery, oncology input, and frequent follow up. This, combined with the aforementioned missing cohort of patients, means that the impact of COVID19 on skin cancer services is ongoing, as once standard practice is restored, the service is likely to be faced with an increased patient load, requiring more invasive, time-consuming and costly treatment. We therefore suggest that it would be valuable to continue multi-centre prospective data collection to assist in resource planning.

Ethical approval

Approval for retrospective data collection obtained via local audit department

Funding

None

Declaration of Competing Interest

None

Supplementary materials

Supplementary material associated with this article can be found, in the online version, at doi:[10.1016/j.bjps.2022.06.062](https://doi.org/10.1016/j.bjps.2022.06.062).

References

1. Collaborative C. Elective surgery cancellations due to the COVID-19 pandemic: global predictive modelling to inform surgical recovery plans. *Br J Surg* 2020;107(11):1440-9 [published Online First: 20200613]. doi:[10.1002/bjs.11746](https://doi.org/10.1002/bjs.11746).
2. Capitelli-McMahon H, Hurley A, Pinder R, et al. Characterising non-melanoma skin cancer undergoing surgical management during the COVID-19 pandemic. *J Plast, Reconstruct Aesthet Surg* 2020 [published Online First: 31 Oct 2020]. doi:[10.1016/j.bjps.2020.10.042](https://doi.org/10.1016/j.bjps.2020.10.042).
3. Nolan GS, Dunne JA, Kiely AL, et al. The effect of the COVID-19 pandemic on skin cancer surgery in the United Kingdom: a national, multi-centre, prospective cohort study and survey of Plastic Surgeons. *BJS (Br J Surg)* 2020 n/a(n/a). doi:[10.1002/bjs.12047](https://doi.org/10.1002/bjs.12047).
4. Griffin S. Covid-19: waiting times in England reach record highs. *Bmj* 2020;370:m3557 [published Online First: 20200911]. doi:[10.1136/bmj.m3557](https://doi.org/10.1136/bmj.m3557).
5. Mahase E. Covid-19: urgent cancer referrals fall by 60%, showing "brutal" impact of pandemic. *Bmj* 2020;369:m2386 [published Online First: 20200612]. doi:[10.1136/bmj.m2386](https://doi.org/10.1136/bmj.m2386).

Adam McClean*, Paolo Matteucci
Department of Plastic and Reconstructive Surgery, Hull
University Teaching Hospitals NHS Trust, Hull, United
Kingdom

Joshua Totty
Department of Plastic and Reconstructive Surgery, Hull
University Teaching Hospitals NHS Trust, Hull, United
Kingdom
Centre for Clinical Sciences, Hull York Medical School,
Hull, United Kingdom

*Corresponding author.

E-mail address: adam.mcclean1@nhs.net (A. McClean)

© 2022 British Association of Plastic, Reconstructive and Aesthetic Surgeons. Published by Elsevier Ltd. All rights reserved.

<https://doi.org/10.1016/j.bjps.2022.06.062>

Interlocking pectoralis major advancement and turnover flaps for sternal wound reconstruction: A combined approach for complex wounds



Dear Sir,

Introduction

Large sternal wounds in patients with complex comorbidities, infections, and multiple prior surgeries require the recruitment of healthy vascularized tissue to the region for proper wound coverage. Options for sternal reconstruction typically include the pectoralis major, omentum, rectus abdominis, or a combination of flaps. Versatility, proximity, and clearly delineated perfusion patterns make the pectoralis major an effective choice in most scenarios.^{1,2} Combining pectoralis advancement and turnover techniques unilaterally has been shown to provide adequate wound coverage while limiting morbidity when tissue requirements for the wound are less.³ The use of two interlocking pectoralis flap types described below - an advancement flap on one side and split turnover on the contralateral side - provides a greater amount of adequate healthy tissue bulk for total wound coverage and dead space obliteration in larger, deeper wounds. We present and compare patient outcomes of this technique to bilateral pectoralis advancement flaps from a single surgeon in a tertiary academic center.

Methods

A retrospective review was performed on patients who underwent sternal wound reconstruction between 2001 and 2018. Patients undergoing bilateral pectoralis advancement (BPA) or interlocking pectoralis advancement plus turnover (IPT) flaps were eligible for inclusion. Pectoralis advancement consisted of elevation of the pectoralis major muscle off the underlying chest wall with advancement medially. In the BPA technique, bilateral muscle flaps were secured to each other.

The MGB Institution Review Board (IRB) approved all study procedures and materials. Data were analyzed with STATA Version 13.0 (StataCorp, College Station, Texas). A *p*-value of less than 0.05 was considered statistically significant.

Abbreviations: BCC, Basal Cell Carcinoma.

Surgical technique: interlocking advancement turnover technique (IPT)

The advancement flap is elevated as described above with the addition of standard elevation of the skin flap from the muscle completely. Division of the insertion is done when needed for greater mobilization and flap reach. For the turnover flap, the pectoralis major is separated from the overlying skin flap completely and divided from its insertion on the humerus. The cephalic vein is carefully identified and protected. The thoracoacromial vessels are ligated and divided, and the turnover flap is elevated medially to the level of the internal mammary perforators. The muscle is then split longitudinally between intercostal segments and inset to both the superior and inferior portions of the sternal wound and to the contralateral advancement flap. The advancement flap fills in the middle sternal defect and interdigitates with the separated portions of the turnover flap (Figure 1).

Results

Thirty-nine patients met inclusion criteria (Table 1). Successful definitive sternal wound reconstruction, defined as achievement of wound coverage without the need for secondary reconstruction, was achieved in all patients in the IPT cohort and nineteen patients (95%) in the BPA cohort. Complications were categorized as major if they required return to the operating room and minor if managed conservatively.

Three patients in the BPA cohort (15%) and three patients in the IPT cohort (16%) experienced a major complication ($p=0.95$). All major complications in the interlocking cohort were hematomas and occurred within two postoperative days. Major complications in the BPA cohort included

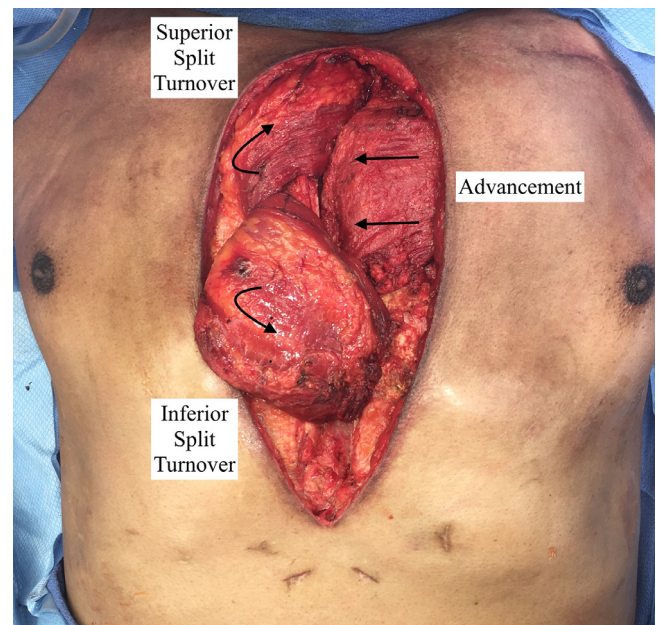


Fig. 1 Interlocking pectoralis major advancement plus turnover (IPT) flaps for sternal wound reconstruction demonstrating interlocking advancement and split turnover flaps adequately fill defect prior to skin closure.

one infection requiring re-debridement followed by rectus abdominis myocutaneous flap on postoperative day 45, an infection requiring additional debridement of the sternum and re-advancement of the flaps, and one hematoma. There was one mortality within 30 days postoperatively due to complications from shock liver and a dysrhythmia in the IPT group.

Table 1 Patient demographics, wound characteristics, and postoperative complications.

| | Interlocking Advancement plus Turnover (IPT) ($n=19$) | Bilateral Advancement (BPA) ($n=20$) | <i>P</i> -value |
|-------------------------------------|---|--|-----------------|
| Female, n (%) | 7 (37) | 7 (35) | 0.90 |
| Age, mean (SD) | 64 (10) | 61 (12) | 0.42 |
| BMI, mean (SD) | 33 (6) | 32 (8) | 0.79 |
| Tobacco use, n (%) | 5 (26) | 7 (35) | 0.48 |
| Diabetes mellitus, n (%) | 15 (79) | 11 (55) | 0.16 |
| Hypertension, n (%) | 16 (84) | 15 (75) | 0.41 |
| Preoperative anticoagulation, n (%) | 7 (37) | 8 (40) | 1.0 |
| Preoperative Wound Characteristics | | | |
| Sternal nonunion, n (%) | 15 (79) | 14 (70) | 0.52 |
| Wound Dehiscence, n (%) | 15 (79) | 8 (40) | 0.02* |
| Infection, n (%) | 16 (84) | 12 (60) | 0.16 |
| Major complications, n (%) | 3 (16) | 3 (15) | 0.95 |
| Infection | 0 | 2 (10) | 0.16 |
| Hematoma | 3 (16) | 1 (5) | 0.27 |
| Minor complications, n (%) | 7 (37) | 3 (15) | 0.16 |
| Wound Infection | 3 (16) | 1 (5) | 0.34 |
| Wound Dehiscence | 2 (11) | 1 (5) | 0.66 |
| Skin Necrosis | 1 (5) | 1 (5) | 1.0 |
| Hematoma | 1 (5) | 0 | 0.48 |

Discussion

Larger sternal wounds needing extensive obliteration of the deeper mediastinal space represent a reconstructive challenge that has led to the development of our technique consisting of an interlocking pectoralis major advancement flap with a contralateral pectoralis turnover flap (IPT). We compared the results from this cohort of patients to those undergoing bilateral pectoralis advancement flaps (BPA) and found similar outcomes between the two groups.

Successful sternal wound coverage was achieved in all patients who underwent IPT flaps even though preoperatively this group of patients had higher rates of sternal wound infections compared to the bilateral pectoralis advancement group ($p = 0.044$). Both cohorts had comparable major complication rates (15% bilateral advancement, 16% advancement plus turnover). All major complications in the advancement plus turnover group were due to hematoma and occurred within two days postoperatively, which is likely attributable to the greater degree of dissection with 37% undergoing bilateral pectoralis disinsertion in the IPT group. In contrast, pectoralis disinsertion was performed in only 15% of the BPA cohort: two bilateral cases and one unilateral case. In the BPA group, infection was the cause of two of the three major complications, likely attributable to less effective obliteration of dead space.

Drawbacks of the IPT technique include more extensive dissection required as well as potential cosmetic and functional deformities from disinsertion of the pectoralis muscles, which must be considered during the preoperative assessment. Future prospective studies will include a functional outcome analysis to further investigate differences in upper extremity deficits.

Conclusion

We present a novel technique for sternal wound reconstruction. Pectoralis advancement with interlocking contralateral turnover flaps (IPT) is an effective method particularly for larger and deeper sternal wounds.

Ethical approval

Ethical approval was obtained from the Mass General Brigham IRB prior to the study.

Funding

None.

Declaration of Competing Interest

The authors have no financial or personal conflicts/relationships of interest to disclose in relation to the content of this article.

References

1. Zahiri HR, Lumpkins K, Kelishadi S, et al. Pectoralis major turnover versus advancement technique for sternal wound reconstruction. *Ann Plast Surg* Feb 2013;70(2):211-15. doi:10.1097/SAP.0b013e3182367dc5.
2. Sears ED, Momoh AO, Chung KC, Lu YT, Zhong L, Waljee JF. A national study of the impact of delayed flap timing for treatment of patients with deep sternal wound infection. *Plast Reconstr Surg* Aug 2017;140(2):390-400. doi:10.1097/PRS.0000000000003514.
3. Brown RH, Sharabi SE, Kania KE, Hollier LH, Izaddoost SA. The split pectoralis flap: combining the benefits of pectoralis major advancement and turnover techniques in one flap. *Plast Reconstr Surg* Jun 2017;139(6):1474-7. doi:10.1097/PRS.0000000000003328.

Arman T. Serebrakian[#]

Ricardo Ortiz[#]

Ann Kogosov

Jonathan M. Winograd

*Division of Plastic and Reconstructive Surgery,
Massachusetts General Hospital, Harvard Medical School,
55 Fruit Street, Boston, MA 02114, United States*

[#]The first two authors contributed equally to this manuscript.

E-mail address: JWINOGRAD@mgh.harvard.edu (J.M. Winograd)

© 2022 British Association of Plastic, Reconstructive and Aesthetic Surgeons. Published by Elsevier Ltd. All rights reserved.

<https://doi.org/10.1016/j.bjps.2022.06.020>

Postoperative magnetic resonance imaging following lunate resection and vascularized os pisiform transfer in Kienböck's disease



Dear Sir,

Lunate resection and vascularized os pisiform transfer for advanced stages of Kienböck's disease were first reported by Saffar in 1982.¹ This procedure has been a useful approach for treating advanced stages of Kienböck's disease. Several patient-series studies have reported favorable long-term results such as pain relief and improvements in the range of motion. Conversely, radiographic changes in the transferred pisiform have also been reported. The cause of transferred pisiform deterioration remains unclear.² There are two main possible causes: weakened per-

fusion of pisiform or osteoarthritis owing to low congruity with surrounding bones.

Magnetic resonance imaging (MRI) is a useful examination procedure to investigate bone conditions. However, no studies to date have evaluated transferred pisiform using MRI after the procedure. Here, we aimed to investigate the condition of the pisiform bone and that of the bones around the pisiform after the procedure in patients who underwent postoperative MRI.

Ten patients from two institutes who underwent lunate resection and vascularized os pisiform transfer for Kienböck's disease between April 2011 and December 2020 were assessed retrospectively. Six patients (mean age, 45 years; range, 18-66 years) who underwent postoperative MRI were included. All six patients were classified as having Lichtman stage IIIb. The observation period after the surgery ranged from 1 to 7 years. All patients were operated by physicians certified by the Japanese Society of Hand Surgery. Each surgeon determined the surgical technique. The procedures for elevating the vascularized pisiform followed a technique previously described by our group, which follows the original description by Saffar.^{1,3} A longitudinal palmar incision of the forearm was made along the flexor carpi ulnaris (FCU) tendon and was extended distally in a zigzag fashion at the site of the wrist crease. The pisiform was dissected from the muscular attachment and the FCU tendon.

The vascular pedicle was separated from the dorsal branch of the ulnar nerve and the pisiform was elevated. The carpal tunnel was opened, and the flexor tendons and median nerve were retracted radially. The anterior capsule was opened in a U-shape.

The lunate was usually excised in small pieces and a posterior wall, consisting of the posterior horn of the lunate, the posterior ligaments, and the posterior capsule, must be preserved. Thereafter, the pisiform was inserted into the space created by the excision of the lunate. Temporary fixation of the grafted bone with K-wires was performed in three patients. After the operation, external fixation was applied in all patients for approximately 4 weeks.

Radiographs of the wrist in standard posteroanterior and lateral views were obtained at follow-up examination for all patients. The radiographic findings were evaluated for the stage of Kienböck's disease according to Lichtman's classification, changes in carpal height ratio and radio scaphoid angle, and sclerotic changes of the lunate, pisiform, or both.

The MRI examination timing was chosen based on each physician's preference. MRI was performed with a 1.5-T or 3.0-T field strength. We also checked the preoperative MRI findings to examine whether there were signal changes in the bones around the transferred pisiform.

At follow-up, the pain was noted to have decreased in five patients. Postoperative wrist flexion-extension ranged from 75° to 140°; the preoperative values ranged from 55° to 130°. The range of motion decreased in one patient, while the grip strength increased in all six patients postoperatively.

At follow-up, the Hand20 score (possible range, 0-100) varied (range, 0-47). In the current series, five out of six patients had a satisfactory rating according to Lichtman's criterion.

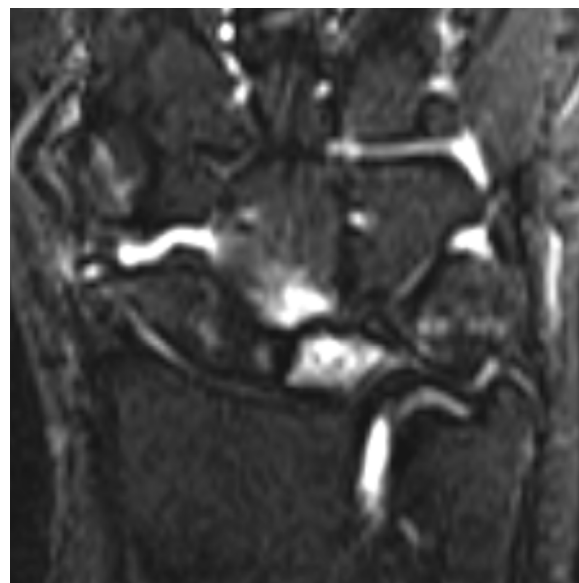


Figure 1 Postoperative magnetic resonance imaging of the right wrist in patient 3, a 67-year-old woman with stage IIIb Kienböck's disease.

Magnetic resonance imaging findings

The duration between surgery and postoperative MRI ranged from 5 months to 5 years (mean, 2 years and 1 month). In three patients, the preoperative MRI findings showed signal changes less severe than those after surgery in the carpal bones, capitate bone ($n = 2$), and scaphoid bone ($n = 1$). Bone marrow lesions in the transferred pisiform were found in five patients on postoperative MRI findings.

For the signal intensity of bones around the transferred pisiform, a signal change was observed in five patients. The signal change at the transferred pisiform side of the capitate bone was the greatest. Signal changes in the hamate and triquetral bones were found only at the transferred pisiform side in two patients each; those of the scaphoid and radius bones were found only at the transferred pisiform side in one patient each.

In one patient, the transferred pisiform was fractured and split in two in the coronal plane without signal changes in the bones around the pisiform (Table 1 and Figure 1)

We showed that five of six patients demonstrated bone marrow lesions in transferred pisiform, and the lesion was observed at the site facing the surrounding bone. A previous study, in which postoperative imaging evaluations were performed only with radiography examination, reported that deterioration was most likely caused by compromised perfusion of the pisiform.² It is difficult to discriminate between the deterioration caused by compromised perfusion and that caused by low congruity with the surrounding bones.⁴ The partial signal change of the pressure area could be attributed to an osteoarthritis change. Moreover, if there is a signal change in the opposite part of the bone around the transferred pisiform, bone marrow edema could be attributed to osteoarthritis by low congruity.⁵

Our postoperative evaluation using MRI revealed that postoperative osteoarthritic changes in the pisiform could

Table 1 Characteristics and radiography and MRI findings of patients with Kienböck's disease undergoing vascularized os pisiform transfer.

| Case No. | Age (years) | Sex | Lichtman's stage | Period since operation (y: years, m: months) | Duration between surgery and MRI (y: years, m: months) | MRI | | | | CHR | | | | RSA | | | | | |
|----------|-------------|-----|------------------|--|--|----------------------|-----------|--|---|---------------|---|---------------|------|---------------|---------------|---------------|---------------|---------------|---------------|
| | | | | | | Transferred pisiform | | Signal change of bones around the transferred pisiform | | Affected side | | Affected side | | Affected side | | Affected side | | Affected side | |
| | | | | | | T1WI | T2WI | STIR | C | H | T | S | R | Preoperative | Postoperative | Preoperative | Postoperative | Preoperative | Postoperative |
| 1 | 54 | M | IIIb | 2 y 5 m | 2 y 5 m | Iso | Iso | Low | - | - | - | - | 0.47 | 0.47 | 62 | 59 | - | - | |
| 2 | 37 | M | IIIb | 7 y 0 m | 5 y 0 m | Low | Iso | High | o | o | - | - | 0.39 | 0.38 | 82 | 85 | 0.44 | 76 | |
| 3 | 67 | F | IIIb | 6 y 1 m | 1 y 11 m | Low | Iso | High | o | o | o | - | 0.49 | 0.48 | 60 | 72 | 0.52 | 61 | |
| 4 | 44 | M | IIIb | 3 y 9 m | 1 y 9 m | Low | Iso | High | o | o | o | o | 0.46 | 0.47 | 67 | 64 | 0.47 | 56 | |
| 5 | 18 | M | IIIb | 1 y 7 m | 5 m | Low | Low & Iso | High | o | o | - | - | 0.47 | 0.48 | 63 | 70 | 0.53 | 48 | |
| 6 | 47 | F | IIIb | 1 y 0 m | 11 m | Iso | Iso | Slightly high | o | o | - | - | 0.51 | 0.45 | 52 | 58 | 0.53 | 37 | |

signal change confirmed both pre- and postoperatively; CHR, carpal height ratio; RSA, radio scaphoid angle; T1WI, T1-weighted image; T2WI, T2-weighted image; STIR, short T1 inversion recovery; C, capitata; H, hamate; T, triquetrum; S, scaphoid; R, radius.

be associated with low congruity with the surrounding bones than with compromised perfusion of the pisiform.

Our study had some limitations. The number of patients was small, the timing of MRI was not consistent, and the preoperative MRI findings of three patients showed slight signal changes in the bone around the lunate.

Computed tomography scan images, which are often suitable for evaluating skeletal and joint space changes and stenosis, could supplement these findings.

In summary, wrist osteoarthritis after the procedure could be attributed to the low congruity of the transferred pisiform and surrounding bones than the compromised perfusion of the pisiform

Declaration of Competing Interest

The authors disclose no conflicts of interest with regard to the present work.

Acknowledgments

None

Supplementary materials

Supplementary material associated with this article can be found, in the online version, at doi:[10.1016/j.bjps.2022.04.016](https://doi.org/10.1016/j.bjps.2022.04.016).

References

- Saffar P. Replacement of the semilunar bone by the pisiform. Description of a new technique for the treatment of Kienboeck's disease. *Ann Chir Main* 1982;1:276-9.
- Daecke W, Lorenz S, Wieloch P, Jung M, Martini AK. Lunate resection and vascularized os pisiform transfer in Kienböck's disease: an average of 10 years of follow-up study after Saffar's procedure. *J Hand Surg Am* 2005;30:677-84.
- Ishii H, Tatebe M, Hirata H. Distal radius joint surface reconstruction using a pedicle pisiform osteochondral transfer. *J Hand Surg Am* 2015;40:2075-80.
- Aaron RK, Dyke JP, Ciombor DM. et al. Perfusion abnormalities in subchondral bone associated with marrow edema, osteoarthritis, and avascular necrosis. *Ann NY Acad Sci* 2007;1117:124-37.
- McAlindon TE, Watt I, McCrae F, Goddard P, Dieppe PA. Magnetic resonance imaging in osteoarthritis of the knee: correlation with radiographic and scintigraphic findings. *Ann Rheum Dis* 1991;50:14-19.

Masaomi Saeki
 Michiro Yamamoto
 Masahiro Tatebe
 Shigeru Kurimoto
 Hidemasa Yoneda
 Hitoshi Hirata

Department of Hand Surgery, Nagoya University Graduate School of Medicine, 65 Tsurumai-cho, Showa-ku, Nagoya 466-8550, Japan

E-mail address: m.saeki@med.nagoya-u.ac.jp (M. Saeki)

Rotational osteo-onychocutaneous flap for central polydactyly of the foot: A novel technique for correction of the deformity



Dear Sir,

Surgeries for polydactyly of the foot require functional and cosmetic considerations according to the anomaly type. Patients with postaxial and preaxial polydactyly may have problems in wearing shoes because of their widened forefoot. Foot pain related to callosity and/or bunion is their main reason for surgery,¹ and re-approximation of transverse intermetatarsal ligament² and advancement skin flap³ are performed to correct the widened forefoot after excision of extra-digits. On the other hand, for the central polydactyly, cosmetic reason is more important. Both duplicated digits are deviated from the longitudinal axis of the ray.^{4,5} If simple excisions of the extra-digits are performed, the deformity in the main digits could remain.⁵ How to manage the residual deformity in the main digits remains an unsolved issue.⁵ To minimize this residual deformity of the remained digit, a novel surgical technique is introduced.

Between March 2010 and February 2020, six toes in six children of central polydactyly of the foot, were reconstructed by the novel rotational osteo-onychocutaneous (OOC) flap technique. The indications of this rotational OOC flap procedure were central polydactyly of the foot with the main digit having angulation and rotational deformity.

One of the authors (GHB) designed this technique, and performed all the operations (Figure 1). The main digit was decided either by radiographic ossification or by the apparent nail size - the one which was more ossified or had larger nail was determined as the main digit, and the other one as the extra-digit to be excised. A U-shaped skin incision was designed for the main digit, an elliptical incision was designed for the extra-digit, and an L-shaped ribbon-like skin flap was designed for later reconstruction of lateral side of the main digit. After excising the extra-digit, part of middle phalangeal head was removed to fit articular surface of the main digit. Then radial collateral ligament of the distal interphalangeal (DIP) joint was reconstructed using ligament periosteal flap preserved from the extra-digit. The L-shaped ribbon-like skin flap was raised carefully. Then, OOC flap was dissected to the DIP joint level using No. 15 blade. The flap contained nail, nail bed, extensor tendon, periosteum, and bone of dorsal part of the distal phalanx. The raised flap was rotated medially to fit the skin edge of the excised

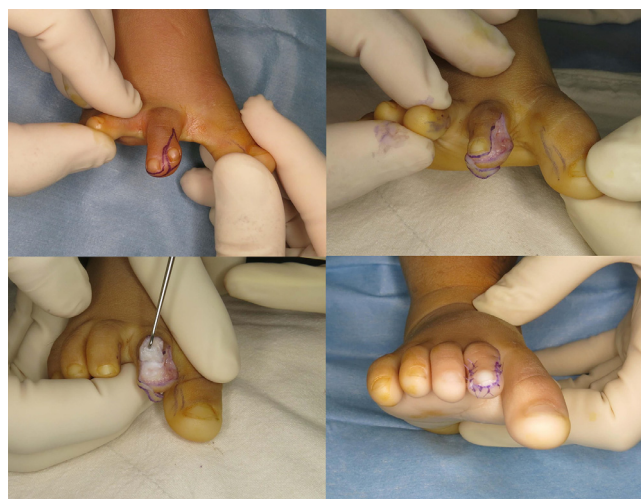

Figure 1 A U-shaped skin incision was designed for the main digit, an elliptical incision for the extra-digit, and an L-shaped ribbon-like skin flap for later reconstruction. After excision of the extra-digit and reconstruction of the radial collateral ligament of the distal interphalangeal joint, the L-shaped ribbon-like skin flap was raised carefully. Then osteo-onychocutaneous flap was dissected to the distal interphalangeal joint level, which was medially rotated. The defect on the lateral side of the flap was covered by the previously raised L-shaped flap.

extra-digit. The defect on the lateral side of the flap caused by medial rotation, was covered by the previously raised L-shaped flap. After tourniquet release, circulation of the flap was checked. The foot was immobilized using long leg cast for four weeks.

Six patients (five boys and one girl), whose mean age at the time of the surgery was 24 (range, 12-51) months, were retrospectively reviewed after institutional review board approval (IRB No. 2103-036-1202). Four patients were distal phalangeal type, and two middle phalangeal type. After average follow-up period of 42.0 (range, 6-79) months, all patients and their parents were satisfied with the cosmetic and functional results. The width of the nail was measured 80.5% of the normal side by average. The angulation deformity was improved from average 16.8 (range, 2.3-48.0) degrees to 4.2 (range, 0.5-11.2) degrees in distal phalangeal type, and from average 10.3 (range, 2.9-17.7) degrees to 5.9 (range, 2.0-9.8) degrees in middle phalangeal type. No nail plate deformity or groove developed. By radiographs, the residual angulation deformity was $<5^\circ$ in all patients (Figure 2). No acute complications such as partial necrosis of the flap was found.

The OOC flap, which comprised of nail, nail bed, extensor tendon, periosteum, and one millimeter thickness of bone of dorsal part of the distal phalanx with overlying skin was rotated with the hinge at DIP joint. Subsequent ossification resulted in no or minimal deformity in the main digit, and growth of the nail component was favorable as well. The ossification of distal and middle phalanges of toe central polydactyly is usually delayed and hypoplastic. This is a problem when performing osteotomy procedure, which might be one reason many patients with central polydactyly of the foot are not being surgically treated until the ossification is completed. To correct the 'eyes of a bird' deformity of the

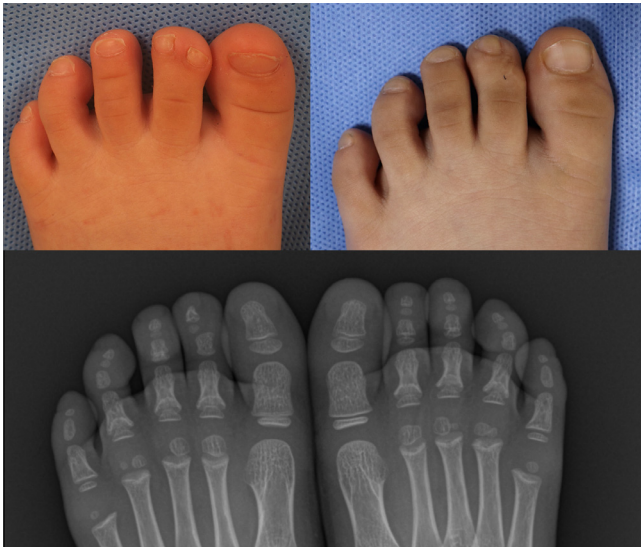

Figure 2 A patient (16 months of age) with central polydactyly of the toe presented with ‘eyes of a bird’ nail deformity. Seventy-nine months after rotational osteo-onychocutaneous flap procedure, the main digit showed no residual angulation nor rotational deformity. Radiographically, the ossification of distal phalanx was hypoplastic when compared to that of the contralateral side, but its deformity was not significant.

nail, we need derotational corrective osteotomy at the level of middle or proximal phalangeal level. Not like corrective osteotomy for the angulation deformity, the derotational corrective osteotomy may cause deterioration of flexion-extension axis of the toe. The axis of flexion-extension after surgery can be changed into oblique plane. Thus, we do not recommend the osteotomy to correct angulation and rotational deformity of central polydactyly of the foot.

In conclusion, our novel technique of rotational OOC flap procedure resulted in satisfactory outcome for patients with ‘eyes of a bird’ type toe nail deformity of central polydactyly of the foot. It corrected the angulation and rotational deformity of the toe nail of the main digit without causing any complications.

Declaration of Competing Interest

None

Funding

None

Ethical Approval

This study obtained ethical approval by [Seoul National University](#) (IRB No. 2103-036-1202)

References

1. Adler J, Springer K, Gentless J, et al. Concomitant syndactyly and polydactyly in a pediatric foot. *J Foot Ankle Surg* 1997;36:151-4.

2. Osborn EJ, Davids JR, Leffler LC, et al. Central polydactyly of the foot: surgical management with plantar and dorsal advancement flaps. *J Pediatr Orthop* 2014;34:346-51.
3. Akin S. An unusual and nonclassified central polydactyly of the foot. *Ann Plast Surg* 2004;53:86-8.
4. Watanabe H, Fujita S, Oka I. Polydactyly of the foot: an analysis of 265 cases and a morphological classification. *Plast Reconstr Surg* 1992;89:856-77.
5. Oshima J, Sasaki K, Sasaki M, Aihara Y, Nishijima A, Sekido M. Surgical management and postoperative evaluation based on morphological classification in central polydactyly of the foot. *J Plast Reconstr Aesthet Surg* 2021;74:2156-62.

Ji Sup Hwang
Jihyeung Kim
Kee Jeong Bae
Yohan Lee
Goo Hyun Baek

Department of Orthopaedic Surgery, Seoul National University Hospital, 101 Daehak-ro, Jongno-gu, Seoul 03080, Republic of Korea

*Corresponding author. Goo Hyun Baek, Department of Orthopaedic Surgery, Seoul National University Hospital, 101 Daehak-ro, Jongno-gu, Seoul 03080, Republic of Korea
E-mail address: ghbaek@snu.ac.kr (G.H. Baek)

© 2022 British Association of Plastic, Reconstructive and Aesthetic Surgeons. Published by Elsevier Ltd. All rights reserved.

<https://doi.org/10.1016/j.bjps.2022.06.031>

Free fillet lower leg flap with fenestration of the pelvis as prevention of vascular problem after hemipelvectomy



Dear Sir,

We read with great interest the article by L. Kreutz-Rodrigues et al. from Mayo Clinic: Reconstruction of complex hemipelvectomy defects: a 17-year single-institutional experience with lower extremity free and pedicled flaps¹. Congratulations to the authors for the excellent results and for including the largest published group of patients to date. We completely agree with the harvesting technique as described by the authors. We believe that the elevation of the flap with fibula is faster^{2,3} and in addition the fibula can be used to reconstruct the pelvic ring. Certainly, double-team surgery is standard for time-saving and minimising the ischaemia time. However, we consider the use of a pedicled flap with rotation of the pedicle in the pelvis or bending of the vascular pedicle around the edge of iliac crest too risky. It can cause venous thrombosis, as described by Kreutz-Rodrigues et al.¹. Previous studies have reported the occur-

Abbreviations: BCC, Basal Cell Carcinoma.

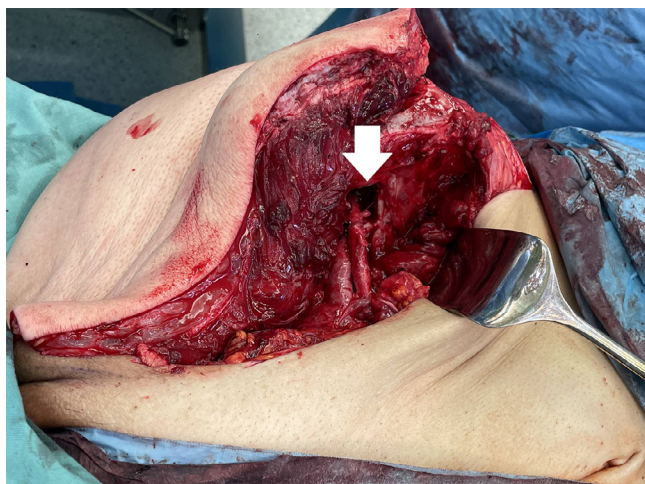


Figure 1 Anastomosis of the popliteal artery and vein with the external iliac artery and vein performed through a fenestrated window of the pelvis (white arrow).

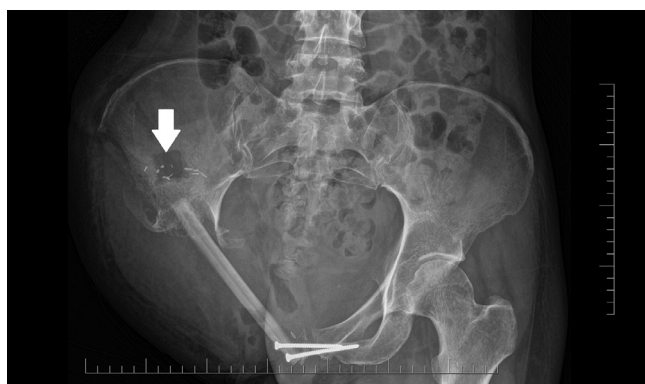

Figure 2 X-ray image of the bone fenestration performed in the area of the right iliac fossa (white arrow).

rence of venous thrombosis in three out of seven cases⁴. We propose a technique where the vascular pedicle can be inserted into the pelvis through a bone window, allowing for successful vascular anastomosis without any vascular complications.

Herein, a case of 34-year-old woman with advanced stage osteosarcoma of the right femur extending to the right hemipelvis is described. The fillet flap from the lower leg contained the distal part of the fibula, which was used to replace the missing portion of the right pelvis in the pubic region. The popliteal vessels of the flap were located on the side opposite to that of the recipient external iliac vessels. The flap could not be rotated, as its size and shape perfectly matched those of the defect. In fact, in case of rotation, the defect would have only been partially covered and it would have been difficult to utilise the fibula for the reconstruction of the pelvis. This issue was addressed by creating a 3 × 3 cm fenestration of the pelvis in the iliac fossa, through which the popliteal artery and vein were passed and an anastomosis was performed without creating tension (Figure 1). Fenestration was performed by drilling four holes in the corners of the planned bone window, which

were then connected with an oscillating saw. The edges of the defect were smoothed by rasping. Bleeding from cancellous bone was controlled by applying bone wax. Anastomosis was performed with single Prolene 6/0 sutures. The flap was completely re-perfused uneventfully. The surgery took 6 h and 30 min. No intra- and post-operative complications were encountered. The radiographic image after reconstruction can be seen in Figure 2.

By using our innovative technique, no marginal flap loss or venous thrombosis was observed.

The pelvic window allows performing a high-quality kink-free anastomosis, reducing the risk of vascular complications (especially venous thrombosis) without disrupting the static properties of the pelvis.

Ethics statement

All procedures performed in this study involving human participants were in accordance with ethical standards of the Institutional and National Research Committee, and with the Helsinki declaration and its later amendments, or comparable ethical standards.

Declaration of Competing Interest

The authors have no conflicts of interest to disclose.

Funding statement

The authors declare that this study has received no financial support.

References

1. Kreutz-Rodrigues L, Weissler JM, Moran SL, et al. Reconstruction of complex hemipelvectomy defects: A 17-year single institutional experience with lower extremity free and pedicled fillet flaps. *J Plast Reconstr Aesthetic Surg* 2020;73:242-54. doi:10.1016/j.bjps.2019.09.028.
2. Bibbo C, Newman AS, Lackman RD, Levin LS, Kovach SJ. A simplified approach to reconstruction of hemipelvectomy defects with lower extremity free fillet flaps to minimize ischemia time. *J Plast Reconstr Aesthetic Surg* 2015;68:1750-4. doi:10.1016/j.bjps.2015.07.006.
3. Faria JC, Aguiar S, Ferreira F de O, Lopes A. Fillet flap for reconstruction after hemipelvectomy: report of three cases. *J Plast Reconstr Aesthetic Surg* 2009;62:e110-11. doi:10.1016/j.bjps.2008.06.075.
4. Roulet S, Le Nail LR, Vaz G, et al. Free fillet lower leg flap for coverage after hemipelvectomy or hip disarticulation. *Orthop Traumatol Surg Res* 2019;105:47-54. doi:10.1016/j.otsr.2018.10.018.

Zdenek Dvorak
Department of Plastic and Aesthetic Surgery, St. Anne's
Faculty Hospital and Medical Faculty of Masaryk University
in Brno, Berkova 34, Brno, ZIP 612 00, Czech Republic

Tomas Tomas
Department of Orthopaedic Surgery, St. Anne's Faculty
Hospital and Medical Faculty of Masaryk University in
Brno, Pekarska 53, Brno, ZIP 656 91, Czech Republic

Martin Kubat
Department of Plastic and Aesthetic Surgery, St. Anne's
Faculty Hospital and Medical Faculty of Masaryk University
in Brno, Berkova 34, Brno, ZIP 612 00, Czech Republic

Vasileios Apostolopoulos
Department of Orthopaedic Surgery, St. Anne's Faculty
Hospital and Medical Faculty of Masaryk University in
Brno, Pekarska 53, Brno, ZIP 656 91, Czech Republic

Nzinga Tawa
Department of Orthopaedic and Trauma Surgery, Centre
Hospitalier du Chinonais, Saint-Benoît-la-Forêt, Route de
Tours, BP 224, Chinon Cedex, ZIP 37502, France
E-mail address: zdenek.dvorak@fnusa.cz (Z. Dvorak)

© 2022 British Association of Plastic, Reconstructive and Aesthetic Surgeons. Published by Elsevier Ltd. All rights reserved.

<https://doi.org/10.1016/j.bjps.2022.06.071>

Bemiparin vs enoxaparin in the prevention of thrombosis in microvascular head and neck reconstruction



Dear Sir,

Introduction

Microvascular flaps are the gold standard in head and neck reconstruction. The patients undergoing this type of surgery have an increased risk of thrombosis and the prophylaxis with Heparin is mandatory in the postoperative period. However, an excessive effect of the anticoagulant action can lead to local and systemic bleeding, and can negatively influence the outcome of the surgery.

Bemiparin is a second generation low molecular weight heparin (LMWH), with the anti-Xa: anti-IIa ratio greater than all heparins (8: 1). This characteristic reduce the risk of bleeding in the postoperative period compared to other drugs.¹

This study aims to compare the use of Bemiparin vs Enoxaparin in the immediate postoperative in patients undergoing microvascular head and neck reconstruction. We analyzed the incidencie local bleeding that could affect the

irrigation of the flap due to extravascular compression because of the hematoma.

Materials and methods

This is an observational study on a total group of 204 patients who underwent a microvascular flap for head and neck reconstruction in the Oral and Maxillofacial Surgery Department of the Ramón y Cajal Hospital (Madrid). A group of 67 patients was treated according to a protocol for venous thromboembolism prophylaxis (2016-2018). This group was compared with data collected retrospectively from a group of 137 patients treated with a previous protocol that used Enoxaparin as the main drug (2006-2015). All patients followed the same thromboprophylaxis protocol: first dose 6 hours after surgery and continue every 24 h until the 6th postoperative day (3.500 IU/24h in the Bemiparin group and 40mg/24h in Enoxaparin group). The patients were followed up until the 10th postoperative day.

The primary variable of safety was the incidence of post-operative bleeding events and the primary variable of effectiveness was the incidence of thrombotic complications in the microvascular anastomoses of the free flaps.

In the statistical analysis, the *p*-values were calculated with a chi2 for binary variables. Linear regression models were performed using as dependent variables major bleeding events and the flap loss rate.

Results

The flap success rate in patients treated with Bemiparin was 91% and 91,2% in the Enoxaparin group. (6 flap losses vs 12 flap losses). The difference between both groups was no statically significant ($p = 0.963$). [Tables 1](#) and [2](#).

Regarding major postoperative bleeding, only 1 event was recorded in the Bemiparin group, while 18 events were

Table 1 Cause of flap necrosis in Bemiparin group.

| Flap necrosis in Bemiparin group: 6 | Cause | Number |
|-------------------------------------|------------------------|--------|
| Revised flaps: 0 | | |
| No revised flaps: 6 | Wound infection | 4 |
| | Late arterial ischemia | 2 |

Table 2 Cause of flap necrosis in Bemiparin group.

| Flap necrosis in Enoxaparin group: 12 | Cause | Number |
|---------------------------------------|------------------------------|--------|
| Revised flaps : 5 | Vein congestion by hematoma | 2 |
| | Arterial thrombosis | 1 |
| | Vein thrombosis | 1 |
| | Arterial and vein thrombosis | 1 |
| No revised flaps: 7 | Wound infection | 4 |
| | Late arterial ischemia | 3 |

observed in patients treated with Enoxaparin, representing 1.5% versus 13.1%, being the difference statically significant between both groups ($p = 0.008$).

On the other hand, linear regression models showed that the only study variable related to presenting major bleeding was the type of thromboprophylactic treatment (Bemiparin vs Enoxaparin), $p = 0.007$.

Discussion

Microvascular flaps are the gold standard for head and neck reconstruction, because they provide good functional and aesthetic results, with a high success rate of free flaps. Flap loss rates are described between 1 and 10% in the literature.^{2,3} Flap loss rate in our study was 9% in Bemiparin group and 8,8% in Enoxaparin group, which is among the range described in the literature.

Bemiparin is the LMWH with the lowest molecular weight and the highest ratio of anti-Xa:anti-IIa activity (8:1). Therefore, it has a higher antithrombotic potency with a lower risk of bleeding.

Moreno González et al.⁴ compared the administration of Bemiparin 2.500 IU/day for 7 days in the postoperative period of abdominal surgery with low/moderate risk of thromboembolism, with another protocol administering 5.000 IU of UFH 2 times a day. They observed that Bemiparin was as effective as UFH in reducing the incidence of thromboembolism, and was more effective in preventing bleeding events. Abad Rico et al.⁵ report that Bemiparin is effective and well tolerated in thromboprophylaxis in surgery, having advantages over UFH, in particular, lower risk of bleeding and reduction in total costs per patient. Coinciding with these results, our study showed that patients treated with Bemiparin 3.500 IU/24h had fewer major bleeding events than those treated with Enoxaparin 40 mg/24h (1.5% vs 13.1%, $p = 0.008$).

Conclusions

Flap survival rate was not influenced by the type of antithrombotic treatment in our study. The patients treated with Bemiparin had a lower rate of major postoperative bleeding events than those treated with Enoxaparin.

Declaration of Competing Interest

None.

Author contributions

Kora Sagüillo: idea, contributions, data collection, drafting, statistics, editing, final approval; Francisco Perez-Flecha: idea, contributions, data collection; Fernando Almeida: idea, contributions, edits, final approval; Manuel Picón: idea, contributions; Julio Acero: idea, contributions, edits, final approval.

Funding source

Independent promotion project funded partially by Laboratorios Farmacéuticos Rovi S.A. through a winning scholarship of the III International Scholarship Competition for biomedical research with bemiparin.

*Approved by Clinical Research Ethics Committee of the Ramón y Cajal Hospital, Foundation for Biomedical Research of the Ramón y Cajal University Hospital (FIBIO-HRC)

References

1. Ciccone MM, Cortese F, Corbo F, et al. Bemiparin, an effective and safe low molecular weight heparin: a review. *Vascular Pharmacol* 2014;**62**(1):32-7.
2. Kruse ALD, Luebbbers HT, Grätz KW. Factors influencing survival of free-flap in reconstruction for cancer of the head and neck: a literature review: factors influencing survival of free-flap. *Microsurgery* 2010;**30**(3):242-8.
3. Wu C-C, Lin P-Y, Chew K-Y. Free tissue transfers in head and neck reconstruction: Complications, outcomes and strategies for management of flap failure: analysis of 2019 flaps in single institute: outcome results in head and neck reconstruction. *Microsurgery* 2014;**34**(5):339-44.
4. Moreno Gonzalez E, Fontcuberta J, de la Llama F. Prophylaxis of thromboembolic disease with RO-11 (ROVI), during abdominal surgery. EMRO1 (Grupo Fstudio Multicentrico RO-11). *Hepatogastroenterology* 1996;**43**(9):744-7.
5. Abad Rico JI, Lozano Sánchez FS, Rocha E. Clinical experience with bemiparin: drugs. 2010; 70:25-33.

Kora Sagüillo

Department of Oral and Maxillofacial Surgery, Villalba General Hospital, Madrid, Spain
Department of Oral and Maxillofacial Surgery, Rey Juan Carlos University Hospital, Madrid, Spain

Francisco Pérez-Flecha

Department of Oral and Maxillofacial Surgery, Fundación Jiménez Díaz University Hospital, Madrid, Spain

Fernando Almeida, Manuel Picón, Julio Acero

Department of Oral and Maxillofacial Surgery, Ramón y Cajal University Hospital, Madrid, Spain
University of Alcalá de Henares, Madrid, Spain
Ramón y Cajal Research Institute (IRYCIS) Spain
E-mail address: KORASAGUILLO@GMAIL.COM (K. Sagüillo)

© 2022 British Association of Plastic, Reconstructive and Aesthetic Surgeons. Published by Elsevier Ltd. All rights reserved.

<https://doi.org/10.1016/j.bjps.2022.06.041>

Le Fort I osteotomy by the precious technique contributes to the reduction of bleeding



Dear Sir,

Le Fort I osteotomy is one of the major surgical procedures for the management of dentofacial deformities. During Le Fort I osteotomy, pterygomaxillary disjunction is necessary to mobilize the maxilla. Disjunction with an osteotome directed into the pterygomaxillary fissure is the most common method for achieving vertical maxillary separation. However, separation with an osteotome is still controversial, and various complications, including haemorrhage, have been reported.^{1,2}

Precious et al. successfully performed maxillary down fractures and pterygomaxillary disjunction without an osteotome.³ However, there are few comparative studies of the Precious technique.⁴ Therefore, in this study, we compared the Precious technique with conventional pterygomaxillary disjunction, which uses an osteotome.

This study included patients treated simultaneously with Le Fort I osteotomy and sagittal split ramus osteotomy (SSRO). Patients with jaw deformities due to cleft lip and cleft palate or syndromic craniosynostosis were excluded.

We reviewed the records of 20 consecutive patients who underwent Le Fort I osteotomies between 2020 and 2021; of these patients, the first 10 underwent surgery with the conventional technique and the last 10 with the Precious technique.

From the gingival incision in both techniques, the periosteum was dissected, which exposed the anterior surface of the maxilla. The dissection was carried around the lateral maxillary buttress to the pterygomaxillary buttress and around the piriform aperture, including the nasal floor and nasal septum. The osteotomy was made with a reciprocating saw at the lateral maxillary buttress and directed to the ipsilateral piriform rim. The same osteotomy was performed on the contralateral side. A thin osteotome was used to complete the posterior osteotomies of the lateral and medial maxillary buttresses. A U-shaped osteotome was used to separate the nasal septum from the maxilla.

For cases that used the conventional technique, the pterygomaxillary junction was separated with curved osteotomes by placing a finger inside the mouth and feeling the hamulus. Once the osteotomies were completed, the down fracture was performed with digital pressure.

For cases that used the Precious technique, Tessier spreading forceps were inserted into the osteotomy where it crosses the anterior maxillary pillar. Using the spreading forceps, complete separation of the tuberosity and the pterygoid process of the sphenoid bone occurred.

All patients underwent SSRO according to the method described by Hunsuck⁵. All operations were performed by the same craniofacial surgeon. Furthermore, during the operations, systolic blood pressure was kept constant between 85 mmHg and 90 mmHg.

Table 1 Comparison between conventional and precious technique.

| | conventional technique | Precious technique | P value |
|----------------------|------------------------|--------------------|---------|
| Operative age (year) | 25.6 ± 5.24 | 28.0 ± 7.26 | 0.408 |
| Male | 5/10 | 3/10 | 0.650 |
| Operative time (min) | 228±24.5 | 237±40.1 | 0.557 |
| Bleeding (ml) | 468±297 | 132±64.2 | <0.05 |

Total operative time and the amount of bleeding in each group were evaluated. Significance was assessed using the Wilcoxon rank sum test. All calculations were performed using SPSS version 27.0 for Windows (IBM, Armonk, NY, USA), and *P* values less than 0.05 were considered to indicate statistical significance.

The results are presented in Table 1. The operative time of the Precious group ranged between 168 and 306 (mean, 237 ± 40.1) min. The operative time of the conventional group ranged between 195 and 277 (mean, 228 ± 24.5) min. There was no significant difference between the groups (*P* = 0.557).

The amount of blood loss in the Precious group ranged between 50 and 220 (mean, 132 ± 64.2) ml. The amount of blood loss in the conventional group ranged between 100 and 1015 (mean, 468 ± 297) ml. There was a significant difference between the groups (*P* < 0.05). However, there was no correlation between operative time and the amount of blood loss.

Severe complications after pterygomaxillary disjunction have been reported; thus, numerous studies have investigated ways to reduce these complications.^{1,2} Because these complications were thought to be caused by malpositioning of the osteotome or by accidental fractures during down fracture, various types of osteotomes were developed and ultrasonic bone curettes were occasionally used. The technique reported by Precious et al. was performed without pterygoid chisel,³ and although this technique has already been used successfully, no evidence of its usefulness has been published.⁴

In our study, there was no significant difference in operation time, but the amount of bleeding was smaller in the Precious group than in the conventional group. Thus, the risk of injury to vascular structures adjacent to the pterygoid plate might be minimized.

A limitation of this study was not compared not only maxilla, but maxilla and mandible. However, since the same mandibular osteotomy was performed in both groups, the difference in the amount of bleeding depends on the maxilla.

In conclusion, the Precious technique is useful for reducing the amount of bleeding. However, accidental fractures during maxillary down fractures can still occur with this technique.

Presentation at previous meetings

None.

Funding

No funding or grant support.

Ethical approval

This study was approved by the Institutional Research Ethics Board of Keio University Hospital (approval number, 20190287).

Declaration of Competing Interest

None declared.

References

1. Franz JK, Carola B, Gwen S, et al. Intra- and perioperative complications of Le Fort I osteotomy: a prospective evaluation of 1000 patients. *J Craniofac Surg* 2004;15:971-7.
2. Lanigan DT, Hey JH, West RA. Major vascular complications of orthognathic surgery: hemorrhage associated with Le Fort I osteotomies. *J Oral Maxillofac Surg* 1990;48:561-73.
3. Precious DS, Morrison A, Ricard D. Pterygomaxillary separation without the use of an osteotome. *J Oral Maxillofac Surg* 1991;49:98-9.
4. Breeze J, Vereia Linares C, Stockton P. Is an osteotome necessary for pterygomaxillary dysjunction or dysjunction through the tuberosity during Le Fort I osteotomy? A systematic review. *Br J Oral Maxillofac Surg* 2016;54:248-52.
5. Hunsuck EE. A modified intraoral sagittal splitting technic for correction of mandibular prognathism. *J Oral Surg* 1968;26:250-3.

Akira Kikuchi, Yoshiaki Sakamoto*, Kazuo Kishi
 Department of Plastic and Reconstructive Surgery, Keio
 University School of Medicine, 35 Shinanomachi,
 Shinjuku-ku, Tokyo 160-8582, Japan

*Corresponding author.

E-mail address: ysakamoto@z8.keio.jp (Y. Sakamoto)

© 2022 British Association of Plastic, Reconstructive and Aesthetic Surgeons. Published by Elsevier Ltd. All rights reserved.

<https://doi.org/10.1016/j.bjps.2022.06.015>

Los Deline copolyamide filler for breast and buttock augmentation. The position statement of the Italian Aesthetic Medicine Association (AMEI)



Dear Sir,

In esthetic medicine a recent and urgent alert has grown regarding the administration of a new filler called Los De-

line, used for great breast and buttock volume augmentation. Los Deline (Bio Trh, s.r.o., Czech Republic) is a hydrophilic gel that is composed of 98% sodium chloride solution (0.9%) and 2% copolyamide. It was first developed for facial contouring in 2005 with the name Aquafilling (Biomedica, spol, s.r.o., Czech Republic), whose name was changed in 2008. The reason of the growing alert relies on its composition, since copolyamide is a non-resorbable component when injected into human tissues. Indeed, copolyamide is poly(acrylamide-co-N,N'-methyl-ene-bisacrylamide), which has the same composition as polyacrylamide gel (PAAG) fillers. Its use is primarily related to breast augmentation. A comparison between copolyamide and PAAG was carried on with Nuclear Magnetic Resonance (NMR), showing that the copolyamide and PAAG shared the same characteristics.¹ For this reason, Los Deline, sharing the same properties of PAAG fillers, arises serious doubt on its safety, although provided with the European Conformity Mark (CE). In this regard, considering its composition, several alerts about the use of copolyamide were published so far. Although it is easy to inject and is natural looking, once a complication occurs, treatment is very difficult to manage.

In this scenario, we performed an overview of the literature about the use of copolyamide, addressing its safety and complications. The electronic databases ScienceDirect, MEDLINE, Scopus, Embase, the Cochrane Library, ClinicalTrials.gov, EU Clinical Trials Register and World Health Organization International Clinical Trials Registry were searched until 05 March 2022. The following keywords have been used: copolyamide OR aquafilling OR Los Deline. A manual search of the reference lists of the included studies and review articles was successively carried out in order to detect missed papers. Published (full-text studies and meeting abstracts) and unpublished studies or gray literature (i.e. for which only a registered protocol was available) were searched from the aforementioned electronic databases. The electronic search provided a total of 41 citations. We firstly screened the articles by title abstract. At the end, we included the following articles in our overview.

In 2017, Son et al. reported three cases of palpable lump on the left upper parasternal area, pain and hardness in the left lower quadrant of the abdomen, migration to both axillae, the subclavian triangles, and the intercostal space of the left parasternal area.² Moving forward, Ikizceli et al. in 2019 reported a case of a young woman complaining about breast pain. Interestingly, the breast sonography showed a cyst, measuring up to 25 mm containing hyperechogenic internal echoes, without any appreciable capsule between the glandular tissue and the pectoral muscle. The main importance aim, after pain complaint, is related to the diagnostic problems that may arise as the gel can mask breast lesions, including cancer.³

In the last two years, Namgoong et al. in 2020 reported 399 patients treated for filler-related complications in 4 years in a single institute. 146 of them necessitated the filler removal from breast or buttock. The most common complications reported in this group of patients were induration and masses (83.6%), pain (52.1%), firmness (24.7%), asymmetry (10.3%), migration (8.2%), mastitis (6.8%), dimpling (6.2%), fever (3.4%), and sepsis ($n = 1$). After surgical removal, there was no recurrence of infection.⁴ More recently, Nomoto et al. performed a retrospective cohort study including all the patients referring to a single hos-

Abbreviations: BCC, Basal Cell Carcinoma.

For AMEI (Associazione di Medicina Estetica Italiana), Via Caduti di Marcinelle, 7 - 20,134 Milan, Italy

pital in a time frame of three years. 29 women presented complaining breast deformity. Among them, eight had infections located in the site injections and mammary gland inflammation. Five complained indurations (single large/small lumps). In 4 cases, the filler had migrated outside of the breast, including to the back and also vulva.¹

Posing copolyamide under the spotlight highlighted different complications related to its injections. Furthermore, there are concerns regarding its toxicity and influence on the surrounding tissues. About this point, Chalcarz et al. in 2020 reported four cases of patients evaluated after copolyamide injection: interestingly, inflammation markers were found enhanced with statistically significant variations in the number of lymphocytes B (CD20) and macrophages (CD68), and differentiation of immunohistochemical reaction area for lymphocytes T (CD3) and lymphocytes B (CD20). This data provide evidence about the pro-inflammatory effect of such exogenous device.⁵

The pro-inflammatory effect of copolyamide and the side effects are still a clear signal for more efforts needed in order to assess the real safety of this product. We believe that its entry in the Italian market should be postponed until serious study and analysis are assessed and performed in order to evaluate its safety in the clearest way.

Declaration of Competing Interest

FV is Opinion Expert for Sinclair Pharma.

Funding

None.

Ethical approval

Not required.

References

1. Nomoto S, Hirakawa K, Ogawa R. Safety of copolyamide filler injection for breast augmentation. *Plast. Reconstr. Surg. Glob. Open* 2021;9(2):e3296 PMID: 33680632; PMCID: PMC7929552. doi:10.1097/GOX.0000000000003296.
2. Son MJ, Ko KH, Jung HK, Koh JE, Park AY. Complications and radiologic features of breast augmentation via injection of aquafilling Gel. *J. Ultrasound Med.* 2018;37(7):1835-9 Epub 2017 Dec 27. PMID: 29280175. doi:10.1002/jum.14527.
3. Ikizceli T, Cindemir E, Gulsen G, Bijan B. Imaging findings of aquafilling gel injection for breast augmentation. *Breast J.* 2020;26(2):278-80 Epub 2019 Nov 3. PMID: 31680345. doi:10.1111/tbj.13682.
4. Namgoong S, Kim HK, Hwang Y, Shin SH, You HJ, Kim DW, Kim A, Jung SP, Yoon ES. Clinical experience with treatment of aquafilling filler-associated complications: a retrospective study of 146 cases. *Aesthetic Plast. Surg.* 2020;44(6):1997-2007 Epub 2020 Sep 16. PMID: 32936330. doi:10.1007/s00266-020-01889-7.
5. Chalcarz M, Żurawski J. Injection of Aquafilling® for breast augmentation causes inflammatory responses independent of visible symptoms. *Aesthetic Plast. Surg.* Apr 2021;45(2):481-

90 Epub 2020 Sep 16. PMID: 32939601; PMCID: PMC8012309. doi:10.1007/s00266-020-01949-y.

Giovanni Buzzaccarini
AMEI (Associazione di Medicina Estetica Italiana), Via
Caduti di Marcinelle, 7, 20134 Milan, Italy
Gynaecologic and Obstetrics Clinic, Department of
Women's and Children's Health, University of Padua,
Padua, Italy

Antonio Simone Laganà
Unit of Gynecologic Oncology, ARNAS "Civico - Di Cristina -
Benfratelli", Department of Health Promotion, Mother and
Child Care, Internal Medicine and Medical Specialties
(PROMISE), University of Palermo, Palermo, Italy

Marco Borin
AMEI (Associazione di Medicina Estetica Italiana), Via
Caduti di Marcinelle, 7, 20134 Milan, Italy
U.O.C. Otorhinolaryngology, ASST Grande Ospedale
Metropolitano Niguarda Piazza Ospedale Maggiore, 3,
20162 Milano, Italy

Simona Vari, Giovanni Tulipano, Stefano Vertuè
AMEI (Associazione di Medicina Estetica Italiana), Via
Caduti di Marcinelle, 7, 20134 Milan, Italy

Marco Noventa
Gynaecologic and Obstetrics Clinic, Department of
Women's and Children's Health, University of Padua,
Padua, Italy

Maria Albini, Franco Vercesi
AMEI (Associazione di Medicina Estetica Italiana), Via
Caduti di Marcinelle, 7, 20134 Milan, Italy
E-mail address: giovanni.buzzaccarini@gmail.com (G.
Buzzaccarini)

© 2022 British Association of Plastic, Reconstructive and Aesthetic Surgeons. Published by Elsevier Ltd. All rights reserved.

<https://doi.org/10.1016/j.bjps.2022.06.047>

Utilizing a lower extremity vein graft for immediate lymphatic reconstruction



Dear Sir,

Introduction

Immediate lymphatic reconstruction (ILR) is a microsurgical technique to reduce the risk of breast cancer related

Abbreviations: BCC, Basal Cell Carcinoma.

Presented as an e-poster presentation at the American Society for Reconstructive Microsurgery 2022 Annual Meeting (Carlsbad, California)

lymphedema (BCRL) development after axillary lymph node dissection (ALND). Inadequate length of the axillary vein tributary as well as venous back-bleeding are two technical challenges that can lead to ILR procedures being aborted at a rate of approximately 25%.^{1,2} Unsuccessful ILR procedures leave patients with a greater risk of developing BCRL.³ Yamamoto et al.⁴ described their experience using a vein graft in lymphovenous anastomoses performed to treat lymphedema, however the use of vein grafts in preventative lymphovenous anastomoses has not yet been observed. Recently, our team began routinely harvesting a lower extremity vein graft (LEVG) for all ILR procedures. We describe the technical approach of an LEVG for ILR and evaluate the effects on aborted case rates and intraoperative time.

Methods

Retrospective review

A retrospective review of our lymphatic surgery database was conducted. We identified consecutive patients diagnosed with node-positive unilateral breast cancer who were taken to the operating room for attempted ILR immediately between September 2016 and November 2021. Demographics and intraoperative variables were analyzed descriptively.

Surgical technique

After induction, a 5-cm target vein with a diameter of 1–2 mm was identified by ultrasound in the medial lower leg. Branching was identified to increase the likelihood of valve presence.⁵ During the ALND, the graft was harvested by the reconstructive team. The vein was clipped distally and divided to test for valve competency. The proximal vein was then clipped and divided. The graft was flushed with heparinized saline and was wrapped in a moist gauze.

The native axillary vein tributary was preserved by the oncologic surgeon.^{1,5} Following the ALND, the proximal LEVG was anastomosed end-to-end to the distal end of the axillary vein tributary. The orientation of the vein was maintained in order to appropriately position the valve for the prevention of venous backflow into the LEVG (Fig. 1).

The distal part of the LEVG was utilized for the lymphovenous bypass using the intussusception technique.⁵ Anastomotic patency of the bypass was confirmed using fluorescein isothiocyanate. The incision was closed in a standard manner. Postoperatively, ILR patients were enrolled in our lymphedema surveillance protocol.³

Results

Two hundred and forty-seven patients with nodal-positive unilateral breast cancer were taken to the OR for attempted ILR in the past 5 years. The average patient age was 54 years. 205 consecutive patients underwent ILR without an LEVG and 42 consecutive patients underwent ILR with an LEVG.

Prior to the use of an LEVG ($n = 205$), our abort rate was 14%. Since routinely utilizing an LEVG with ILR ($n = 42$), we have not aborted a single case (Fig. 2). Prior to the use of an LEVG, the average intraoperative time for ILR was 81 min (range = 29 min to 4 h and 23 min). Following the routine implementation of an LEVG with ILR, our average intraoperative time was 71 min (range = 37 min to 2 h and 2 min). Anastomotic patency was confirmed in all patients by visualization of fluorescein in the vein. One patient developed a partial dehiscence of their graft donor site, requiring revision under local anesthesia.

Discussion

In this technical overview, we introduce and describe the use of an LEVG for ILR. Since the routine implementation of an LEVG, no ILR procedures have been aborted. There are two reasons for this. First, the added length of the vein graft reduces the reliance on the oncologic surgeon to identify and preserve an adequate venous conduit. Second, the LEVG increases the likelihood of valve presence, thereby reducing the potential for venous back-bleeding by promoting unidirectional flow.^{4,5}

As lymphatic care becomes centralized, we have begun to serve as a major regional center in lymphatic care, and many of our patients travel long distances for treatment. In doing so, patients make both emotional and financial investments in their care. Therefore, using an LEVG to reduce

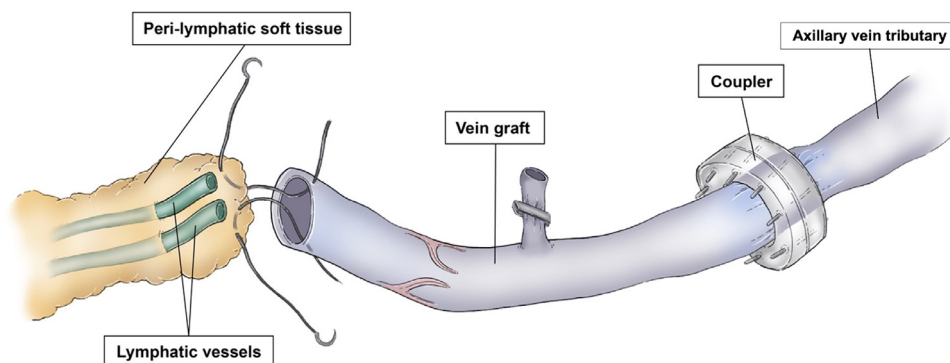


Fig. 1 Illustration of ILR utilizing a lower extremity vein graft (LEVG). The axillary vein tributary is anastomosed to the vein graft using an anastomotic coupling device (Synovis MCA Inc., Birmingham, AL, USA). The orientation of the LEVG is maintained, with the proximal LEVG anastomosed to the distal axillary vein tributary. By doing so, the valve orientation is maintained.

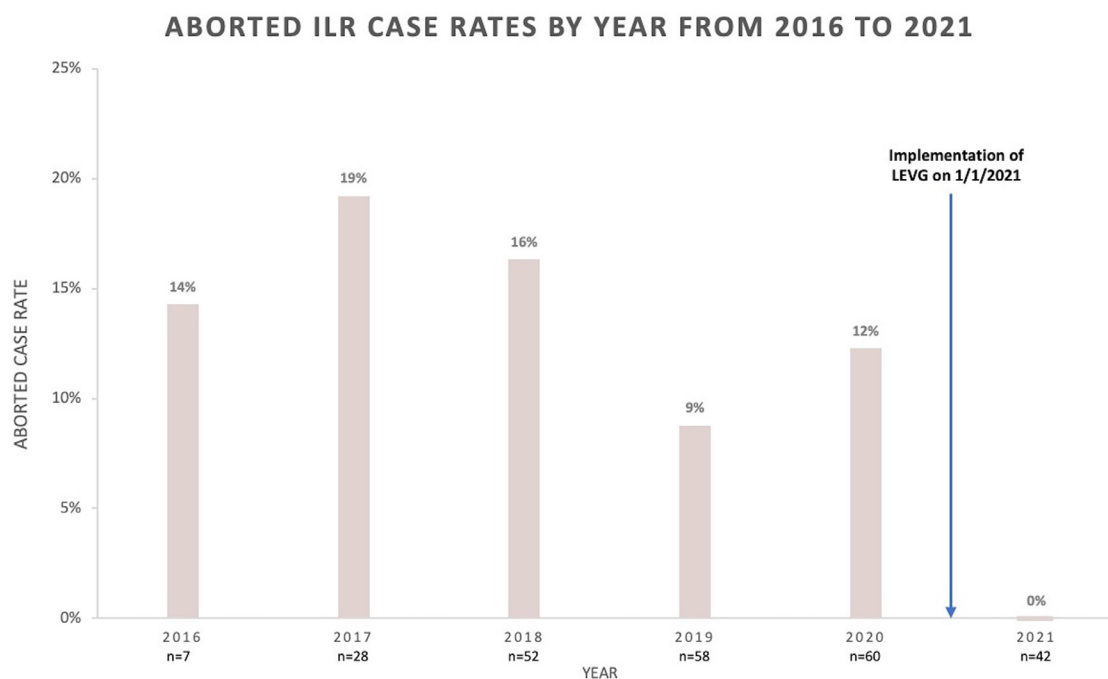


Fig. 2 Institutional Immediate Lymphatic Reconstruction Aborted Case Rates Before and After Routine Implementation of Lower Extremity Vein Graft on January 1, 2021.

aborted ILR procedures is of significant benefit to patients. Additionally, the incidence of donor site complication was minimal.

Despite an LEVG requiring one additional anastomosis to connect the graft to the axillary vein tributary, ILR intraoperative time was not affected. The LEVG was harvested during the oncologic surgery, which maximized efficiency without changing workflow. The added length of the LEVG gave the reconstructive surgeon more flexibility in choosing the optimal lymphatic channel(s) to bypass while simultaneously reducing the technical demands of the bypass itself.

In this technical contribution, we describe our early experience performing ILR utilizing an LEVG. This is a relatively straight-forward technique and allows for reduction in aborted case rates without increasing intraoperative time, however, the clinical value and the impact of this technique on the development of BCRL has yet to be determined.

Declaration of Competing Interest

None to disclose

Funding

Rosie Friedman is supported by the 2022 JOBST Lymphatic Research Grant awarded by the Boston Lymphatic Symposium, Inc.

Statement of ethical approval

Formal and documented ethical approval was obtained by the Beth Israel Deaconess Medical Center Institutional Review Board under Protocol #2021P000540.

Supplementary materials

Supplementary material associated with this article can be found, in the online version, at doi:[10.1016/j.bjps.2022.06.076](https://doi.org/10.1016/j.bjps.2022.06.076).

References

- Mele A, Fan B, Pardo J, et al. Axillary lymph node dissection in the era of immediate lymphatic reconstruction: considerations for the breast surgeon. *J Surg Oncol* 2021;123(4):842-5. doi:[10.1002/jso.26355](https://doi.org/10.1002/jso.26355).
- Feldman S, Bansil H, Ascherman J, et al. Single Institution Experience with Lymphatic Microsurgical Preventive Healing Approach (LYMPHA) for the Primary Prevention of Lymphedema. *Ann Surg Oncol* 2015;22(10):3296-301. doi:[10.1245/s10434-015-4721-y](https://doi.org/10.1245/s10434-015-4721-y).
- Johnson AR, Fleishman A, Granoff MD, et al. Evaluating the Impact of Immediate Lymphatic Reconstruction for the Surgical Prevention of Lymphedema. *Plast Reconstr Surg* 2021 Published online. 373E-381E. doi:[10.1097/PRS.0000000000007636](https://doi.org/10.1097/PRS.0000000000007636).
- Yamamoto T, Yoshimatsu H, Yamamoto N, Yokoyama A, Numahata T, Koshima I. Multisite Lymphaticovenular Anastomosis Using Vein Graft for Uterine Cancer-Related Lymphedema after Pelvic Lymphadenectomy. *Vasc Endovascular Surg* 2015;49(7):195-200. doi:[10.1177/1538574415614402](https://doi.org/10.1177/1538574415614402).
- Coriddi M, Mehrara B, Skoracki R, Singhal D, Dayan JH. Immediate Lymphatic Reconstruction: technical Points and Literature Review. *Plast Reconstruct Surg- Glob Open* 2020 Published online. doi:[10.1097/GOX.0000000000003431](https://doi.org/10.1097/GOX.0000000000003431).

Rosie Friedman, Valeria P. Bustos, Tanya Postian,
Jaime Pardo, Ryoko Hamaguchi, Bernard T. Lee
*Division of Plastic and Reconstructive Surgery, Beth Israel
Deaconess Medical Center, Harvard Medical School,
Boston, MA, USA*

Ted A. James
*Department of Surgery, Beth Israel Deaconess Medical
 Center, Harvard Medical School, Boston, MA, USA*

Dhruv Singhal*
*Division of Plastic and Reconstructive Surgery, Beth Israel
 Deaconess Medical Center, Harvard Medical School,
 Boston, MA, USA*

*Corresponding author at: Division of Plastic and
 Reconstructive Surgery, Beth Israel Deaconess Medical
 Center, Harvard Medical School, 110 Francis St, Suite 5A,
 Boston, MA, 02215, USA.
 E-mail address: dsinghal@bidmc.harvard.edu (D. Singhal)

© 2022 British Association of Plastic, Reconstructive and Aesthetic
 Surgeons. Published by Elsevier Ltd. All rights reserved.

<https://doi.org/10.1016/j.bjps.2022.06.076>

Congenital muscular torticollis in ‘late-comers’: A proposal for grading of severity and outcome scales



Dear Sir,

Congenital muscular torticollis, a disorder of the sternomastoid muscle, presents as a unilateral deformity of the neck leading to inclination of the head towards the affected side. Often, patients present late in our country (‘late-comers’) due to benign nature of disease, non-availability and long distances to specialised medical facilities, poverty and ignorance. The standard treatment for neglected torticollis is surgical release. However, there is no universally acceptable system to assess severity of the disease and to grade the surgical outcomes, especially in ‘late-comers’.

Lee et al. described a scoring system which considered function and cosmesis for pre- and post-operative assessments.¹ While 0-3 points were scored for 3 functional and 3 cosmetic criteria, only functional criteria were used for pre-operative assessment. Time at which the final outcome score should be assessed was not defined. The assessment of facial asymmetry, head tilt and neck movement were based on clinical observation alone which predispose to massive observer bias. The cosmetic criteria of scar, loss of column and lateral bands were also scored as per the observer’s esthetic sense. Lack of objectivity in criteria makes them unsuitable for comparison of outcomes of different management techniques employed by surgeons who may have different perceptions and standards for assessment.

The presence of lateral band post-operatively indicates incomplete release during surgery. Loss of column has

not been uniformly noted either with unipolar or bipolar releases,^{1,2} while too much importance was attached to its cosmetic significance.¹ Significantly, the facial asymmetry in ‘late-comers’ does not get corrected despite complete surgical release. Non-improvement in facial asymmetry downgrades an otherwise excellent surgical outcome and a modified Lee scoring system was proposed which excluded assessment of facial asymmetry.^{2,3} However, the variations in parameters, element of subjectivity and observer bias still persisted.^{2,3} In our opinion, it is not prudent to include such parameters in assessment of ‘late-comers’.

Another scoring system used for infants who underwent manual stretching or surgical treatment assessed rotational deficit, side flexion deficits, craniofacial asymmetry, residual bands, head tilt and assessment by parents.⁴ While rotational and side flexion deficits were measured in degrees, all other criteria were subjective. This scoring system did not grade the severity of torticollis and was also not applicable for older patients.

A meta-analysis on effectiveness of surgical treatment for neglected congenital muscular torticollis noted that multiple scoring systems had been used which are at variance with each other.⁵ Appropriately, their conclusion stated that a standardised scoring system needs to be developed for comparison of pre- and post-operative results for future research.

Literature search did not reveal any system to grade the severity of torticollis in ‘late-comers’. The persistent inconsistencies prompted us to formulate a new scoring system which could rectify these ‘errors’, objectively grade the severity of the disease, quantify the surgical outcomes and help to establish uniformity while comparing outcomes at different centres.

We developed Lok Nayak Hospital Severity Grading Scale (LNHSGS) which objectively records all the parameters pre-operatively (Table 1). It incorporates the functional components viz. head tilt, axial rotation and lateral flexion of neck in degrees. Normal range of axial rotation is a mean of 70°, while mean for lateral flexion of neck is 45° on each side. Digital pictures and angular measurements are taken using computer software (IC Measure/Image Meter/Image J, etc.).

Further, it is vital that the outcomes measured are relative to the severity of the deformity. A patient with greater initial deformity may not have a similar outcome as that of a mild torticollis. We also developed Lok Nayak Hospital Outcome Scoring Scale (LNHOSS) wherein the outcomes are assessed at 6 months post-operatively. By that time the neck is soft and supple, scars have matured, and massage and use of cervical collar are discontinued. LNHOSS evaluates the functional parameters of head tilt, rotational deficit and lateral flexion deficit on a 4-point scale objectively (Table 2). The deficit for lateral neck flexion is calculated from the mean values for contralateral side, while axial rotation deficit is calculated from the mean value for the ipsilateral side. The improvements in head tilt and restriction in rotational and lateral flexion deformity are estimated in percentage [(Initial deficit – Residual deficit)/Initial deficit × 100].

The scar characteristics are recorded using Vancouver Scar Scale (VSS). A patient satisfaction score on a 4-point scale is additionally used to subjectively quantify the functional and esthetic outcomes. The patients grade the out-

Table 1 Lok Nayak Hospital Severity Grading Scale (LNHS GS) for torticollis in 'late-comers'.

| Functional components | Points | | |
|---|--------------------|-------|-----|
| | 1 | 2 | 3 |
| Head tilt (degrees) | <5 | 5-15 | >15 |
| Deficit in range of axial rotation of neck (degrees) | <10 | 10-25 | >25 |
| Deficit in range of lateral flexion of neck (degrees) | <10 | 10-25 | >25 |
| Grades of torticollis (minimum score 3, maximum score 9). | | | |
| Grade I (Mild) | : Total score 3-4. | | |
| Grade II (Moderate) | : Total score 5-6. | | |
| Grade III (Severe) | : Total score 7-9. | | |

Table 2 Lok Nayak Hospital Outcome Scoring Scale (LNHOSS) for quantifying the surgical results.

| *Improvement in | Points | | | |
|--|---------------------|--------|--------|------|
| | 1 | 2 | 3 | 4 |
| Head tilt | <25% | 25-50% | 50-75% | >75% |
| Rotational deficit | <25% | 25-50% | 50-75% | >75% |
| Lateral Flexion deficit | <25% | 25-50% | 50-75% | >75% |
| Final outcomes (minimum score 3, maximum score 12) | | | | |
| Poor | : Total score 3-4 | | | |
| Fair | : Total score 5-7 | | | |
| Good | : Total score 8-10 | | | |
| Excellent | : Total score 11-12 | | | |

*The improvement calculated as (Initial deficit- Residual deficit) / Initial deficit x 100 = ____%.

comes on 5 parameters viz. improvement in neck tilt; achievement of bilateral neck symmetry; ease of neck movements, quality of scars and improvement in self-esteem (0:Poor; 1:Fair; 2:Good and 3:Excellent). The scores are collated and the overall outcome is interpreted as 'Poor' (total score ≤5); 'Fair' (total score 6-9); 'Good' (total score 10-12) and 'Excellent' (total score 13-15).

We trust that use of LNHS GS for pre-operative grading of severity of torticollis, and LNHOSS for objective quantification of surgical outcomes would obtain wide acceptability and ensure uniformity across various comparative studies in future.

Ethical approval

Not required.

Funding

None.

Conflict of Interest

None.

References

1. Lee EH, Kang YK, Bose K. Surgical correction of muscular torticollis in the older child. *J Pediatr Orthop* 1986;6:585-9.

- Lee GS, Lee MK, Kim WJ, Kim HS, Kim JH, Kim YS. Adult patients with congenital muscular torticollis treated with bipolar release: report of 31 cases. *J Korean Neurosurg Soc* 2017;60(1):82-8. doi:10.3340/jkns.2016.0303.018.
- Omid-Kashani F, Hasankhani EG, Sharifi R, Mazlumi M. Is surgery recommended in adults with neglected congenital muscular torticollis? A prospective study. *BMC Musculoskelet Disord* 2008;9:1-6. doi:10.1186/1471-2474-9-158.
- Cheng JCY, Tang SP, Chen TMK, Wong MWN, Wong EMC. The Clinical presentation and outcome of treatment of congenital muscular torticollis in infants- a study of 1086 cases. *J Pediatr Surg* 2000;35(7):1091-6. doi:10.1053/js.2000.7833.
- Kim HJ, Ahn HS, Yim SY. Effectiveness of surgical treatment for neglected congenital muscular torticollis: a systematic review and meta-analysis. *Plast Reconstr Surg* 2015;136(1):67e-77e. doi:10.1097/PRS.0000000000001373.

Aakanksha Goel
Prabhat Shrivastava
Arun Goel
Padam S Bhandari

Department of Burns and Plastic Surgery, Lok Nayak Hospital and associated Maulana Azad Medical College, New Delhi, 110002, India

E-mail address: drpsacademics@gmail.com (P. Shrivastava)

© 2022 British Association of Plastic, Reconstructive and Aesthetic Surgeons. Published by Elsevier Ltd. All rights reserved.

<https://doi.org/10.1016/j.bjps.2022.06.053>

Development of a treatment pathway for enzymatic debridement in cutaneous burns: A single centre experience



Dear Sir,

Early wound debridement for deep partial and full thickness burns reduces infection risk, facilitates prompt evaluation of the wound bed and shortens hospital admission.¹ Current standard of care (SOC) for burn debridement is surgical excision. Disadvantages of this technique include blood loss and excision of viable tissue.²

Enzymatic debridement (ED) is an alternative to SOC. Proposed benefits of ED include dermal preservation, reduced time to complete debridement and wound closure, reduced need for surgical intervention and improved scar quality.^{3,4} ED may be particularly useful for “difficult to treat” areas, such as the face, hands and perineum.^{3,4}

A limited number of randomised-controlled trials, cohort studies and case reports have evaluated ED. Based on this evidence, European Consensus Guidelines (ECG)^{3,4} have been developed to guide its use. However, these guidelines do not necessarily cover the practicalities of delivering ED within the health service and several “off-guideline” uses are reported. The main aim of this letter is to describe the evolution of our practice at Queen Victoria Hospital, including the integration of ED as part of our service, refinements in application, patient selection, peri-procedure care and a revised interpretation of outcomes, particularly with respect to healing times.

Since 2016 we have treated 168 patients with ED, with a mean age 49 years (range: 14-97 years) and a mean TBSA of 4.97% (range: 0.1-36%); [Table 1](#). We have treated most areas of the body including face, upper limbs and feet. The majority were flame and scald burns, however we have successfully debrided mixed thermal/chemical burns (from vape batteries), which is not currently recommended by the ECG. Most patients received ED prior to either delayed autograft (18, 11%) or allograft (114, 68%). We have used ED in large burns (>30% TBSA), including sequential applications, and to prevent escharotomy in circumferential upper limb and chest burns which restricted ventilation. We have found that ED also improves depth assessment; many of the burns clinically diagnosed as full thickness often retain some dermis post-ED and to date, we have only seen one “true” full thickness injury (exposed subcutaneous fat) post-ED. The median number of days between burn injury and ED was 2 (IQR: 0-2), however we have successfully applied ED beyond the recommended 72 h post-injury, up to 9 days. The ECG recommend that if autografting is planned it is performed at least 2 days after ED (to limit secretions and local bleeding) and ideally within 21 days. This is because in wounds showing evidence of secondary healing, skin trans-

Table 1 Patient and burn injury details.

| TBSA | N (%) |
|---|----------|
| <5% | 123 (73) |
| 5 to <10% | 19 (11) |
| 10 to <30% | 23 (14) |
| ≥30% | 3 (2) |
| Mechanism of injury | |
| Flame | 87 (52) |
| Contact | 17 (10) |
| Scald | 59 (35) |
| Chemical | 3 (2) |
| Electrical | 2 (1) |
| Area of burn treated with Nexobrid ^a | |
| <1% | 7 (8) |
| 1-2% | 42 (51) |
| 3-5% | 26 (31) |
| ≥5 to <10% | 2 (2) |
| ≥10 to <30% | 5 (6) |

^a Data since October 2019 ($n = 83$), when data collection for this variable started.

plantation is thought to have worse outcomes than no intervention. In our unit, the median number of days between ED and autograft is 26 (IQR 15-35.5), and we have successfully autografted up until 114 days post-ED, in a patient with a non-healing 3 × 4 cm scalp burn who wished to pursue non-operative management for as long as possible.

Over time we have streamlined the treatment pathway for ED. After initial review by a consultant to decide whether ED is indicated, our approach is primarily nurse-led; from application, removal, dressings and subsequent follow-up. Whilst ED is regarded a formal debridement procedure (with written patient consent), we have moved away from application in a theatre setting. In collaboration with anaesthetic colleagues, we have formulated a pathway that enables appropriate analgesia to be delivered, in the form of regional anaesthesia or long-acting local anaesthetic (LA) for smaller burns, in a ward-based environment. Since October 2019, we have used LA for 27 cases and regional blocks for 40 cases, including 17 epidurals or spinal blocks. Whilst the ECG recommend regional blockade for upper limb burns, there is a paucity of data regarding epidurals for lower limb burns, which we have found highly effective. Implementing this pathway has enabled us to treat some burns with ED as day case ($n = 36$), reducing the overall length of stay to a median of 6.5 bed days (IQR 2-7).

Healing time after ED remains a controversial area. The ECG recommend that autografting be considered if no significant progress with epithelisation is made after 21 days due to unstable scarring and intensive wound care requirements of prolonged conservative management. At our unit, we are increasingly allowing burns that are unhealed at 21 days, but showing signs of healing, more time to heal spontaneously. Median time from injury to discharge from the service is 50 days (IQR 33.5-74; range 3-190 days), and 8 outpatient appointments. Despite these relatively prolonged healing times, in our burns reconstruction clinic it is rare for patients managed with ED to require subsequent reconstruction compared to those who are skin grafted.

In summary, our protocol for ED enables us to treat burn wounds of various aetiologies and sizes in a ward-based setting, thereby reducing theatre utilisation and length of stay. This is facilitated by our use of LA and regional blockade. As our experience evaluating wound beds post-ED has developed, we are increasingly allowing burns longer time for spontaneous healing. To support widespread adoption of ED, we recommend further research regarding use in non-thermal burns, analgesic modalities (especially LA and epidurals), and a long-term analysis of scar outcomes for burns managed with prolonged (>21 day) non-surgical management.

Declaration of Competing Interest

AL, HC, DL and SB have no conflicts of interest to declare. BD was part of the 2020 European Consensus Guideline Group, is a member of the data monitoring committee for a Nexobrid trial and has chaired meetings on the use of Nexobrid.

Funding

None.

Ethical approval

Not required.

References

1. Xiao-Wu W, Herndon DN, Spies M, Sanford AP, Wolf SE. Effects of delayed wound excision and grafting in severely burned children. *Arch Surg* 2002. doi:10.1001/archsurg.137.9.1049.
2. Rosenberg L, Krieger Y, Bogdanov-Berezovski A, Silberstein E, Shoham Y, Singer AJ. A novel rapid and selective enzymatic debridement agent for burn wound management: A multi-center RCT. *BURNS* 2014;40:466-74. doi:10.1016/j.burns.2013.08.013.
3. Hirche C, Citterio A, Hoeksema H, Koller J, Lehner M, Martinez JR, et al. Eschar removal by bromelain based enzymatic debridement (Nexobrid®) in burns: An European consensus. *Burns* 2017;43:1640-53. doi:10.1016/j.burns.2017.07.025.
4. Hirche C, Kreken Almeland S, Dheansa B, Fuchs P, Governa M, Hoeksema H, et al. Eschar removal by bromelain based enzymatic debridement (Nexobrid®) in burns: European consensus guidelines update. *Burns* 2020. doi:10.1016/j.burns.2020.03.002.

Alice Lee

Core Surgical Trainee, Department of Plastic Surgery, Stoke Mandeville Hospital, Mandeville Road, Aylesbury HP21 8AL, United Kingdom

Henrietta Creasy

Specialist Registrar in Plastic Surgery, Queen Victoria Hospital NHS Foundation trust, Holtye Road, East Grinstead RH19 3DZ, United Kingdom

Denise Lancaster

Burns Governance Quality and Data Lead, Queen Victoria Hospital NHS Foundation Trust, Holtye Road, East Grinstead RH19 3DZ, United Kingdom

Simon Booth
Burn Researcher, McIndoe Burn Centre, Queen Victoria Hospital NHS Foundation trust, Holyte Road, East Grinstead, RH19 3DZ, United Kingdom

Baljit Dheansa
Consultant Burns & Plastic Surgeon and Honorary Senior Lecturer, Queen Victoria Hospital NHS Foundation trust, Holtye Road, East Grinstead, RH19 3DZ, United Kingdom
E-mail address: alice.lee13@imperial.ac.uk (A. Lee)

© 2022 British Association of Plastic, Reconstructive and Aesthetic Surgeons. Published by Elsevier Ltd. All rights reserved.

<https://doi.org/10.1016/j.bjps.2022.06.061>

Image data sharing for patients born with a cleft lip: A call for action to the UK cleft community



Dear Sir,

Introduction

The standardised measurement of outcomes is essential to facilitate consistent and comprehensive evaluation of healthcare interventions for patients born with cleft lip and palate.¹ Certain outcomes, such as speech and maxillary growth, have established and validated outcome tools that were designed in the United Kingdom (UK) and are integrated within the standardised audit system.² Facial aesthetic outcome measurement is crucial to evaluate the success of cleft lip surgical reconstruction and tools have previously been described within five broad themes of direct clinical, photographic, videographic, three-dimensional and patient reported outcome assessment. Unlike speech and maxillary growth, none of these measures of aesthetic outcomes have been sufficiently validated, nor internationally accepted for use, thus a standardised method is currently not recognised. To advance this field, using modern techniques of machine and deep learning, researchers need access to a large databank of facial images.

Status quo for cleft image data in the UK

Cleft care in the UK is centralised into 11 managed clinical networks following the Clinical Standards Advisory Group (CSAG) report in 1998. The CSAG report had important ramifications for cleft data as it led to the development of national audit data collection. Standardised patient facial images are captured within each cleft unit at prescribed time points in adherence with the 2018 national guidelines published by the Institute of Medical Illustrators. Yet despite

Abbreviations: BCC, Basal Cell Carcinoma.

much data being collated by the Cleft Registry and Audit NNetwork (CRANE), facial images are not collected nationally and data sharing of facial images between individual cleft units rarely occurs.

Data sharing

Data sharing increases sample size and enables big data analysis, which allows for greater precision in measuring small effects, independent confirmation of results and enhanced efficiency. The European Union's General Data Protection Regulation (GDPR) introduced data privacy laws involving the storage, transfer and sharing of data in 2018. GDPR is often viewed as a barrier to data sharing, but the legislation provides greater control and protection to the individual to enable data sharing with their permission.³ Patient data belongs to the individual who voluntarily provided their information, and most patients are supportive of their data being used for research.⁴ Traditionally, organisations have been reluctant to share data, and this may be due to a lack of incentive, technical barriers, cost implications and concerns regarding the political, legal and ethical elements of data privacy.⁵

Yet despite the barriers, a culture for data sharing is rapidly gaining momentum. The COVID-19 pandemic highlighted the immediate positive impact of data sharing for the benefit of global public health when China made the SARS-CoV-2 genome publicly available through open access platforms to hasten development of critical diagnostic assays.⁵ The Goldacre Report published in April 2022 advocates for the better, broader and safer use of health data for research and analysis. The report recognises data as being at the core of healthcare and the review aims to unleash the power of NHS data by making it more available on trusted research environments (TREs), which are secure but facilitate sharing.

Benefits and risk of sharing image data

The sharing of facial image data between UK cleft units for research purposes would have a dramatic impact on the advance of a validated facial aesthetic outcome tool. The incidence of cleft is approximately 1/700 live births, which means that individual UK cleft units can only access a small sample size of patient images. A secure yet accessible national cleft facial image databank would increase sample size considerably and allow data scientists to design and test meaningful tools, which in turn would facilitate objective and comprehensive evaluation. Data sharing does come with risks of data leaks of sensitive information and for data to be used for unintended and potentially harmful purposes.³ However, with the presence of secure sharing environments with appropriate safeguards, we believe the benefits outweigh the risks to promote scientific discovery for the good of the population who have voluntarily allowed their images to be recorded in the first place.

Conclusions and call for action

The UK has a rich source of standardised cleft facial images which are not currently being used to their full potential. A paradigm shift is required to foster a culture of data sharing for the benefit of the population, whilst protecting participating individuals. The Goldacre report describes practical ways in which data sharing can take place in the NHS via TREs, and the UK government has already committed a financial investment. Cleft facial images are ideal for data sharing because they are harmonised due to the standardised methods of image data collection. A unified approach from the UK cleft community to create a cleft facial image databank at this opportune time following the Goldacre report will be beneficial for the global population of patients and families affected by cleft.

Ethical approval

The study does not involve human or animal subjects

Funding

None

Declaration of Competing Interest

None

References

1. Weidler EM, Britto MT, Sitzman TJ. Facilitators and barriers to implementing standardized outcome measurement for children with cleft lip and palate. *Cleft Palate Craniofac J* 2021;**58**(1). doi:[10.1177/1055665620940187](https://doi.org/10.1177/1055665620940187).
2. Sharma VP, Bella H, Cadier MM, Pigott RW, Goodacre TEE, Richard BM. Outcomes in facial aesthetics in cleft lip and palate surgery: a systematic review. *J Plast, Reconstruct Aesthet Surg* 2012;**65**(9):1233-45. doi:[10.1016/j.bjps.2012.04.001](https://doi.org/10.1016/j.bjps.2012.04.001).
3. White T, Blok E, Calhoun VD. Data sharing and privacy issues in neuroimaging research: Opportunities, obstacles, challenges, and monsters under the bed. *Hum Brain Mapp* 2022;**43**(1):278-91. doi:[10.1002/hbm.25120](https://doi.org/10.1002/hbm.25120).
4. Watts G. Data sharing: keeping patients on board. *Lancet Digital Health* 2019;**1**(7):e332-3. doi:[10.1016/S2589-7500\(19\)30163-3](https://doi.org/10.1016/S2589-7500(19)30163-3).
5. Schwalbe N, Wahl B, Song J, Lehtimäki S. Data sharing and global public health: defining what we mean by data. *Front Digital Health* 2020;**2**. doi:[10.3389/fdgh.2020.612339](https://doi.org/10.3389/fdgh.2020.612339).

Matthew Fell
North Bristol NHS Trust, United Kingdom

Sophie Butterworth
Newcastle upon Tyne NHS Foundation Trust, United Kingdom

Kerry Humphries
The University of Bristol, United Kingdom

David C G Sainsbury
Newcastle upon Tyne NHS Foundation Trust, United
Kingdom

Felicity Vidya Mehendale
The University of Edinburgh, United Kingdom

Bruce Richard
Birmingham Women's and Children's Hospital, United
Kingdom
E-mail address: mattfell@doctors.org.uk (M. Fell)

© 2022 British Association of Plastic, Reconstructive and Aesthetic Surgeons. Published by Elsevier Ltd. All rights reserved.

<https://doi.org/10.1016/j.bjps.2022.06.082>

Patient perspectives on nipple-areola complex micropigmentation during the COVID-19 pandemic



Dear Sir,

Introduction

Micropigmentation, also referred to as dermopigmentation and medical tattooing, is a well-recognised option for nipple-areola complex (NAC) reconstruction, either by itself, or in combination with surgical nipple reconstruction. Its importance to patients in the breast reconstruction journey has also been explored, and deemed a valuable part to the patient.¹ The importance to patients of breast reconstruction following mastectomy has also been studied extensively and found that it can improve the patient's psychological wellbeing.²

The Covid-19 pandemic had a significant impact on health seeking behaviour, with significant reductions, particularly after the first lockdown period in the United Kingdom, and a very slow return to "pre-pandemic" levels.³ The British Association of Plastic Reconstructive and Aesthetic Surgeons (BAPRAS) and the Association of Breast Surgery (ABS) issued statements regarding the recommencement of both immediate & delayed breast reconstruction, but these did not include or refer to NAC reconstruction.⁴

Our aim was to assess the views of patients regarding micropigmentation in response to the COVID-19 pandemic, and whether their attitudes to seeking out this part of the reconstructive journey had been altered.

Results

A review of 53 patients between August and December 2020 who were due to attend for NAC micropigmentation were

surveyed for their opinions and views on micropigmentation during the COVID-19 pandemic. The majority of patients (56.6%) were awaiting their first micropigmentation intervention, with the remainder at varying later stages. Our micropigmentation team describes "Stage 0" patients as those awaiting their first intervention, with "Stage 1" being those awaiting their second intervention to re-apply the micropigmentation to build colours up. "Stage 2" and beyond follow the same pattern. "Top-up" refers to those patients receiving re-applications when the colours fade, which is normal with the semi-permanent pigments that are routinely used. 81.1% of surveyed patients reported that COVID-19 had not impacted on their decision to have micropigmentation, with the same proportion happy to proceed with micropigmentation at the time of questioning. 84.9% were not self-isolating in response to the pandemic, with the same proportion reporting they were well at the time of questioning. 94.3% of patients surveyed felt that micropigmentation was an important part of their reconstructive journey, with some describing it as "the end" of the journey, and others as the "most important" part of the journey.

Discussion

The breast reconstruction journey is incredibly variable and individualised to each patient. The psychological, social, and emotional impact of breast cancer and reconstruction is well established. The use of micropigmentation can provide a positive impact, allowing closure, and "an end" to the cancer journey of these patients. Whilst not every patient may wish for, or seek out, NAC micropigmentation, those who do describe benefits from it.

COVID-19 resulted in alteration of the provision of Breast Cancer care, which included the suspension of immediate breast reconstruction, which therefore impacted psychological health in those who experienced delays or alterations.⁵ In addition, COVID-19 also had an impact on health seeking behaviour in general. The data published by the Department of Health and Social Care (DHSC) and the Office of National Statistics (ONS) describes this in relation to primary care consultation rates. It is unlikely that this data set reflects or includes the specific patient group we have studied.

The micropigmentation clinics our team provided were halted during the first lockdown, as they were identified as "non-essential" during that time. When the service was recommenced, the clinic was relocated to a private hospital site during the pandemic. Many patients mentioned this as part of their positive experience, explaining that being away from an acute site, and so away from any COVID-19 patients, was reassuring, as well as the welcoming entrance to the clinic building, with clear directions within the building to the clinic room.

Formal review of consultation rates, including how these were conducted, for breast reconstruction and NAC reconstruction or micropigmentation on a national level would be of benefit. Nevertheless, the majority of women surveyed still felt that they wanted to proceed with micropigmentation and would have been happy to proceed at that time of the COVID-19 pandemic.

| Stages of micropigmentation | | |
|-----------------------------|----|-------|
| Stage 0 | 30 | 56.6% |
| Stage 1 | 11 | 20.8% |
| Stage 2 | 7 | 13.2% |
| Stage 3 | 2 | 3.8% |
| Stage 4 | 1 | 1.9% |
| “Top-up” | 2 | 3.8% |
| Total = | 53 | |

| Has COVID impacted your decision to have micropigmentation? | | |
|---|----|-------|
| Y | 7 | 13.2% |
| N | 43 | 81.1% |
| Not documented | 3 | 5.7% |

| Are you happy to have micropigmentation done now? | | |
|---|----|-------|
| Y | 43 | 81.1% |
| N | 4 | 7.5% |
| Not documented | 4 | 7.5% |
| Other | 2 | 3.8% |

Conclusion

Our review suggests the majority (81.1%) of women had not altered their decision on micropigmentation and would still proceed with it, despite the pandemic situation. This highlights the importance of body image from the patients' own perceptions. While our study is limited by the small population size, it does reinforce the importance of micropigmentation in the breast reconstruction journey. More detailed reviews, such as formal Health Related Quality of Life outcomes of NAC micropigmentation, with or without Nipple or Breast reconstruction should be considered, in order to provide optimal information to our patients, but the individuality of this pathway must be appreciated when planning with our patients.

Ethical approval

Not required.

Declaration of Competing Interest

No conflicts of interested declared.

Funding

No funding required for this study.

Supplementary materials

Supplementary material associated with this article can be found, in the online version, at doi:[10.1016/j.bjps.2022.06.032](https://doi.org/10.1016/j.bjps.2022.06.032).

References

- Porter C, Pilley M, Agarwal R. The role of skin camouflage and micropigmentation in the fields of burns and plastic surgery. *PMFA J* 2015;2(2).
- Chen W, Lv X, Xu X, Gao X, Wang B. Meta-analysis for psychological impact of breast reconstruction in patients with breast cancer. *Breast Cancer* 2018;25:464-9.
- Department of Health and Social Care and Office for National Statistics, “Direct and Indirect health impacts of COVID-19 in England,” UK Government, 2021.
- British Association of Plastic Reconstructive and Aesthetic Surgeons, “Breast Reconstruction,” [Online]. Available: <https://www.bapras.org.uk/professionals/clinical-guidance/breast-reconstruction>. [Accessed 6 May 2022].
- Swainston J, Chapman B, Grunfeld EA, Derakshan N. COVID-19 Lockdown and Its Adverse Impact on Psychological Health in Breast Cancer. *Front Psychol* 2020;11:2033.

S. Frost
M. Pilley
C. Porter
R. Agarwal

Department of Plastic Surgery, University Hospitals of Leicester NHS Trust, Infirmary Square, Leicester, LE1 5WW, UK

E-mail addresses: stephen.frost1@nhs.net (S. Frost), reena.agarwal@uhl-tr.nhs.uk (R. Agarwal)

© 2022 British Association of Plastic, Reconstructive and Aesthetic Surgeons. Published by Elsevier Ltd. All rights reserved.

<https://doi.org/10.1016/j.bjps.2022.06.032>

Representation of plastic and cosmetic surgeons in British newspapers



Dear Sir,

Introduction

With the increasing demand for cosmetic procedures following the COVID-19 lockdown, there is a growing need for transparency regarding the qualifications and training of individuals providing these treatments.¹ Surgeon selection may be compromised by a lack understanding of the differences between surgical specialists and the training and experience they receive.² For example, the terms “plastic surgeon” or “cosmetic surgeon” may be appropriately or inappropriately used to describe plastic surgeons, other surgeons, non-surgical doctors, and individuals without medical training. This further amplifies the mis-conception that “cosmetic surgery” is a surgical speciality and that it can be interchangeably used with the term “plastic surgery”.³ The GMC do not recognise the term “cosmetic surgeon” and so

Abbreviations: BCC, Basal Cell Carcinoma.

consequently this area is unregulated and relies on reaction to bad practice rather than primary legislation.

The aim of this study was to investigate the incidence rate of British newspapers referring to clinicians inappropriately as plastic or cosmetic surgeons.

Materials and method

The top five tabloid and top five broadsheet newspapers based on readership (Audit Bureau of Circulations) were selected. The *i* and Daily Mirror had to be excluded as they lacked online search features. The remaining eight newspapers included in the search were: The Sun, The Metro, The Daily Mail, Standard, Guardian, Times, Telegraph and Financial Times. The selected newspaper's websites were searched for articles written between 09/2016 to 09/2021 for the keywords "plastic surgeon" OR "cosmetic surgeon".

All articles were read by the two key investigators and those that referred to doctors practicing within the UK as plastic or cosmetic surgeons were selected. Following this, the names of the referenced doctors were searched for in the GMC register to determine if they were on any higher training register.

Results

The search on the selected keywords found a total of 2326 articles. 2107 articles were excluded as they did not refer to a specifically named individual practicing within the UK as a plastic or cosmetic surgeon. Of the 219 articles remaining, 136 (62%) referred to individuals as "plastic surgeons" and 83 (38%) referred to individuals as "cosmetic surgeons".

22 (16%) of the doctors referred to as "plastic surgeons" were not listed on the GMC speciality register for plastic surgery. Of those inappropriately referred to as "plastic surgeons": 11 were not on any higher specialist register, 7 were on the ophthalmology register, 3 were on the GP register, and 1 was on the ENT register.

39 (47%) of the individuals described "cosmetic surgeons" were listed on the plastic surgery speciality register and 11 (13%) were on other higher surgical specialist registers (2 were on the ENT register and 9 were on ophthalmology register). 33 (40%) of the cosmetic surgeons were not listed on the GMC register as having higher surgical training as 18 (22%) were on the GP register and 15 (18%) were not listed on any training register. There was no statistically significant difference in the proportion of inappropriate references of individuals as either plastic surgeon ($p=0.276$) or cosmetic surgeons ($p=0.283$) between the tabloid and broadsheet (Tables 1 and 2).

Discussion

There is a degree of public misunderstanding regarding the role and scope of work carried out by plastic surgeons.² Our data demonstrates that this is compounded by the UK journalistic press' use of the terms plastic or cosmetic surgeon to describe a range of practitioners who offer cosmetic procedures. These practitioners include other higher specialty surgeons but most concerning is that 40% of those referred

Table 1 Usage of the term "plastic surgeon" $p=0.276$ (Pearson chi-squared).

| | Not on plastic surgery training register | On plastic surgery training register | Total |
|------------|--|--------------------------------------|-------|
| Tabloid | 12 (14%) | 76 (86%) | 88 |
| Broadsheet | 10 (21%) | 38 (79%) | 48 |
| Total | 22 (16%) | 114 (84%) | 136 |

Table 2 Usage of the term "cosmetic surgeon" $p=0.283$ (Pearson chi-squared).

| | Not on higher surgical training register | On higher surgical training register | Total |
|------------|--|--------------------------------------|-------|
| Tabloid | 23 (37%) | 40 (63%) | 63 |
| Broadsheet | 10 (50%) | 10 (50%) | 20 |
| Total | 33 (40%) | 50 (60%) | 83 |

to as cosmetic surgeons have not completed higher surgical training and that 16% of doctors referred to as plastic surgeons are not consultant plastic surgeons. The obvious danger with these misnomers is that they compromise patient safety and may lead to litigation due to a lack of understanding about the important differences in the training and qualifications of individuals providing cosmetic treatments.

Although this data demonstrates how the press portray doctors doing cosmetic surgery and not necessarily how these clinicians describe themselves, the GMC Guidance for Doctors Who Offer Cosmetic Interventions states that practitioners "must always be honest and never misleading about skills, experience, qualifications, professional status and current role" and "must make sure the information published is factual and can be checked, and does not exploit patients' vulnerability or lack of medical knowledge".⁴ This could arguably extend to ensuring accurate representation in the media where possible.

More broadly, these findings also indicate further encroachment in the surgical domains that traditionally plastic surgeons held as their own. As other specialties extend their practice to include cosmetic procedures within their organ or system domain, there is a greater need to advertise what plastic surgery encompasses amongst the general public. Crucially there needs to be increased awareness of the distinct differences between plastic and cosmetic surgeons, to safeguard public safety and protect practitioners from litigation.

Declaration of Competing Interest

There are no conflicts of interest in the materials or subject matter dealt within the manuscript.

Ethical approval

Not required.

Funding

No funding was sought for this project.

Authors' contribution

MRG - data collection, data processing, manuscript preparation, RWFB - ideation, data collection, data processing, manuscript preparation, APJ - critical appraisal, KPA - critical appraisal.

References

1. British Association of Aesthetic Plastic Surgeons. Post-pandemic panic [Press release] https://baaps.org.uk/media/press_releases/1824/postpandemic_panic_baaps_issues_a_stark_warning_to_the_public_dont_fall_victim_to_unscrupulous_providers_selling_surgery_as_a_postlockdown_quick_fix/ [Accessibility verified April 3, 2021]
2. Shah A, Patel A, Smetona J, Rohrich RJ. Public perception of cosmetic surgeons versus plastic surgeons: increasing transparency to educate patients. *Plast Reconstr Surg* 2017;139(2) 544e-557e.
3. Reid AJ, Malone PSC. Plastic surgery in the press. *J Plast Reconstr Aesthet Surg* 2008;61(8):866-9.
4. GMC. Guidance for doctors who offer cosmetic interventions. <https://www.gmc-uk.org/ethical-guidance/ethical-guidance-for-doctors/cosmetic-interventions> [Accessibility verified April 3, 2021]

M.R. Goodarzi
R.W.F. Breakey
A.P. Jones
K.P. Allison

Department of Plastic and Reconstructive Surgery, James Cook University Hospital, Middlesbrough, TS4 3BW, United Kingdom

E-mail address: Mohammad.goodarzi1@nhs.net (M.R. Goodarzi)

© 2022 British Association of Plastic, Reconstructive and Aesthetic Surgeons. Published by Elsevier Ltd. All rights reserved.

<https://doi.org/10.1016/j.bjps.2022.06.048>

Social Media Marketing of Cosmetic Services in the United States: Examining Gender Disparities



Dear Sir,

Introduction

Cosmetic surgery has established itself as rapidly-growing industry in the United States in the 21st century. According to the American Society of Plastic Surgeons, 15.5 million

cosmetic procedures were performed in 2020, a 131% increase over the last 2 decades.² Many Americans do their own online research regarding potential procedures before approaching a surgeon for a consultation; a rapidly growing percentage of this research is being conducted via social media.¹ Men have always represented a smaller proportion of the Americans undergoing cosmetic procedures.³ However, there is clear evidence that demand among the male demographic is significantly increasing; 1.1 million cosmetic procedures were performed on males in 2020, a 172% increase from 2000.^{4,5}

While both the number of men undergoing cosmetic procedures and the number of potential patients performing research through social media has clearly increased over the past two decades, whether or not plastic surgery practices adequately market their services to men on their social media profiles remains unclear. Thus, the goal of this study is to quantify potential gender differences seen in plastic surgery marketing on social media in the U.S.

Methods

A systematic search was conducted using Google, Facebook, and Instagram to examine potential gender disparities in plastic surgery social media marketing in all 50 U.S. states. For each state, the principal search term of “plastic surgery [state]” was queried, and the websites of the first 5 private plastic surgery practices to appear were selected for that state. The Facebook and Instagram profiles of each practice were then searched for and viewed.

Each practice's Facebook and Instagram profile were analyzed in two separate fashions: The presence or absence of advertisement for male services in the last ten posts, and the proportion of specific procedures advertised. To be recorded, a post(s) must have explicitly indicated that a service was being marketed to men.

The resultant data from obtained from this search was then analyzed using IBM SPSS. Two Pearson Chi-Squared tests were performed to examine the statistical significance of differences between the Facebook and Instagram data; the first examining the number of specific procedure mentions marketed to males on each platform, and the second examining the state-by-state profile data in regard to number of profiles on each platform advertising male-specific procedures.

Results

A total of 242 Facebook and 231 Instagram profiles were selected and subsequently analyzed for this study. It should be noted that not all states had five profiles on each platform advertising male services. 2239 Facebook posts and 2294 Instagram posts were reviewed. Only 4.73% of Facebook posts and 7.97% of Instagram posts were advertisements to men. The number of both Facebook and Instagram profiles of plastic surgery practices with posts marketed towards male patients varied widely by state.

Botox/fillers, rhinoplasty, and laser hair removal are the most popular procedures among males in the U.S, followed by facelifts and blepharoplasty repair. With regard to the

Table 1 Comparison of specific male procedures advertised, Facebook and Instagram.

| Procedure | Facebook | Instagram |
|----------------------|------------------|-------------|
| Botox/Fillers | 59 | 80 |
| Rhinoplasty | 33 | 34 |
| Facelift | 24 | 31 |
| Gynecomastia Repair | 15 | 19 |
| Laser Hair Removal | 12 | 18 |
| Blepharoplasty | 6 | 6 |
| Liposuction | 5 | 3 |
| Other | 13 | 12 |
| Statistical Analysis | $\chi^2 = 2.813$ | $p = 0.902$ |

marketing of these procedures versus their actual popularity, practices did a slightly better job on Instagram than Facebook. However, Instagram's superiority over Facebook in terms of procedure-specific marketing was not statistically significant ($p = 0.90$). Additionally, it was found that in states with more than one plastic surgery practice advertising to men via social media, those practices were more likely to use Instagram than Facebook for marketing although this did not reach statistical significance ($p = 0.51$).

Discussion

The number of Americans undergoing cosmetic procedures has more than doubled over the past two decades and is projected to continue to grow. Women have historically been the dominant consumers of these services. However, the American Society of Plastic Surgery's statistics show that the popularity of cosmetic procedures is also growing among men and the number patients researching their options through social media is rapidly increasing.⁴ But it is unclear as to whether social media marketing of cosmetic procedures has adequately targeted the male market.

The results of our analysis indicate that the answer to this question is no; however, the prevalence of advertisements targeted toward men and the marketing of the most popular procedures among males was at least slight better on Instagram compared to Facebook. Limitations of our study include the fact that the analysis did not account for differences in social media activity and tendencies between men and women (Tables 1 and 2).

Conclusion

Social media research of potential cosmetic procedures among both men and women has grown significantly amongst men and women over the past decade. However, plastic surgery practices have not done an effective job in capitalizing upon this newfound popularity of cosmetic procedures in men with their social media advertising campaigns. The industry has shown improvement in this area on Instagram, which is becoming the more popular platform. There still appears to be room for cosmetic practices to fur-

Table 2 Comparison of number of profiles offering male services by state, Facebook and Instagram.

| Number of Profiles (Out of Five) | Number of States | |
|----------------------------------|------------------|--------------|
| | Facebook | Instagram |
| Five | 0 | 2 |
| Four | 2 | 2 |
| Three | 3 | 6 |
| Two | 8 | 10 |
| One | 21 | 18 |
| Zero | 17 | 12 |
| Statistical Analysis | $\chi^2 = 4.286$ | $p = 0.0509$ |

ther grow this space by improving their marketing efforts in order to further capture the male consumer.

Declaration of Competing Interest

None.

Ethical approval

Not required.

Funding

No financial funding or support was received for this review.

References

1. Array. (2021, March 30). *Array*. The aesthetic society. <https://www.surgery.org/media/news-releases/the-aesthetic-society-stats-reveal-americans-spent-over-9-billion-aesthetic-plastic-surgery-2020>. Accessed 6 October 2021.
2. 2019 Plastic Surgery Statistics Report. American society of plastic surgeons. <https://www.plasticsurgery.org/documents/News/Statistics/2019/plastic-surgery-statistics-full-report-2019.pdf>. Accessed 8 October 2021.
3. Montemurro P, Porcnik A, Hedén P, Otte M. The influence of social media and easily accessible online information on the aesthetic plastic surgery practice: literature review and our own experience. *Aesthet Plast Surg* 2015;**39**(2):270-7. doi:10.1007/s00266-015-0454-3.
4. 2020 Plastic Surgery Statistics Report. American society of plastic surgeons. <https://www.plasticsurgery.org/documents/News/Statistics/2020/plastic-surgery-statistics-full-report-2020.pdf>. Accessed 8 October 2021.
5. ASAPS 2000 Statistics on cosmetic surgery: American society for aesthetic plastic surgery. <https://www.surgery.org/sites/default/files/2000stats.pdf>. Accessed 7 October 2021.

Davis B. Rippee
School of Medicine, The University of Mississippi Medical Center, 2500 North State Street, Jackson, MS 39216, United States

H. Todd Hudson
College of Medicine, Medical University of South Carolina, Charleston, SC 29425, United States
Division of Plastic Surgery, Medical University of South Carolina, Charleston, SC 29425, United States

Sami Tarabishy
*Division of Plastic Surgery, Medical University of South
 Carolina, Charleston, SC 29425, United States*

Fernando A. Herrera
*College of Medicine, Medical University of South
 Carolina, Charleston, SC 29425, United States*
*Division of Plastic Surgery, Medical University of South
 Carolina, Charleston, SC 29425, United States*
 E-mail address: herreraf@musc.edu (F.A. Herrera)

© 2022 Published by Elsevier Ltd on behalf of British Association of Plastic, Reconstructive and Aesthetic Surgeons.

<https://doi.org/10.1016/j.bjps.2022.06.029>

Medical malpractice litigations after hair restoration surgery in the United States



Dear Sir,

Medical malpractice is an evolving field with significant consequences for physicians regardless of the verdict. Plastic surgeons have a 15% chance of being sued each year, and cosmetic surgeries are commonly involved.¹ Although most medical malpractice litigations are in favor of defendants, the economical and psychological stress during litigations are a significant concern for surgeons.¹

Hair loss affects millions of adults, both men and women, in the United States.² Earlier stages of hair loss could be managed conservatively with medicine and lifestyle modifications, but more moderate to severe cases may require hair restoration procedures. More than 180,000 people in the United States undergo hair transplant procedures annually.³ Although hair transplantation is generally safe, these procedures are not risk free. Common complications include infections, scarring, and patient dissatisfaction,⁴ which may prompt patients to pursue medical malpractice litigations against providers offering these procedures. While several studies were published on malpractice litigations involving other cosmetic surgeries, lawsuits after hair restoration surgery have not been discussed to date. The purpose of this study was to identify factors associated with malpractice litigations against surgeons performing hair transplantations, litigation outcomes, and magnitude of indemnity payments to plaintiffs following hair restoration procedures.

We used the Westlaw legal database (Thompson Reuters, NY), a comprehensive resource with legal documents from over 40,000 legal databases, to search jury verdicts and settlements related to hair transplant and hair restoration.

The Boolean term “(hair transplant) OR (hair restoration surgery) OR (hair restoration)” was used to collect all litigation cases associated with hair transplant and hair restoration procedures. Cases whose defendants were not surgeons or organizations that performed the surgery were excluded. Duplicate cases were also excluded. We collected trial outcomes (plaintiff vs. defendant verdicts), reasons behind malpractice litigations and payouts for litigations in favor of plaintiffs. We calculated frequencies and percentages of descriptive variables across cases, trial outcomes, and alleged reasons for malpractice out of total number of cases. Since the Westlaw dataset is publicly available under subscription, no Institutional Review Board review was needed for this study.

Among 27 malpractice litigations involving hair transplant that occurred between 1986 and 2019, 15 cases met our inclusion/exclusion criteria. Scarring and lack of informed consent ($N = 9$, 60.0% each) were the most common alleged reasons for malpractice (Table 1). 10 cases (66.7%) were ruled in favor of defendants vs. 5 cases (33.3%) in favor of plaintiffs. Two cases (13.3%) involved failure to diagnose, treat, or make a referral for skin cancer, which allegedly led to progression and spread of the cancer. Other alleged reasons for litigation included infection, scalp lacerations, lack of improvement, failure to inform the side effects of pain medications, and fraud ($N = 1$, 6.7% for each alleged reason).

Among the hair transplant malpractice litigations, five cases (33.3%) were in favor of the plaintiffs and indemnity payments ranged from \$20,000 to \$1238,534 (median \$134,700) (Table 2). Among these, 4 (80.0%) reported lack of informed consent as an alleged reason for malpractice and we will depict two of these cases as examples. The first case was a 70-year-old plaintiff with an intraoperative stroke that led to permanent brain damage and speech impairment. The defendant surgeon failed to perform a preoperative evaluation and failed to provide a proper informed consent. The plaintiff was under anesthesia for over 10 h despite of his age and medical conditions. Despite the intraoperative complication, the plaintiff was not treated with thrombolytics in a timely manner nor referred to a neurologist by the defendant. A plaintiff verdict was determined for the case, costing the defendant side \$1238,534 after the jury reduced the gross damage payment of \$2720,000. In another plaintiff verdict case, the patient was not informed of the scalp reduction until nitrous oxide was administered for anesthesia. The plaintiff suffered a large scar on the scalp and was not in a proper mental state to give consent for the procedure. Consequently, this case costed the surgeon \$175,500 for failure to obtain a proper informed consent.

These cases demonstrate the importance of informed consent in cosmetic surgery. While disclosing all relevant information is a key part of informed consent process, surgeons should work with patients to ensure their understanding of risks and benefits of hair transplant surgery and make a shared decision.⁵

Consequently, despite the high volume of hair transplant surgeries among Americans, there is a low risk of medical malpractice litigations against surgeons performing these surgeries. However, with the ongoing high demand of

Table 1 Alleged reasons for malpractice and trial outcomes.

| Alleged reason for malpractice | No. of cases ^a | Defense verdict | Plaintiff verdict |
|--------------------------------------|---------------------------|-----------------|-------------------|
| Scarring | 9 (60.0%) | 5 (55.6%) | 4 (44.4%) |
| Informed consent | 9 (60.0%) | 5 (55.6%) | 4 (44.4%) |
| Requiring multiple surgeries | 3 (20.0%) | 2 (66.7%) | 1 (33.3%) |
| Failure to treat, diagnose, or refer | 2 (13.3%) | 2 (100.0%) | 0 (0.0%) |
| Others ^b | 5 (33.3%) | - | - |

^a The total number exceeds the number of cases as multiple alleged reasons for malpractice were noted for some cases.

^b Other reasons for malpractice litigation included infection, scalp lacerations, lack of improvement, failure to inform the side effects of pain medications, and fraud ($N = 1$ each).

Table 2 Plaintiff verdict payouts and alleged reasons for malpractice.

| Case | Scarring | Informed consent | Requiring multiple surgeries | Failure to treat, diagnose, or refer | Payout |
|------|----------|------------------|------------------------------|--------------------------------------|------------|
| 1 | - | + | - | - | \$1238,534 |
| 2 | - | + | + | - | \$175,500 |
| 3 | + | + | + | - | \$134,700 |
| 4 | + | - | - | - | \$50,000 |
| 5 | + | + | - | - | \$20,000 |

these procedures, proper informed consent could avoid an increased escalation of lawsuits. Hair transplant surgeons must follow general principles of medical ethics to ensure patient safety and minimize medicolegal liability in their practice. These findings should provide information to assist practitioners to make relevant changes in their practice to improve patient satisfaction, lower complications and reduce their medicolegal liability.

Ethical approval

Not required as data were publicly available under subscription.

Funding

No funding was received for this work.

Declaration of Competing Interest

The authors have no competing interests to declare.

Acknowledgements

None.

References

- Boyd JB, Moon HK, Martin S, Mastrogiovanni DB. Plastic surgery and the malpractice industry. *Plast Reconstr Surg* 2021;147(1):239-47. doi:10.1097/PRS.0000000000007497.
- Phillips TG, Slomiany WP, Allison R. Hair loss: common causes and treatment. *Am Fam Physician* 2017;96(6):371-8.
- International society of hair restoration surgery. International society of hair restoration surgery: 2013 practice census results. *Published online* 2013:25.
- Kerure AS, Patwardhan N. Complications in hair transplantation. *J Cutan Aesthet Surg* 2018;11(4):182-9. doi:10.4103/JCAS.JCAS_125_18.
- Ubbink DT, Santema TB, Lapid O. Shared decision-making in cosmetic medicine and aesthetic surgery. *Aesthetic Surg J* 2016;36(1):NP14-19. doi:10.1093/asj/sjv107.

Jung Ho Gong

Daniel D. Kim

Raman Mehrzad*

Division of Plastic Surgery, The Warren Alpert Medical School of Brown University, 222 Richmond St, Providence, RI, USA

*Corresponding author.

E-mail address: raman_m1@hotmail.com (R. Mehrzad)

© 2022 British Association of Plastic, Reconstructive and Aesthetic Surgeons. Published by Elsevier Ltd. All rights reserved.

<https://doi.org/10.1016/j.bjps.2022.06.097>

Communication: Virtual application cycle impact on integrated plastic surgery residency instagram presence'



Dear Sir,

Introduction

As a result of the COVID-19 pandemic, medical students approaching residency faced numerous challenges due to the social distancing requirements that became a necessity. Barriers included shortened clerkships, fewer in-person patient care experiences, canceled visiting student rotations, and difficulty engaging with residency programs on a personal level. Medical students had limited access to the interpersonal interactions between residents and faculty that forge connections and convey a realistic view of medical facilities and the surrounding area.

Social media offers a place for applicants to gain a better understanding of the “culture” of a program, without having to invest the time and money for a visit in person.¹ Across surgical specialties, there has been an increase in residency program social media platform involvement to meet this demand, with integrated plastic surgery having a relatively large percentage of residency programs with social media presence compared to other surgical specialties. Since 2018, integrated plastic surgery residencies' presence on social media has increased dramatically, with Instagram being the most utilized platform.²

The aim of this study was to elucidate the initial effect of the COVID-19 pandemic on integrated plastic residency program social media presence by evaluating programs' posting history, follower count, and content posted surrounding the 2020-2021 virtual recruitment cycle.

Methods

A list of integrated plastic surgery residency programs was created using the American Council of Academic Plastic Surgeons (ACAPS) website. Instagram accounts for each program were found using program website listings and keyword searches. The virtual recruitment study period was defined by a start date of May 15th, 2020, and an end date of October 21st, 2020 to align with the ACAPS spring announcement of a virtual cycle through the fall revised application deadline. Data collected included post counts, dates, and types, quantitative usage of IG TV video reels and IG “Story Highlights,” and follower count.

Abbreviations: BCC, Basal Cell Carcinoma.

Presented at the Ohio Valley Society of Plastic Surgeons Annual Meeting 2021 and the American Council of Academic Plastic Surgeons Annual Meeting 2022.

This study was exempt from institutional review board review.

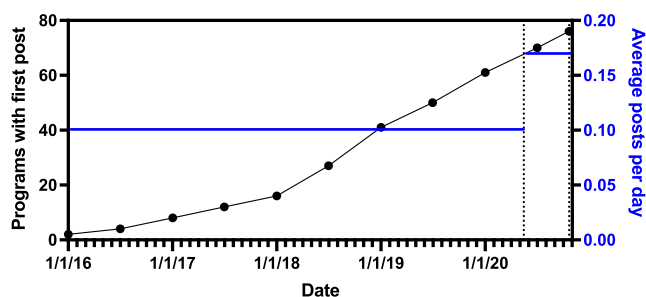


Figure 1 Cumulative number of integrated plastic surgery residency programs with first Instagram posts. Vertical dotted lines indicate the dates of the virtual recruitment study period (May 15, 2020 through October 21, 2020). Blue lines indicate the average number of Instagram posts per day for the periods prior to and following the announcement of a virtual cycle (0.1 and 0.17, respectively).

Results

At the time of data collection, following the ERAS deadline, 76 (92.7%) of the 82 integrated plastic surgery residencies had a program-specific Instagram account. **Figure 1** shows the cumulative number of residency programs that had made their first post plotted against the date of this inaugural post. The average number of posts per day prior to the virtual application announcement was 0.1, which increased to 0.17 following the announcement—an additional ~21 posts per month on average. Nearly half, $41.8\% \pm 3.53\%$ of the total posts, were generated during the virtual recruitment period. For 21 programs, posts made during this period accounted for greater than 50% of their total posts.

Integrated plastic surgery programs utilized a variety of post types on their Instagram accounts (**Table 1**) including both image series and videos. Multi-image content was the most common media used other than single image posts,

Table 1. Integrated plastic surgery instagram use metrics.

| Data point/characteristic | Value |
|---|-----------------------|
| During study period: | |
| Programs making 1st post | 13 |
| Total posts | 2073 |
| Average posts per account | 27 |
| | range 1-122 |
| | median 22 |
| Mean followers per account | 1451 |
| | range 378-4703 |
| Follower:following ratio | 7.6 |
| | range 0.44-131.4 |
| Regression coefficients | |
| # Positions available & post volume | 6.91 ($p < 0.005$) |
| # Positions available & follower volume | 322.2 ($p < 0.005$) |
| Percentage of programs using various media types: | |
| Multi-image content | 94.7% |
| Video content | 51.3% |
| Instagram TV reels | 39.5% |
| Story Highlights | 65.8% |

with multi-image content comprising 36.7% of overall posts. Video posting was less common, with video posts responsible for 10.5% of total posts. Number of residency positions available was positively related to number of posts created and number of followers, with linear regression coefficients 6.91, $p < 0.005$ and 322.2, $p < 0.005$, respectively.

Discussion

Integrated plastic surgery residencies are more active on Instagram than several other surgical specialties. This parallels the massive prevalence of social media use for marketing to patients within the field of plastic surgery.³ We have demonstrated an increase in social media activity that coincides with the transition to a virtualized application cycle, with almost half of all existing posts from integrated plastic surgery residencies occurring during the virtual applicant recruitment period. The number of residency positions was positively related to the number of posts and the number of followers, indicating that account owners may put more effort into their content if they are recruiting a larger number of residents.

Social platforms like Instagram offer programs the opportunity to reach applicants instantaneously, and in a way democratize dissemination of information. However, this is a one-way communication channel until viewers—presumably prospective applicants—contact programs via messaging or other routes. There may be a hesitancy to engage with residency programs on social media due to concerns that contact would draw attention to the applicant's own social media account;⁴ 11% of general surgery program directors have lowered the rank or removed an applicant from the rank list due to their online presence.⁵

Throughout the past few years, social media has become an important way for integrated plastic surgery residency programs to reach medical students. Due to the COVID-19 pandemic, medical students' ability to access information about residency programs via traditional methods was compromised, making digital media outreach more necessary. While the lasting implications of virtual cycles remain unclear, it is likely that social media will continue to be an integral component in how residencies market themselves to applicants. In the future, specific guidelines for residency programs, residency applicants, and engagement between the two will be necessary.

Ethical approval

Not required

Funding

None.

Declaration of Competing Interest

None declared.

References

1. Rohde SC, White EM, Yoo PS. Residency program use of social media in the COVID-19 era: An applicant's perspective. *J Surg Educ* 2021;78(4):1066-8. doi:10.1016/j.jsurg.2020.12.011.
2. Chartier C, Chandawarkar AA, Gould DJ, Stevens WG. Integrated plastic surgery residencies: 2020 update. *Aesthet Surg J* 2021;41(3):372-9. doi:10.1093/asj/sjaa172.
3. Rohrich RJ, Dayan E, Xue AS. Social media in plastic surgery: The future is now? *Plast Reconstr Surg* 2019;144(6):1509-10. doi:10.1097/PRS.0000000000006253.
4. Irwin TJ, Riesel JN, Ortiz R, Helliwell LA, Lin SJ, Eberlin KR. The impact of social media on plastic surgery residency applicants. *Ann Plast Surg* 2021;86(3):335-9. doi:10.1097/SAP.0000000000002375.
5. Langenfeld SJ, Vargo DJ, Schenarts PJ. Balancing Privacy and professionalism: A survey of general surgery program directors on social media and surgical education. *J Surg Educ* 2016;73(6):e28-32 Nov - Dec. doi:10.1016/j.jsurg.2016.07.010.

Meredith G. Moore

University of Cincinnati College of Medicine, 231 Albert Sabin Way, ML 0513, Cincinnati 45267-0513, OH, USA
University of South Florida Dept. of Plastic Surgery, Tampa, FL, USA

Alexandra Kinzer, Kinsey Barhorst, Kyle Singerman, Douglas Dembinski, Ryan Gobble*

University of Cincinnati College of Medicine, 231 Albert Sabin Way, ML 0513, Cincinnati 45267-0513, OH, USA

*Corresponding author.

E-mail address: goblern@ucmail.uc.edu (R. Gobble)

© 2022 British Association of Plastic, Reconstructive and Aesthetic Surgeons. Published by Elsevier Ltd. All rights reserved.

<https://doi.org/10.1016/j.bjps.2022.06.012>

Improving the learning process of ultrasound in plastic surgery: How easy is to read ultrasound images?



Dear Sir,

The ultrasound is increasingly useful in Plastic Surgery, but requires a specific training, in which both technical (manual ability and image acquisition) and cognitive (image interpretation) elements are essential.¹⁻⁴ To our knowledge, this is the first study that compares the cognitive ability of plastic surgeons to interpret the sonographic images to other medical specialists and that establishes an order of difficulty to recognize the main anatomical structures and layers for reconstructive surgeries.

In this study, 30 observers (10 plastic surgeons, 10 radiologists and 10 medical students) were asked to identify 46

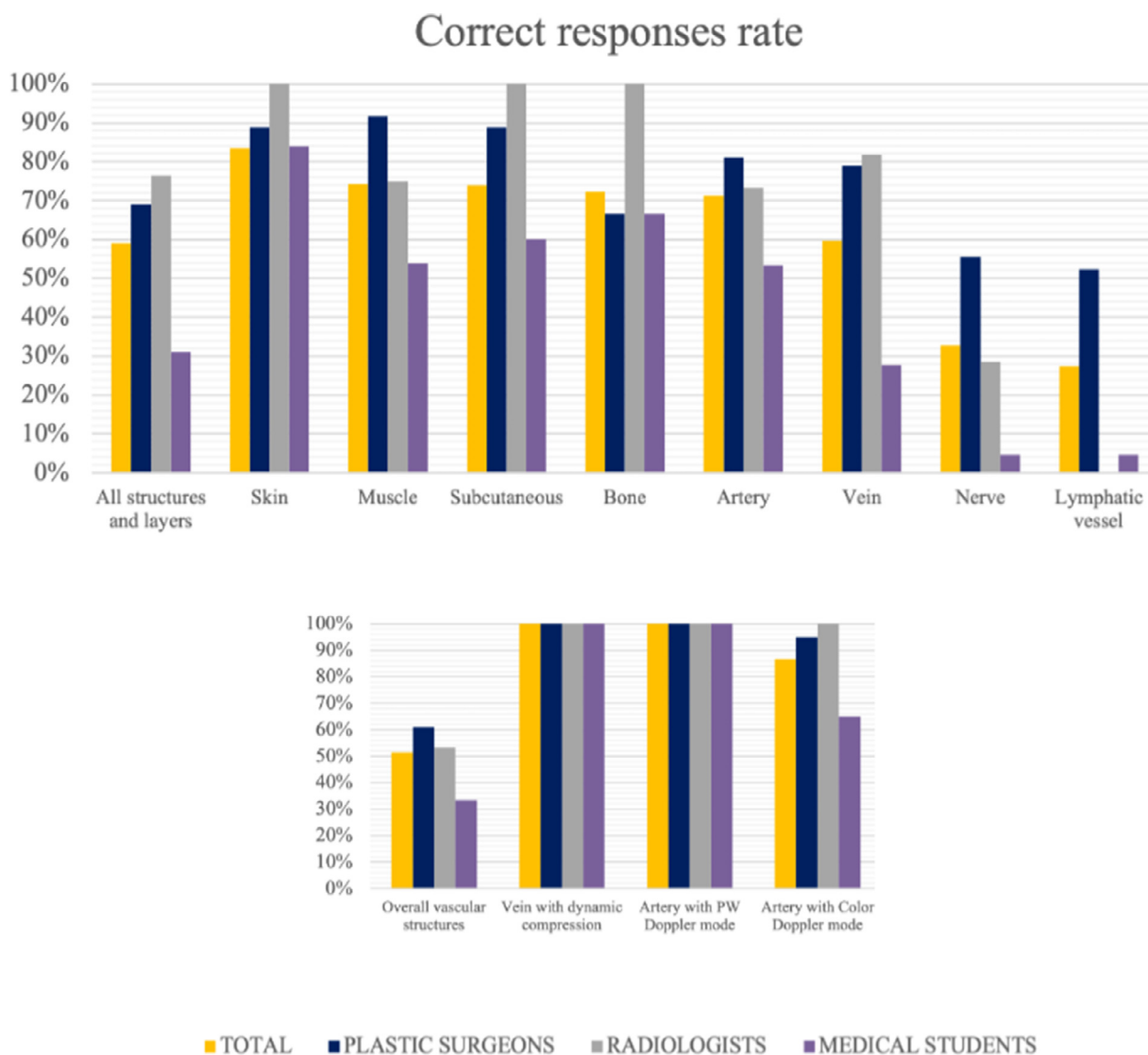


Figure 1 Percentages of correct responses rate divided by anatomical structure or layer and medical specialty.

anatomical structures and layers included in 30 sonographic images.

All the images were screenshots of ultrasound examinations that showed 4 types of layers (skin, subcutaneous tissue, muscle, bone) and 4 types of structures (artery, vein, nerve, lymphatic vessel) with B-mode imaging, except for 2 arteries that were shown with color Doppler mode, 1 artery with pulse-wave Doppler (PW Doppler) and a double photograph showing 1 artery and 1 vein with and without compression of the probe.

The maximum time for each response was 30 s and no answer options or other information were given to the participants, except the word “compression” in the image where it was applied.

The correct responses rates, the intraobserver concordance and the level confidence in the responses were assessed.

There was a total of 1380 answers. The overall correct response rate was 59% (plastic surgeons 69%, radiologists

76.5%, students 31%) (Figure 1). The mean overall confidence in the responses was 2.8, with differences between the subgroups: plastic surgeons 2.5, radiologists 4.1, students 1.7 (ANOVA, $p = 0.001$) (Figure 2).

The identification of anatomical layers was easier than that of the structures (correct response rates: layers 76.8%, structures 50.7%) and the overall order from the easiest to the most difficult was as follows: skin, muscle, subcutaneous tissue, bone, artery, vein, nerve, lymphatic vessel.

However, the use of dynamic compression and other ultrasound modes (color and PW Doppler) improved the identification of vascular structures (Figure 1), and therefore, the order of difficulty changed as follows: veins with dynamic compression and arteries with PW Doppler mode, arteries with color mode, skin, muscle, subcutaneous tissue, bone, vascular structures with B-mode, nerve, lymphatic vessel.

In addition, 6 images that included 10 layers and structures were randomly shown two times to each participant

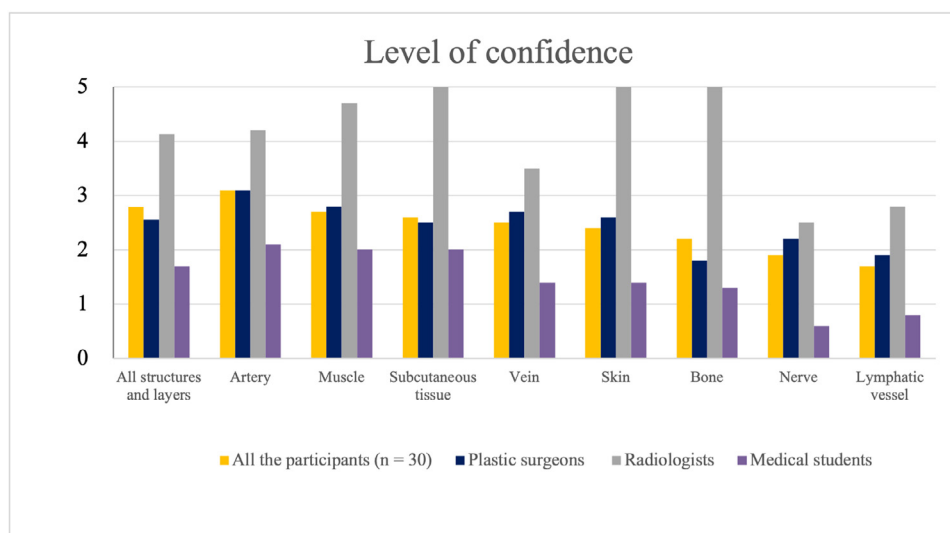


Figure 2 Level of confidence in the responses (range 0-5, from less to more confidence).

(test-retest). The correct responses rate was higher in the second assessment (57% vs 65%, $p = 0.006$), especially among the plastic surgeons: 73% vs 87%, $p = 0.04$; radiologists 61% vs 63%, $p = 0.791$; students 37% to 45%, $p = 0.229$ (McNemar test).

The level of confidence remained at a similar value in both moments (2.6 and 2.7, respectively), but differences between the subgroups were found (paired t -test): plastic surgeons 2.4 vs 2.7 ($p = 0.037$), radiologists 4.3 vs 4 ($p = 0.213$), students 1.5 vs 1.2 ($p = 0.403$).

Finally, the intraobserver agreement was also assessed: Cohen's kappa value 0.741 (plastic surgeons 0.79; radiologists 0.87; students 0.55) and overall intraobserver concordance index 77% (plastic surgeons 83%, radiologists 90%, students 58%). However, only in 50% of the cases the answer was correct in both assessments (plastic surgeons 70%, radiologists 56%, students 24%).

According to our results, the radiologists had the highest overall correct responses rate, confidence and intraobserver agreement, as expected because of their greater experience in ultrasound. However, they did not identify any of the lymphatic vessels shown. On the other hand, although the included plastic surgeons had similar experience in ultrasound than the students, they had closer results to those of the radiologists than to those of the students and they were also the ones who best identified the lymphatic vessels.

These differences would be explained by their higher experience in ultrasound examination of lymphatic vessels compared to the radiologists, and their greater anatomical knowledge compared to the students, which allow them to better know what to find and where to look for it, and consequently, be more accurate in identifying the sonoanatomy when no clinical information was given.

In addition, the plastic surgeons were the ones who improved the most in the second assessment, which may suggest a learning process. The first time an image is assessed, all the possibilities are considered, and the evaluation requires more time and effort. Once the decision is taken, it is less difficult to answer when the same image is evalu-

ated again some minutes later. Besides, it has been demonstrated that after some ultrasonographical sessions a beginner clearly could improved in ultrasonography,⁵ which means that the learning curve is relatively short for some assessments, such as the identification of the anatomical layers or the superficial veins.

In conclusion, our study confirmed that the interpretation of the sonographic image is challenging, especially for lymphatic vessels or when no other information is available, and that the previous knowledge and experience have an important role.

Conflicts of interest

None declared.

Funding

None.

Ethical approval

Not required.

References

- González-Martínez J, Torres-Pérez A, Gijón-Vega M, Nuñez-Villaveiran T. Preoperative vascular planning of free flaps: Comparative study of computed tomographic angiography, color Doppler ultrasonography, and hand-held Doppler. *Plast Reconstr Surg* 2020;**146**(2):227-37.
- Visconti G, Bianchi A, Hayashi A, Salgarello M. Ultra-high frequency ultrasound preoperative planning of the rerouting method for lymphaticovenular anastomosis in incisions devoid of vein. *Microsurg* 2020;**40**(6):717-18.
- Hayashi A, Yamamoto T, Yoshimatsu H, et al. Ultrasound visualization of the lymphatic vessels in the lower leg. *Microsurg* 2016;**36**(5):397-401.

4. Mullaney PJ. Qualitative ultrasound training: Defining the learning curve. *Clin Radiol* 2019;**74**(4):327 e7-327.e19.
5. Ohrndorf S, Naumann L, Grundey J, et al. Is musculoskeletal ultrasonography an operator-dependent method or a fast and reliably teachable diagnostic tool? Interreader agreements of three ultrasonographers with different training levels. *Int J Rheumatol*. 2010:164518.

Paloma Malagón
Department of Plastic Surgery, Hospital Germans Trias i Pujol, Universitat Autònoma de Barcelona, Barcelona, Spain

Akitatsu Hayashi
Department of Lymphedema Center, Kameda General Hospital, Chiba, Japan

María Del Río, Jordi Vilà, Oihane García
Department of Plastic Surgery, Hospital Germans Trias i Pujol, Universitat Autònoma de Barcelona, Barcelona, Spain

Cristian Carrasco
Shared senior coauthorship, Department of Plastic Surgery, Hospital Germans Trias i Pujol, Universitat Autònoma de Barcelona, Barcelona, Spain

Carmen Higuera
Chief of the Department of Plastic Surgery, Hospital Germans Trias i Pujol, Universitat Autònoma de Barcelona, Barcelona, Spain
E-mail address: pal.malagon@gmail.com (P. Malagón)

© 2022 British Association of Plastic, Reconstructive and Aesthetic Surgeons. Published by Elsevier Ltd. All rights reserved.

<https://doi.org/10.1016/j.bjps.2022.06.087>