


# Protocol for Harvest, Transport and Storage of Human Osteochondral Tissue\*

## *Protocolo para captação, transporte e preservação de tecido osteocondral humano*

Thiago Alberto Vivacqua<sup>1</sup>  Rafael Dantas Prinz<sup>1</sup> Naasson Cavanellas<sup>1</sup> João Maurício Barretto<sup>1</sup>  
Eduardo Branco de Sousa<sup>1</sup> Diego Pinheiro Aguiar<sup>1</sup>

<sup>1</sup> Research Division, Instituto Nacional de Traumatologia e Ortopedia Jamil Haddad, Rio de Janeiro, RJ, Brazil

Address for correspondence Thiago Vivacqua, MD, Instituto Nacional de Traumatologia e Ortopedia Jamil Haddad, Av. Avenida Brasil 500, Rio de Janeiro, RJ, Brazil (e-mail: drthiagovivacqua@gmail.com).

Rev Bras Ortop 2020;55(2):163–169.

### Abstract

**Objective** To elaborate a protocol for the harvest, transport, and preservation of human osteochondral tissue for use in tissue banks (TBs).

**Methods** Osteochondral fragments measuring 2 cm<sup>3</sup> of 5 corpse donors aged between 15 and 45 years old were analyzed. The samples were stored in cell preservation medium containing: human albumin, Iscove's and vancomycin preserved at 4°C. The concentration of proteoglycans in the extracellular medium was quantified by the use of Safranin-O, while tissue structural analysis was assessed by histological study with hematoxylin-eosin stained slides. The images obtained were analyzed according to the histological scores of Mankin and the score proposed by the OsteoArthritis Research Society International. The samples were analyzed with 0, 15, 30 and 45 days of preservation.

**Results** The osteochondral fragments studied showed a progressive decrease in proteoglycan concentration with increased preservation time. After 30 days of preservation, structural changes were identified with discontinuity of the cartilage surface layer. According to the results obtained by the Mankin score, there was a statistically significant difference between 15 and 30 days of tissue preservation.

**Conclusion** The protocol described defined knee transport immersed in Lactated Ringer at a controlled temperature of 10°C until its arrival at the TB. After processing, the preservation solution was composed of Iscove's serum-free cell culture medium supplemented with 10% human albumin and 100 µg/ml vancomycin. The tissue was preserved at a temperature of 4°C until the moment of transplantation characterizing the fresh preservation.

### Keywords

- ▶ cartilage, articular
- ▶ allografts
- ▶ bone transplantation
- ▶ tissue and organ harvesting
- ▶ osteochondral lesion

### Resumo

**Objetivo** Elaborar um protocolo para a captação, transporte e preservação de tecido osteocondral humano para utilização em banco de tecidos (BT).

**Métodos** Foram analisados fragmentos osteocondrais com dimensão de 2 cm<sup>3</sup> de 5 doadores cadáveres com idades entre 15 e 45 anos. As amostras foram armazenadas em meio de preservação celular contendo: albumina humana, Iscove's e vancomicina

\* Study conducted at the Instituto Nacional de Traumatologia e Ortopedia Jamil Haddad, Rio de Janeiro, RJ, Brazil.

**Palavras-chave**

- ▶ cartilagem articular
- ▶ aloenxerto
- ▶ transplante ósseo
- ▶ coleta de tecidos e órgãos
- ▶ lesão osteocondral

preservados à temperatura de 4°C. A concentração de proteoglicanos no meio extracelular foi quantificada pelo uso de Safranina-O, enquanto a análise estrutural do tecido foi avaliada através de estudo histológico com lâminas coradas em hematoxilina-eosina. As imagens obtidas foram analisadas segundo os escore histológicos de Mankin e o escore proposto pela OsteoArthritis Research Society International. As amostras foram analisadas com 0, 15, 30 e 45 dias de preservação.

**Resultados** Os fragmentos osteocondrais estudados apresentaram diminuição progressiva na concentração de proteoglicanos com o aumento do tempo de preservação. Após 30 dias de preservação, foram identificadas alterações estruturais com descontinuidade da camada superficial da cartilagem. Segundo os resultados obtidos pelo escore de Mankin, houve diferença com significância estatística entre 15 e 30 dias de preservação do tecido.

**Conclusão** O protocolo descrito definiu o transporte de joelho em bloco imerso em Ringer Lactato em temperatura controlada a 10°C até sua chegada ao BT. Após o processamento, a solução de preservação foi composta por meio de cultura celular sem soro Iscove's suplementado com albumina humana a 10% e vancomicina 100 µg/mL. O tecido foi preservado à temperatura de 4°C até o momento do transplante caracterizando a preservação a fresco.

**Introduction**

Osteochondral allograft transplantation (OAT), represents the only treatment option capable of restoring bone stock and restoring joint surface with hyaline cartilage after deep synovial joint damage.<sup>1,2</sup> The main indication for OAT is the presence of focal osteochondral lesion >2.0 cm<sup>2</sup> associated with painful symptoms in the load-bearing joints.<sup>1-4</sup> Preservation of human osteochondral tissue is a key factor in OAT success. Tissue storage time, as well as the preservation means used, are related to chondrocyte viability maintenance after the procedure.<sup>1,5</sup>

The 4°C temperature is the most commonly used for preserving osteochondral tissue in humans or animal models.<sup>6</sup> Tissue cooling below the average body temperature of 37°C induces a reduction in chondrocyte cellular metabolism, leading to lower consumption of nutrients provided by the preservation medium used.<sup>7</sup> To date, there is no consensus in the literature regarding the standardization of a protocol for the harvest, transport and preservation of osteochondral tissue in tissue banks (TBs), either national or in those located in other countries in the Americas and Europe. The aim of the present study was to develop a protocol for the harvesting, transport and preservation of human osteochondral tissue for use in TBs.

**Material and Methods****Selection of Donors**

The study population consisted of 5 musculoskeletal tissues from corpse donors (CDs) from June 2015 to December 2016 that met the criteria for organ donation of the National Transplant System (SNT, in the Portuguese acronym), according to the rules published by the Ministry of Health (MS, in the Portuguese acronym) Ordinance n° 2.600 published on

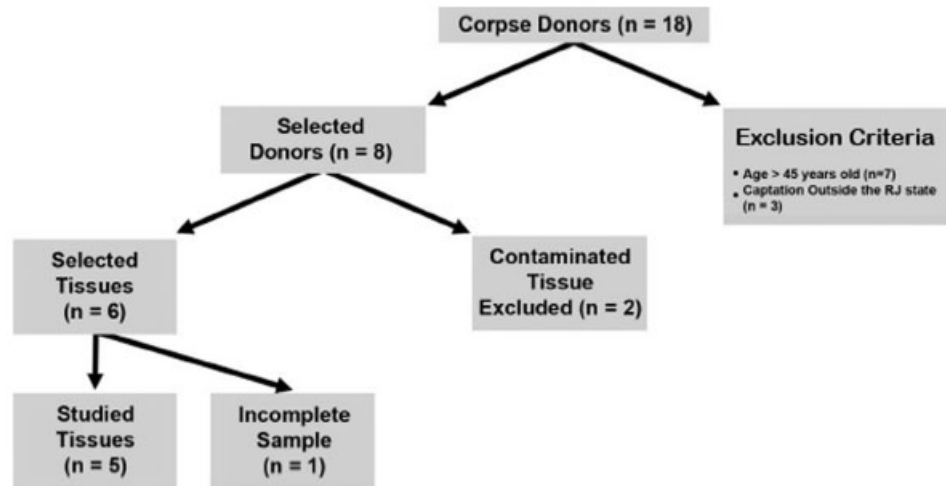
October 21, 2009. After approval by the Institutional Research Ethics Committee (CAAE 45288015.7.0000.5273), CDs aged between 15 and 45 years old, without history of trauma, surgery or previous knee joint infection, were included in the study, selected for harvesting and removal of osteochondral fragments. The collected joint was removed in its entirety, and taken to the TB, where it was processed and submitted to visual evaluation, being excluded in case of any articular cartilage injury. Cadaveric donors from outside the state of Rio de Janeiro were also excluded due to the long-lasting travel time between the harvesting site and the headquarters of the TB. Finally, the knees of five CDs were selected for the research (► **Figure 1**).

**Harvesting and Transport Protocol**

After median knee incision and subcutaneous dissection, femoral osteotomies were performed 2.0 cm above the superior pole of the patella, and tibial, 5 cm distal to the tibial tubercle, with the aid of a surgical oscillating saw, without opening the knee joint capsule. The joint was immersed in Ringer Lactate, vacuum packaged, and stored in a thermal flask at 4°C, controlled by a local thermostat until arrival at the TB (► **Figure 2**).

**Human Osteochondral Tissue Processing Protocol**

Tissue processing was performed by a medical staff member of the research team in an ISO 5-class room located within the TB. Eight 2 × 3 cm<sup>2</sup> fragments were collected by CD, for histological analysis, which were preserved at 4°C. The preservation medium used was composed by cell culture medium without Iscove's serum (Thermo Fischer, Waltham, MA, USA) supplemented with 10% human albumin and vancomycin 100 µg/mL. Tissues were subjected to analysis on the harvesting day, defined as day zero (d0), and after 15 (d15), 30 (d30) and 45 days (d45) of preservation



**Fig. 1** Corpse donor selection flowchart for research. CD (corpse donor).

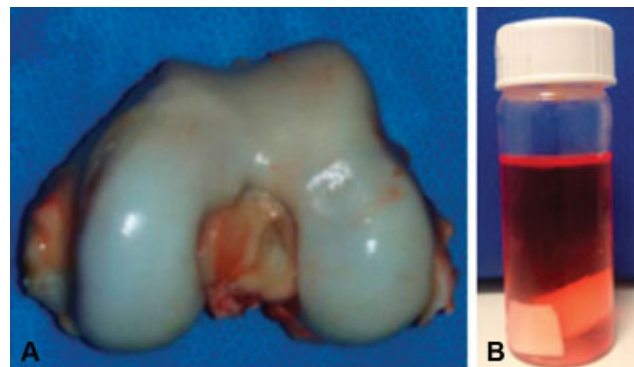


**Fig. 2** Thermal flask for transporting osteochondral tissue (A). Temperature control thermometer (B). Source: Personal Archive.

(► **Figure 3**). Tissue fragments were also sent for culture in the microbiology laboratory of the institution to exclude infection.

### Tissue Analysis Protocol

The osteochondral fragments were submitted to histological sections and stained by hematoxylin and eosin (H&E) technique for global tissue analysis, and by Safranin O (SO) for glycosaminoglycan deposition evaluation. The slides were analyzed under an optical microscope and photographed to record the results at 100x magnification. The generated images were named alphanumerically, so that the letter indicated the preservation time of the tissue, and the number indicated the donor, so that the evaluators were blinded to the preservation time and the CD. The evaluators received the images obtained in an electronic storage device, and the application forms of the two selected scores for the research.



**Fig. 3** Methodology of preparation of osteochondral fragments (OF) for tissue analysis. Distal femoral joint surface selected for OF removal and histological analysis (A). The fragments were kept in the preservation medium at 4°C. (B). Sample Evaluation Period (C). D (day). Source: Personal Archive.

We used the modified Mankin score,<sup>8</sup> whose score ranges from 0 to 14 points, and the score described by the OsteoArthritis Research Society International (OARSI),<sup>9</sup> which quantifies the changes related to synovial cartilage degeneration, graduating them from 0 to 6.

### Analysis of the Results

The results obtained were tabulated in a Microsoft Excel (Microsoft Corporation, Redmond, WA, USA) spreadsheet for further statistical analysis. The analysis of the present study was formed by the scores obtained from the visual evaluation of the osteochondral fragments in the 4 evaluation moments (d0, d15, d30, d45) according to the 2 previously selected scores. In all, 38 evaluations were performed, which make up the database dimension of the present study. One assessment was lost regarding the CD 388 in time d0. The collected data were analyzed by the IBM SPSS Statistics for Windows, Version 22.0 (IBM Corp. Armonk, NY, USA). The graphics were built in the Microsoft Excel 2011 software.

For sample characterization and descriptive analysis of the variables, given the qualitative nature of the scores, the mean

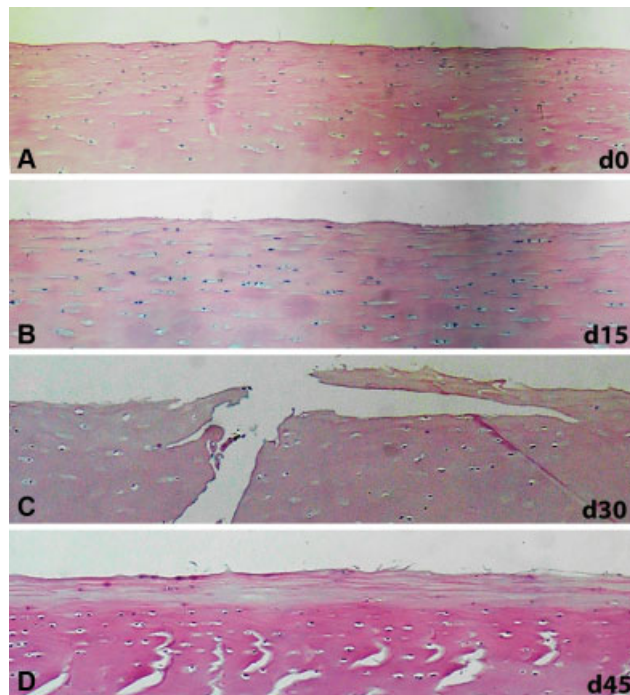
and mean-based statistics could not be calculated; thus, the data were synthesized by means of relative frequency distributions, and descriptive statistics as median, minimum and maximum. Following the nonparametric approach of analysis, given the ordinal qualitative nature of the scores, the significance of the temporal evolution of a score was assessed by the Wilcoxon test, comparing the scores of one assessment with the respective scores of the previous assessment. All of the comparisons were performed considering a maximum significance level of 5% (0.05), that is, the following decision rule was adopted in the tests: rejection of the null hypothesis whenever the p-value associated with the test was  $< 0.05$ .

## Results

### Histological Evaluation

Sections stained by H&E of the tissue from the harvesting day (d0), and from the 15<sup>th</sup> day of preservation (d15), showed no structural changes in the superficial layer of the articular cartilage (►Figure 4A-B). However, in samples evaluated after 30 days (d30), and after 45 days (d45) of preservation, changes were identified in the superficial layer of the cartilage, such as loss of continuity and presence of cracks in the articular surface. (►Figure 4C-D).

When histologically evaluating the intermediate cartilage region by H&E staining, no structural changes were observed in the four evaluation moments. The deep cartilage layer as



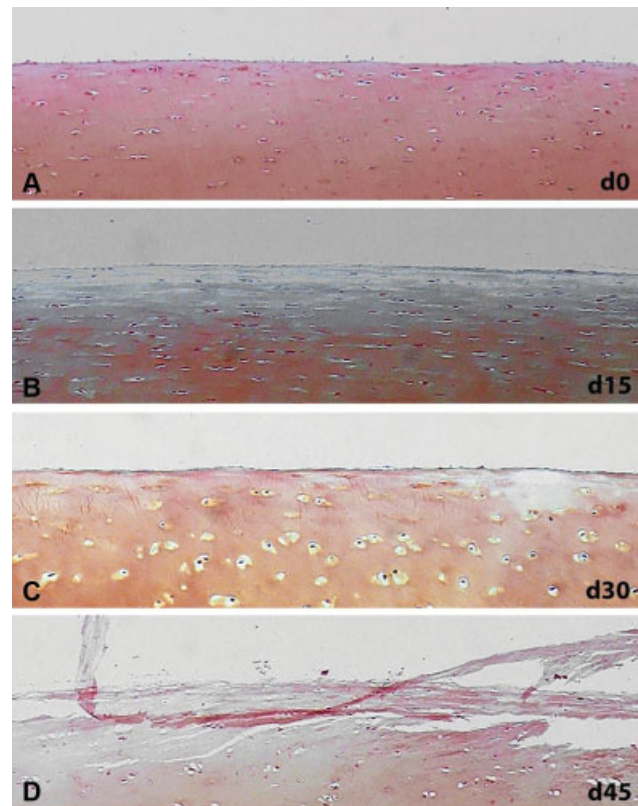
**Fig. 4** Photomicrograph of the preserved superficial cartilage layer at 4°C stained with hematoxylin and eosin (H&E). H&E-stained histological sections of osteochondral fragment obtained on the day of tissue harvesting (A), histological section of osteochondral fragment after 15 days of preservation, d15 (B), histological section of osteochondral fragment after 30 days of preservation, d30 (C) and histological section of osteochondral fragment after 45 days of preservation, d45 (D).

well as the subchondral bone plate remained preserved throughout the preservation period analyzed.

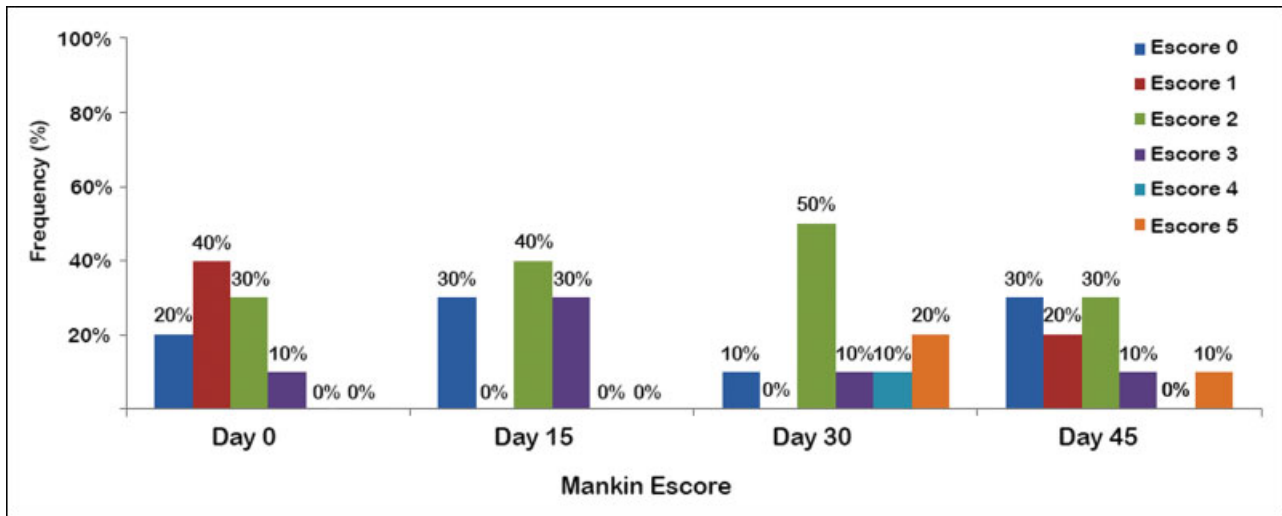
Analysis of histological sections stained with SO after 15 days of preservation (d15) showed a decrease in the concentration of proteoglycans in the peripheral portion of the superficial layer when compared with the samples in d0. After 30 days of preservation (d30), there was a decrease in proteoglycan concentration in the superficial cartilage layer of the analyzed osteochondral fragment (OF). Finally, after 45 days of preservation (d45), structural diffuse lesions in the superficial layer of cartilage were observed, associated with decrease in concentration of proteoglycans (►Figure 5). Histological analysis after SO staining did not identify a decrease in proteoglycan concentration in the intermediate cartilage layer, nor in the deep layer, in the four evaluation times.

### Result of Histological Scores

The frequency distribution of the results obtained according to the Mankin score is presented in ►Figure 6. The highest score obtained was five points, regardless of the period analyzed. After 15 days of preservation, 100% of the evaluated slides obtained 3 points out of the 14 possible points, showing good results regarding the tissue alterations



**Fig. 5** Photomicrograph of the superficial cartilage layer preserved at 4°C and stained with Safranin O (SO). Histological section stained with SO from osteochondral fragment obtained on the day of tissue harvest, d0 (A), histological section of osteochondral fragment after 15 days of preservation, d15 (B), histological section of osteochondral fragment after 30 days of preservation, d30 (C) and histological section of osteochondral fragment after 45 days of preservation, d45 (D).



**Fig. 6** Frequencies of results according to the Mankin histological score. The maximum score obtained on the Mankin score was 5 points.

analyzed by the score. After 45 days of preservation, the results were similar, with 90% of the sections evaluated adding up to 3 points.

At 30 days of preservation, the samples had a statistically significant difference in relation to the 15-days-preserved tissue, suggesting worse quality of osteochondral tissue according to the criteria used by the Mankin score.

The frequency distribution obtained according to the OARSI score is presented in **Figure 7**. In the period defined as d0, 30% of the evaluated slides presented histological alterations even before the samples were submitted to preservation at 4°C. The alterations described were restricted to the superficial layer of the articular cartilage, especially the decrease of proteoglycan concentration. At 15 days of preservation, 80% of the samples were classified as type 0 or 1, containing only superficial changes in the tissue according to the description of the score used. After 30 days of preservation, 70% of the samples were classified as type 2, containing structural changes in the superficial layer, as well as a decrease in proteoglycan concentration. No tissue sam-

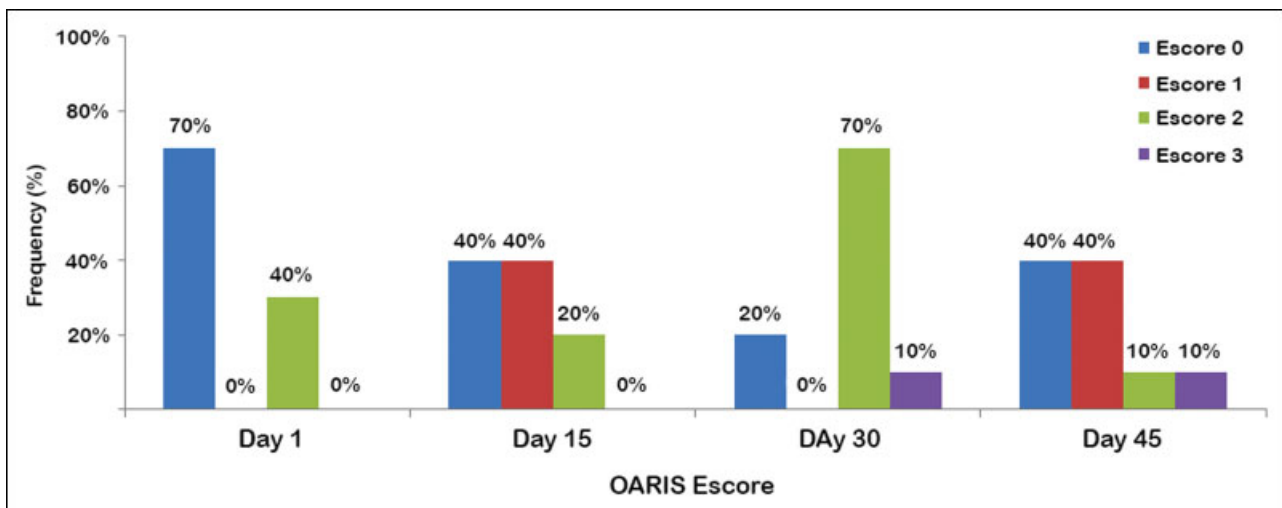
ple analyzed showed changes related to articular cartilage degeneration, classified as type 4, 5 or 6 according to the OARSI score.

According to the histological evaluation assessed by the OARSI score, no statistically significant variations were observed between the results obtained in the different periods of osteochondral tissue evaluation.

### Discussion

Osteochondral allograft transplantation represents a biological method capable of providing hyaline cartilage for the treatment of osteochondral lesions thicker than 2cm<sup>2</sup>.<sup>1,2,4,10</sup> Cell viability of donor tissue at the time of surgery is an indispensable factor for successful treatment. The absence of a protocol defined in the literature led us to the need to develop a proper methodology for harvest, transport and storage of human osteochondral tissue.

Several factors influence the preservation of human osteochondral fragments, aiming at increasing the number



**Fig. 7** Osteoarthritis Research Society International. Abbreviations: OARSI, Osteoarthritis Research Society International.

of viable chondrocytes as well as the longer period of tissue storage. Thus, temperature and storage medium are variables widely discussed in the literature.

Regarding temperature, the discussion involves preservation at 4°C, 25°C, 37°C or cryopreservation.<sup>11–17</sup> The increase in preservation temperature is associated with a higher nutrient consumption offered by the preservation medium, there is the need for periodic change of medium, exposing the tissue to the risk of contamination and increasing the cost of storage.<sup>12</sup> Cook et al<sup>17</sup> were able to prove up to 89.8% of viable chondrocytes in canine osteochondral fragments using the Missouri Osteochondral Allograft Preservation System (MOPS) at 25°C after 60 days of tissue preservation; however, fresh preservation at 4°C remains the gold standard in the literature.

In a preliminary study, performed with surgical disposal material, our group showed that refrigeration at 4°C offers better preservation capacity of osteochondral fragments than at 37°C for up to 14 days.<sup>18</sup> For this reason, in the current study with young CD tissues, we kept the option of cooling the fragments to 4°C. Our results confirm previous findings that the temperature of 4°C is adequate for allograft preservation.

Several supplemented media were evaluated for their benefits on the viability of preserved cartilaginous tissue, including dexamethasone-associated media,<sup>19</sup> hyaluronic acid,<sup>20</sup> allogeneic serum,<sup>21</sup> or tumor necrosis factor inhibitor  $\alpha$ <sup>19</sup> and the cellular apoptosis inhibiting agent,<sup>22</sup> among others. The divergence in the literature between the means used, the absence of *in vivo* research, and the high cost of the preservation methods evaluated, make it difficult to decide on the best supplement to use in conjunction with preservation media to improve the quality of tissue stored for transplantation. Pearsall et al<sup>7</sup> determined that human osteochondral allografts could be kept viable for up to 44 days with an average viability of 67% when kept in a storage medium supplemented with antibiotic, glutamine and 10% fetal bovine serum, without growth factors. Another study concluded that allografts stored in antibiotic Ringer lactate solution could be implanted within 7 days, while storage in serum-free medium would increase this time to 2 weeks.<sup>17</sup> Considering the findings of these studies, we opted to include in our protocol transporting the fragments in Ringer lactate, because it is cheaper and affordable in any hospital where the harvest of tissue is made, leaving the preservation in supplemented-Iscove's medium, more expensive and dependent of structure for preparation, for storage after processing by the TB.

The method described for the transport of osteochondral tissue kept it at the appropriate temperature (4/10°C) until the beginning of the tissue processing procedure. Preservation of osteochondral tissue at 4°C was able to maintain the structural characteristics of the articular cartilage layers for up to 15 days of storage in cell culture medium without supplementation with Iscove's serum, supplemented with 10% human albumin and vancomycin 100 µg/mL.

Histological evaluation using H&E-stained slides demonstrated preservation of articular cartilage layers removed on

the day of tissue collection (d0), being these defined as control group. After 30 and 45 days of preservation, there were changes in the superficial layer of the tissue, demonstrating that this region is subject to changes related to the preservation time. The integrity of the superficial portion of the cartilaginous tissue is of utmost importance for load absorption and distribution. Lesions in the superficial cartilage layer are related to alteration in tissue permeability, favoring the penetration of synovial fluid, initiating the process of joint degeneration.<sup>23</sup> The layers of intermediate, deep cartilage and calcified cartilage did not change during the period evaluated. These findings describe a typical pattern of injury related to the preservation of human osteochondral tissue, in which only the superficial layer of cartilage presented discontinuities and delamination.

Visual evaluation of SO-stained slides showed a gradual decrease in proteoglycan concentration in the extracellular matrix along with the increase of preservation time in the studied samples. In 30% of the samples there was a decrease in the concentration of proteoglycans in the superficial layer of the tissue soon after harvesting (d0). This finding suggests that alterations in chondrocyte metabolism may exist even in physiologically young patients without lesions described in the articular cartilage. After 30 days of preservation, all of the analyzed samples showed a decrease in proteoglycan concentration in the superficial layer. The remaining articular cartilage layers had their proteoglycan concentration preserved after the entire evaluation period (45 days). Our results confirm the need for osteochondral tissue transplantation with the shortest possible preservation time, because they describe the structural alteration after fresh OF preservation, although restricted to the superficial layer of the articular cartilage. Structural changes in the superficial layer allow the flow of synovial fluid, leading to the formation of subchondral cysts, thus initiating the process of joint degeneration.<sup>21</sup>

Our work had some limitations. First, there were no quantitative analyses of cell viability of the tissue studied. Second, the histological evaluation methodology used was based on scores created for the study of cartilaginous tissue with degenerative changes. There is no histological score in the literature to evaluate cadaveric human osteochondral tissue. Finally, the data generated are of a qualitative nature and may be subject to interobserver variations.

## Conclusion

The described protocol defined the transport of a knee in a block immersed in Ringer Lactate at 10°C controlled temperature until its arrival at the TB. After processing, the preservative solution was composed of cell culture medium without Iscove's serum, supplemented with 10% human albumin and vancomycin 100 µg/mL. Tissue was preserved at 4°C until transplantation, characterizing fresh preservation.

## Conflict of Interests

The authors have no conflict of interests to declare.

## References

- 1 Zouzas IC, Bugbee WD. Osteochondral Allograft Transplantation in the Knee. *Sports Med Arthrosc Rev* 2016;24(02):79–84
- 2 Dhollander A, Verdonk P, Tirico LE, Gomoll AH. Treatment of failed cartilage repair: State of the Art. In: *Journal of ISAKOS: Joint Disorders & Orthopaedic Sports Medicine*, p. jisakos. 2016-000057.
- 3 LaPrade RF, Botker J, Herzog M, Agel J. Refrigerated osteoarticular allografts to treat articular cartilage defects of the femoral condyles. A prospective outcomes study. *J Bone Joint Surg Am* 2009; 91(04):805–811
- 4 Gracitelli GC, Moraes VY, Franciozi CE, Luzo MV, Belloti JC. Surgical interventions (microfracture, drilling, mosaicplasty, and allograft transplantation) for treating isolated cartilage defects of the knee in adults. *Cochrane Database Syst Rev* 2016; 9:CD010675
- 5 De Caro F, Bisicchia S, Amendola A, Ding L. Large fresh osteochondral allografts of the knee: a systematic clinical and basic science review of the literature. *Arthroscopy* 2015;31(04):757–765
- 6 Sherman SL, Garrity J, Bauer K, Cook J, Stannard J, Bugbee W. Fresh osteochondral allograft transplantation for the knee: current concepts. *J Am Acad Orthop Surg* 2014;22(02):121–133
- 7 Pearsall AW IV, Tucker JA, Hester RB, Heitman RJ. Chondrocyte viability in refrigerated osteochondral allografts used for transplantation within the knee. *Am J Sports Med* 2004;32(01): 125–131
- 8 Mankin HJ, Dorfman H, Lippiello L, Zarins A. Biochemical and metabolic abnormalities in articular cartilage from osteoarthritic human hips. II. Correlation of morphology with biochemical and metabolic data. *J Bone Joint Surg Am* 1971;53(03): 523–537
- 9 Pritzker KP, Gay S, Jimenez SA, et al. Osteoarthritis cartilage histopathology: grading and staging. *Osteoarthritis Cartilage* 2006;14(01):13–29
- 10 Richter DL, Schenck RC Jr, Wascher DC, Treme G. Knee articular cartilage repair and restoration techniques: a review of the literature. *Sports Health* 2016;8(02):153–160
- 11 Raz G, Safir OA, Backstein DJ, Lee PT, Gross AE. Distal Femoral Fresh Osteochondral Allografts: Follow-up at a Mean of Twenty-two Years. *J Bone Joint Surg Am* 2014;96(13):1101–1107
- 12 Williams RJ III, Dreese JC, Chen CT. Chondrocyte survival and material properties of hypothermally stored cartilage: an evaluation of tissue used for osteochondral allograft transplantation. *Am J Sports Med* 2004;32(01):132–139
- 13 Ball ST, Amiel D, Williams SK, et al. The effects of storage on fresh human osteochondral allografts. *Clin Orthop Relat Res* 2004; (418):246–252
- 14 Garrity JT, Stoker AM, Sims HJ, Cook JL. Improved osteochondral allograft preservation using serum-free media at body temperature. *Am J Sports Med* 2012;40(11):2542–2548
- 15 Pallante AL, Bae WC, Chen AC, Görtz S, Bugbee WD, Sah RL. Chondrocyte viability is higher after prolonged storage at 37 degrees C than at 4 degrees C for osteochondral grafts. *Am J Sports Med* 2009;37(Suppl 1):24S–32S
- 16 Xia Z, Murray D, Hulley PA, Triffitt JT, Price AJ. The viability and proliferation of human chondrocytes following cryopreservation. *J Bone Joint Surg Br* 2008;90(09):1245–1248
- 17 Cook JL, Stoker AM, Stannard JP, et al. A novel system improves preservation of osteochondral allografts. *Clin Orthop Relat Res* 2014;472(11):3404–3414
- 18 de Sousa EB, Aguiar DP, Barcelos JF, Duarte ME, Olej B. Approaches to preserve human osteochondral allografts. *Cell Tissue Bank* 2015;16(03):425–431
- 19 Bian L, Stoker AM, Marberry KM, Ateshian GA, Cook JL, Hung CT. Effects of dexamethasone on the functional properties of cartilage explants during long-term culture. *Am J Sports Med* 2010;38(01): 78–85
- 20 Yamada T, Uchida K, Onuma K, et al. Hyaluronic Acid (800 kDa) Supplementation of University of Wisconsin Solution Improves Viability of Osteochondral Grafts and Reduces Matrix Metalloproteinase Expression during Cold Preservation. *ScientificWorldJournal* 2015;2015:631369
- 21 Onuma K, Urabe K, Naruse K, Uchida K, Itoman M. Allogenic serum improves cold preservation of osteochondral allografts. *Clin Orthop Relat Res* 2012;470(10):2905–2914
- 22 Linn MS, Chase DC, Healey RM, Harwood FL, Bugbee WD, Amiel D. Etanercept enhances preservation of osteochondral allograft viability. *Am J Sports Med* 2011;39(07):1494–1499
- 23 McCulloch K, Litherland GJ, Rai TS. Cellular senescence in osteoarthritis pathology. *Aging Cell* 2017;16(02):210–218