

The Effect of Orthognathic Surgery on Osteoprotegerin as Immunological Caliper of Bone Healing

Sara Soliman*, Mamdouh Ahmed

Oral and Maxillofacial Surgery Department, Faculty of Dentistry, Cairo University, Cairo, Egypt

Citation: Soliman S, Ahmed M. The Effect of Orthognathic Surgery on Osteoprotegerin as Immunological Caliper of Bone Healing. Open Access Maced J Med Sci. 2016 Dec 15; 4(4):705-708. <https://doi.org/10.3889/oamjms.2016.123>

Keywords: Cytokine; osteoprotegerin (OPG); bone remodelling; fracture healing; orthognathic surgery.

***Correspondence:** Sara Soliman. Oral and Maxillofacial Surgery Department, Faculty of Dentistry, Cairo University, Cairo, Egypt. E-mail: sarasaid009@gmail.com

Received: 21-Oct-2016; **Revised:** 29-Oct-2016; **Accepted:** 30-Oct-2016; **Online first:** 22-Nov-2016

Copyright: © 2016 Sara Soliman, Mamdouh Ahmed. This is an open-access article distributed under the terms of the Creative Commons Attribution-NonCommercial 4.0 International License (CC BY-NC 4.0).

Funding: This research did not receive any financial support.

Competing Interests: The authors have declared that no competing interests exist.

BACKGROUND: Osteoprotegerin (OPG) is considered to be the cytokine that plays an important role in the healing process. OPG regulates bone cell biology, osteoblast–osteoclast, bone-immune cross-talk and maintenance of bone mass. It plays an important role in the development, induction, and repair of bone. Orthognathic surgery as multiples segmental osteotomies has been taken as a model surgery to assess the changes in osteoprotegerin levels in the post-operative bone healing period.

AIM: The aim of the study was to evaluate OPG as immunological caliper of bone healing.

MATERIAL AND METHODS: OPG was evaluated in nine patients seeking orthognathic surgery. Patients were examined and checked to be medically and immunologically free prior to surgery. Blood samples were collected immediate pre-operative as control group and for six weeks post-operative as study group.

RESULTS: Data were collected from nine consecutive patients. The results showed higher levels of OPG. it showed significant increase in the immediate post-operative value ($p = 0.001$) which started to increase gradually during the six weeks ($p < 0.001$).

CONCLUSIONS: Significant higher levels of OPG during the healing period of orthognathic surgery suggest the its use as immunological caliper of bone healing.

Abstract

Introduction

Osteoprotegerin (OPG) is an antiresorptive cytokine and an osteoblast-secreted decoy receptor; it is considered a key regulator of osteoclastogenesis. It specifically binds to osteoclast differentiation factor and inhibits osteoclast maturation. OPG is involved in bone remodelling and in its healing system since it regulates bone cell biology, osteoblast-osteoclast, immune cross-talk and maintenance of bone mass [1].

The RANKL-RANK-OPG cytokine system is one of the principal mediators in the maintenance of bone cell function and activation of bone remodelling by the Basic Multicellular Unit (BMU) which carries out remodelling. The balance of the trimolecular control factor complex composed of OPG, RANKL { receptor activator of nuclear factor kappa beta (NFkB ligand)}, It is also commonly referred to as osteoprotegerin ligand (OPGL) or osteoclast differentiation factor

(ODF) and RANK (receptor activator of NFkB) maintains physiologic bone remodeling and renewal of the bone matrix [2, 3].

Osteosynthesis of the bone matrix is achieved by osteoblasts and coordinated with resorption of extracellular bone matrix performed by osteoclasts. The mismatch between the activities of osteoblasts and osteoclasts has immunopathologic implications associated with either a decrease or increase of bone mass mineral density. The OPG–RANKL complex counterbalances the effect of the RANK–RANKL complex, thus playing the most important role in bone homeostasis [4, 5]. Circulating levels of OPG were found to be a predictor of delayed bone healing and non-union of bone suggesting the active relationship of its circulating levels to healing process. OPG was found to be of value as the prognostic marker of bone activity, wound healing activity and the therapeutic progress following surgery [6-8]. Orthognathic surgery as an elective surgery is considered the most convenient in the maxillofacial surgeries to study the

immunological effect of surgical trauma on patients and changes detected in OPG levels. Patients could be carefully chosen intact preoperatively and not suffering from any systemic or immunological diseases, as these factors will affect the preoperative immunological status of the patient.

Patients and Methods

The study was conducted on nine patients suffering from dentofacial deformity and seeking correction by orthodontic-orthognathic surgery. The patients were chosen randomly from those attending the outpatient clinic of Oral and Maxillofacial Surgery Department at Faculty of Oral and Dental Medicine Cairo University. Eight patients had undergone bimaxillary osteotomy and case number nine had mandibular surgery only. All patients were healthy not suffering from any systemic or bone diseases and the age range between 16-30.

Each patient was subjected to the following: clinical diagnosis (history, clinical evaluation, photographs and radiographs), pre-operative orthodontic treatment and patient preparation before surgery. All patients were informed about the surgical procedure and the schedule of blood samples and an informed consent was assigned. OPG levels were evaluated by taking blood samples according to the following schedule; immediate preoperative, immediate post-operative, three days, one week, two weeks, four weeks and six weeks post-operative. A Serum separator tube (SST) was used to allow samples to clot for two hours at room temperature or overnight at 4°C before centrifugation for 15 minutes at 1000 × g. Aliquot was removed immediately and the samples stored at -80°C. Human Osteoprotegerin (OPG) ELISA Kit (catalogue noCSB-E04692h was used to detect OPG levels. The assay employed the quantitative sandwich enzyme immunoassay technique with a detection range 0.312 ng/ml-20 ng/ml.

Statistical analysis

Data were fed to the computer and analysed using IBM SPSS software package version 20.0 [9]. Quantitative data were described using range (minimum and maximum) mean, standard deviation and median [10].

Results

The post-operative course was eventful

expect; limited mouth opening was seen in the patient with single jaw surgery (BSSO) and managed by physical therapy. One case showed periodontal abscess in the lower right molars; it appeared one-month post-operatively and treated in a routine manner. All patients experienced periods of tolerable pain that decreased gradually after surgery and remained from 3 to 4 weeks. Oedema was observed in all patients and resolved gradually after 1 to three months (Fig. 1).

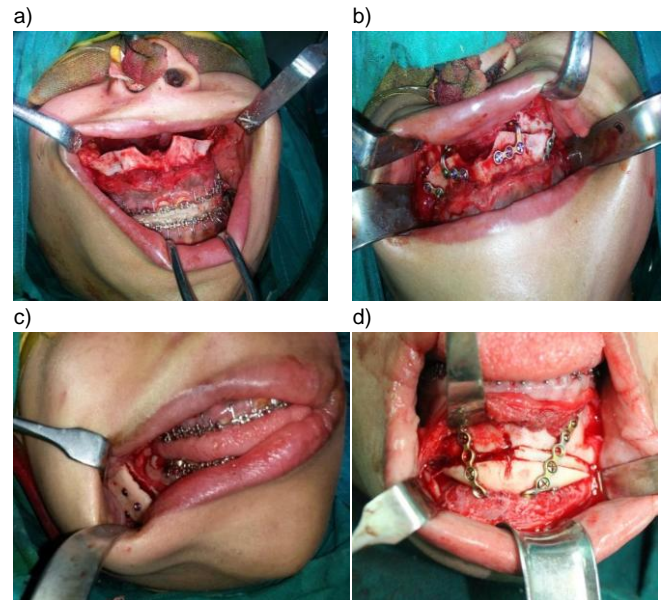


Figure 1: Fixation of case number 8. a) Maxilla and mandible wired together in maxillomandibular fixation. b) Stabilisation of the maxilla by two plates on each side, one at piriform region and one at the maxillary buttress. c) Proximal segment passively seated and fixed to the distal segment by 3 screws. d) Bone graft and rigid fixation of sliding genioplasty

The changes in OPG in the whole group in the predetermined period immediate postoperative, after three days, after one week, two weeks, four weeks and six weeks in comparison to the preoperative level was investigated.

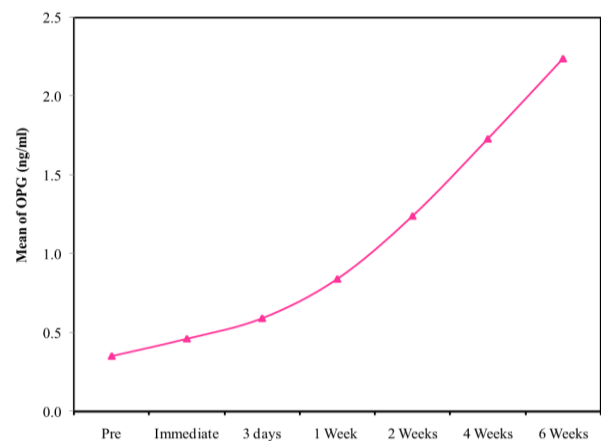


Figure 2: Comparison between the different periods according to OPG ng/ml

It was detected that there is a significant increase in the level of OPG immediate post-operative at ($p = 0.001$). the concentration of OPG was started to increase gradually and it was significant at the following periods (3 days post-operative, one week, two weeks, four weeks and six weeks post-operative) at p -value < 0.001 . The increase in OPG level in six weeks postoperatively was found to be significant regarding the immediate post-operative value $p < 0.001$ (Fig. 2).

Discussion

Osteoprotegerin (OPG) has been chosen in this study as the new most recent calliper. It is sensitive to hard tissue changes and a key regulator of both physiologic and pathologic osteoclast formation that regulates bone resorption and remodelling. An elevated level of serum OPG was connected with high bone turnover and administration to humans has also demonstrated marked decreases in bone resorption. These opinions were supported by the findings reported from several studies.

In the present study Osteoprotegerin (OPG) showed a significant increase throughout the post-operative period in a steady way till six weeks post-operative. This finding is concordant with Giganti MG et al, [11] and Lee et al, [12] as OPG showed significant increase immediately after fracture. The results of the present study are not in agreement with Clombini et al, [13] he investigated the role of OPG in humerus fracture healing at different time points before and after surgery and observed higher OPG, but it was not significant.

OPG can be used as marker for post-operative complications, it is not bone-specific as elevated levels may be accompanied by post-operative complications, this opinion was supported by several studies [14-16]. Post-operative pain could be attributed to the elevated level of OPG as it is known to be involved in a complex cytokine network that causes immune activation and may contribute to nociceptive sensitization. This was in agreement with the findings that showed the relation of the significant increase OPG and the incidence of complex regional pain syndrome (CRPS) [17].

The assessment of OPG in the current study was planned for a period of six weeks post-operatively. The follow-up period of OPG was concordant with previous studies, [18-20] OPG was assessed for 12 weeks and the increase was found to be significant at 4 weeks post-operative and turned to be not significant at 8 and 12 weeks post-operative. For the previous finding six weeks follow-up period is an appropriate duration. The significant increase without remission in the six weeks post-operative

period was attributed to the process of bone healing following the osteotomies. Bone healing begins immediately after fracture or osteotomy by hematoma formation and release of cytokines, mesenchymal cells and growth factor, followed by the extended period of bone remodelling.

Orthognathic surgery has been selected as a model surgery in this study. Patients are young, intact, non-traumatized and immunocompetent. Candidates for orthognathic surgery are considered systemically and immunologically free, so for the reliability of the results pre-operative levels of the two callipers are considered control. This category of surgery being an elective procedure, so blood loss is easily estimated, operative time pre-determined and the surgical trauma is the planned and any adverse effect will be attributed to the effect of surgery. Patients incorporated in the present study were demanding surgery and has no psychological hindrance like patients of trauma or neoplasm. Recalls for follow-up was accomplished easily as orthognathic patients are committed to the surgeon and orthodontist.

Significant higher levels of OPG following orthognathic surgery suggest the use of OPG as a good calliper for the assessment of bone healing and regeneration of hard tissue. Further investigations with wide scale sample and for the extended period of time is needed to emphasise the application of OPG as a pre and postoperative immunological calliper predicting the post-operative healing course.

References

1. Kong YY, Boyle WJ, Penninger JM. Osteoprotegerin ligand: a regulator of immune responses and bone physiology. *Immunol Today*. 2000; 21: 495–502. [https://doi.org/10.1016/S0167-5699\(00\)01718-7](https://doi.org/10.1016/S0167-5699(00)01718-7)
2. Wan M, Shi X, Feng X, Cao X. Transcriptional Mechanisms of Bone Morphogenetic Protein-induced Osteoprotegerin Gene Expression. *J Biol Chem*. 2001; 276: 10119–25. <https://doi.org/10.1074/jbc.M006918200> PMID:11139569
3. Fahrleitner A, Prenner G, Leb G, Tscheliessnigg KH, Piswanger-Sölkner C, Obermayer-Pietsch B, et al. Serum osteoprotegerin is a major determinant of bone density development and prevalent vertebral fracture status following cardiac transplantation. *J Inter Bone Miner Soc*. 2003; 32: 96-106. [https://doi.org/10.1016/s8756-3282\(02\)00926-2](https://doi.org/10.1016/s8756-3282(02)00926-2)
4. Ryser MD, Qu Y, Komarova SV. Osteoprotegerin in Bone Metastases: Mathematical Solution to the Puzzle. *PLOS Comput Biol*. 2012; 8: e1002703. <https://doi.org/10.1371/journal.pcbi.1002703> PMID:23093918 PMID:PMC3475686
5. Kohli SS, Kohli VS. Role of RANKL–RANK/osteoprotegerin molecular complex in bone remodeling and its immunopathologic implications. *Indian J Endocrinol Metab*. 2011; 15: 175-81. <https://doi.org/10.4103/2230-8210.83401> PMID:21897893 PMID:PMC3156536
6. Rogers A, Eastell R. Circulating osteoprotegerin and receptor activator for nuclear factor kappa B ligand: clinical utility in metabolic bone disease assessment. *J Clin Endocrinol Metab*. 2005; 90: 6323–31. <https://doi.org/10.1210/jc.2005-0794> PMID:16105967

7. Theoleyre S, Wittrant Y, Tat SK, Fortun Y, Redini F, Heymann D. The molecular triad OPG/RANK/RANKL: involvement in the orchestration of pathophysiological bone remodelling. *Cytokine Growth Factor Rev.* 2004; 15: 457–75. <https://doi.org/10.1016/j.cytogfr.2004.06.004> PMID:15561602
8. Hofbauer LC, Schoppet M. Serum measurement of osteoprotegerin-clinical relevance and potential applications. *Eur J Endocrinol.* 2001; 145: 681–3. <https://doi.org/10.1530/eje.0.1450681>
9. Kotz S, Balakrishnan N, Read CB, Vidakovic B. *Encyclopedia of statistical sciences.* 2nd ed. Hoboken, NJ: Wiley-Interscience, 2006.
10. Kirkpatrick LA, Feeney BC. *A simple guide to IBM SPSS statistics for version 20.0.* Student ed. Belmont, Calif.: Wadsworth, Cengage Learning, 2013.
11. Giganti MG, Liuni F, Celi M, Gasbarra E, Zenobi R, Tresoldi I, et al. Changes in serum levels of TNF-alpha, IL-6, OPG, RANKL and their correlation with radiographic and clinical assessment in fragility fractures and high energy fractures. *J Biol Regul Homeost Agents.* 2012; 26: 671–80. PMID:23241117
12. Lee JS, Ryu CH, Moon NH, Kim SJ, Park SY, Suh KT. Changes in serum levels of receptor activator of nuclear factor-kB ligand, osteoprotegerin, IL-6 and TNF in patients with a concomitant head injury and fracture. *Arch Orthop Trauma Surg.* 2009; 129: 711-8. <https://doi.org/10.1007/s00402-008-0632-8> PMID:18427820
13. Colombini A, Lombardi G, Galliera E, Dogliotti G, Randelli P, Meerssemann A, et al. Plasma and drainage fluid levels of soluble receptor activator of nuclear factor-kB (sRANK), soluble receptor activator of nuclear factor-kB ligand (sRANKL) and osteoprotegerin (OPG) during proximal humerus fracture healing. *Int Orthop.* 2011; 35: 777–82. <https://doi.org/10.1007/s00264-010-1088-3> PMID:20623281 PMID:PMC3080502
20. Grzegorzewska AE, Mlot M. Serum osteoprotegerin level is lower in peritoneal dialysis patients than in hemodialysis ones. *Annal Academ medic Bialost.* 2004; 49: 193-6.
14. Freedman J, Goddard D. Elevated levels of transforming growth factor β and prostaglandin E2 in aqueous humor from patients undergoing filtration surgery for glaucoma. *Can J Ophthalmol.* 2008; 43: 3. <https://doi.org/10.3129/i08-037>
15. Krämer HH, Hofbauer LC, Szalay G, Breimhorst M, Eberle T, Zieschang K, Rauner M, Schlereth T, Schreckenberger M, Birklein F. Osteoprotegerin: A new biomarker for impaired bone metabolism in complex regional pain syndrome? *PAIN.* 2014; 155(5):889-95. <https://doi.org/10.1016/j.pain.2014.01.014> PMID:24447513
16. Pape HC, Giannoudis PV, Krettek C, Trentz O. Timing of fixation of major fractures in blunt polytrauma: role of conventional indicators in clinical decision making. *J Orthop Trauma.* 2005; 19: 551–62. <https://doi.org/10.1097/01.bot.0000161712.87129.80> PMID:16118563
17. Sen O, Gokcel A, Kizilkilic O, Erdogan B, Aydin MV, Sezgin N. The relation between serum levels of osteoprotegerin and postoperative epidural fibrosis in patients who underwent surgery for lumbar disc herniation. *Neuro Res.* 2005; 27: 452-55. <https://doi.org/10.1179/016164105X15631> PMID:15949247
18. Crottia TN, Smith MD, Findlay DM, Zreiqatd H, Ahern MJ, Weedon H, et al. Factors regulating osteoclast formation in human tissues adjacent to peri-implant bone loss: expression of receptor activator Nf κ B, RANK ligand and osteoprotegerin. *Biomater.* 2004; 25: 565–73. [https://doi.org/10.1016/S0142-9612\(03\)00556-8](https://doi.org/10.1016/S0142-9612(03)00556-8)
19. Nagasawa T, Kobayashi H, Kiji M, Aramaki M, Mahanonda R, Kojima T, et al. LPS-stimulated human gingival fibroblasts inhibit the differentiation of monocytes into osteoclasts through the production of osteoprotegerin. *Clin Exp Immunol.* 2002; 130: 338–44. <https://doi.org/10.1046/j.1365-2249.2002.01990.x> PMID:12390325 PMID:PMC1906523