

Varicella Zoster Virus Pneumonitis and Brainstem Encephalitis Without Skin Rash in an Immunocompetent Adult

Ramachandiran Nandhagopal,¹ Nelly Khmeleva,³ B. Jayakrishnan,¹ Teresa White,³ Faisal Al Azri,² Jojoy George,¹ Anna Heintzman,³ Khalfan Al Zeedy,¹ Lucy Rorke-Adams,⁵ Arunodaya R. Gujjar,¹ D. Scott Schmid,⁶ Abdullah Al-Asmi,¹ Maria A. Nagel,³ Poovathoor Chacko Jacob,¹ and Don Gilden^{3,4}

Departments of ¹Medicine and ²Radiology and Molecular Imaging, College of Medicine and Health Sciences, Muscat, Oman; Departments of ³Neurology and ⁴Microbiology, University of Colorado School of Medicine, Aurora; ⁵Department of Pathology, Children's Hospital of Philadelphia, Perelman School of Medicine at University of Pennsylvania; and ⁶Centers for Disease Control and Prevention, Atlanta, Georgia

Varicella zoster virus (VZV) pneumonitis and brainstem encephalitis developed in an immunocompetent adult without rash. Chest computed tomography exhibited nodularity; lung biopsy revealed multinucleated giant cells, Cowdry A inclusions, VZV antigen, and DNA. Varicella zoster virus central nervous system disease was verified by cerebrospinal fluid (CSF) anti-VZV IgG antibody with reduced serum/CSF ratios.

Keywords. absence of rash; brainstem encephalitis; pneumonitis; VZV.

Reactivation of varicella zoster virus (VZV) usually produces zoster (shingles), often followed by chronic pain (postherpetic neuralgia). Zoster may also be complicated by meningoencephalitis, cerebellitis, cranial nerve palsies, vasculopathy, myelopathy, and various inflammatory disorders of the eye [1], all of which may develop in the absence of rash. To our knowledge, there has been only a single report of VZV infection involving both the nervous system and viscera in the absence of rash [2].

Received 2 July 2014; accepted 7 July 2014.

Correspondence: Don Gilden, MD, Department of Neurology, University of Colorado School of Medicine, 12700 E. 19th Avenue, Box B182, Aurora, CO 80045 (don.gilden@ucdenver.edu).

Open Forum Infectious Diseases

© The Author 2014. Published by Oxford University Press on behalf of the Infectious Diseases Society of America. This is an Open Access article distributed under the terms of the Creative Commons Attribution-NonCommercial-NoDerivs licence (<http://creativecommons.org/licenses/by-nc-nd/4.0/>), which permits non-commercial reproduction and distribution of the work, in any medium, provided the original work is not altered or transformed in any way, and that the work is properly cited. For commercial re-use, please contact journals.permissions@oup.com.

DOI: 10.1093/ofid/ofu064

In this study, we describe a remarkable case of pneumonitis and brainstem encephalitis produced by VZV without rash.

CASE REPORT

A 37-year-old healthy woman in Oman with no past history of varicella or recent zoster rash presented with a 5-day history of productive cough, progressive paraparesis, urinary incontinence, lingual dysarthria, dysphagia, hiccups, and intractable vomiting. She was intubated and mechanically ventilated for 25 days. Brain magnetic resonance imaging (MRI) revealed a nonenhancing lesion in the dorsal medulla (Figure 1A and B) without diffusion restriction that was most likely inflammatory; the thoracic spinal cord MRI was normal. Chest x-ray and computed tomography (CT) scanning revealed bilateral upper lung consolidation and multiple nodules (Figure 1D and G). Diagnostic bronchial washing and sputum culture did not provide microbiological evidence for bacterial pneumonia as the cause of her lung pathology. She was treated with intravenous methylprednisolone 1 g/day for 5 days for the inflammatory brain and lung lesions, along with intravenous meropenem, 1 g 3 times daily for 3 weeks, because her intubated airway was colonized by *Pseudomonas aeruginosa*. After extubation, she was transferred to Sultan Qaboos University Hospital in Muscat, Oman for further evaluation.

On admission, positive neurological signs included gaze-evoked torsional nystagmus, a weak gag reflex, and a hypotonic paraparesis, greater on the left with an extensor plantar response. cerebrospinal fluid (CSF) contained 6 cells, all mononuclear; CSF protein and glucose were normal; CSF acid-fast staining and culture for *Mycobacterium tuberculosis*, test for cryptococcal antigen, polymerase chain reaction (PCR) for Epstein-Barr virus, cytomegalovirus, herpes simplex virus-1 and -2, varicella zoster virus (VZV), enterovirus, and mumps virus were all negative. Serum immunoglobulin (Ig)G, IgM, C3, and C4 complement were normal; infectious mononucleosis antibody was negative; α 1-antitrypsin was 3.14 g/L (normal 0.88–1.74 g/L). The vasculitis panel including antinuclear antibody, antineutrophil cytoplasmic antibody, extractable nuclear antigens, antiglomerular basement membrane antibody, anti-cardiolipin, anti- β 2 glycoprotein, and lupus anticoagulant were negative. Serum was negative for antibody to aquaporin 4 and human immunodeficiency virus-1 and -2. She was treated with intravenous Ig (75 gm over 5 days) and oral prednisolone (40 mg/day) for the initial 13 weeks, which was tapered in the next 8 weeks for the inflammatory lung and brainstem disease, after which she received inhalational fluticasone (250 μ g/dose)

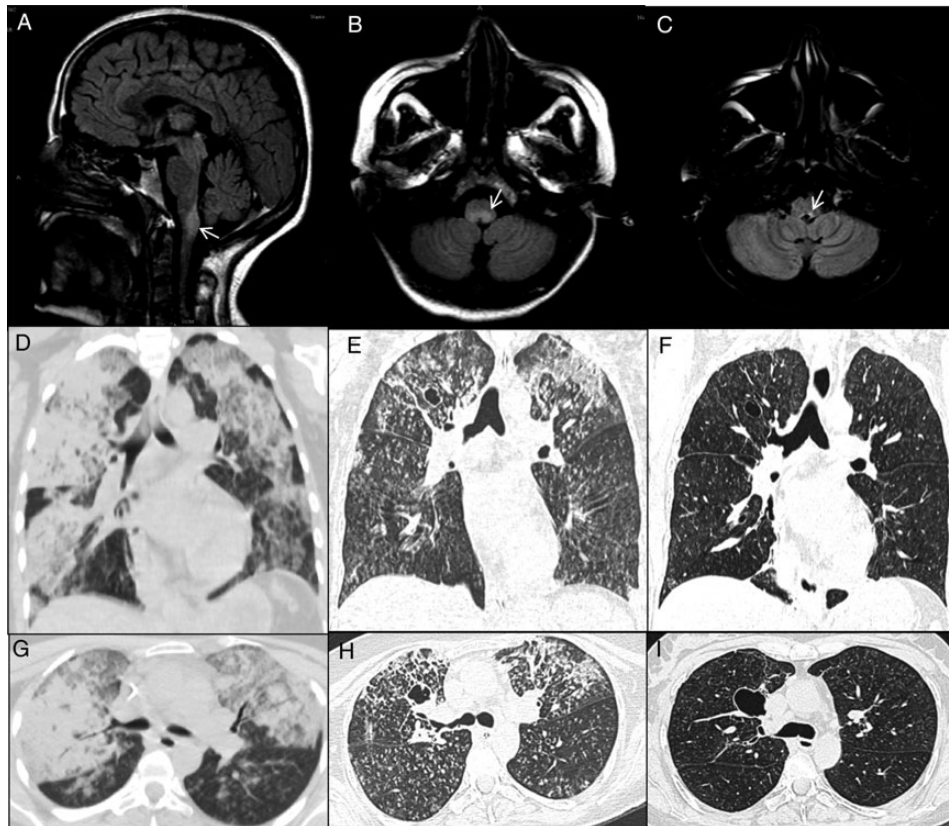


Figure 1. FLAIR brain magnetic resonance imaging shows hyperintense signal (arrows) in dorsal medulla on sagittal (A) and axial (B) views, with regression 10 months later (C). Initial coronal (D) and axial (G) chest computed tomography (CT) revealed multifocal air-space opacification with multiple nodules predominantly in upper lungs bilaterally, greater on the right (D). One month later, coronal (E) and axial (H) chest CT revealed more prominent multifocal small nodular opacities randomly in both lung fields, cavitating cystic lesions in the right upper zone and resolving upper lobe consolidation bilaterally. Five months after initial presentation, coronal (F) and axial (I) lung CT showed marked persistence of small cystic areas in the right upper lung, but nearly complete resolution of the fibrotic lesions and micronodular shadows.

Table 1. Timeline of Relevant Clinical Features, Laboratory Analysis, Imaging Studies, and Treatment

Time (months)	0–1	1–3	3–4	4–5	5–6	10
Clinical features	Pulmonary and neurological symptoms; intubation	Extubation, transfer to Muscat at 1 month	Improvement at 3 months	Continued improvement at 5 months		
Laboratory results	Bronchial washings and sputum cultures negative; intubated airway <i>Pseudomonas</i> +	CSF, vasculitis labs; lung and renal biopsy performed				
Imaging	Brain MRI brain lesion (Figure 1A and B); chest CT abnormal (Figure 1D and G)	Chest CT chest shows resolving consolidation at 1 month (Figure 1E and H)		Chest CT improvement at 5 months, (Figure 1F and I)		Brain MRI lesion resolved (Figure 1C)
Treatment	Methylprednisolone, 5 days; meropenem, 3 weeks	IVIg, 5 days; prednisolone, daily	Prednisolone, daily	Prednisolone, taper	Acyclovir IV for 2 weeks; then valacyclovir PO for 1 month; fluticasone/salmeterol, 24 days	

Abbreviations: CSF, cerebrospinal fluid; CT, computed tomography; IVIG, intravenous immunoglobulin; MRI, magnetic resonance imaging.

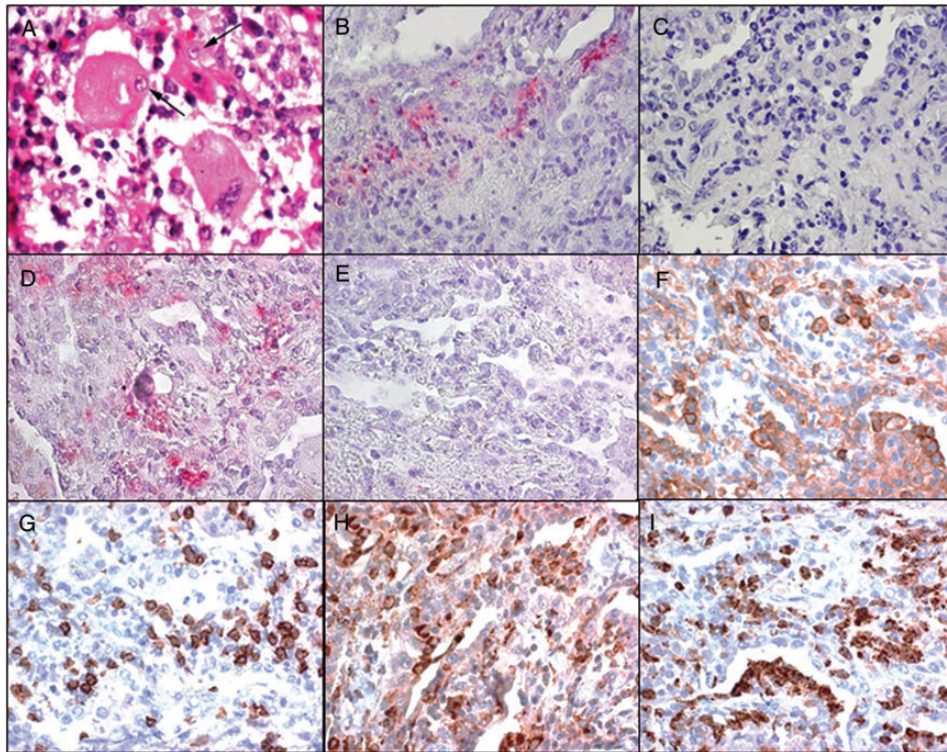


Figure 2. Hematoxylin-eosin staining of lung biopsy revealed multinucleated giant cells containing intranuclear inclusions (A, arrows). Of 200 5- μ m sections cut from the formalin-fixed, paraffin-embedded lung biopsy, immunostaining of every other section as described [3] with 2 different antibodies to varicella zoster virus (VZV) revealed VZV in multiple nonconsecutive sections. Note detection of VZV antigen after immunostaining with mouse anti-VZV immunoglobulin (IgE) antibody (B, pink color), but not after staining the adjacent section with control mouse IgG1 antibody (C). Varicella zoster virus antigen was also demonstrated after immunostaining with rabbit anti-VZV IgG antibody (D, pink color), but not with rabbit anti-HSV IgG antibody (E) or normal rabbit serum (data not shown). Further analysis of immune cells present in sections adjacent to those containing VZV antigen showed T cells expressing CD4 (F) and CD8 (G), macrophages expressing CD68 (H), and neutrophils expressing CD15 (I). Magnification $\times 600$.

plus salmeterol (50 μ g/dose twice daily) along with oral moxifloxacin (400 mg/day) for 24 days (Table 1).

One month after the onset of her illness, there was marked resolution of the confluent consolidation in the upper lobes (Figure 1E and H). Lung biopsy indicated bronchiolitis obliterans organizing pneumonia and interstitial pneumonitis and multinucleated giant cells containing intranuclear inclusions (Figure 2A, arrows) but did not give rise to any organisms. The patient developed anemia, but a bone marrow biopsy revealed no abnormal infiltrates, blasts, or granuloma. She received blood transfusions, inotropic support, and initial mechanical ventilation followed by noninvasive ventilatory support for 1 month during her critical illness. Renal biopsy for transient nephrotic range proteinuria showed only mild mesangial hypercellularity in the glomerulus. Liver function remained normal.

Three months after onset of symptoms, cough and sputum had almost disappeared and 1–2 L/min of oxygen maintained an oxygen saturation of 98%. Repeat chest CT at 5 months revealed resolution of the fibrotic and micronodular lesions with persistence of small cystic areas (Figure 1F and I). Her paraparesis, sphincter dysfunction, dysphagia, and gag reflex also

improved. Results of earlier CSF examination revealed anti-VZV IgG but not anti-HSV antibody, with reduced serum/CSF ratios of anti-VZV IgG antibody indicative of intrathecal synthesis of anti-VZV IgG antibody. Immunohistochemistry revealed VZV antigen (Figure 2B–E) and PCR-amplified VZV DNA in lung tissue as described [3]. The abundance of CD4 and CD8 T cells, macrophages, and neutrophils had also decreased (Figure 2F–I). Although our patient was markedly improved, because VZV can persist for months to years, she was treated with intravenous acyclovir (10 mg/kg 3 times daily for 2 weeks), followed by oral valacyclovir (1 g 3 times daily for 1 month) (Table 1). Brain MRI at 10 months after her initial symptoms showed marked regression of the dorsal medullary lesion (Figure 1C). Magnetic resonance angiography revealed no beading or narrowing of intracranial vessels.

DISCUSSION

In this study, we describe an extraordinary case of VZV pneumonitis and brainstem encephalitis that developed simultaneously in an immunocompetent adult in the absence of rash.

Because primary VZV infection would be expected to produce widespread rash (varicella) and VZV reactivation without rash is well documented, we presume that this was VZV reactivation and not primary infection. Although no particular lung lesion is VZV-specific, chest CT scanning did show nodularity typically described in VZV pneumonitis [4–6], and histopathology of the lung biopsy revealed multinucleated giant cells and Cowdry A inclusions characteristic of human herpesvirus infection. Virological analysis detected VZV antigen and VZV DNA. Detection of anti-VZV IgG antibody in CSF with reduced serum/CSF ratios of anti-VZV IgG antibody, indicative of intrathecal synthesis of anti-VZV IgG antibody, provided virological verification that VZV caused central nervous system (CNS) disease. The value of detecting anti-VZV IgG to diagnose CNS disease produced by VZV has been widely demonstrated, not only in a patient with repeated episodes of CNS disease, including brainstem inflammation without rash [7], but also in multiple patients with VZV myelopathy [8] and VZV vasculopathy [9].

Although VZV reactivation is well known to produce multiple neurological and ocular disorders in the absence of rash [1], visceral VZV infection without rash appears to be less frequent. Yet, rare cases of VZV reactivation without rash have produced fatal massive hepatic necrosis [10], disseminated infection of lung, liver, kidney, and bone marrow [11], as well as infection of the peripheral and CNS, esophagus, kidney, adrenal gland, and lymph nodes [2]. Finally, although our patient improved before VZV infection was verified virologically and received antiviral treatment, earlier virological analysis might have obviated months of intensive care.

Acknowledgments

We thank Marina Hoffman for editorial assistance and Cathy Allen for manuscript preparation.

Financial support. This work was supported by the National Institutes of Health (Grant AG032958 to D. G. and M. A. N.; Grant AG006127 to D. G.; and Grant NS067070 to M. A. N.).

Potential conflicts of interest. All authors: No reported conflicts. All authors have submitted the ICMJE Form for Disclosure of Potential Conflicts of Interest.

References

1. Gilden D, Cohrs RJ, Mahalingam R, et al. Neurological disease produced by varicella zoster virus reactivation without rash. *Curr Top Microbiol Immunol* **2010**; 342:243–53.
2. Dueland AN, Devlin M, Martin JR, et al. Fatal varicella zoster virus meningoradiculitis without skin involvement. *Ann Neurol* **1991**; 29:569–72.
3. Mathias M, Nagel MA, Khmeleva N, et al. VZV multifocal vasculopathy with ischemic optic neuropathy, acute retinal necrosis and temporal artery infection in the absence of zoster rash. *J Neurol Sci* **2013**; 325:180–2.
4. Kim JS, Ryu CW, Lee SI, et al. High-resolution CT findings of varicella-zoster pneumonia. *Am J Roentgenol* **1999**; 172:113–6.
5. Frangides CY, Pneumatikos I. Varicella-zoster virus pneumonia in adults: report of 14 cases and review of the literature. *Eur J Intern Med* **2004**; 15:364–70.
6. Maher TM, Gupta NK, Burke MM, et al. CT findings of varicella pneumonia after lung transplantation. *Am J Roentgenol* **2007**; 188:557–9.
7. Haug A, Mahalingam R, Cohrs RJ, et al. Recurrent polymorphonuclear pleocytosis with increased red blood cells caused by varicella zoster virus infection of the central nervous system. *J Neurol Sci* **2010**; 292:85–8.
8. Gilden D, Nagel MA, Ransohoff RM, et al. Recurrent varicella zoster virus myelopathy. *J Neurol Sci* **2009**; 276:196–8.
9. Nagel MA, Forghani B, Mahalingam R, et al. The value of detecting anti-VZV IgG antibody in CSF to diagnose VZV vasculopathy. *Neurology* **2007**; 68:1069–73.
10. Ross JS, Fanning WL, Beautyman W, et al. Fatal massive hepatic necrosis from varicella-zoster hepatitis. *Am J Gastro* **1980**; 74:423–7.
11. Grant RM, Weitzman SS, Sherman CG, et al. Fulminant disseminated varicella zoster virus infection without skin involvement. *J Clin Virol* **2002**; 24:7–12.