

A comparison between 18F-FDG PET/CT and classical physical examination package for cancer screening in asymptomatic Chinese patients

Cong Ma^{1,2}, Wei-Hua Zhang³, Bing-Xiang Yu^{1,2}, Bai-Xuan Xu⁴

¹Department of Health Medicine, Chinese PLA General Hospital, Beijing 100853, China;

²Geriatric Cardiology Department of Second Medical Center & National Clinical Research Center of Geriatric Disease, Chinese PLA General Hospital, Beijing 100853, China;

³Department of Respiratory, First Medical Center, Chinese PLA General Hospital, Beijing 100853, China;

⁴Department of Nuclear Medicine, First Medical Center, Chinese PLA General Hospital, Beijing 100853, China.

To the Editor: Cancer is the leading cause of death in China.^[1] With rapid economic development, 18F-fluorodeoxyglucose (FDG) positron emission tomography (PET)/computed tomography (CT) for screening cancer in asymptomatic patients is gaining popularity in China. PET/CT is a type of molecular imaging technology, which uses a specific tracer for localization and quantification of the disease at a molecular level.^[2] However, the utility of such screening is still controversial.^[3] Based on the past clinical experience, the previous physical examination protocol has been optimized, and a classical physical examination protocol has been set up at the author's study center. So far, there is no evidence to know which approach was better for cancer screening in asymptomatic individuals.

All the asymptomatic cases who were admitted to the hospital with a voluntary choice of FDG PET/CT examination in the department of health medicine between January 1, 2015 and December 31, 2017 were retrospectively reviewed. Patients with a previous history of a malignant tumor or incomplete clinical data were excluded. This study was conducted in accordance with the principles of the *Declaration of Helsinki*, and the study protocol was approved by the Ethics Committee of Chinese PLA General Hospital (No. 2007029). 18F-FDG PET/CT was performed on a Siemens Biograph 64 HD machine. The axial field view of this system is 21.6 cm. Subjects were required to fast for at least 4 h before undergoing imaging, and the serum glucose level was maintained below 6.5 mmol/L. Next, a 4.44 MBq/kg 18F-FDG injection was administered to the subjects. Whole-body 18F-FDG PET scanning was performed 45 to 60 min after the injection. Five or six-bed positions that included

the head to the thigh of the patient were imaged. All 18F-FDG PET/CT images were displayed on a hard copy and at the workstation. Image interpretation of 18F-FDG PET/CT was based on the consensus of two nuclear medicine physicians. The median effective dose from 18F-FDG PET was 3.69 mSv while that from low dose CT was 4.93 mSv. The median total effective dose was 8.85 mSv.

Clinical data about each enrolled case, including general information (sex, age, and patient ID), past history, personal history (smoking and drinking history), family history of cancer, physical examination, laboratory tests, imaging examinations (CT lung screening, thyroid, abdominal and pelvic ultrasound examination, and brain magnetic resonance imaging), endoscopic examinations (gastrofiberscopy and colonofiberscopy), and FDG PET/CT examination were retrospectively collected.

A total of 5934 individuals undergoing FDG PET/CT examination were retrospectively reviewed during 3-year period. Of them, 2843 agreed to undergo endoscopic examinations. Among 2843 recruited patients, 52 patients were excluded because of inadequate laboratory tests and imaging examinations. After exclusion, 2791 individuals were included in the analysis.

In the cancer screening program, 64 (2.29%) patients were found to have malignant tumors, of which 48 were males and 16 were females. The mean age of the patients was 61.72 ± 17.12 years (range 28–91 years). To some extent, the detection rate of malignancy tended to increase with age. It was only 1.11% in the subjects younger than 50 years, while in those older than 50, this rate rose to 3.57% ($P < 0.05$).

Access this article online

Quick Response Code:



Website:
www.cmj.org

DOI:
10.1097/CM9.0000000000001376

Cong Ma and Wei-Hua Zhang contributed equally to this work.

Correspondence to: Dr. Bai-Xuan Xu, Department of Nuclear Medicine, First Medical Center, Chinese PLA General Hospital, Beijing 100853, China
E-Mail: xubaixuan66@sina.com

Copyright © 2021 The Chinese Medical Association, produced by Wolters Kluwer, Inc. under the CC-BY-NC-ND license. This is an open access article distributed under the terms of the Creative Commons Attribution-Non Commercial-No Derivatives License 4.0 (CCBY-NC-ND), where it is permissible to download and share the work provided it is properly cited. The work cannot be changed in any way or used commercially without permission from the journal.

Chinese Medical Journal 2021;134(7)

Received: 05-09-2020 Edited by: Peng Lyu

Of 64 subjects, 59 cases were detected by the classical physical examination package. The pathological reports proved that the 59 malignancy cases comprised 19 cases of colorectal cancer, 16 cases of lung cancer, nine cases of stomach cancer, three cases of hepatocellular carcinoma (HC), four cases of thyroid cancer, two cases of esophagus cancer, one case of renal cancer, two cases of gall bladder cancer, one case of pancreatic cancer, one case of bladder cancer, and one case of breast cancer.

Furthermore, among the 90 subjects who had abnormal FDG uptake or malignant changes in FDG uptake in the PET cancer screening, 52 were diagnosed with cancer according to the pathological reports. These included 13 cases of colorectal cancer, 17 of lung cancer, nine of stomach cancer, two of HC, four of thyroid cancer, one of esophagus cancer, one of renal cancer, two of gall bladder cancer, two of pancreatic cancer, and one of breast cancer. As per the FDG PET/CT, 90 subjects were suspected of having malignant lesions, of which 52 were found to be truly positive, and the detection rate of FDG PET/CT in cancer screening was 1.86% (52/2791). The sensitivity, specificity, positive predictive value (PPV), and negative predictive value (NPV) of FDG PET/CT were 81.25% (52/64), 98.61% (2689/2727), 57.78% (52/90), and 99.56% (2689/2701), respectively. There were 38 false-positive lesions in FDG PET/CT and 12 false-negative lesions detected by pathology. The 38 false-positive lesions in FDG PET/CT were found in the thyroid (16 cases), stomach (five cases), colon (six cases), prostate (two cases), gallbladder (two cases), liver (one case), breast (one case), lung (two cases), pancreas (one case), shoulder joint (one case), and gluteus maximus (one case). These lesions have been confirmed as benign lesions by the histological methods. The 12 false-negative cases included two cases of lung cancer and colorectal cancer each, one case of each thyroid cancer, HC, esophagus cancer, and bladder cancer. These 12 false-negative cases showed no abnormal focal FDG accumulation in FDG PET/CT that was suggestive of malignancy. However, the malignant lesions were caught by other screening tests, such as ultrasonography, magnetic resonance imaging, laboratory tests, and endoscopic examinations. All these false-negative subjects were histologically diagnosed with cancer at a later point of time.

According to the classical physical examination package, 61 subjects were suspected of having malignant lesions, of which 59 were found to be truly positive. The detection rate of classical physical examination package in cancer screening was 2.11% (59/2791). The sensitivity, specificity, PPV, and NPV of the classical physical examination package were 92.19% (59/64), 99.93% (2725/2727), 96.72% (59/61), and 99.82% (2725/2730), respectively. There were only two false-positive lesions and five false-negative lesions as per the classical physical examination package. Both the false-positive lesions were confined to the lungs. The five false-negative cases included 3 cases of lung cancer, and one of each thyroid cancer and pancreatic cancer.

In order to judge the diagnostic power of the two cancer-screening protocols, the ROC curve analysis was

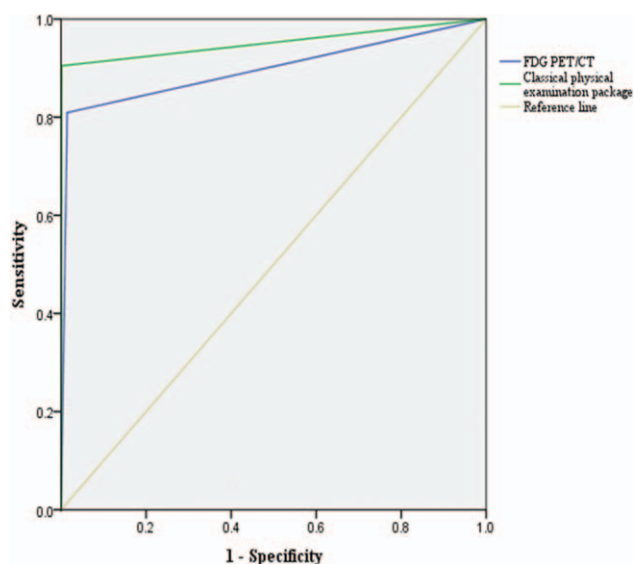


Figure 1: ROC curve for assessing the efficiency of FDG PET/CT and classical physical examination package. The area under the ROC curve of FDG PET/CT was 0.898 (95% CI: 0.840–0.955), $P < 0.001$. The area under the ROC curve of the classical physical examination package was 0.952 (95% CI: 0.909–0.994), $P < 0.001$. CI: Confidence interval; FDG PET/CT: 18F-fluorodeoxyglucose positron emission tomography/computed tomography; ROC: Receiver operating characteristic.

performed for each method to aid in the selection of the most useful way [Figure 1]. Each of the two approaches showed high values for cancer screening. The areas under the ROC curves were 0.898 (95% confidence interval [CI]: 0.840–0.955) and 0.952 (95% CI: 0.909–0.994) for FDG PET/CT and classical physical examination package, respectively. The classical physical examination package showed better performance in cancer screening. The diagnostic accuracy was significantly higher for the classical physical examination package compared to the PET/CT ($P < 0.001$).

This study compared the diagnostic performance of whole-body FDG PET/CT and classical physical examination package in asymptomatic adults with cancer. Although the whole-body FDG PET/CT illustrated a good performance, the diagnostic accuracy was significantly higher in the classical physical examination package. The classical physical examination package presented a higher sensitivity, specificity, PPV, and NPV. The false-positive lesions in FDG PET/CT screening included active inflammatory lesions, small size lesions, benign tumors, and some aberrant physiologic uptakes of FDG in normal organs. The last type of false positivity is commonly seen in the urogenital system and skeletal muscles.^[4] One challenge posed by the FDG PET/CT screening is the difficulty in distinguishing gastrointestinal cancers. The false-positive findings were usually for aberrant physiologic uptakes, benign adenomas, inflammatory lesions, and hyperplastic polyps. Therefore, colonoscopy and gastroscopy are the gold standards for the diagnosis of gastrointestinal cancers. In addition, thyroid cancer is a major limitation of cancer screening. There is no safe SUVmax cutoff to discriminate benign from malignant thyroid incidentalomas using FDG PET/CT, and only one-third of focal uptakes are malignant.^[5] Lung cancer was also included as

limitations in cases of small tumors as ground-glass nodule (GGN). However, the overall false positivity for lung cancer detection was the same as compared to the FDG PET/CT with classical physical examination package.

This study also has some limitations. First, this was a single-center retrospective study; most of the subjects were special populations who were economically sound. Therefore, this result cannot be applied to the general population. Second, subjects older than 80 years and younger than 30 years were few, which may have given rise to a potential. Therefore, the study population cannot represent all the asymptomatic Chinese patients. Hence, multi-center studies are needed to confirm these results and should be testified in populations with different economic backgrounds.

Based on the results, it can be suggested that the classical physical examination package might be an effective modality for cancer screening in asymptomatic cancer patients. FDG PET/CT is more suitable for patients with positive or suspected results in classical physical examination of the high-risk group.

Conflicts of interest

None.

References

1. Chen W, Zheng R, Baade PD, Zhang S, Zeng H, Bray F, *et al.* Cancer statistics in China, 2015. *CA Cancer J Clin* 2016;66:115–132. doi: 10.3322/caac.21338.
2. Yao NT, Zheng Q, Xu ZQ, Yin JH, Lu LG, Zuo Q, *et al.* Positron emission computed tomography/single photon emission computed tomography in Parkinson disease. *Chin Med J* 2020;133:1448–1455. doi: 10.1097/cm9.0000000000000836.
3. Schöder H, Gönen M. Screening for cancer with PET and PET/CT: Potential and limitations. *J Nucl Med* 2007;48 (Suppl 1):4s–18s.
4. Reinking MF, Osman MM. Prospective evaluation of physiologic uptake detected with true whole-body 18F-FDG PET/CT in healthy subjects. *J Nucl Med Technol* 2009;37:31–37. doi: 10.2967/jnmt.108.055004.
5. Bertagna F, Treglia G, Piccardo A, Giubbini R. Diagnostic and clinical significance of F-18-FDG-PET/CT thyroid incidentalomas. *J Clin Endocrinol Metab* 2012;97:3866–3875. doi: 10.1210/jc.2012-2390.

How to cite this article: Ma C, Zhang WH, Yu BX, Xu BX. A comparison between 18F-FDG PET/CT and classical physical examination package for cancer screening in asymptomatic Chinese patients. *Chin Med J* 2021;134:873–875. doi: 10.1097/CM9.0000000000001376