



Contents lists available at ScienceDirect

Gynecology and Minimally Invasive Therapy

journal homepage: www.e-gmit.com

Case report

Uterine artery pseudoaneurysm caused by a uterine manipulator

Toshiyuki Seki ^a, Yoshinobu Hamada ^{a, *}, Teppei Ichikawa ^a, Shin Onoto ^a,
Manabu Nakata ^b, Satoshi Takakura ^a^a Department of Obstetrics and Gynecology, Dokkyo Medical University Koshigaya Hospital, Minamikoshigaya, Koshigaya, Saitama, Japan^b Department of Radiology, Dokkyo Medical University Koshigaya Hospital, Minamikoshigaya, Koshigaya, Saitama, Japan

ARTICLE INFO

Article history:

Received 16 November 2015

Received in revised form

28 March 2016

Accepted 6 April 2016

Available online 14 May 2016

Keywords:

laparoscopy

pseudoaneurysm

uterine artery

uterine manipulator

ABSTRACT

A uterine artery pseudoaneurysm (UAP) can occur after a traumatic event to the uterus, and cause massive bleeding. A uterine manipulator has been widely used for gynecologic laparoscopic surgery as basically an atraumatic instrument. We describe here a woman with a UAP caused by a uterine manipulator. She underwent laparoscopic ovarian cystectomy with a uterine manipulator due to torsion of a left ovarian cyst. Eleven days later, she came to our hospital with massive vaginal bleeding. Transvaginal Color Doppler ultrasound showed an intrauterine cystic mass with swirling blood flow, and three-dimensional arterial imaging from computed tomography revealed a UAP on the left side. Selective uterine artery angiography demonstrated a pseudoaneurysm in the distal portion of the left uterine artery, and embolization was performed successfully. A UAP should be taken into consideration in uterine bleeding after the use of a uterine manipulator.

Copyright © 2016, The Asia-Pacific Association for Gynecologic Endoscopy and Minimally Invasive Therapy. Published by Elsevier Taiwan LLC. This is an open access article under the CC BY-NC-ND license (<http://creativecommons.org/licenses/by-nc-nd/4.0/>).

Introduction

A uterine manipulator is a widely used intrauterine device for gynecologic laparoscopic surgery. It facilitates surgical procedures by allowing anteversion, retroversion, lateral movement, and elevation of the uterus, exposing a cul-de-sac of adhesive endometriosis, or lateralizing the ureter in laparoscopic hysterectomy.

A pseudoaneurysm is a perfused sac communicating with the arterial lumen due to deficiency in one or more layers of the arterial wall (Figure 1). Trauma, surgery, or infection can cause vascular injury and enable blood to enter the periarterial tissue, resulting in development of a pseudoaneurysm.¹ A uterine artery pseudoaneurysm (UAP) is rare and can rupture, leading to massive bleeding. Based on previous reports, a UAP can develop after cesarean delivery, dilation and curettage, vaginal delivery, chorioamnionitis, myomectomy, hysterectomy, resection of endometriosis, resection of tubal pregnancy, and cervical conization.

In this report, we present the first case of a UAP with massive vaginal bleeding due to the use of a uterine manipulator for a laparoscopic ovarian cystectomy.

Case Report

A 35-year-old, gravida 0, para 0 Japanese woman was diagnosed with an intrapelvic cystic mass that was increasing in size. She did not have any relevant medical history. She came to our hospital because of lower abdominal pain. A pelvic examination revealed a normal vagina, an unremarkable cervix, and a palpable pelvic mass with tenderness. A transvaginal ultrasound examination showed a cystic mass measuring 10 cm in her pelvis. Magnetic resonance imaging also showed a cystic mass without a solid component. The abdominal pain was increasing, and laparoscopic surgery was performed under the diagnosis of ovarian cyst torsion. A laparoscopic survey confirmed torsion of the left ovarian cyst with congestion, and left ovarian cystectomy was performed, using a Uterine Manipulator (Atom Medical, Tokyo, Japan; http://www.atomed.co.jp/tmp/pdf3/P113_Instruments_for_Hysteroscopy.pdf) to facilitate laparoscopic handling of the gynecologic organ. This device has an arm with a wide range of motion and an atraumatic intrauterine portion that has a soft elastic tip balloon to secure the position of the uterus and a round shaped head. We gently inserted the device into the uterus, inflated the balloon with 3 mL of normal saline, based on the instruction manual that stated that < 10 ml of saline should be used, and removed it after completion of the surgery without bleeding. The left ovarian cyst was easily detected upon scope insertion without uterus manipulation because the cyst was large. However, we gently kept the uterus anterior using the

Conflicts of interest: All authors have no conflicts of interest to declare.

* Corresponding author. Department of Obstetrics and Gynecology, Dokkyo Medical University Koshigaya Hospital, 2-1-50, Minamikoshigaya, Koshigaya, Saitama, 343-8555, Japan.

E-mail address: y-hamada@dokkyomed.ac.jp (Y. Hamada).

<http://dx.doi.org/10.1016/j.gmit.2016.04.002>

2213-3070/Copyright © 2016, The Asia-Pacific Association for Gynecologic Endoscopy and Minimally Invasive Therapy. Published by Elsevier Taiwan LLC. This is an open access article under the CC BY-NC-ND license (<http://creativecommons.org/licenses/by-nc-nd/4.0/>).

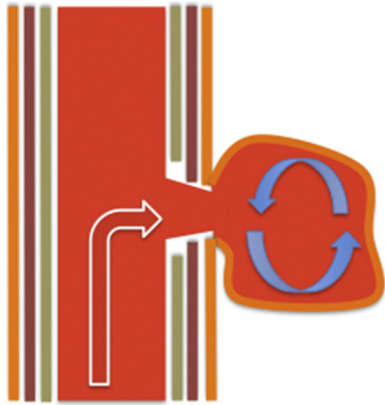


Figure 1. Illustration of pseudoaneurysm formation.

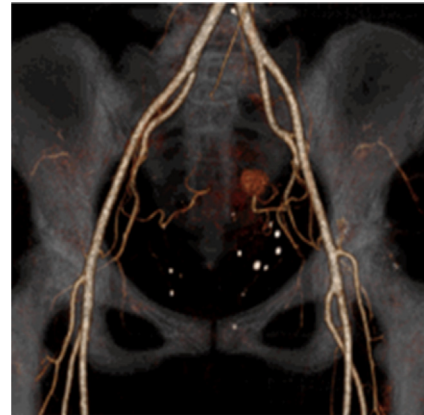


Figure 3. Three-dimensional computed tomography showing a pseudoaneurysm located at the distal end of the left uterine artery.

manipulator for most of the procedure to survey the opposite side of the adnex in detail because the patient was nulligravida and wanted to become pregnant, and to make a large working space at the cul-de-sac. Uterine wall perforation did not occur during surgery. The operating time was 110 minutes and the total blood loss was 25 mL.

Five days after surgery, the patient complained of spotty vaginal bleeding. A transvaginal grayscale ultrasound showed a 1.5 cm anechoic space in the uterine cavity, but she was discharged because genital bleeding had stopped (Figure 2A). At 11 days after surgery, the patient presented at our hospital with massive vaginal bleeding. The hemoglobin concentration was 12.8 g/dL and blood pressure was stable. Transvaginal color Doppler ultrasound imaging showed an intrauterine cystic lesion with swirling blood flow (Figure 2B). Gadolinium-enhanced dynamic magnetic resonance imaging showed a 1.5 cm mass in the left uterine wall that was enhanced in the early phase, and the dye was pooled at the delayed phase. This led to a diagnosis of pseudoaneurysm, and three-dimensional (3D) computed tomography (CT) revealed that the pseudoaneurysm was fed from the left uterine artery (Figure 3). Therefore, we consulted an interventional radiologist, and pelvic angiography was performed for definitive diagnosis and treatment. A selective left iliac angiogram through the right femoral artery with a 4F shepherd's hook catheter (Gadelius Medical, Tokyo, Japan) and a microcatheter with a 1.7F tip (Veloute; Asahi Intec, Nagoya, Japan) demonstrated a pseudoaneurysm located distal of the uterine artery. Embolization was performed with gelatin particles (Gelpart; Nipponkayaku, Tokyo, Japan), occlusion of the artery was completed, and the vaginal bleeding stopped. After embolization, the hemoglobin concentration was 10.3 mg/dL and blood transfusion was not required.

Five days after embolization, 3D-CT confirmed the absence of the pseudoaneurysm. At the 1-month follow up, normal menstruation had resumed, and a transvaginal color Doppler ultrasound imaging showed a normal uterus without abnormal blood flow.

Discussion

To our knowledge, this is the first report of a UAP due to the use of a uterine manipulator. According to previous publications, various clinical events and procedures responsible for the occurrence of UAP have been reported. The most frequent relevant procedure is cesarean delivery.¹ The next most frequent cause is pregnancy related events, including normal vaginal delivery, instrumental delivery, and surgical abortion.¹ Gynecologic procedures, including abdominal, laparoscopic, and hysteroscopic myomectomy and abdominal hysterectomy, also reported the development of a UAP.^{1,2} Other rare causes are laparoscopic dissection of endometriotic lesions, uterine cervical conization, resection of a tubal pregnancy, manual placenta removal, and chorioamnionitis.^{1,3–5} Because this patient did not have a significant medical history or pregnancy, we believe that the uterine manipulator made a vascular injury on the uterine wall that resulted in UAP formation.

Although the mechanism of UAP formation is not completely clarified, trauma to the uterine artery is believed to be one possible cause. Surgery or another interventional procedures may cause damage and lead to a defect in the arterial wall. Arterial blood escapes from this defect and diffuses through adjacent tissue, and forms a perfused sac that contains the adventitia or surrounding tissue.^{6,7} Uterine wall complications of a uterine manipulator with

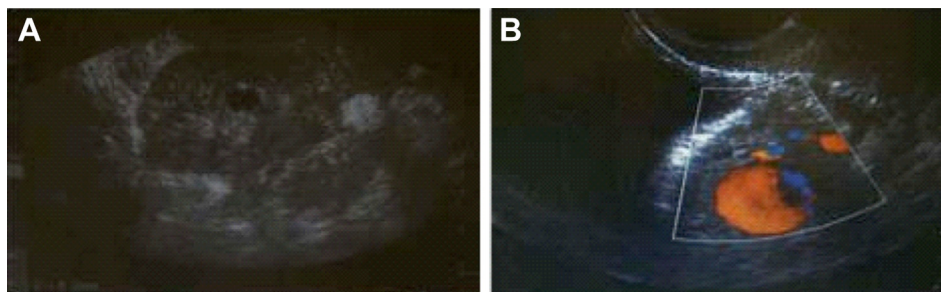


Figure 2. (A) Grayscale ultrasound imaging showing a 1.5-cm anechoic lesion in the uterine cavity. (B) Color Doppler imaging showing swirling blood flow with a to-and-fro pattern in the intrauterine cystic lesion.

a balloon tip have been described, due to remnants of parts, uterine rupture or perforation.^{8,9} Logani et al reported in their pathological study of laparoscopic hysterectomy specimens that there were countless stromal vessels with tumor/non-neoplastic endometrial tissue in the uterus with stage I endometrial cancer, and normal endometrial glands and stromal tissue within vascular spaces also are found in the uterus resected for benign disease.¹⁰ The authors stated that the intrauterine balloon causes collapse of both the lymphatics and vasculature of the uterine endometrium and myometrium.¹⁰ Wu et al reported two cases of uterine rupture caused by overinflation of a manipulator balloon.¹¹ The balloon was inflated to approximately 25 mL, which is much larger than the volume used in our case. However, the capacity of the uterine cavity varies among patients, with Vilos et al showing that intrauterine pressure may reach an excessively high level (> 200 mmHg) with 2 mL of balloon inflation.¹² In our case, inflation of 3 mL did not cause uterine wall perforation, but intrauterine balloon pressure or stretching of the uterine wall can cause vascular injury, subsequently forming a UAP. Therefore, a manipulator should be used restrictively and with an effort to minimize uterine wall damage by reducing the inflation volume of the balloon tip and handling the manipulator gently throughout the procedure as a potentially traumatic instrument.

UAP is a rare cause of postoperative genital bleeding, but can lead to a life-threatening hemorrhage when it ruptures. Early detection and therapeutic intervention before the UAP manifests clinically is important to prevent severe hemorrhage. Although a definitive diagnosis for UAP requires angiography, the usefulness of several noninvasive diagnostic modalities, including color Doppler ultrasound and CT angiography, have been reported. Color Doppler ultrasound imaging demonstrates the *to-and-fro* sign, which is turbulent arterial-like flow in the cystic lesion presenting a high sensitivity and specificity in the detection of UAP.^{13,14} Color Doppler ultrasound imaging is noninvasive and accessible, which are important for early diagnosis. In our case, color Doppler ultrasound imaging provided important information that suggested the definite diagnosis. In addition, helical CT angiography is also useful for the non-invasive detection and diagnosis of pseudoaneurysms. CT angiography has some advantages over other imaging modalities. CT angiography is not as operator-dependent and has a shorter acquisition time. Although constructing 3D images may be time consuming, it provides sufficient diagnostic information to plan a treatment strategy, such as detection of the feeding artery.¹⁵ In our case, initial examination using grayscale ultrasound alone suggested that the lesion was in the uterine cavity, and not in the uterine wall, due to insufficient information provided by this imaging, and this led to delayed diagnosis. A combination of multiple diagnostic modalities, especially color Doppler ultrasound imaging,

is important to make an early and precise diagnosis. After diagnosis, treatment to prevent severe hemorrhage should be performed as soon as possible.

In conclusion, this presented case indicates that a uterine manipulator could cause a UAP and massive bleeding. Although the uterine manipulator is a useful device for laparoscopic surgery, we should consider the uterine manipulator as a potential traumatic device for uterine vessels. After laparoscopic surgery using the uterine manipulator, color Doppler ultrasound imaging of the uterus may help early diagnosis of UAP, and early intervention can be achieved before massive bleeding occurs.

References

1. Isono W, Tsutsumi R, Wada-Hiraike O, et al. Uterine artery pseudoaneurysm after cesarean section: case report and literature review. *J Minim Invasive Gynecol*. 2010;17:687–691.
2. Ito N, Natimatsu Y, Tsukada J, Sato A, Hasegawa I, Lin BL. Two cases of post-myomectomy pseudoaneurysm treated by transarterial embolization. *Cardiovasc Intervent Radiol*. 2013;36:1681–1685.
3. Moon G, Jeon S, Nam K, Choi S, Sunwoo J, Ryu A. Pseudoaneurysm of uterine artery causing intra-abdominal and vaginal bleeding after cervical conization. *Obstet Gynecol Sci*. 2015;58:256–259.
4. Baba Y, Matsubara S, Kuwata T, et al. Uterine artery pseudoaneurysm: not a rare condition occurring after non-traumatic delivery or non-traumatic abortion. *Arch Gynecol Obstet*. 2014;290:435–440.
5. Woodhams R, Ogasawara G, Ishida K, et al. Successful treatment of acquired uterine arterial venous malformation using N-butyl-2-cyanoacrylate under balloon occlusion. *Acta Radiol Short Reports*. 2014;3:1–6.
6. Zimon A, Hwang J, Principle D, Bahado-Singh R. Pseudoaneurysm of the uterine artery. *Obstet Gynecol*. 1999;94:827–830.
7. Takeda A, Koike W, Imoto S, Nakamura H. Conservative management of uterine artery pseudoaneurysm after laparoscopic-assisted myomectomy and subsequent pregnancy outcome: case series and review of the literature. *Eur J Obstet Gynecol Reprod Biol*. 2014;182C:146–153.
8. Van den Haak L, Alleblas C, Nieboer TE, Rhemrev JP, Jansen FW. Efficacy and safety of uterine manipulators in laparoscopic surgery: a review. *Arch Gynecol Obstet*. 2015;292:1003–1011.
9. Asai S, Asada H, Lin B. Remnant of rubber tip cover of uterine manipulator after laparoscopic myomectomy. *Gynecol Minim Invasive Ther*. 2015;4:18–19.
10. Logani S, Herdman AV, Little JV, Moller KA. Vascular “pseudo invasion” in laparoscopic hysterectomy specimens: a diagnostic pitfall. *Am J Surg Pathol*. 2008;32:560–565.
11. Wu H, Yeh GP, Hsieh TC. Iatrogenic uterine rupture caused by overinflation of RUMI manipulator balloon. *J Minim Invasive Gynecol*. 2005;12:174–176.
12. Vilos GA, Aletobi FA, Eskandar MA. Endometrial thermal balloon ablation with the ThermoChoice system: effect of intrauterine pressure and duration of treatment. *J Am Assoc Gynecol Laparosc*. 2000;7:325–329.
13. Abu-Yousef MM, Wise JA, Shamma AR. The “to-and-fro” sign: duplex Doppler evidence of femoral artery pseudoaneurysm. *Am J Roentgenol*. 1988;150:632–634.
14. Helvie A, Silver TM, Kresowik F. The distinction between femoral artery pseudoaneurysms and other causes of groin masses: value of duplex Doppler. *Am J Roentgenol*. 1988;150:1177–1180.
15. Saad NE, Saad WE, Davies MG, Waldman DL, Fultz PJ, Rubens DJ. Pseudoaneurysms and the role of minimally invasive techniques in their management. *Radiographics*. 2005;25:S173–189.