

## Case Report

# Benzalkonium chloride induced corrosive balanoposthitis in a man requiring clean intermittent catheterization

Yo Satoji,<sup>1</sup> Shohei Tobu,<sup>2</sup> Kyohei Matsushita,<sup>2</sup> Kazuma Udo<sup>2</sup> and Mitsuru Noguchi<sup>2</sup>

<sup>1</sup>Department of Urology, Kumamoto City Hospital, Kumamoto, and <sup>2</sup>Department of Urology, Faculty of Medicine, Saga University, Nabeshima, Saga, Japan

### Abbreviations & Acronyms

BAC = benzalkonium chloride  
CIC = clean intermittent catheterization

**Correspondence:** Yo Satoji M.D., Department of Urology, Kumamoto City Hospital, 4-1-60 Higashimachi, Higashi-ku, Kumamoto 862-8505, Japan. Email: ynbdd561@ybb.ne.jp

**How to cite this article:** Satoji Y, Tobu S, Matsushita K, Udo K, Noguchi M. Benzalkonium chloride induced corrosive balanoposthitis in a man requiring clean intermittent catheterization. *IJU Case Rep.* 2021; 4: 101–103.

This is an open access article under the terms of the Creative Commons Attribution-NonCommercial-NoDerivs License, which permits use and distribution in any medium, provided the original work is properly cited, the use is non-commercial and no modifications or adaptations are made.

Received 16 October 2020; accepted 20 December 2020. Online publication 12 January 2021

This case was presented at the 26th Annual Meeting of the Japanese Continence Society on 14 September 2019.

**Introduction:** Men who require intermittent catheterization may be susceptible to balanoposthitis. Benzalkonium chloride is commonly used to disinfect reusable catheters, but the concentration of this solution is critical.

**Case presentation:** A 40-year-old man presented with fever, pus around the glans and foreskin, and difficult catheterization. On physical examination, his urethral meatus was too narrow to insert a catheter. Suprapubic catheterization and 2 weeks of intravenous and topical treatment cured the ulcer of the glans. However, after restarting catheterization, the ulcer of the glans relapsed, and the patient's urethral meatus was completely closed. Circumcision and incision of the meatus were performed, and antibiotics were administered. Unexpectedly, restarting catheterization caused recurrent balanoposthitis. Close inquiry revealed that the patient was using a 10% benzalkonium chloride soaking solution for a reusable catheter, which was a toxic concentration.

**Conclusion:** The disinfectant concentration should be confirmed when refractory balanoposthitis is encountered in patients who require catheterization.

**Key words:** balanoposthitis, benzalkonium compounds, clean intermittent catheterization, disinfectants, neurogenic bladder.

## Keynote message

BAC is a commonly used disinfectant for nondisposable urinary catheters, but high concentrations are toxic to the skin and mucosa. Patients may have difficulty determining the concentrations of over-the-counter disinfectants. The concentration of disinfectants should be confirmed when refractory balanoposthitis occurs in patients who require CIC.

## Introduction

Appropriate catheterization is essential for patients with neurogenic bladder. There are several types of catheters for CIC, including nondisposable catheters which are stored in cases filled with disinfectant solution. A popular soaking solution is 0.02% BAC with 84–87% glycerin.<sup>1</sup> Considering that catheters are inserted into the urethral mucosa, an appropriate concentration of BAC is 0.025%. In fact, different concentrations of BAC are available commercially, ranging from 0.025 to 10%. A 10% agent is labeled as “must use after dilution.”

## Case presentation

A 40-year-old man visited our institution with complaints of fever, pus around the glans and foreskin, and difficulty with catheterization (Fig. 1). He had a 10-year history of CIC for voiding control after suffering a spinal injury at the age of 30 years. He visited hospitals only when he was symptomatic; otherwise, he obtained all supplies for CIC on the Internet. Two weeks before presentation, he and his wife traveled, and he tried to use an intermittent indwelling catheter for the first time. Insertion of the new catheter was difficult, and he used his usual catheter. On the next day, the foreskin started to swell, and after 2 days, he had a

fever of 38°C. A local dermatologist prescribed antibiotics, anti-inflammatory drugs, antihistamines, and topical steroids. Erosion and swelling of his penis did not recover, and catheter insertion became too difficult to perform CIC.

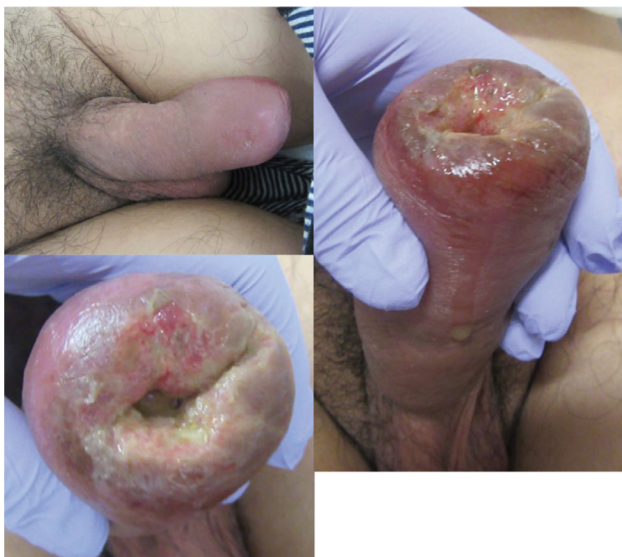On physical examination, his urethral meatus was severely obstructed, so that the catheter could not be inserted into his urethra. Ultrasonography revealed a greatly enlarged bladder. Laboratory data showed a high serum white blood cell count (12 300/mm<sup>3</sup>; neutrophils 78.9%, lymphocytes 13.3%, eosinophils 2.1%) and C-reactive protein of 4.17 mg/L. A suprapubic catheter was inserted into the bladder for urinary drainage.

After suprapubic catheterization, intravenous antibiotics and topical antiulcer agents were administered for 2 weeks. The appearance of the glans was recovered, and catheterization was performed with no problems.

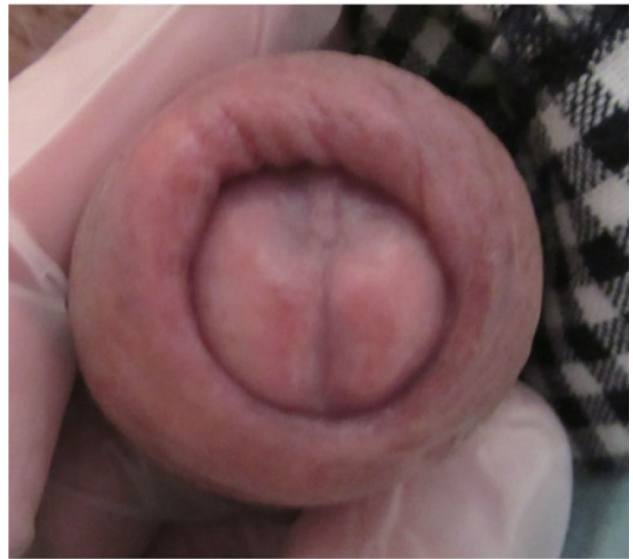After 2 days, however, he presented to our institution again, complaining of difficulty with catheterization. The glans and foreskin were swollen with pus, and the urethral meatus was completely closed (Fig. 2). Due to the recurrent balanoposthitis, we checked his IgE antibody for latex, and performed computed tomography and cystography to rule out pelvic disease, which might cause ischemia of the genitalia and vesicoureteral reflux as a cause of urinary tract infection. These examinations revealed no apparent abnormalities. As phimosis could be a trigger for balanoposthitis, circumcision and incision of the meatus were performed, and antibiotics were administered.

Two days after the glans healed and catheterization resumed, balanoposthitis recurred (Fig. 3). When the patient was questioned again concerning his CIC procedures, it was discovered that he used a 10% BAC soaking solution for the catheter, which is 400 times higher than the appropriate concentration for use in mucosa of the glans and urethra.

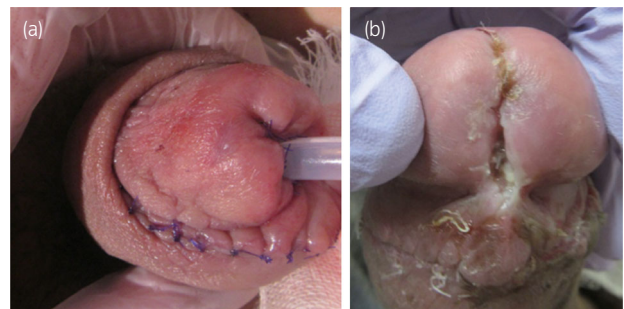
The patient usually used 0.025% BAC solution, but on vacation, he bought a different catheter from a different



**Fig. 1** Appearance of penis at the first presentation. The foreskin and glans are swollen, and erosion and pus discharge are seen. The urethral orifice was obstructed, preventing catheter insertion.



**Fig. 2** Appearance of penis at first recurrence. Two days after restart of CIC, the foreskin and glans are swollen, and catheterization is again impossible.



**Fig. 3** (a) View of the penis after circumcision and cutback of the obstructed urethra. (b) CIC induced recurrence of balanoposthitis after surgery.

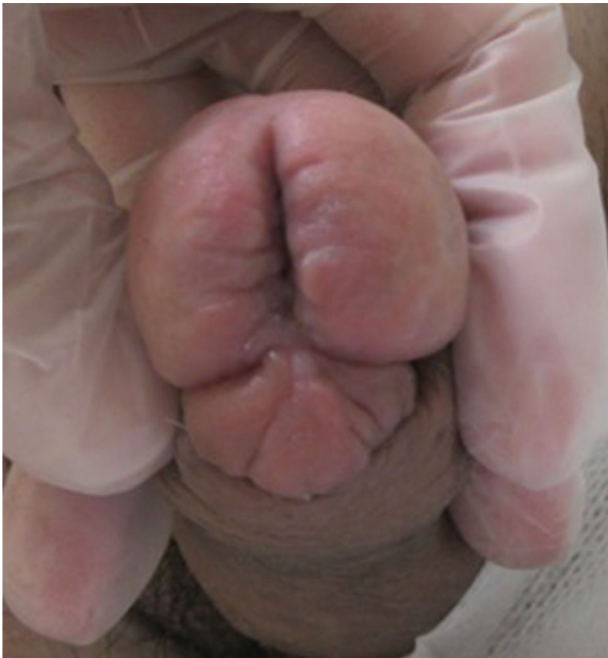vendor. At the same time, he purchased BAC as a disinfectant, which he assumed was 0.025%, but in fact was 10%.

The patient was treated with topical antiulcer agents and resumed use of 0.025% BAC, and symptoms resolved within 5 days (Fig. 4). Balanoposthitis has not recurred in 1 year of follow-up and CIC has been performed without any problems.

## Discussion

In the present case, recurrent corrosive balanoposthitis occurred in a patient with a 10-year history of successful CIC. Although the patient initially appeared to be using the same catheterization technique and materials as usual, careful investigation revealed that he had inadvertently used a toxic concentration of BAC.

BAC is an antibacterial agent that acts by disrupting the cell membranes of the target organisms and shows persistent antibacterial activity on the skin compared to ethanol-based disinfectant.<sup>2</sup> BAC is available by prescription and over the counter, and the recommended concentrations differ



**Fig. 4** The healthy penis after appropriate usage of disinfectant was resumed.

according to the usage. For example, 0.003–0.02% is recommended for ophthalmological solutions.<sup>3</sup> According to the American College of Toxicology, BAC can be safely used as a disinfectant at concentrations up to 0.1%.<sup>4</sup> However, even low concentrations of BAC can be an irritant to human skin,<sup>3</sup> and inappropriate usage of the disinfectant can lead to severe reactions. In another case, an infant experienced severe esophageal injury after ingesting a 10% BAC solution administered by her mother to treat the infant's cough.<sup>5</sup> Ulcerative contact dermatitis and anaphylaxis to BAC-coated catheters have also been reported.<sup>6,7</sup>

CIC is an indispensable voiding method for patients with urinary disorders such as neurogenic bladder. In Japan, the patients can choose their preferred type of intermittent catheters from nondisposable catheters, uncoated single-use catheters, hydrophilic-coated compact catheters, and intermittent balloon catheters. Use of single-use uncoated catheters has some disadvantages such as the need for lubrication, carrying a sufficient number of catheters outside, and disposal. Although hydrophilic-coated compact catheters may prevent more infections and improve patients' quality of life, the cost of these catheters is much higher than the other types, placing a larger economic burden on patients. Young patients are

generally socially active and prefer nondisposable portable catheter kits containing disinfectants and lubricants. These are economically advantageous because they can be repeatedly used for up to 1 month. In Japan, catheters, disinfectants, and lubricants are prescribed at hospitals once a month under physician supervision. However, patients can also purchase catheters and disinfectants on the Internet, and some patients seldom visit a hospital.

In the present case, the patient obtained catheters via the Internet, and information about his CIC materials and process were only available by questioning the patient and his family. The patient tried to use an indwelling catheter for the first time, and he could not insert it through the bladder. This episode misled us to assume that the new catheter injured his urethra and induced urethritis, or that he had an allergic reaction to the new catheter. We first confirmed that the disinfectant he used was BAC, rather than more toxic microbial agent, but we did not question the concentration of the BAC solution.

High concentrations of BAC are toxic to the skin and mucosa. This case demonstrates the need for careful investigation of the concentration of disinfectants used by patients who self-catheterize and present with recurrent balanoposthitis. In addition, education on accurate usage of disinfectants is essential for both patients and medical staff.

## Conflict of interest

The authors declare no conflict of interest.

## References

- 1 Hakuno H, Yamamoto M, Oie S, Kamiya A. Microbial contamination of disinfectants used for intermittent self-catheterization. *Jpn J. Infect. Dis.* 2010; **63**: 277–9.
- 2 Bondurant SW, Duley CM, Harbell JW. Demonstrating the persistent antibacterial efficacy of a hand sanitizer containing benzalkonium chloride on human skin at 1, 2, and 4 hours after application. *Am. J. Infect. Control* 2019; **47**: 928–32.
- 3 Pereira BMP, Tagkopoulos I. Benzalkonium chlorides: Uses, regulatory status, and microbial resistance. *Appl. Environ. Microbiol.* 2019; **85**: e00377–e419.
- 4 Marple B, Roland P, Benninger M. Safety review of benzalkonium chloride used as a preservative in intranasal solutions: an overview of conflicting data and opinions. *Otolaryngol. Head Neck Surg.* 2004; **130**: 131–41.
- 5 Civan HA, Gulcu D, Erkan T. Corrosive esophagitis with benzalkonium chloride in a two days old neonate. *Pediatr. Gastroenterol. Hepatol. Nutr.* 2016; **19**: 207–9.
- 6 Hirata YU, Yanagi T, Yamaguchi Y *et al.* Ulcerative contact dermatitis caused by benzethonium chloride. *Contact Dermatitis.* 2017; **76**: 188–90.
- 7 Shih CK, Huang SH, Tsai CJ, Chu KS, Wu SH. Anaphylaxis to benzalkonium chloride-coated central venous catheter. *J. Clin. Anesth.* 2010; **22**: 632–4.