

A rare case of cervical abscess caused by *Parvimonas micra*

SAGE Open Medical Case Reports
Volume 9: 1–4
© The Author(s) 2021
Article reuse guidelines:
sagepub.com/journals-permissions
DOI: 10.1177/2050313X211024505
journals.sagepub.com/home/sco



Erina Fujiwara¹, Takeshi Tsuda^{1,2} , Kento Wada¹,
Sadanori Waki¹, Yukiko Hanada¹ and Hiroshi Nishimura¹

Abstract

Cervical abscesses develop in the tissue spaces between the cervical fascia. The rapid expansion of these abscesses can lead to fatal outcomes. We describe a case of a deep cervical abscess caused by *Parvimonas micra*. He was referred to our department with complaints of sore throat and neck pain. Ultrasonography revealed a hypoechoic area in the cervical interfascicular space. An ultrasound-guided puncture was performed to collect pus for bacteriological examination. Subsequently, a contrast-enhanced computed tomography scan revealed a multi-focal abscess extending from the left mandible to the left side of the neck, without any mediastinal abscess. An emergency drainage and antibacterial therapies were performed, and the patient progressed well. *Parvimonas micra*, a gram-positive anaerobic bacterium, was detected in the pus collected before incision, and appropriate antibiotics were immediately administered. The collection of pus prior to incision and drainage aids accurate identification of the causative organism and appropriate treatment.

Keywords

Cervical abscess, *Parvimonas micra*, ultrasound guided puncture

Date received: 29 January 2021; accepted: 24 May 2021

Introduction

Cervical abscesses form in spaces consisting of loose connective tissue in the head and neck region and may be caused by pharyngitis, tonsillitis, tooth infection, or trauma. They require prompt diagnosis and treatment because they can lead to mediastinitis and sepsis as the abscess develops. *Streptococcus* spp. and *Staphylococcus* spp. are representative causative bacteria; however, mixed infections with anaerobic bacteria, such as *Fusobacterium* spp. are also common.^{1,2} Pus specimens are often collected at the time of incision and drainage, and in some cases, appropriate evaluation of the causative organism is not performed. In recent years, bacterial classification methods have changed in line with technological advances, and appropriate specimen collection and assessment of causative organisms have become imperative in the treatment of infectious diseases. We report a case of cervical abscess in which we were able to identify the causative organism as *Parvimonas micra* by performing a puncture prior to incision and drainage.

Case report

The patient was a 45-year-old man who presented to his local doctor with sore throat and neck pain that had persisted for

several days. He was diagnosed with acute tonsillitis and was referred to our department for treatment. At the first visit to our hospital, his body temperature was 38.5°C and SpO₂ was 98% without respiratory distress. All the lower left teeth were missing, and no redness or swelling was noted in the oral cavity. The left tonsil was swollen and had reddish pus adherence, and the laryngoscope showed swelling of the left wall of the middle pharynx and edematous changes in the left arytenoid. In addition, the left neck was indurated, erythematous, and tender. The patient did not have a history of diabetes mellitus.

Blood examination revealed that the white blood cell (WBC) count was 19,100/μL and the C-reactive protein level was 27.91 mg/L. Ultrasonography showed a hypoechoic area

¹Department of Otorhinolaryngology, National Hospital Organization Osaka National Hospital, Osaka City, Japan

²Department of Otorhinolaryngology – Head and Neck Surgery, Graduate School of Medicine, Osaka University, Suita City, Japan

Corresponding Author:

Takeshi Tsuda, Department of Otorhinolaryngology, National Hospital Organization Osaka National Hospital, 2-1-14 Houenzaka, Chuo-ku, Osaka City 540-0006, Osaka, Japan.
Email: tsuda.takeshi.se@mail.hosp.go.jp



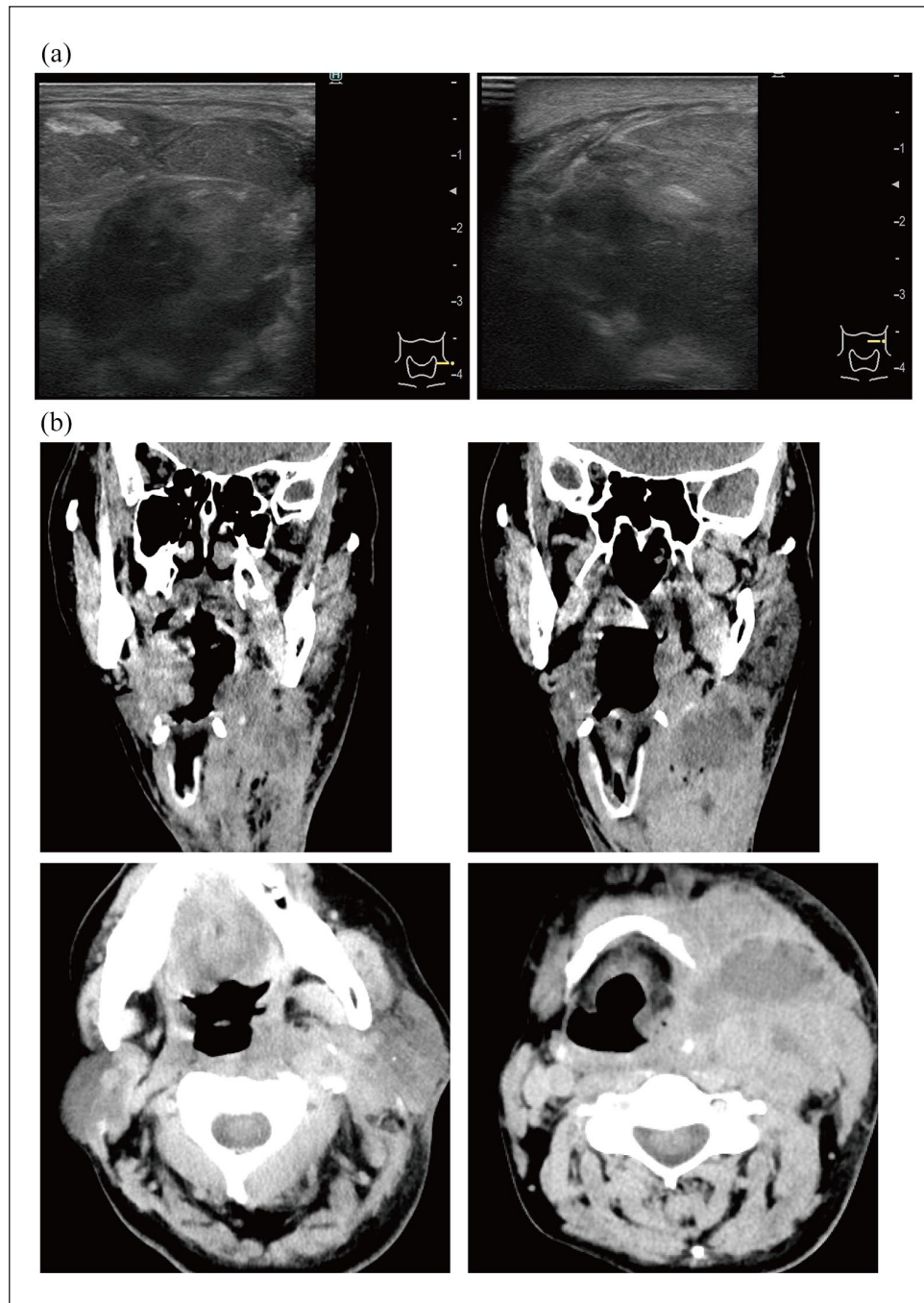


Figure 1. (a) Pre-operative cervical ultrasound image. Extensive hypoechoic areas with indistinct borders noted in the left mandible and just below the sternocleidomastoid muscle in the left neck. (b) Pre-operative contrast-enhanced computed tomography. A low-density area is seen from the left mandible to the left deep neck. The same area has a contrast effect on the margins and an internal septum.

from the left submandibular space to the carotid artery space, and a diagnosis of neck abscess associated with left peritonsillitis was made (Figure 1(a)). Approximately 10 mL of pus was collected by puncture using a 20-G needle under ultrasound guidance, and samples were submitted for bacteriological testing. A contrast-enhanced computed tomography (CECT) revealed a huge abscess with a septum on the left side of the

neck; however, it did not show continuity from the root of the tooth to the abscess (Figure 1(b)). Conversely, although ring-enhancement was not accompanied in the left sub-tonsillar region, a continuous contrast effect was observed between the inferior pole of the left tonsil and the abscess.

On the same day, the patient was admitted to the hospital and underwent drainage under general anesthesia. Two

transverse incisions were made on the left side of the neck, and the pus was drained from the same area without tracheostomy. After copious saline irrigation, a drain was inserted. Since both gram-positive cocci and negative rods were detected in the culture results of the pus collected with puncture prior to drainage, intravenous administration of meropenem 0.5 g three times a day was commenced. In the follow-up of the culture results of the pus, only *Parvimonas micra* was found to be growing on postoperative day six. Therefore, the antibacterial drug was changed to 3 g of ampicillin/sulbactam three times a day by intravenous infusion until day 9, after which amoxicillin/clavulanate (500 mg:125 mg) was orally administered three times a day for 1 week. All antimicrobial agents were susceptible to *Parvimonas micra* (Figure 2(a)). In combination with antibiotics, the wound was irrigated with saline solution once a day. The drain was removed on the 9th postoperative day, and the patient was discharged on the 13th postoperative day (Figure 2(b)).

Discussion

Cervical abscesses could be caused by pharyngitis, tonsillitis, dental infections, or trauma. In this case, although tooth loss and poor oral hygiene were observed, the lower left tooth had fallen out long ago and the CECT did not show continuity from the tooth root to the abscess. Contrastingly, a continuous contrast effect was observed between the inferior pole of the left tonsil and the abscess. Thus, the cervical abscess was associated with left peritonsillitis; surgical drainage and antibiotic administration are the recommended treatment. In recent years, ultrasound-guided puncture and drainage have reportedly been useful.^{3,4} Puncture drainage reduces disadvantages, such as the presence of undesirable scars and neurovascular injuries, and can also reduce contamination.⁵ This would be useful for accurate identification of causative bacteria and appropriate antimicrobial therapy.

In this case, we performed ultrasound-guided puncture and drainage to confirm the presence of an abscess, and submitted a pus specimen for culture and sensitivity testing. If drainage by puncture was sufficient, we had planned to follow up with antimicrobial therapy only. However, CECT showed residual abscess; therefore, we subsequently carried out urgent incision and drainage on the same day. An incision along the anterior border of the sternocleidomastoid muscle would have resulted in a large wound. Therefore, two small incisions were made along the dermatome line to drain the abscess because the abscess was multi-focal. For antibiotic treatment, penicillin-based drugs containing beta-lactamase inhibitors are often chosen because anaerobic bacteria of *Streptococcus* spp., *Staphylococcus* spp., and *Fusobacterium* spp. are often detected. In addition, carbapenems are sometimes chosen because cases with *Klebsiella* infection have been reported.^{2,6} In this patient, both gram-positive and gram-negative bacteria were detected in the

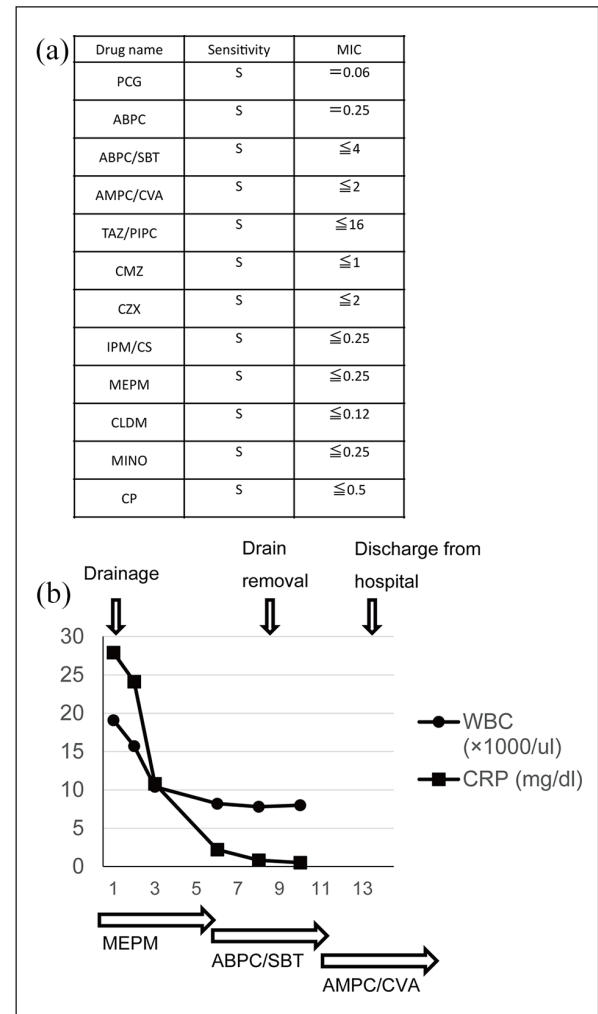


Figure 2. (a) Susceptibility of various antimicrobial agents to *Parvimonas micra*. No resistance to any antimicrobial agent observed. (b) Post-hospitalization progress. On the day of admission, the abscess was punctured and incision and drainage were performed under general anesthesia. Antimicrobial agents were administered as shown in this figure. The patient's symptoms improved quickly with a decrease in inflammation. MIC: minimal inhibitory concentration; PCG: penicillin G; ABPC: ampicillin; ABPC/SBT: ampicillin/sulbactam; AMPC/CVA: amoxicillin/clavulanate; TAZ/PIPC: tazobactam/piperacillin; CMZ: cefmetazole; CZX: ceftizoxime; IPM/CS: imipenem/cilastatin; MEPM: meropenem; CLDM: clindamycin; MINO: minocycline; CP: chloramphenicol; WBC: white blood cell; CRP: C-reactive protein.

rapid culture of the pus; therefore, we first treated the patient with carbapenem antibiotics. Since *Parvimonas micra* was identified as the causative organism on day 6, antibiotic therapy was promptly de-escalated. *Parvimonas micra* is a gram-positive anaerobe that constitutes the bacterial flora of the oral and gastrointestinal tracts and reportedly, closely associates with chronic periodontal disease and dental abscesses. *Peptostreptococcus micra*, which was formerly classified in the genus *Peptostreptococcus*, was reclassified into the genus *Micromonas* in 1999 and named *Micromonas micra*,

and reclassified into the genus *Parvimonas* in 2006 and named *Parvimonas micra*.^{7,8} Reportedly, *Parvimonas micra* can be difficult to identify by some bacteriological methods and can only be identified using new techniques such as 16S rRNA gene sequencing and matrix-assisted laser desorption ionization–time of flight mass spectrometry (MALDI-TOF MS).⁹ The pathogenicity of *Parvimonas micra* is due to the presence of capsule-forming strains, high protease activity, and toxicity of hydrogen sulfide formed by the use of glutathione.⁴

Although detection of *Parvimonas micra* in cervical abscesses has not been reported, it would not be surprising if it caused cervical abscesses owing to the nature of the organism. There may be three possible reasons for the lack of reporting: (1) the change in the bacterial classification method (from phenotypic classification based on morphology and biochemical properties to genetic classification); (2) difficulty in identification by clinical examination; and (3) in many cases, bacteriological examination involving submitting pus for examination that has been exposed to the open air after drainage. The accurate identification of the causative organism in our case was possible because the bacteriological examination was performed by submitting a puncture prior to the incision and drainage of pus with appropriate laboratory methods. The clinical features and drug susceptibility of infections caused by *Parvimonas micra* have not been extensively studied because laboratory identification has historically been difficult. Reportedly, 3.2% of the patients with *Parvimonas micra* infection showed resistance to metronidazole; however, the majority of patients did not show significant resistance to general antimicrobial agents.¹⁰ Our patient was susceptible to meropenem, ampicillin/sulbactam, and amoxicillin/clavulanate, and was not found to be resistant to any antimicrobial agent.

Conclusion

We encountered a case of cervical abscess caused by *Parvimonas micra* infection. In cases with an infectious disease, a significant difference is seen in the severity of the disease depending on the causative organism; therefore, it is desirable to collect appropriate specimens, identify the organism, and select the appropriate treatment. Collecting pus by puncture, prior to incision and drainage, for pus examination is imperative in the treatment of a cervical abscess.

Acknowledgements

The authors thank Editage (www.editage.com) for English language editing.

Declaration of conflicting interests

The author(s) declared no potential conflicts of interest with respect to the research, authorship, and/or publication of this article.

Ethical approval

Our institution does not require ethical approval for reporting individual cases or case series.

Funding

The author(s) received no financial support for the research, authorship, and/or publication of this article.

Statement of human and animal rights

This article does not contain any studies with human or animal subjects.

Statement of informed consent

Written informed consent was obtained from the patient for using the data in this study.

ORCID iD

Takeshi Tsuda  <https://orcid.org/0000-0002-6861-1700>

References

1. Velhonoja J, Lääveri M, Soukka T, et al. Deep neck space infections: an upward trend and changing characteristics. *Eur Arch Otorhinolaryngol* 2020; 277(3): 863–872.
2. Rijal S and Romdhoni AC. Bacteria pattern, results of antibiotic sensitivity test, and complications of deep neck abscess patients in Dr. Soetomo General Hospital. *Biomol Health Sci J* 2018; 1(2): 124.
3. Tanaka K, Tsunoda A, Tou M, et al. Minimally invasive and inexpensive percutaneous abscess drainage using an indwelling needle cannula. *Am J Otolaryngol* 2020; 41(6): 102664.
4. Riggio MP and Lennon A. Identification of oral *Peptostreptococcus* isolates by PCR-restriction fragment length polymorphism analysis of 16S rRNA genes. *J Clin Microbiol* 2003; 41(9): 4475–4479.
5. Kessler L, Piemont Y, Ortega F, et al. Comparison of microbiological results of needle puncture vs. superficial swab in infected diabetic foot ulcer with osteomyelitis. *Diabet Med* 2006; 23(1): 99–102.
6. Paul WF, Howard W, Francis BH, et al. *Cummings otolaryngology: head and neck surgery*. 7th ed. Philadelphia, PA: MOSBY Elsevier, 2010, pp. 226–233.
7. Murdoch DA and Shah HN. Reclassification of *Peptostreptococcus magnus* (Prevot 1933) Holdeman and Moore 1972 as *Finegoldia magna* comb. nov. and *Peptostreptococcus micros* (Prevot 1933) Smith 1957 as *Micromonas micros* comb. nov. *Anaerobe* 1999; 5(5): 555–559.
8. Tindall BJ and Euzéby JP. Proposal of *Parvimonas* gen. nov. and *Quatricoccus* gen. nov. as replacements for the illegitimate, prokaryotic, generic names *Micromonas* Murdoch and Shah 2000 and *Quatricoccus* Maszenan et al. 2002, respectively. *Int J Syst Evol Microbiol* 2006; 56(Pt 11): 2711–2713.
9. Watanabe T, Hara Y, Yoshimi Y, et al. Clinical characteristics of bloodstream infection by *Parvimonas micra*: retrospective case series and literature review. *BMC Infect Dis* 2020; 20(1): 578.
10. Cobo F, Rodríguez-Granger J, Sampedro A, et al. Pleural effusion due to *Parvimonas micra*. A case report and a literature review of 30 cases. *Rev Esp Quimioter* 2017; 30(4): 285–292.