



Inflammation and Infection

Demonstrative Imaging of Emphysematous Cystitis

Tal May^{a,*}, Avi Stein^a, Roni Molnar^{a,b,**}, Yoram Dekel^a^a Carmel Medical Center, Department of Urology, 7 Michal Street, Haifa, Israel^b Carmel Medical Center, Department of Radiology, 7 Michal Street, Haifa, Israel

ARTICLE INFO

Article history:

Received 10 January 2016

Received in revised form

29 February 2016

Accepted 1 March 2016

Keywords:

Emphysematous cystitis

Computed tomography

Urinary bladder

ABSTRACT

This case report presents an incidental finding of emphysematous cystitis on computed tomography (CT) scan done as part of evaluating abdominal pain in a 78 years old man with a history of metastatic thymus carcinoma.

© 2016 The Authors. Published by Elsevier Inc. This is an open access article under the CC BY-NC-ND license (<http://creativecommons.org/licenses/by-nc-nd/4.0/>).

Introduction

Emphysematous cystitis is a rare infection of the urinary bladder produced by gas forming uropathogens. *Escherichia coli* and *Klebsiella pneumoniae* are the predominant pathogens. The major risk factor is diabetes mellitus.¹ It has been postulated that the high tissue glucose levels provides the substrate for the microorganisms which are able to start fermentation of the glucose, resulting in the production of carbon dioxide. The clinical presentation may be atypical and unrelated to the degree of inflammation. Abdominal pain is the major clinical manifestation.¹ The best diagnostic tool is abdominal CT,² which may demonstrate the extent and the location of the gas collection in and around the bladder wall, or an air-fluid level in the bladder.^{3–5}

Case report

A 78 years old male, with a history of metastatic thymic carcinoma previously treated by chemotherapy, was admitted because

of dizziness and ataxia. Cranial CT scan of the head showed a number of brain lesions suspected to be of metastatic origin. Radiation therapy was advised and corticosteroid therapy was initiated. Neither systemic fever nor any lower urinary tract symptoms were reported. Laboratory examination revealed only mild leukocytosis.

Due to abdominal pain, CT scan was ordered. The CT scan revealed the presence of large amount of gas in the bladder wall which could be clearly seen using the “lung window” (Figs. 1 and 2). In addition, there were a number of air bubbles adjacent to the urinary bladder, without any intra-luminal pathology. Urinary culture was obtained and a urethral Foley catheter was inserted. Urine culture grew *E. coli* and based on the sensitivity ofloxacin treatment was initiated. Due to the patient worsening general condition, he was referred to the oncology department for radiation therapy.

Discussion

Gas forming bacteria are uncommonly reported as pathogens in the urinary tract mostly in diabetic patients. Emphysematous pyelonephritis is presented by air detected in the kidney or collecting system. It may be a life threatening infection frequently requiring surgical treatment. Emphysematous cystitis is a rare condition associated with an increased risk of asymptomatic

* Corresponding author. Tel.: +972 525922295.

** Corresponding author. Carmel Medical Center, Department of Radiology, 7 Michal Street, Haifa, Israel.

E-mail address: talmay9@gmail.com (T. May).

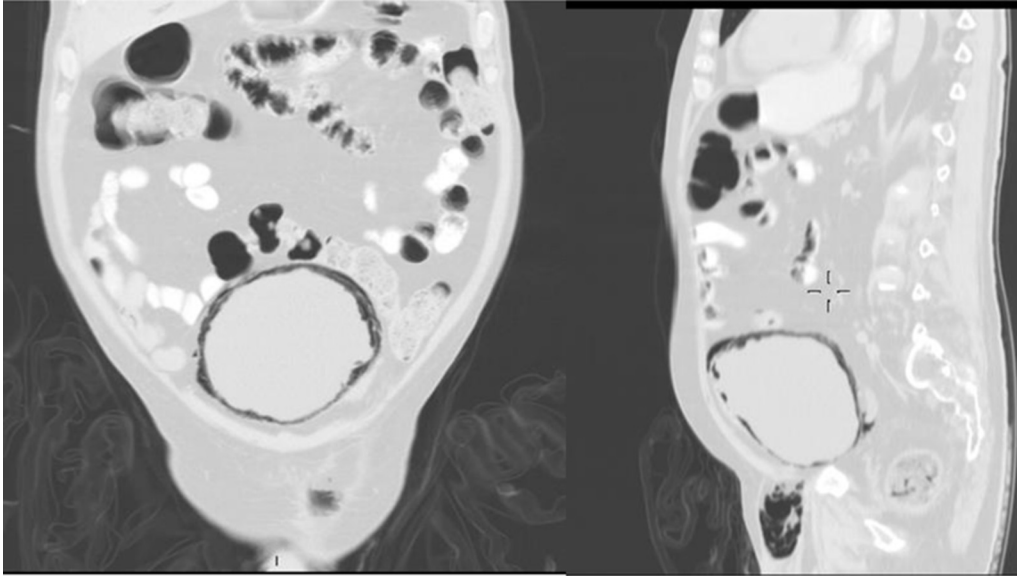


Figure 1. CT scan of the abdomen in coronal and sagittal view (lung window): diffuse air bubbles within the bladder wall.

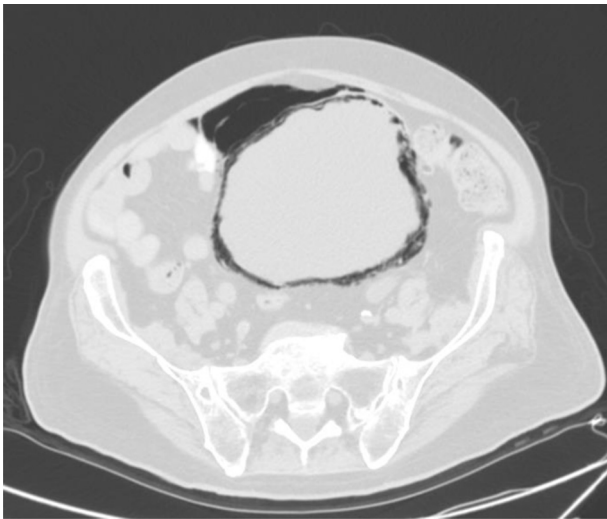


Figure 2. CT scan of the pelvis in axial view (lung window): diffuse air infiltration within the bladder wall.

bacteriuria. Patients with indwelling urethral catheters, long standing UTIs, bladder outlet obstruction or neurogenic bladders are considered to be at higher risk to develop complicated UTIs such as emphysematous cystitis. Most often they are asymptomatic.

As in the presented case, emphysematous cystitis is characterized mainly by pockets of gas forming in and around the bladder wall caused by ferment bacteria.⁵ The herewith presented CT scan images clearly demonstrate diffuse air bubbles within the bladder wall.

References

1. Grupper M, Kravtsov A, Potasman I. Emphysematous cystitis: illustrative case report and review of the literature. *Medicine*. 2007;86:47.
2. Mokabberi R, Ravakhah K. Emphysematous urinary tract infection: diagnosis, treatment and survival (case review series). *Am J Med Sci*. 2007;333(2):111–116.
3. Goldman SM, Fishman EK. Upper urinary tract infection: the current role of CT, ultrasound, and MRI. *Semin Ultrasound CT MR*. 1991;12:335–360.
4. Joseph RC, Amendola MA, Artze ME, et al. Genitourinary tract gas: imaging evaluation. *Radiographics*. 1996;16:295–308.
5. Quint HJ, Drach GW, Rappaport WD, Hoffmann CJ. Emphysematous cystitis: a review of the spectrum of disease. *J Urol*. 1992;147:134–137.