



Case Report

Delayed diagnosis of shunt overdrainage following functional hemispherotomy and ventriculoperitoneal shunt placement in a hemimegalencephaly patient



Yasunori Nagahama ^{a,*}, David Peters ^b, Sho Kumonda ^c, Adam Vesole ^b, Charuta Joshi ^d, Brian J. Dlouhy ^a, Hiroto Kawasaki ^a

^a Department of Neurosurgery, University of Iowa Hospitals and Clinics, Iowa City, IA, USA

^b Carver College of Medicine, University of Iowa Hospitals and Clinics, Iowa City, IA, USA

^c Surgery residency program, Teine Keijinkai Hospital, Sapporo, Japan

^d Department of Pediatrics, University of Iowa Hospitals and Clinics, Iowa City, IA, USA

ARTICLE INFO

Article history:

Received 5 October 2016

Received in revised form 26 November 2016

Accepted 24 December 2016

Available online 24 January 2017

Keywords:

Hemimegalencephaly

Peri-insular functional hemispherotomy

Hemispherectomy

Postoperative hydrocephalus

Shunt overdrainage

ABSTRACT

Shunt overdrainage represents a nebulous condition of variable clinical and imaging presentations, where the diagnosis is primarily clinical. The condition presents a diagnostic challenge particularly in patients with cognitive impairment and developmental delays. Here we present a 3-year-old boy with drug-resistant focal onset seizures due to hemimegalencephaly who previously underwent functional hemispherotomy followed by ventriculoperitoneal shunt placement for postoperative hydrocephalus. The subsequent clinical course was complicated by delayed diagnosis of shunt overdrainage in the absence of significant image findings. Maintaining a high index of suspicion for the possibility of shunt overdrainage is critical even in the face of unremarkable imaging findings.

© 2017 The Authors. Published by Elsevier Inc. This is an open access article under the CC BY-NC-ND license (<http://creativecommons.org/licenses/by-nc-nd/4.0/>).

1. Introduction

Postoperative hydrocephalus is a well-known sequela after a hemispheric disconnection procedure and necessitates ventriculoperitoneal (VP) shunt placement for cerebrospinal fluid (CSF) diversion [1]. Shunt overdrainage represents an incompletely understood condition of variable clinical presentations and imaging findings [2]. The diagnosis is primarily clinical [2], and can be challenging to identify in patients with cognitive impairment and developmental delays, where clinical information obtainable from patients and families may be limited. We present a case of delayed diagnosis of shunt overdrainage in a pediatric patient who previously underwent functional hemispherotomy for drug resistant focal onset seizures associated with hemimegalencephaly (HME). This case illustrates the challenge inherent in care of this patient population and a need for vigilance regarding the possibility of shunt overdrainage.

2. Case report

A 3-year-old boy with a history of right-sided functional hemispherotomy for focal onset seizures associated with HME and

subsequent hydrocephalus treated with VP shunt placement presented with episodes of nausea and emesis. The medical history also included premature birth at 29 weeks, developmental delay, and epilepsy since 1 month of the age (but without a history of infantile spasms). Prior to this encounter, he had initially been transferred from an outside hospital to the author's institution at the age of 13 months with increased seizure frequency refractory to multiple antiseizure drugs. Each seizure lasted for 30 s to a few minutes, occurred every 1 to 2 h, and involved left upper extremity jerking, eye blinking, eye deviation to the left, and lip smacking, along associated with impaired consciousness. On neurological examination, he was macrocephalic and awake, but non-verbal. No abnormal skin lesions were noted. He grimaced and withdrew his extremities from painful stimuli. Electroencephalography (EEG) showed continuous spikes from the right hemisphere, maximal at the central area. Magnetic resonance imaging (MRI) showed findings consistent with HME, including asymmetric hemispheres, larger on the right side. After the preoperative workup, the patient underwent right-sided peri-insular functional hemispherotomy (Fig. 1). The pathology specimen revealed clusters of immature neurons and supportive glial cells adjacent to periventricular white matter, a nodular arrangement of irregularly oriented neurons in the amygdala, and gliosis in the hippocampus. These results were consistent with incomplete differentiation and migration of neurons on histopathology in HME. Despite initial postoperative resolution of the seizures, he experienced seizure

* Corresponding author at: Department of Neurosurgery, University of Iowa Hospitals and Clinics, 200 Hawkins Drive, Iowa City, IA 52242, USA.

E-mail address: yasunori-nagahama@uiowa.edu (Y. Nagahama).

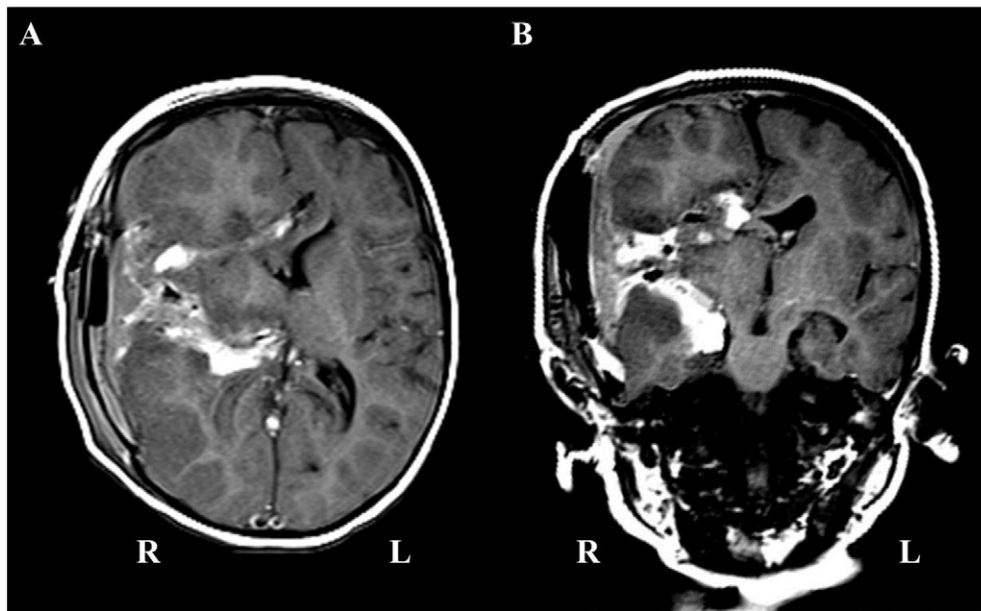


Fig. 1. T1 axial (A) and coronal (B) MRI images show expected postoperative changes after peri-insular functional hemispherotomy with high T1 signals corresponding to the areas of right hemispheric disconnection.

recurrence, and at 3 years of age underwent resection of residual incompletely disconnected tissue at the posteromedial ventral frontal lobe (both profuse bleeding from tissue resection and distorted brain anatomy as expected for HME had likely resulted in incomplete disconnection in this area during the first surgery). A few months later, he presented with an episode of unresponsiveness, followed by episodes of emesis, with an MRI finding of pseudomeningocele (Fig. 2A). Lumbar puncture revealed an opening pressure of 28 cm of H₂O, concerning for hydrocephalus. He underwent left frontal VP shunt placement for CSF diversion, with a Strata valve (Medtronic, Inc., USA) programmed at 1.5 (the setting can be adjusted to a different level as necessary with an external magnet from 0.5 up to 2.5 in 0.5 increments; the higher the setting of the valve, the more resistance to the CSF flow and thus less flow; the setting at 1.5 provides an opening pressure of about 7 and 9 cm of H₂O when a patient is lying or standing, respectively).

It was several weeks after the shunt placement that he presented to the emergency room (ER) for evaluation of episodes of nausea and emesis. The clinical and imaging workup were unremarkable, including shunt series and axial T2 MRI that showed an expected decrease in the size of the ventricles and pseudomeningocele (Fig. 2B). The symptoms spontaneously resolved, and he was discharged from the ER. He was brought back a few days later with vomiting as well as drowsiness

and abnormal eye movements. The workup was unremarkable again, including a nuclear shuntogram. The opening pressure at the time of the shuntgram dye injection was 7 cm of H₂O. A gastroenterology workup was also unremarkable. He was discharged after an overnight observation. He continued to have intermittent episodes every two to three weeks, lasting minutes to an hour and involving vomiting, loss of consciousness, and unresponsiveness, followed each time by spontaneous resolution of the symptoms. These episodes required multiple evaluations at the ER which continued to show the overall stable neuroimaging findings (Fig. 2C). Although the possibility of intermittent shunt malfunction was considered, the imaging studies were always unremarkable. Intracranial pressure (ICP) monitoring was not felt to be high yield, given the intermittent and infrequent nature of the presentations. About 5 months after the shunt placement, the Strata valve was re-adjusted from 1.5 up to 2.0 (i.e. higher resistance to the CSF flow and thus less CSF flow; the setting at 2.0 provides an opening pressure of about 10.5 and 12.5 cm of H₂O when a patient is lying or standing, respectively) to evaluate for the possibility of shunt overdrainage. The patient has not experienced recurrence of the episodes for over one year since the re-programming of the valve. The ventricular size was noted to be stable 3 months after the valve re-adjustment (Fig. 2D). The patient has also continued to be seizure-free since the second surgery completing the hemispherotomy.

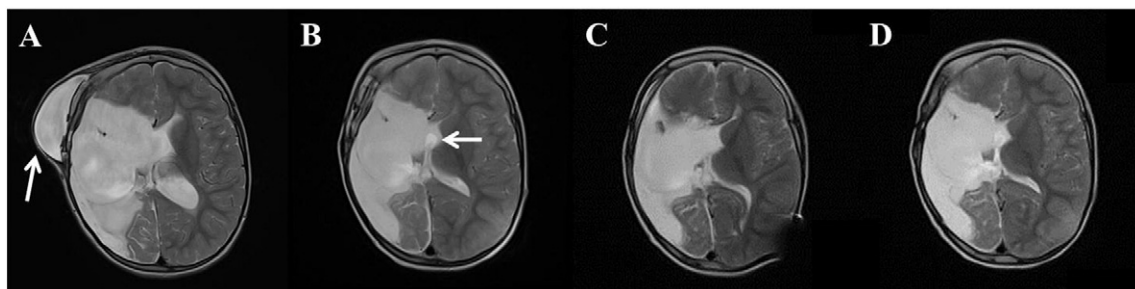


Fig. 2. Axial T2 MRI images obtained just before the shunt placement (A), about 10 days after the shunt surgery (B), about 5 months after the surgery and immediately before the shunt valve re-adjustment (C), and about 3 months after the valve re-programming (D) show overall stable ventricular size and configuration, except an initial expected postoperative decrease in the size of the ventricles and pseudomeningocele. The white arrow in (A) points to a pseudomeningocele at the prior operative site, and the white arrow in (B) points to the approximate location the ventricular catheter tip (The catheter tip is not shown in this particular image slice).

3. Discussion

Hydrocephalus requiring CSF diversion continues to be a possible sequela of hemispheric disconnection (about 20% for functional hemispherectomy versus 30% for anatomic hemispherectomy) despite a decreased incidence of postoperative hydrocephalus due to the technical improvements that rely more on disconnection and minimize tissue resection (i.e. functional hemispherotomy) [1]. Peri-insular functional hemispherotomy, performed in this case, represents one of the modern variants of functional hemispherotomy [3]. Functional hemispherotomy is performed to treat drug resistant epilepsy resulting from various medical conditions, including HME [4]. HME is a rare congenital condition involving abnormal development and malformation of the brain characterized by abnormal enlargement of an affected entire hemisphere [4]. These patients typically present with drug resistant epilepsy, cognitive impairments, and contralateral motor deficits. The severe epilepsy justifies early surgical intervention [4].

The patient in this report promptly underwent peri-insular functional hemispherotomy, followed by an unremarkable postoperative course and seizure resolution. The surgical intervention for HME is known to be highly challenging because of the increased size and consistency of the affected hemisphere making surgical manipulations difficult [4]. In addition, increased vascularity and more fragile vasculature may result in greater intraoperative blood loss [4]. The distorted anatomy also contributes to the difficulty of the surgery, particularly in disconnection of the posterior frontal base region where no clear boundary can be appreciated between the gray matter of the frontal lobe and that of the hypothalamus as well as the basal ganglia [4]. This patient required resection of the remaining posteromedial ventral frontal lobe to complete hemispherotomy after recurrence of the seizures.

In addition to the type of hemispheric disconnection (i.e. functional versus anatomic hemispherectomy), the etiology necessitating the procedure is known to be associated with subsequent development of hydrocephalus requiring CSF diversion [5]. A higher rate of need for CSF diversion has been reported after hemispherectomy for HME (i.e. 40%) [5]. The patient in this case presented after the second surgery with the clinical and imaging findings, concerning for hydrocephalus, namely decreased responsiveness, emesis, and pseudomeningocele. Increased CSF pressure was confirmed with the opening pressure of lumbar puncture. The time course of development of hydrocephalus requiring shunt placement after hemispherectomy is known to be variable, and has been reported to vary from the immediate postoperative time to 8.5 years after the procedure [1].

Shunt overdrainage is a condition with various clinical presentations, ranging from mild to very severe symptoms, often requiring

multiple evaluations and admission in some cases [2]. The condition typically presents with postural headache as well as nausea, emesis, and irritability, exacerbated in an upright position and alleviated in a supine position [2]. The diagnosis is primarily clinical [2], but clinical information obtainable from patients with cognitive impairment and developmental delays may be limited. Imaging studies may reveal slit ventricles in some patients, but others may have normal or enlarged ventricles [2]. The lack of sensitive and specific neuroimaging findings complicates the diagnosis. Intermittent symptoms are considered to be a result of intermittent shunt occlusion caused by collapsed ventricle obstructing inlet port of the ventricular tube. In this case, because of the large brain tissue defect that resulted from the hemispherotomy, the imaging studies did not appear to show a slit ventricle. The infrequent and intermittent nature of the symptoms made continuous invasive ICP monitoring not realistically feasible. Furthermore, the ventricular size may be stable even after shunt overdrainage is addressed and the associated symptoms improve [2]. In this case, the ventricular size continued to appear to remain stable even after the Strata valve adjustment and symptom resolution, except for initial expected postoperative decrease. Care providers must remain cognizant of the possibility of shunt overdrainage, especially in patients with cognitive impairment and developmental delays regardless of the size of ventricles.

4. Conclusion

Postoperative hydrocephalus requiring CSF diversion is a well-recognized phenomenon after hemispheric disconnection for drug resistant epilepsy. Shunt overdrainage represents a nebulous condition of variable clinical and imaging presentations, where the diagnosis is primarily clinical. Taking a detailed history and maintaining a high index of suspicion for the possibility of shunt overdrainage are critical for improving outcomes.

References

- [1] Lew SM, Matthews AE, Hartman AL, Haranhalli N. Posthemispherectomy hydrocephalus: results of a comprehensive, multiinstitutional review. *Epilepsia* 2013;54:383–9.
- [2] Kondageski C, Thompson D, Reynolds M, Hayward RD. Experience with the strata valve in the management of shunt overdrainage. *J Neurosurg* 2007;106:95–102.
- [3] Villemure JG, Daniel RT. Peri-insular hemispherotomy in paediatric epilepsy. *Childs Nerv Syst* 2006;22:967–81.
- [4] Di Rocco C, Battaglia D, Pietrini D, Piastra M, Massimi L. Hemimegalencephaly: clinical implications and surgical treatment. *Childs Nerv Syst* 2006;22:852–66.
- [5] Phung J, Krogstad P, Mathern GW. Etiology associated with developing posthemispherectomy hydrocephalus after resection-disconnection procedures. *J Neurosurg Pediatr* 2013;12:469–75.