

Efficiency and accuracy of artificial intelligence in the radiographic detection of periodontal bone loss: A systematic review

Asmhan Tariq¹, Fatmah Bin Nakhi¹, Fatema Salah¹, Gabass Eltayeb¹, Ghada Jassem Abdulla¹, Noor Najim¹, Salma Ahmed Khedr¹, Sara Elkerdasy¹, Natheer Al-Rawi¹, Sausan Alkawas¹, Marwan Mohammed¹, Shishir Ram Shetty^{1,*}

¹Department of Oral and Craniofacial Health Sciences, College of Dental Medicine, University of Sharjah, Sharjah, United Arab Emirates

ABSTRACT

Purpose: Artificial intelligence (AI) is poised to play a major role in medical diagnostics. Periodontal disease is one of the most common oral diseases. The early diagnosis of periodontal disease is essential for effective treatment and a favorable prognosis. This study aimed to assess the effectiveness of AI in diagnosing periodontal bone loss through radiographic analysis.

Materials and Methods: A literature search involving 5 databases (PubMed, ScienceDirect, Scopus, Health and Medical Collection, Dentistry and Oral Sciences) was carried out. A specific combination of keywords was used to obtain the articles. The PRISMA guidelines were used to filter eligible articles. The study design, sample size, type of AI software, and the results of each eligible study were analyzed. The CASP diagnostic study checklist was used to evaluate the evidence strength score.

Results: Seven articles were eligible for review according to the PRISMA guidelines. Out of the 7 eligible studies, 4 had strong CASP evidence strength scores (7-8/9). The remaining studies had intermediate CASP evidence strength scores (3.5-6.5/9). The highest area under the curve among the reported studies was 94%, the highest F1 score was 91%, and the highest specificity and sensitivity were 98.1% and 94%, respectively.

Conclusion: AI-based detection of periodontal bone loss using radiographs is an efficient method. However, more clinical studies need to be conducted before this method is introduced into routine dental practice. (*Imaging Sci Dent* 2023; 53: 193-8)

KEY WORDS: Artificial Intelligence; Radiography, Dental; Periodontitis; Alveolar Bone Loss; Diagnosis

Introduction

Periodontal disease is characterized by destruction of the periodontal attachment apparatus, loss of the alveolar bone, and, in untreated cases, tooth loss.¹ This oral disease is quite prevalent, affecting between 20-50% of the population. It is associated with various factors, including smoking, poor oral hygiene, and certain systemic diseases.^{2,3} An early diagnosis of periodontal disease is crucial for devising an appropriate treatment plan and ensuring a positive prognosis. In

addition to clinical examinations, which include periodontal pocket probing, bleeding on probing, and determining the clinical attachment level, radiological examinations serve as a supplementary method for diagnosing periodontal disease.⁴

With ever-changing technology, increasingly sophisticated methods are being developed to enhance and refine medical diagnostics. One such advancement is artificial intelligence (AI), a technology that emulates human intelligence.⁵ One form of AI is the convolutional neural network (CNNs). CNNs are a category of artificial neural networks that analyze visual imagery, making them particularly useful in the radiographic assessment of bone loss in periodontal disease.⁶ This technology employs deep learning and is not limited to executing pre-programmed instructions. Remarkably,

Received April 26, 2023; Revised June 18, 2023; Accepted June 23, 2023

Published online August 2, 2023

*Correspondence to : Dr. Shishir Ram Shetty

Department of Oral and Craniofacial Health Sciences, College of Dental Medicine, University of Sharjah, 27272 Sharjah, United Arab Emirates
Tel) 971-6-505-7333, E-mail) drshishirshettyomr@yahoo.com

Copyright © 2023 by Korean Academy of Oral and Maxillofacial Radiology

This is an Open Access article distributed under the terms of the Creative Commons Attribution Non-Commercial License (<http://creativecommons.org/licenses/by-nc/3.0>) which permits unrestricted non-commercial use, distribution, and reproduction in any medium, provided the original work is properly cited.

Imaging Science in Dentistry · pISSN 2233-7822 eISSN 2233-7830

CNNs can also “gain experience” or learn from practice, thereby assisting healthcare providers in achieving accurate diagnoses and effective future treatment outcomes.⁷

To the best of our knowledge, very few systematic reviews have analyzed the role of AI in the detection of periodontal bone loss. The purpose of this study was to systematically review the published articles regarding the efficiency of AI in detecting periodontal bone loss.

Materials and Methods

Research question

The application of AI in radiographic detection of periodontal diseases will depend on the evidence reported in clinical studies. This systematic review was centered around the following research question: How efficient and accurate are the current clinical applications of artificial intelligence in the radiographic diagnosis of periodontal diseases?

Search strategy and protocol

A comprehensive literature search was conducted across several databases, including PubMed, ScienceDirect, Scopus, and Dentistry and Oral Sciences (EBSCO). This was supplemented with a manual search. The search process spanned from November 2, 2021, to February 16, 2022. All the articles identified were published within the period of 2018 to 2022.

For the search strategy, a set of keywords was used in combinations in the databases to generate various results. The keyword combinations, structured according to the Boolean method, were “artificial intelligence (OR deep learning OR convolutional neural network)” AND “periodontal disease (OR bone loss OR periodontitis)” AND “Radiography (OR panoramic radiograph OR periapical radiography).” Other keywords, such as “detect” and “diagnosis,” were used as well.

Eligibility criteria

This study included full-text articles in English that described research utilizing AI to detect periodontal bone loss in dental radiographs, specifically panoramic and periapical radiographs. Review articles, communications, commentaries, case reports, and opinion papers were excluded. Non-radiographic studies involving the use of AI to detect periodontitis were also excluded.

Data extraction

The detailed data extraction procedure was conducted in accordance with the PRISMA (Preferred Reporting Items

for Systematic Reviews and Meta-Analyses) guidelines (Fig. 1).⁸

The screening procedure was independently conducted by 10 reviewers, divided into pairs for each database. If a disagreement arose, a third reviewer, who was a supervising faculty member, was brought in to resolve the issue.

The keyword combinations specified earlier were utilized to retrieve 2,290 articles from various databases: 1,125 from the Health and Medical Collection (ProQuest), 358 from ScienceDirect, 311 from Dentistry and Oral Science, 424 from PubMed, and 72 from Scopus. These five groups then reviewed the 2,290 articles to eliminate any duplicates, resulting in a total of 375 articles. After further screening for full-text availability, 37 articles remained. Twenty of the 37 articles were removed because they were review articles, communications, commentaries, conference papers, and opinion papers. This left 17 articles qualifying for the eligibility stage, 10 of which were non-radiographic studies pertaining to AI and periodontitis. Finally, 7 full-text articles were eligible for the qualitative analysis.

The raw data for this systematic review, recorded in an Excel spreadsheet, are available at Figshare.com (doi: 10.6084/m9.figshare.19586008).

The studies were assessed using the Critical Appraisal Skills Programme (CASP) diagnostic study checklist.⁹

Results

Evidence table

An evidence table was made to summarize the data of the articles (Table 1). The table contains specific parameters such as author, year, country, sample type and size, the AI software used, main study findings, and statistical findings (area under the curve [AUC], sensitivity, specificity).¹⁰⁻¹⁶

Study quality assessment

The studies were assessed using the CASP diagnostic study checklist, which includes 12 questions.⁹ Nine of the 12 questions were assigned 1 point each (3 questions in the checklist required descriptive answers and were therefore not assigned a score). These 9 questions were used for the quality assessment of the 7 eligible articles. It was found that out of the 7 eligible studies, 4 had strong evidence (scores ranging between 7 and 8). The remaining studies had intermediate-strength evidence (scores ranging between 3.5 and 6.5) (Table 2).

Study characteristics and outcomes

All of the studies were equivalence trials, with sample siz-

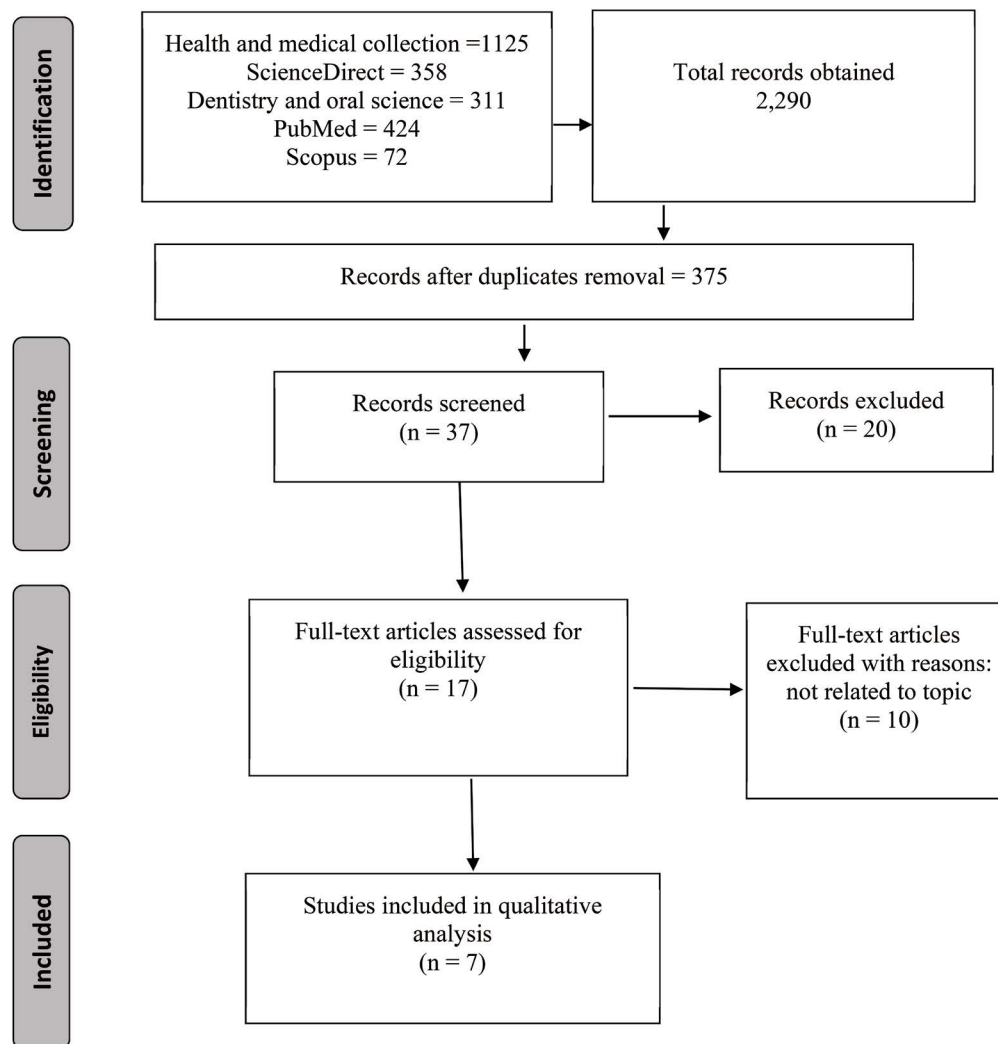


Fig. 1. PRISMA flowchart of the systematic review.

es ranging from 30 to 2276 patients. Three of the 7 studies were conducted in South Korea.^{10,11,15} German, Turkish, Thai, and Swiss researchers conducted 1 study each.^{12-14,16} The dates of the published studies ranged from 2018 to 2022. One study was published in 2018,¹⁵ 2 in 2019,^{10,12} 3 in 2020,^{11,13,14} and 1 in 2022.¹⁶ All 7 studies evaluated the use of AI models (specifically, the CNN subtype of deep learning) to detect periodontal bone loss.¹⁰⁻¹⁶ Five articles demonstrated accuracy above 80%, while two had accuracy results below 80%.

Three studies used the F1 score as the metric to measure accuracy. The F1 score combines the precision and recall score of an AI model.^{10,12,14} The study by Kurt Bayrakdar et al.¹⁴ showed the highest F1 score (91%), while Kim et al.¹⁰ and Krois et al.¹² found F1 scores between 75% and 78% in their studies.

The area under the curve (AUC) was also used to assess

the efficiency of the learning machines. This parameter represents a model's ability to distinguish changes or abnormalities in images. The highest AUC was 94%.¹² Lower AUC scores were reported by Lee et al. and Kim et al.^{10,15}

Specificity was analyzed in 5 of the 7 studies. Zadrožny et al.¹⁶ reported the highest specificity (98.1%), followed by Kim et al.¹⁰ (92%). In contrast, the lowest specificity score (63%) was reported by Krois et al.¹² Two studies reported specificity ranging from 71% to 88%.^{13,14}

Sensitivity metrics were reported by 6 of the 9 studies. Kurt Bayrakdar et al.¹³ (94%) and Krois et al.¹² (92%) reported the highest sensitivity.

Discussion

The application of deep learning-based technology for identifying periodontal bone loss in panoramic and periapi-

Table 1. Evidence table for the eligible studies

Author, year, country	Sample type and size	AI software used	Main study findings	Statistical findings	Evidence strength score
Kim et al., 2019 ¹⁰ South Korea	12,179 panoramic radiographs	DeNTNet using deep learning (CNN)	DeNTNet was more effective in detecting PBL on panoramic radiographs than dental clinicians.	F1 score: DeNTNet: 0.75 Clinicians: 0.69 AUROC: 0.95 Sensitivity:0.87 Specificity:0.96	5.5/9 Intermediate evidence
Chang et al., 2020 ¹¹ South Korea	518 panoramic radiographs	Hybrid of deep learning for detection and CAD for classification.	The hybrid model showed high accuracy and excellent reliability in detecting radiographic bone loss.	AUC/Sensitivity/specificity: not mentioned. The mean absolute difference between AI and the radiologist diagnosis was 0.25	5.5/9 Intermediate evidence
Krois et, al., 2019 ¹² Germany	85 panoramic radiographs	CNN	The accuracy and reliability of the CNN were similar to those of dentists, but the diagnosis was faster with CNN.	Mean accuracy: Dentists: 0.06 CNN: 0.067 Sensitivity:0.02 Specificity: 0.14	7/9 Strong evidence
Kurt Bayrakdar et al., 2020 ¹³ Turkey	2,276 panoramic radiographs	CNN	The utilization of AI for interpreting dental radiographs facilitated the prompt diagnosis and treatment planning of periodontal diseases.	Sensitivity 0.9429 Specificity 0.8857	7/9 Strong evidence
Thanathornwong and Suebnukarn, 2020 ¹⁴ Thailand	100 panoramic radiographs	Regional CNNs	R-CNN tended to reduce the effort and time required for the automated screening of periodontal diseases.	Sensitivity: 0.84 Specificity:0.88	8/9 Strong evidence
Lee et al., 2018 ¹⁵ South Korea	1,740 periapical radiographs	Deep CNN	Deep CNN proved to be very effective and efficient in detecting periodontal bone loss compared to experienced periodontists.	Sensitivity specificity: not mentioned. CNN: AUC (95%)	7.5/9 Strong evidence
Zadrożny et al., 2022 ¹⁶ Switzerland.	30 panoramic radiographs	Diagnocat software	The AI system can be very useful in the initial screening of panoramic radiographs.	Specificity: >0.9 Sensitivity: >0.9 for assessment of missing teeth and prosthetic restorations, and >0.8 for PBL.	6.5/9 Intermediate evidence

PBL: periodontal bone loss, AI: artificial intelligence, CNN: convolutional neural network, R-CNN: region-based convolution neural network, AUROC: area under the receiver operating characteristic curve, CAD: computer-aided design, AUC: area under the curve

cal radiographs can greatly assist dental clinicians in making accurate diagnoses. This technology significantly cuts down on the time required for radiographic examinations, thereby allowing more time for clinical examinations and treatment planning.¹⁷⁻²⁰

Deep learning, a more complex subdomain of AI, utilizes mathematical algorithms to mimic the way the human brain perceives, processes, and learns new information.²¹ CNNs, which constitute a specific subtype of deep learning, are used to process and interpret radiographic and photographic images with high accuracy.²² It is anticipated that CNN models will be extensively applied in healthcare settings, particularly for automatic feature learning and disease clas-

sification in medical images. Current studies are exploring the use of CNN models for early detection of diseases such as cancer, neurological and eye disorders, and dental conditions.^{23,24} The majority of the articles included in this systematic review utilized region-based CNNs (R-CNNs) for the detection of periodontal bone loss.¹⁰⁻¹⁶

The process of using a CNN to detect radiographic changes follows a specific sequence. In the initial stage the radiographs are classified and annotated. They are then passed through the layers of the CNN, which is trained by various chain functions. Once the training is completed, validation and testing are carried out, typically using new datasets.²²⁻²⁵

Kurt Bayrakdar et al.¹³ used a CNN with 22 deep layers

Table 2. The CASP diagnostic checklist scores for each article

Authors and year	Title	Evidence scores
Kim et al., 2019 ¹⁰	DeNTNet: Deep Neural Transfer Network for the detection of periodontal bone loss using panoramic dental radiographs (Diagnostic)	5.5/9 Intermediate evidence
Chang et al., 2020 ¹¹	Deep Learning Hybrid Method to Automatically Diagnose Periodontal Bone Loss and Stage Periodontitis	5.5/9 Intermediate evidence
Krois et al., 2019 ¹²	Deep Learning for the Radiographic Detection of Periodontal Bone Loss	7/9 Strong evidence
Kurt Bayrakdar et al., 2020 ¹³	Success of artificial intelligence system in determining alveolar bone loss from dental panoramic radiography images	7/9 Strong evidence
Thanathornwong and Suebnukarn, 2020 ¹⁴	Automatic detection of periodontal compromised teeth in digital panoramic radiographs using faster regional convolutional neural networks.	8/9 Strong evidence
Lee et al., 2018 ¹⁵	Diagnosis and prediction of periodontally compromised teeth using a deep learning-based convolutional neural network algorithm	7.5/9 Strong evidence
Zadrozny et al., 2022 ¹⁶	Artificial Intelligence Application in Assessment of Panoramic Radiographs	6.5/9 Intermediate evidence

to analyze panoramic radiographs of periodontally healthy and diseased (with bone destruction) patients. In contrast, Kim et al.¹⁰ used CNN with transfer networks (DeNTNet) in their study. Thanathornwong and Suebnukarn¹⁴ used an R-CNN, which primarily focuses on object detection at a speed surpassing that of conventional CNNs. Krois et al.¹² used a deep learning CNN machine, supplemented with a transfer network, to detect periodontal bone loss. Two studies (Chang et al.¹¹ and Krois et al.¹²) reported that CNNs could be used for overall assessments of the bone level, cemento-enamel junction, level, and tooth long-axis.

In 6 out of the 7 studies, panoramic radiographs were used for the training, validation, and testing datasets.¹⁰⁻¹⁶ However, Kim et al.¹⁵ used cropped panoramic images in their study.¹⁰ Only 1 study used periapical radiographs. While panoramic radiographs are commonly used for detecting alveolar bone loss, they may not offer the same level of image detail and resolution as periapical radiographs.²⁶

In conclusion, the application of artificial intelligence in the investigation of periodontal disease can be beneficial and efficient in minimizing patient chairside time, though it is not without challenges. These challenges encompass ethical concerns related to patient trust and reliance, as well as technical issues such as the need for software updates, potential technical difficulties, and the costs and setup of the machinery.

The use of CNN-based deep learning models in clinical trials has demonstrated effectiveness in identifying periodontally compromised teeth. This approach also reduces patient chairside time by providing a quicker, yet accurate, diagnosis. However, relying solely on deep learning meth-

ods using radiographs may not provide sufficient precision. Dental specialists typically utilize a combination of methods, including clinical findings and periodontal chartings, in conjunction with radiographs.

Conflicts of Interest: None.

References

1. Highfield J. Diagnosis and classification of periodontal disease. *Aust Dent J* 2009; 54 Suppl 1: S11-26.
2. Bourgeois D, Inquimbert C, Ottolenghi L, Carrouel F. Periodontal pathogens as risk factors of cardiovascular diseases, diabetes, rheumatoid arthritis, cancer, and chronic obstructive pulmonary disease - is there cause for consideration? *Microorganisms* 2019; 7: 424.
3. Nazir M, Al-Ansari A, Al-Khalifa K, Alhareky M, Gaffar B, Almas K. Global prevalence of periodontal disease and lack of its surveillance. *ScientificWorldJournal* 2020; 2020: 2146160.
4. Ramenzoni L, Lehner M, Kaufmann M, Wiedemeier D, Attin T, Schmidlin PR. Oral diagnostic methods for the detection of periodontal disease. *Diagnostics (Basel)* 2021; 11: 571.
5. Al-Rawi N, Sultan A, Rajai B, Shuaeeb H, Alnajjar M, Alketbi M, et al. The effectiveness of artificial intelligence in detection of oral cancer. *Int Dent J* 2022; 72: 436-47.
6. Abiodun OI, Jantan A, Omolara AE, Dada KV, Mohamed NA, Arshad H. State-of-the-art in artificial neural network applications: a survey. *Heliyon* 2018; 4: e00938.
7. Shetty S, Reddy S, Shetty R, Halkai, R, Shetty S, Halkai, K. Machine learning in maxillofacial radiology: a review. *J Datta Meghe Inst Med Sci Univ* 2021; 16: 794-6.
8. Page MJ, McKenzie JE, Bossuyt PM, Boutron I, Hoffmann TC, Mulrow CD, et al. The PRISMA 2020 statement: an updated guideline for reporting systematic reviews. *BMJ* 2021; 372:

- n71.
9. [casp-uk.net](https://www.casp-uk.net) [Internet]. Oxford: Critical appraisal skills programme; 2023 [cited 2023 March 4]. Available from <https://www.casp-uk.net>.
 10. Kim J, Lee HS, Song IS, Jung KH. DeNTNet: deep neural transfer network for the detection of periodontal bone loss using panoramic dental radiographs. *Sci Rep* 2019; 9: 17615.
 11. Chang HJ, Lee SJ, Yong TH, Shin NY, Jang BG, Kim JE, et al. Deep learning hybrid method to automatically diagnose periodontal bone loss and stage periodontitis. *Sci Rep* 2020; 10: 7531.
 12. Krois J, Ekert T, Meinhold L, Golla T, Kharbot B, Witteimer A, et al. Deep learning for the radiographic detection of periodontal bone loss. *Sci Rep* 2019; 9: 8495.
 13. Kurt Bayrakdar S, Çeliko, Bayrakdar IS, Orhan K, Bilgir E, Odabas A, et al. Success of artificial intelligence system in determining alveolar bone loss from dental panoramic radiography images. *Cumhuriyet Dent J* 2020; 23: 318-24.
 14. Thanathornwong B, Suebnukarn S. Automatic detection of periodontal compromised teeth in digital panoramic radiographs using faster regional convolutional neural networks. *Imaging Sci Dent* 2020; 50: 169-74.
 15. Lee JH, Kim DH, Jeong SN, Choi SH. Diagnosis and prediction of periodontally compromised teeth using a deep learning-based convolutional neural network algorithm. *J Periodontal Implant Sci* 2018; 48: 114-23.
 16. Zadrożny Ł, Regulski P, Brus-Sawczuk K, Czajkowska M, Parkanyi L, Ganz S, et al. Artificial intelligence application in assessment of panoramic radiographs. *Diagnostics (Basel)* 2022; 12: 224.
 17. Uzun Saylan BC, Baydar O, Yeşilova E, Kurt Bayrakdar S, Bilgir E, Bayrakdar İŞ, et al. Assessing the effectiveness of artificial intelligence models for detecting alveolar bone loss in periodontal disease: a panoramic radiograph study. *Diagnostics (Basel)* 2023; 13: 1800.
 18. Ryu J, Lee DM, Jung YH, Kwon O, Park S, Hwang J, et al. Automated detection of periodontal bone loss using deep learning and panoramic radiographs: a convolutional neural network approach. *Appl Sci (Basel)* 2023; 13: 5261.
 19. Chartrand G, Cheng PM, Vorontsov E, Drozdal M, Turcotte S, Pal CJ, et al. Deep learning: a primer for radiologists. *Radiographics* 2017; 37: 2113-31.
 20. Nguyen TT, Larrivée N, Lee A, Bilaniuk O, Durand R. Use of artificial intelligence in dentistry: current clinical trends and research advances. *J Can Dent Assoc* 2021; 87: I7.
 21. Bordoloi D, Singh V, Sanober S, Buhari SM, Ujjan JA, Boddu R. Deep learning in healthcare system for quality of service. *J Healthc Eng* 2022; 2022: 8169203.
 22. Hwang JJ, Jung YH, Cho BH, Heo MS. An overview of deep learning in the field of dentistry. *Imaging Sci Dent* 2019; 49: 1-7.
 23. Miotto R, Wang F, Wang S, Jiang X, Dudley JT. Deep learning for healthcare: review, opportunities and challenges. *Brief Bioinform* 2018; 19: 1236-46.
 24. Corbella S, Srinivas S, Cabitza F. Applications of deep learning in dentistry. *Oral Surg Oral Med Oral Pathol Oral Radiol* 2021; 132: 225-38.
 25. Manerikar CR, Mani A, Mani S, Sachdeva S, Sodhi JK. Convolutional neural network in periodontology - innovative technology or new era? - a review. *Ann Rom Soc Cell Biol* 2021; 25: 7453-63.
 26. Hou GL, Hung CC, Yang YS, Shieh TY, Tsai CC. Radiographic alveolar bone loss in untreated Taiwan Chinese subjects with adult periodontitis measured by the digital scanning radiographic image analysis method. *Dentomaxillofac Radiol* 2003; 32: 104-8.