

Case Report

---

# Atypical Cogan's Syndrome with Choroidal Effusion: A Case Report

Won Hyuk Oh   Jee Hye Lee   Je Hyung Hwang

Department of Ophthalmology, Sanggye Paik Hospital, Inje University College of Medicine, Seoul, Republic of Korea

## Keywords

Angle-closure glaucoma · Choroidal effusion · Cogan's syndrome

## Abstract

Cogan's syndrome is a rare form of autoimmune vasculitis that manifests with ocular and audiovestibular symptoms. The clinical presentations of Cogan's syndrome can be classified as typical and atypical, and the auditory symptoms are classically similar to those seen in cases of Meniere's syndrome. Without treatment, Cogan's syndrome could become severe, resulting in sensorineural hearing loss in over 50% of patients. This report describes a rare case of uncontrolled intraocular pressure and choroidal effusion in a patient with atypical Cogan's syndrome. A 51-year-old woman was referred to our clinic on account of bilateral distortion of visual acuity and ocular pain following admission to the internal medicine department for bilateral hearing loss, acute renal failure, and fever. Upon ocular examination, we observed bilateral 2–3+ cells in the anterior chamber and closed-angle glaucoma, and choroidal effusion in the right eye. The intraocular pressure could not be controlled with topical and systemic medications, and a bilateral valve implant surgery was performed subsequently. Two weeks later, after systemic corticosteroid therapy, the choroidal effusion resolved. Cogan's syndrome can provoke angle-closure glaucoma with choroidal effusion in patients with a short axial length and shallow anterior chamber.

© 2022 The Author(s).  
Published by S. Karger AG, Basel

Won Hyuk Oh and Jee Hye Lee contributed equally to this work and both should be considered as first authors.

---

Correspondence to:  
Je Hyung Hwang, [violentviolet15@daum.net](mailto:violentviolet15@daum.net)

## Introduction

Cogan's syndrome, a rare autoimmune vasculitis, manifests with ocular involvement and audiovestibular symptoms. Based on the clinical presentation, Cogan's syndrome can be classified as typical and atypical: typical Cogan's syndrome is characterized by interstitial keratitis and vestibuloauditory dysfunction, and atypical Cogan's syndrome manifests with significant inflammatory eye diseases, such as scleritis, retinal vasculitis, retinal vein obstruction, and angle-closure glaucoma, in addition to interstitial keratitis [1]. The auditory symptoms in Cogan's syndrome are classically similar to those observed in cases of Meniere's syndrome. Without treatment, Cogan's syndrome could become severe, resulting in sensorineural hearing loss in over 50% of the patients [2].

Classically, ocular involvement includes interstitial keratitis, which manifests as photophobia, ocular pain, decreased visual acuity, and conjunctival injection, and it is usually bilateral [1]. A severe decrease in visual acuity is rare in Cogan's syndrome; however, blindness may occur [3]. Systemic involvement is more common in atypical Cogan's syndrome. In typical Cogan's syndrome, the interval between the onset of ocular and audiovestibular manifestations is less than 2 years. However, in atypical Cogan's syndrome, this interval broadens [4]. We herein present a case of bilateral atypical Cogan's syndrome with choroidal effusion and unusual ocular manifestation.

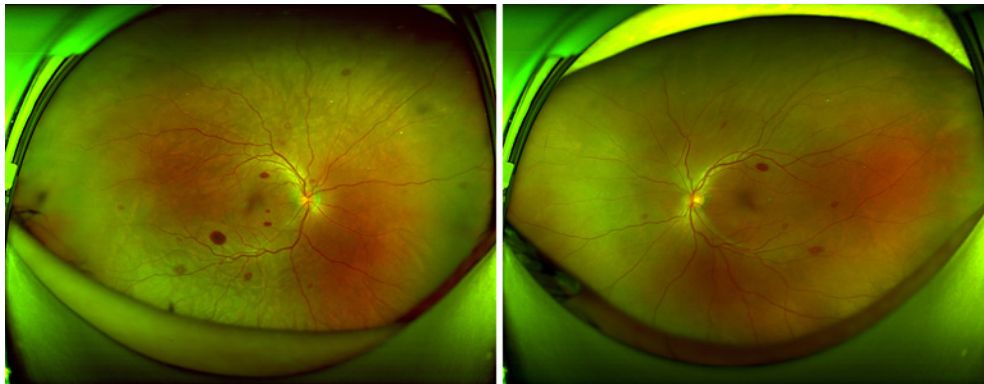
## Case Presentation

A 51-year-old Korean woman was referred to our ophthalmology clinic with a primary complaint of bilateral ocular pain and decreased visual acuity. The patient was initially admitted to the internal medicine department for acute renal failure, fever, and malaise. She was similarly referred to the ear, nose, and throat department for bilateral hearing loss.

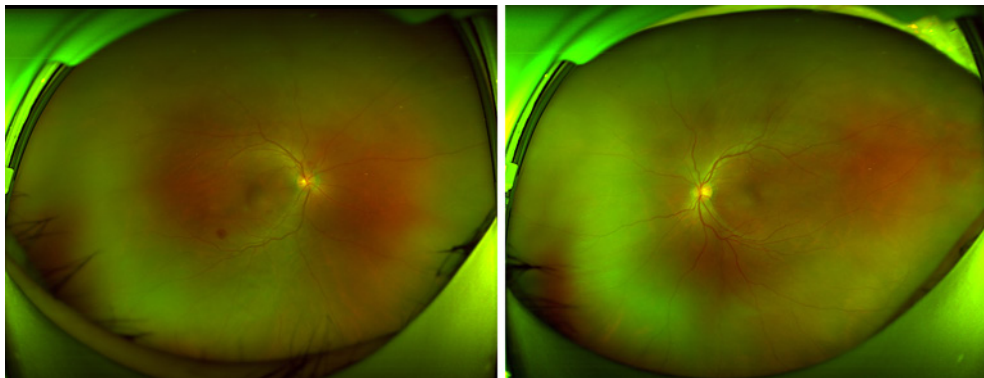
Upon ocular examination, the best corrected visual acuity (BCVA) was hand motion in both eyes. Intraocular pressure (IOP) was 62/68 mm Hg, as measured by a Goldmann Applanation Tonometer (GAT). On slit-lamp examination, the cornea revealed epithelial edema without interstitial keratitis, and the anterior chamber was slit-like and presented 2–3+ cells. Appositional closed-angle was observed during gonioscopy examination, with axial lengths of 21.94 mm and 22.13 mm in the left and right eye, respectively. On fundus examination, we observed multiple retinal hemorrhages in both eyes and choroidal effusion in the right eye (Fig. 1). We diagnosed the patient with atypical Cogan's syndrome and recommended the initiation of systemic corticosteroid therapy by the internal medicine department.

Because of the high IOP, the patient was started on maximal antiglaucoma therapy, except intravenous hyperosmotic agents owing to renal failure. Two days later, the IOP did not decrease; hence, a laser iridotomy was performed on both eyes. On fundus examination, performed 1 week after systemic corticosteroid therapy initiation, the choroidal effusion was resolved, and the retinal hemorrhages had nearly disappeared (Fig. 2); however, the IOP was 52/54 mm Hg, as measured by a GAT.

The patient underwent bilateral Ahmed glaucoma valve (Model FP7; NewWorld Medical Inc., Rancho Cucamonga, CA, USA) implant surgery, with the plate positioned superonasally. The surgery was uneventful, with a remarkable postoperative recovery in both eyes. On postoperative day one, the IOP was 14 mm Hg and 16 mm Hg in the right and left eye, respectively, when measured by a GAT, and the visual acuity was 20/200 and 20/160 in the right and left eye, respectively.



**Fig. 1.** Fundus photograph of the choroidal effusion in the right eye acquired at initial visit.



**Fig. 2.** Fundus photograph of the resolved choroidal effusion in the right eye following systemic corticosteroid therapy.

One month after the systemic treatment, the patient's BCVA was 20/40 and 20/32, and the IOP was 12 mm Hg and 14 mm Hg in the right and left eye, respectively, following the instillation of antiglaucoma eye drops (topical prostaglandin, timolol, and dorzolamide); moreover, the bilateral hearing loss and renal failure had more or less resolved. Six months after the surgery, the BCVA was 20/20 in both eyes and IOP was 12/12 mm Hg with topical antiglaucoma eye drops.

## Discussion and Conclusions

In the present case, the patient's IOP could not be controlled with topical and systemic medications; hence, bilateral valve implant surgery was performed. The choroidal effusion resolved 2 weeks after the initiation of systemic corticosteroid therapy. The diagnosis of Cogan's syndrome can be difficult due to the variability in presentation and its rarity [5]. Moreover, the clinical manifestations of atypical Cogan's syndrome vary due to vasculitis, and the ocular symptoms can involve the whole eye [5].

Choroidal effusion has recently been considered one of the major mechanisms related to primary angle-closure glaucoma [6]. Thus, in our patient, the immune response-related inflammation could have been one of the causes of Cogan's syndrome. Additionally, choroidal expansion can provoke angle-closure glaucoma, although microphthalmia with a shallow

anterior chamber and a short axial length remain the main causes. The ocular symptoms of Cogan's syndrome rarely lead to permanent visual loss [5]; however, in our patient, the IOP could not be controlled despite maximal antiglaucoma therapy and laser peripheral iridotomy; it was only controlled after the Ahmed glaucoma valve implant surgery.

Corticosteroids are the mainstay of treatment for Cogan's syndrome. Systemic and topical corticosteroids are effective for ocular inflammation [7]. Haynes et al. [1] reported that 95% of the untreated patients in their study developed permanent hearing loss, while 55% of the patients treated with systemic steroids improved within 2 weeks; furthermore, hearing loss in 8% of the patients improved after 2 weeks. Therefore, early systemic corticosteroid therapy within 2 weeks is the most effective treatment for Cogan's syndrome. Durtette et al. [8] reported that ocular manifestations of Cogan's syndrome tend to respond well to treatment, with 84% responding to steroids alone. In this case, autoimmune vasculitis with inflammation is one of the major causes of choroidal effusion and retinal hemorrhages. The choroidal effusion, retinal hemorrhage, and anterior chamber inflammation rapidly regressed 1 week after the initiation of systemic and topical corticosteroids; moreover, the systemic symptoms and hearing loss recovered with systemic treatment. Haynes et al. [9] described that hearing loss improved within 14 days (3 days in 1 case) after systemic corticosteroids treatment. In this case, the response of ocular manifestations and hearing loss was very rapid. In atypical Cogan's syndrome, the interval between the onset of ocular and audiovestibular symptoms is more than 2 years [6]; however, in this case, the ocular and audiovestibular symptom onset was observed at nearly the same time.

To the best of our knowledge, this is the first case of atypical Cogan's syndrome with choroidal effusion, which necessitated an Ahmed glaucoma valve implant surgery. Moreover, Cogan's syndrome can provoke angle-closure glaucoma with choroidal effusion in patients with a short axial length and a shallow anterior chamber.

## Statement of Ethics

This case report of patient data did not require ethical approval in accordance with local guidelines. All procedures followed were in accordance with ethical standards and the Helsinki Declaration. Written informed consent was obtained from the patient for publication of this case report and any accompanying images.

## Conflict of Interest Statement

The authors have no conflicts of interest to declare.

## Funding Sources

No funding was received by any of the authors.

## Author Contributions

Conceptualization and writing – original: Je Hyung Hwang.

Validation: Won Hyuk Oh.

Writing – review and editing: Won Hyuk Oh and Jee Hye Lee.

## Data Availability Statement

All data generated or analyzed during this study are included in this article. Further inquiries can be directed to the corresponding author.

## References

- 1 Haynes BF, Kaiser-Kupfer MI, Mason P, Fauci AS. Cogan syndrome: studies in thirteen patients, long-term follow-up, and a review of the literature. *Medicine*. 1980;59(6):426–41.
- 2 Vollertsen RS. Vasculitis and Cogan's syndrome. *Rheum Dis Clin North Am*. 1990;16(2):433–9.
- 3 Vollertsen RS, McDonald TJ, Younge BR, Banks PM, Stanson AW, Ilstrup DM. Cogan's syndrome: 18 cases and a review of the literature. *Mayo Clin Proc*. 1986;61(5):344–61.
- 4 Sevgi DD, Sobrin L, Papaliadis GN. Cogan syndrome with severe medium and large vessel vasculitis. *Digit J Ophthalmol*. 2016;22(1):32–4.
- 5 Espinoza GM, Prost A. Cogan's syndrome and other ocular vasculitides. *Curr Rheumatol Rep*. 2015;17(4):24.
- 6 Sakai H, Morine-Shinjo S, Shinzato M, Nakamura Y, Sakai M, Sawaguchi S. Uveal effusion in primary angle-closure glaucoma. *Ophthalmology*. 2005;112(3):413–9.
- 7 Grasland A, Pouchot J, Hachulla E, Blétry O, Papo T, Vinceneux P, et al. Typical and atypical Cogan's syndrome: 32 cases and review of the literature. *Rheumatology*. 2004;43(8):1007–15.
- 8 Durtette C, Hachulla E, Resche-Rigon M, Papo M, Zenone T, Loiger B, et al. Cogan syndrome: characteristics, outcome and treatment in a French nationwide retrospective study and literature review. *Autoimmun Rev*. 2017;16:1219–23.
- 9 Haynes BF, Pikus A, Kaiser-Kupfer M, Fauci AS. Successful treatment of sudden hearing loss in Cogan's syndrome with corticosteroids. *Arthritis Rheum*. 1981;24(3):501–3.