



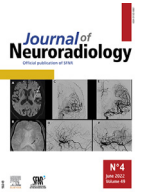Since January 2020 Elsevier has created a COVID-19 resource centre with free information in English and Mandarin on the novel coronavirus COVID-19. The COVID-19 resource centre is hosted on Elsevier Connect, the company's public news and information website.

Elsevier hereby grants permission to make all its COVID-19-related research that is available on the COVID-19 resource centre - including this research content - immediately available in PubMed Central and other publicly funded repositories, such as the WHO COVID database with rights for unrestricted research re-use and analyses in any form or by any means with acknowledgement of the original source. These permissions are granted for free by Elsevier for as long as the COVID-19 resource centre remains active.



Available online at
ScienceDirect
 www.sciencedirect.com

Elsevier Masson France
EM|consulte
 www.em-consulte.com



Original Article

Transient modifications of the olfactory bulb on MR follow-up of COVID-19 patients with related olfactory dysfunction

Amine Ammar^{a,1,*}, Lea Distinguin^{b,1}, Anaëlle Chetrit^a, Dominique Safa^a, Stephane Hans^b, Robert Carlier^a, Jerome R. Lechien^{b,c,d,2}, Myriam Edjlali^{a,e,2}

^a Department of Radiology, APHP, Hôpitaux Raymond-Poincaré & Ambroise Paré, DMU Smart Imaging, GH Université Paris-Saclay, U 1179 UVSQ/Paris-Saclay, Paris, France

^b Department of Otolaryngology-Head & Neck Surgery, Hôpital Foch, UVSQ/Paris-Saclay, Paris, France

^c Department of Otolaryngology-Head & Neck Surgery, CHU Saint-Pierre, Université Libre de Bruxelles, Brussels, Belgium

^d Department of Human Anatomy and Experimental Oncology, UMONS Research Institute for Health Sciences and Technology, University of Mons, Mons, Belgium

^e Laboratoire d'imagerie Biomédicale Multimodale (BioMaps), Université Paris-Saclay, CEA, CNRS, Inserm, Service Hospitalier Frédéric Joliot, Orsay, France

ARTICLE INFO

Article History:

Available online 17 March 2022

Keywords:

Anosmia
 COVID-19
 SARS-CoV-2
 Magnetic resonance imaging
 Olfaction disorders

ABSTRACT

Background: : Olfactory dysfunction (OD) has been reported with a high prevalence on mild to moderate COVID-19 patients. Previous reports suggest that volume and signal intensity of olfactory bulbs (OB) have been reported as abnormal on acute phase of COVID-19 anosmia, but a prospective MRI and clinical follow-up study of COVID-19 patients presenting with OD was missing, aiming at understanding the modification of OB during patients' follow-up.

Methods: : A prospective multicenter study was conducted including 11 COVID-19 patients with OD. Patients underwent MRI and psychophysical olfactory assessments at baseline and 6-month post-COVID-19. T2 FLAIR-Signal intensity ratio (SIR) was measured between the average signal of the OB and the average signal of white matter. OB volumes and obstruction of olfactory clefts (OC) were evaluated at both evaluation times.

Results: : The psychophysical evaluations demonstrated a 6-month recovery in 10/11 patients (90.9%). The mean values of OB-SIR significantly decreased from baseline (1.66 ± 0.24) to 6-month follow-up (1.35 ± 0.27), reporting a mean variation of $-17.82 \pm 15.20\%$ ($p < 0.001$). The mean values of OB volumes significantly decreased from baseline (49.22 ± 10.46 mm³) to 6-month follow-up (43.70 ± 9.88 mm³), ($p = 0.006$).

Conclusion: : Patients with demonstrated anosmia reported abnormalities in OB imaging that may be objectively evaluated with the measurement of SIR and OB volumes. SIR and OB volumes significantly normalized when patient recovered smell. This supports the underlying mechanism of a transient inflammation of the OB as a cause of Olfactory Dysfunction in COVID-19 patients.

© 2022 Elsevier Masson SAS. All rights reserved.

Introduction

Coronavirus disease-2019 (COVID-19), linked to the severe acute respiratory syndrome coronavirus 2 (SARS-CoV-2), has been associated with many clinical pictures, ranging from simple rhinitis to acute respiratory distress syndrome. Frequently, the infection has been linked to smell and taste dysfunctions, reported in 50 to 86% of mild-

to-moderate cases.¹ The olfactory dysfunction (OD) may develop through nasal obstruction, such as in common cold, or be related to neurological viral spread through the olfactory cleft mucosa. In the first paper reporting OD as a key symptom of the COVID-19,¹ more than 80% of patients presented with OD without associated rhinorrhea or nasal obstruction. Volume and signal intensity of OB have been reported as abnormal on acute phase of COVID-19 anosmia.² Although the symptoms remain most of the time regressive, MRI findings in patients with prolonged COVID-19-induced OD was significantly associated with lower olfactory bulbs (OB) heights,³ compared to controls. These findings support the perception that SARS-CoV-2 may invade the central nervous system through the olfactory pathway, inflicting immediate and potentially irreversible damage to neuronal structures like the OB. However, a prospective longitudinal study was missing to demonstrate the existence of OB modifications

Abbreviations: COVID-19, coronavirus disease 2019; OB, olfactory bulb; OC, olfactory cleft; OD, olfactory dysfunction; SARS-CoV-2, severe acute respiratory syndrome coronavirus 2; SIR, signal intensity ratio

* Corresponding author at: Department of Radiology of AP-HP - Garches Hospital, 104 Boulevard Raymond-Poincaré, 92380 Garches, France.

E-mail address: amine.ammar@aphp.fr (A. Ammar).

¹ Amine Ammar and Lea Distinguin contributed equally to this article.

² Jerome R. Lechien and Myriam Edjlali are senior authors who also contributed equally to this article.

<https://doi.org/10.1016/j.neurad.2022.03.003>

0150-9861/© 2022 Elsevier Masson SAS. All rights reserved.

in terms of volume and aspect in parallel with the clinical follow up of patients recovering or not from COVID-19 anosmia. We here report a prospective MRI and clinical follow-up study of COVID-19 patients presenting with OD, aiming at understanding the modification of OB during patients' follow-up.

Material and methods

Ethics, patient and setting

The study was approved by the IRB of Foch Hospital (ID-RCB: 2020-A00832-37). Written informed consent was obtained for participants.

From March to May 2020, COVID-19 patients with self-reported sudden OD were prospectively recruited from two University Hospitals (Foch Hospital and Garches Hospital, APHP, Paris, France). Patients had demonstrated mild to moderate COVID-19 through serology or reverse transcription polymerase chain reaction (RT-PCR) findings. Patients with a history of OD before the pandemic, nasal surgery, chronic rhinosinusitis, head and neck trauma, degenerative neurological disease, or contraindication to MRI were excluded from the study.

Olfactory assessments

Patients benefited from psychophysical olfactory assessments (Sniffin'Sticks tests, Medisense, Groningen, Netherlands). The Sniffin'Sticks test is a validated psychophysical olfactory test using 16 smell pens. Each pen was presented to the individual who had to choose the adequate smell between four given options. The final score ranges from 0 (no olfaction) to 16 (perfect olfaction). Hyposmia was defined by a score ranging from 9 to 11 and anosmia if <9 .⁴ The objective evaluations were made within the two or four weeks following the onset of the olfactory disease and throughout the follow-up.

The olfactory cleft specific Lund-Kennedy scoring (OC-LK) was performed to evaluate cleft obstruction, this endoscopic score being correlated with the olfactory function in patients with smell disorder.⁵

The impact of COVID-19 on sinonasal symptoms was evaluated through the French version of the sino-nasal outcome test-22 (SNOT-22),⁶ which is a validated patient-reported outcome questionnaire developed from the U.S. version.⁷

Imaging acquisition

Imaging studies were performed on a 3 Tesla device (Discovery TM MR750, General Electric, Milwaukee, WI, USA) with a 20-elements head and neck coil. The sequences performed in order to assess the OB signal were 3D-FLAIR-CUBE and 3D-T2-FIESTA acquired respectively in coronal and sagittal planes. The 3D-FLAIR sequence parameters were: TR/TE 8000/133ms; section thickness 2mm; matrix 240×240 ; FOV 230×230 mm; flip angle 90° and acquisition time = 4min-36sec. The 3D-T2 FIESTA sequence parameters were: TR/TE 5.9/2.5ms; section thickness 0.6mm; matrix 320×320 ; FOV 180×180 mm; flip angle 55° and acquisition time=4min-32sec. The same protocol was conducted at the initial stage of the infection and at 6-months follow-up.

Image analysis

Two experienced neuroradiologists, blinded to clinical data, independently reviewed the images. A third neuroradiologist resolved potential discordances. Volumes of OB were measured on 3D-T2 sequence using a post-processing application dedicated to segmentation⁸: ITK-SNAP[®] 3.8 (www.itksnap.org).

Olfactory Cleft (OC) obstruction was evaluated on T2/FLAIR images and was defined partial if it didn't affect the entire anteroposterior length.

Quantitative analysis was performed on T2/FLAIR image by adjusting contours of a ROI centered on the OB on a coronal plane, in order to measure the average OB signal intensity. A signal intensity ratio (SIR) was then calculated between the average signal of the OB and the average signal of a ROI placed in the frontal white matter of normal appearance at the same slice level.

Statistical analysis

Statistical analyses were performed using the Statistical Package for the Social Sciences (SPSS version 22.0; IBM Corp, Armonk, NY, USA). Intraclass correlation coefficient was used to assess the reproducibility of OC obstruction, SIR and volume measurements of OB across readers. For statistical analysis, a consensual proofreading was retained for measurements of SIR and OB volumes. The outcomes were compared from baseline to 6-month post-COVID-19 with Wilcoxon signed-rank test. A level of significance of $p < 0.05$ was used.

Results

Eleven anosmic patients were included. The mean age was 41.5 years (range 24-75 years). Patients' characteristics are summarized in Table 1.

Olfactory assessments

Whereas all patients were initially anosmic, only 1 patient remained hyposmic on the 6 months follow-up (9.09%). The latter had a partial recovery with Sniffin'Sticks test improving from 3 to 8.

At the initial examination, OC-LK was normal (score 0) in 8/11 patients (72.72%).

The mean SNOT-22 was 18.45 ± 19.65 (0-61) on the first exam, and was 10.36 ± 16.36 (range 0-47) on the follow-up examination. The hyposmic patient at the second examination had an improvement of the SNOT-22 score from 43 to 0.

Image analysis

Five patients (45.54%) had partial OC obstruction, bilateral in 3 patients on the initial MRI. These obstructions were regressive in all cases on the control MRI.

As for SIR and volume measurements of the OB, the intra-class correlation coefficient was good for SIR measurement ($r=0.898$, 95%CI [0.770–0.956], $p < 0.001$) and excellent for OB volumes measurement ($r=0.996$, 95%CI [0.991–0.998], $p < 0.001$).

Table 1
Patients characteristics.

Characteristics	Patients (N-%)
Age (mean \pm SD) – years old	41.5 \pm 19.5
Gender (female/male)	7/4
Rhinological history	
Patients with seasonal allergy	3/11 (27.3)
Septoplasty	2/11 (18.2)
Other antecedents	
Dysthyroidism	2/11 (18.2)
Hypertension	1/11 (9.1)
Cardiac stent	1/11 (9.1)
Autoimmune disease	1/11 (9.1)
Endometriosis	1/11 (9.1)

SD: standard deviation.

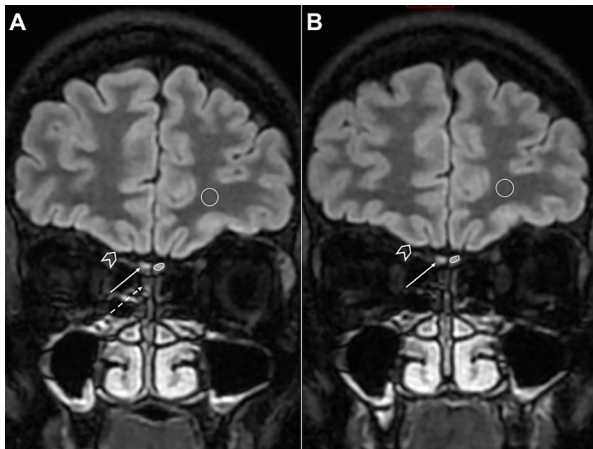


Fig. 1. Signal intensity ratio (SIR) measurement

Coronal Flair-weighted at the same level slices through the olfactory bulbs (OB) in a 32-year-old anosmic female at the initial exam (A) and at the follow-up exam (B), performed respectively at day 4 and 147 from onset of anosmia. The SIR between the average signal of the OB (manual ROI) and the average signal of a ROI placed in the frontal same level white-matter (circle) went from 1.63 to 1.05 on the right and from 1.68 to 0.96 on the left (fall of 35.26% and 42.45% respectively). There was a partial obstruction of right olfactory cleft (dotted arrow) which regressed on control. Note the isointense signal OB (arrows) compared to normal brain cortex (head of arrows).

The mean values of OB-SIR significantly normalized from baseline (1.66 ± 0.24) to 6-month follow-up (1.35 ± 0.27), reporting a mean variation of $-17.82 \pm 15.20\%$ ($p < 0.001$; **Figure 1**).

The mean values of OB volumes significantly decreased from baseline ($49.22 \pm 10.46 \text{ mm}^3$) to 6-month follow-up ($43.70 \pm 9.88 \text{ mm}^3$), with a mean variation of $-10.30 \pm 13.01\%$ ($p = 0.006$; **Figure 2**).

Concerning the patient with persistent hyposmia on the follow-up examination, MRI showed a severe drop in signal intensity ratio

(-23.96% and -27.72%) and of volumes (-27.03% and -28.38%) in the right and left OB respectively.

Note that one patient presented multiple sclerosis-like lesions at first MRI, the disease being not previously known.

Discussion

MR imaging in COVID-19 anosmic patients showed initial increase in signal intensity and volume of olfactory bulbs with a normalisation on 6 months-MRI-follow-up whilst 90% of our patients clinically recovered smell. This supports the underlying mechanism of a transient inflammation of the OB as a cause of OD in COVID-19 patients who recover. Initial signals and volumes would then be increased due to inflammation, followed by a normalization of these measures over time.

Laurendon *et al.*⁹ reported similar findings in a 27-year-old COVID-19 anosmic patient reporting edema and transient swelling of the OB. Initial inflammatory reaction in the OB suggest a neural spread of the SARS-CoV-2 into the OC mucosa. Many viruses, including previous forms of coronaviruses, are known to spread from the nasal epithelium to the olfactory bulb and brain but in smaller proportion of cases.^{10,11} Interestingly, the brain spread of the virus was associated with concomitant brain damage in two recent studies.^{12,13} Accordingly, COVID-19 RNA was identified in the brains of patients, supporting the neurological pattern of the virus.¹⁴ The virus spreads through the angiotensin converting enzyme 2 receptor (ACE2) and transmembrane serine protease 2 (TMPRSS2), which are both expressed in OC epithelium and in the sustentacular cells of the OB.^{10,15} The inflammatory reaction starts in the neuroepithelium, which may appear obstructed on the initial MRI. Eliezer *et al.*¹⁶ found that OD and OC obstruction are present at the early stage of the disease, and improved both at one-month follow-up, suggesting that OD in Covid-19 patients was caused, at least in part, by reversible

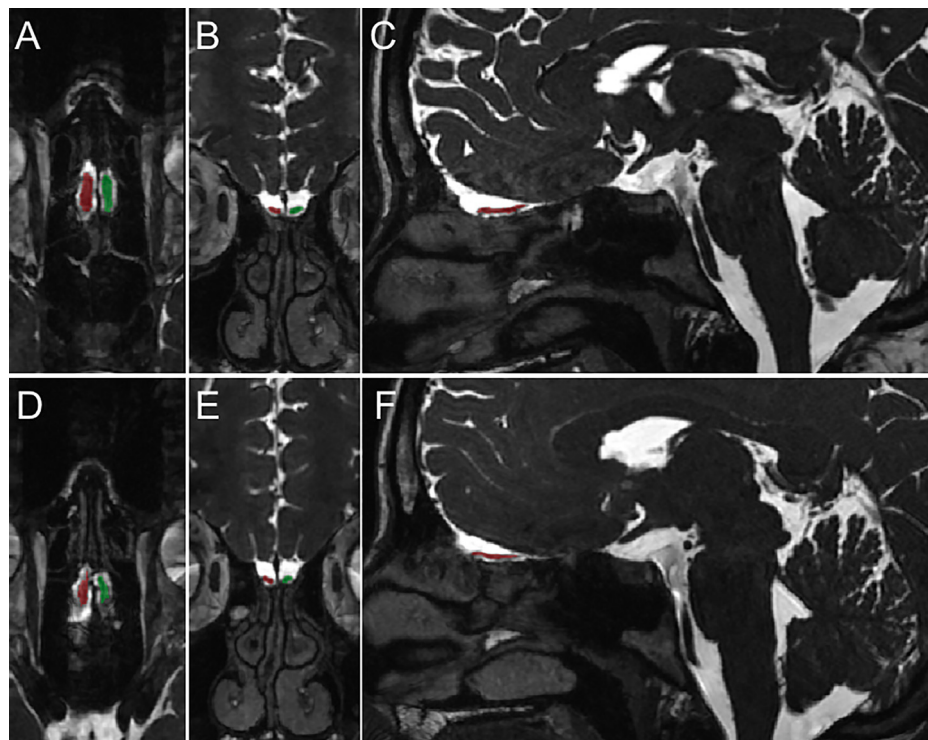


Fig. 2. Measurement of the olfactory bulbs (OB) volumes

Same level reformatted axial, frontal and sagittal 3D-T2-weighted slices through the olfactory bulbs (OB) in a 26-year-old anosmic female at the initial exam (A, B, C) and at the follow-up exam (D, E, F), performed respectively at 7 and 147 days from onset of anosmia. OB volumes varied from 54.91 to 41.80 mm^3 on the right and from 57.73 to 42.7 mm^3 on the left (decrease of 41.0% and 37.85% respectively).

inflammatory changes in the OC. In a recent systematic review,¹⁷ opacification of OC (60/218 - 27.5%) together with normal OB morphology and signal intensity (68/218 - 31.2%) were the most common imaging findings in patients with olfactory dysfunction secondary to COVID-19. In our study, we found only partial OC obstruction in only 4/11 patients on the initial MRI, totally regressive during follow-up, explaining only partly OD. By adding a quantitative analysis of OB signal intensity, our study supports the presence of an initial inflammation of OB as a cause of OD. OB involvement in COVID-19 OD was also mentioned by Aragão *et al.*¹⁸ who found a hypersignal and/or an enhancement of OB on T1-weighted images, explaining the OD by the presence of microbleeding and/or blood-brain barrier break. Kandemirli *et al.*¹⁹ also suggested the potential microhemorrhagic complications by finding a punctate hypointense T2-weighted pattern within the OB in 4/23 patients with persistent COVID-19 OD. Those abnormalities may represent a subsequent marker of severity of inflammatory lesion of the OB.

Interestingly, patients with prolonged OD may develop OB atrophy. Tsvigoulis *et al.*³ demonstrated that prolonged SARS-CoV2-induced OD is significantly associated with lower OB heights bilaterally compared to controls. Concerning our patient with persistent hyposmia on the follow-up examination, MRI showed a severe decrease in volumes, corroborating this hypothesis.

Certain limitations of the present study should be highlighted, including the small sample size of our population and the fact that a vast majority of our patients recovered from anosmia, which was not predictable at the initial time point.

Conclusion

COVID-19 anosmic patients reported initial increase in signal intensity and volume of olfactory bulbs, followed by a normalization at 6 months-MRI-follow-up whilst patient recovered smell. This supports the underlying mechanism of a transient inflammation of the OB as a cause of Olfactory Dysfunction in COVID-19 patients who then recover. In a context where the clinical examination of infected patient is still discouraged because of aerosolization risk, our study supports that the investigation of anosmia through MRI is feasible.

Funding

This research did not receive any specific grant from funding agencies in the public, commercial, or not-for-profit sectors.

Data availability statement

The data that support the findings of this study are available on request from the corresponding author. The data are not publicly available due to privacy or ethical restrictions.

Declarations of Competing Interest

None.

Acknowledgements

We thank Isabelle Ducamp for the management of the patient appointment, Pierre-Frédéric Bourcier for his technical support on the optimization of MR sequence parameters, Florence Toutain,

Clément Serpette and all the MRI technicians involved in MRI examinations, Florence Couppey and all the members of Foch DRCl for the project management.

References

- Lechien JR, Chiesa-Estomba CM, De Siati DR, Horoi M, Le Bon SD, Rodriguez A, et al. Olfactory and gustatory dysfunctions as a clinical presentation of mild-to-moderate forms of the coronavirus disease (COVID-19): a multicenter European study. *Eur Arch Otorhinolaryngol.* 2020;277:2251–2261. <https://doi.org/10.1007/s00405-020-05965-1>.
- Chetrit A, Lechien JR, Ammar A, Chekkoury-Idrissi Y, Distinguin L, Circiu M, et al. Magnetic resonance imaging of COVID-19 anosmic patients reveals abnormalities of the olfactory bulb: preliminary prospective study. *J Infect.* 2020;81:816–846. <https://doi.org/10.1016/j.jinf.2020.07.028>.
- Tsvigoulis G, Fragkou PC, Lachanis S, Palaiodimos L, Lambadiari V, Papathanasiou M, et al. Olfactory bulb and mucosa abnormalities in persistent COVID-19-induced anosmia: a magnetic resonance imaging study. *Eur J Neurol.* 2021;28:e6–e8. <https://doi.org/10.1111/ene.14537>.
- Hummel T, Kobal G, Gudziol H, Mackay-Sim A. Normative data for the “Sniffin’ Sticks” including tests of odor identification, odor discrimination, and olfactory thresholds: an upgrade based on a group of more than 3,000 subjects. *Eur Arch Otorhinolaryngol.* 2007;264:237–243. <https://doi.org/10.1007/s00405-006-0173-0>.
- Poletti SC, Murta G, Hähner A, Hummel T. Olfactory cleft evaluation: a predictor for olfactory function in smell-impaired patients? *Eur Arch Otorhinolaryngol.* 2018;275:1129–1137. <https://doi.org/10.1007/s00405-018-4913-8>.
- de Dorlodot C, Horoi M, Lefebvre P, Collet S, Bertrand B, Eloy P, et al. French adaptation and validation of the sino-nasal outcome test-22: a prospective cohort study on quality of life among 422 subjects. *Clin Otolaryngol.* 2015;40:29–35. <https://doi.org/10.1111/coa.12315>.
- Piccirillo JF, Merritt MGJ, Richards ML. Psychometric and clinimetric validity of the 20-Item Sino-Nasal Outcome Test (SNOT-20). *Otolaryngol Head Neck Surg.* 2002;126:41–47. <https://doi.org/10.1067/mhn.2002.121022>.
- Yushkevich PA, Piven J, Hazlett HC, Smith RG, Ho S, Gee JC, et al. User-guided 3D active contour segmentation of anatomical structures: significantly improved efficiency and reliability. *Neuroimage.* 2006;31:1116–1128. <https://doi.org/10.1016/j.neuroimage.2006.01.015>.
- Laurendon T, Radulesco T, Mugnier J, Gérault M, Chagnaud C, El Ahmadi A-A, et al. Bilateral transient olfactory bulb edema during COVID-19-related anosmia. *Neurology.* 2020;95:224. <https://doi.org/10.1212/WNL.0000000000009850>.
- Brann D, Tsukahara T, Weinreb C, Logan DW, Datta SR. Non-neural expression of SARS-CoV-2 entry genes in the olfactory epithelium suggests mechanisms underlying anosmia in COVID-19 patients. *BioRxiv* 2020:2020.03.25.009084. <https://doi.org/10.1101/2020.03.25.009084>.
- Katal S, Balakrishnan S, Gholamrezaezhad A. Neuroimaging and neurologic findings in COVID-19 and other coronavirus infections: A systematic review in 116 patients. *J Neuroradiol.* 2021;48:43–50. <https://doi.org/10.1016/j.neurad.2020.06.007>.
- Politi LS, Salsano E, Grimaldi M. Magnetic resonance imaging alteration of the brain in a patient with coronavirus disease 2019 (COVID-19) and Anosmia. *JAMA Neurol.* 2020. <https://doi.org/10.1001/jamaneurol.2020.2125>.
- Girardeau Y, Gallois Y, De Bonnecaze G, Escudé B, Lafont C, Chattelier G, et al. Confirmed central olfactory system lesions on brain MRI in COVID-19 patients with anosmia: a case-series. *MedRxiv* 2020:2020.07.08.20148692. <https://doi.org/10.1101/2020.07.08.20148692>.
- Li Y-C, Bai W-Z, Hashikawa T. The neuroinvasive potential of SARS-CoV2 may play a role in the respiratory failure of COVID-19 patients. *J Med Virol.* 2020;92:552–555. <https://doi.org/10.1002/jmv.25728>.
- Meinhardt J, Radke J, Dittmayer C, Franz J, Thomas C, Mothes R, et al. Olfactory transmucosal SARS-CoV-2 invasion as a port of central nervous system entry in individuals with COVID-19. *Nat Neurosci.* 2020. <https://doi.org/10.1038/s41593-020-00758-5>.
- Eliezer M, Hamel A-L, Houdart E, Herman P, Housset J, Jourdain C, et al. Loss of smell in COVID-19 patients: MRI data reveals a transient edema of the olfactory clefts. *Neurology.* 2020. <https://doi.org/10.1212/WNL.0000000000010806>.
- Keshavarz P, Haseli S, Yazdanpanah F, Bagheri F, Raygani N, Karimi-Galoughi M. A systematic review of imaging studies in olfactory dysfunction secondary to COVID-19. *Acad Radiol.* 2021;28:1530–1540. <https://doi.org/10.1016/j.acra.2021.08.010>.
- Aragão MFVV, Leal MC, Cartaxo Filho OQ, Fonseca TM, Valença MM. Anosmia in COVID-19 associated with injury to the olfactory bulbs evident on MRI. *Am J Neuro-radiol.* 2020. <https://doi.org/10.3174/ajnr.A6675>.
- Kandemirli SG, Altundag A, Yildirim D, Tekcan Sanli DE, Saatci O. Olfactory Bulb MRI and Paranasal Sinus CT Findings in Persistent COVID-19 Anosmia. *Acad Radiol.* 2021;28:28–35. <https://doi.org/10.1016/j.acra.2020.10.006>.