



Efficacy of different durations of antifungal prophylaxis with nebulized amphotericin B after lung transplantation: a retrospective cohort study

Chunrong Ju¹, Qiaoyan Lian¹, Xiaohua Wang¹, Lulin Wang¹, Jianheng Zhang¹, Yuhang Cai¹, Xin Xu¹, Rongchang Chen², Jianxing He¹

¹State Key Laboratory of Respiratory Disease, National Clinical Research Center for Respiratory Disease, Guangzhou Institute of Respiratory Health, The First Affiliated Hospital of Guangzhou Medical University, Guangzhou, China; ²Shenzhen Institute of Respiratory Diseases, Shenzhen People's Hospital (First Affiliated Hospital of South University of Science and Technology and Second Affiliated Hospital of Jinan University), Shenzhen, China

Contributions: (I) Conception and design: J He, R Chen, C Ju; (II) Administrative support: J He, R Chen; (III) Provision of study materials or patients: L Wang, Y Cai; (IV) Collection and assembly of data: C Ju, Q Lian, J Zhang, X Xu; (V) Data analysis and interpretation: C Ju, Q Lian, X Wang; (VI) Manuscript writing: All authors; (VII) Final approval of manuscript: All authors.

Correspondence to: Jianxing He, MD. State Key Laboratory of Respiratory Disease, National Clinical Research Center for Respiratory Disease, Guangzhou Institute of Respiratory Health, The First Affiliated Hospital of Guangzhou Medical University, Yanjiang Road, Guangzhou 510120, China. Email: drjianxing.he@gmail.com; Rongchang Chen, MD, PhD. Shenzhen Institute of Respiratory Diseases, Shenzhen People's Hospital (First Affiliated Hospital of South University of Science and Technology and Second Affiliated Hospital of Jinan University), East of Shennan Road, Luohu District, Shenzhen 518020, China. Email: chenrc@vip.163.com.

Background: Nebulized amphotericin B (NAB) is recommended for preventing invasive fungal diseases (IFDs) after lung transplantation. However, the optimal duration of NAB treatment is still unknown. This study aimed to compare the effectiveness of three different durations of antifungal prophylaxis with NAB after lung transplantation: a prolonged course beyond post-transplant 3 months, a medium course of 2 weeks to 3 months, and a short course of less than 2 weeks.

Methods: This a single-center retrospective cohort study analyzed 333 patients who underwent lung or heart-lung transplantation between January 2015 and November 2021.

Results: A prolonged course of NAB treatment was associated with a significantly lower incidence of IFDs (12.6%) at 1 year post-transplant compared with a short (50.9%) or a medium course (28.0%) ($P < 0.001$). There was no significant difference in the rates of adverse effects among the three durations of NAB treatment ($P > 0.05$). A prolonged course of NAB treatment was associated with a significantly higher 1-year survival rate (94.7%) compared with a short (36.8%) or a medium course (72.0%) ($P < 0.001$).

Conclusions: A prolonged course of NAB treatment provided better protection against IFDs than a short or medium course after lung transplantation. Prolonged use of NAB did not significantly increase the incidence of adverse effects.

Keywords: Aspergillosis; invasive fungal infections; lung transplantation; nebulized amphotericin B (NAB); prophylaxis

Submitted Apr 10, 2023. Accepted for publication Aug 14, 2023. Published online Sep 26, 2023.

doi: 10.21037/jtd-23-601

View this article at: <https://dx.doi.org/10.21037/jtd-23-601>

Introduction

Lung transplantation is often the final treatment method for a variety of end-stage lung diseases. However, post-lung transplant survival is still low compared with other solid organ transplantations, mainly due to pulmonary and airway fungal infections (1,2). *Aspergillus* is the most frequent pathogen causing invasive fungal diseases (IFDs) in Chinese lung transplant recipients (3). Universal antifungal prophylaxis is recommended by many lung transplantation guidelines and adopted by most transplant centers.

Compared with other antifungal agents, nebulized amphotericin B (NAB) exhibits a wide range of fungicidal activity, less systemic absorption, a longer half-life, a site-targeted effect, and fewer drug interactions (4,5). Antifungal prophylaxis with either conventional or liposomal amphotericin B is safe and effective (6,7). However, the latter agent has not yet received approval for use in China. Moreover, there is currently no agreement on the most effective duration of antifungal prophylaxis with NAB in individuals who have undergone lung transplantation. The antifungal prophylaxis protocol at our center includes voriconazole plus NAB twice daily for the first 2 to 4 weeks after lung transplantation. The American Society of Transplantation Infectious Disease Community of Practice recommended 2016 a regimen of NAB for 3–4 months (8). It has also been suggested that universal antifungal prophylaxis with inhaled amphotericin B and systemic voriconazole for a minimum of 3–6 months following lung transplantation may be beneficial (9). A Chinese national survey found that invasive pulmonary aspergillosis (IPA) mostly occurs in the first 4–6 months post-transplant (3). This finding suggests that a prolonged duration of antifungal prophylaxis with

NAB deoxycholate beyond post-transplant 3 months may provide better protection against IFDs, especially IPA.

The present study aimed to retrospectively compare the efficacy and safety among three different durations of NAB treatment in preventing IFDs after lung or heart-lung transplantation at a single center in China. We present this article in accordance with the STROBE reporting checklist (available at <https://jtd.amegroups.com/article/view/10.21037/jtd-23-601/rc>).

Methods

Patients

This retrospective cohort study included patients who received lung or lung-heart transplantation between January 2015 and November 2021 at the First Affiliated Hospital of Guangzhou Medical University. The inclusion criteria were: (I) aged 18 years or older; (II) single-lung, double-lung, or heart-lung transplantation; (III) post-transplant antifungal prophylaxis with NAB deoxycholate. The exclusion criteria were: (I) missing medical data; (II) recipients who failed to attend their scheduled follow-up appointments; (III) death caused by other reasons than IFDs within post-transplant 2 weeks. The study was conducted in accordance with the Declaration of Helsinki (as revised in 2013). Ethics approval was obtained from the Institutional Ethics Review Board of the First Affiliated Hospital of Guangzhou Medical University (No. K-2021.11). Due to the retrospective nature of the study, the requirement for informed consent was waived.

Immunosuppressive regimen

The immunosuppressive regimen comprised an immune induction therapy and a maintenance therapy. The immune induction therapy included polyclonal and monoclonal antibodies. A polyclonal antibody, rabbit-anti-human T lymphocyte immunoglobulin (25 mg/dose), was used on the day of transplantation and during the early post-transplant period. A monoclonal antibody, interleukin 2-receptor antagonists, was used on the day of transplantation and post-transplant day 4, with 20 mg each time. Patients also received 10 mg/kg of methylprednisolone intravenously per anastomosis at the time of reperfusion as part of the induction therapy.

A standard triple-immunosuppressant regimen was used for immune maintenance. The methylprednisolone dose

Highlight box

Key findings

- Use of nebulized amphotericin B for more than 3 months after lung transplantation provides better protection against invasive fungal diseases compared to treatment courses of shorter duration.

What is known and what is new?

- Universal antifungal prophylaxis with amphotericin B can prevent pulmonary and airway fungal infections after lung transplantation.
- This study suggests antifungal prophylaxis with amphotericin B for a longer duration is superior to a shorter duration.

What is the implication, and what should change now?

- Further investigation with a prospective design and a large sample size is required to confirm the findings of this study.

was tapered down daily to 0.25 mg/kg of prednisolone over 1 week and then maintained for 12 months after transplantation until graft rejection occurred. On the first post-transplant day, a tacrolimus-based therapy was initiated in combination with mycophenolate mofetil, 500 mg, twice daily. The doses of calcineurin inhibitors were adjusted according to the plasma drug concentrations, and mycophenolic acid to the area under the curve. The target plasma concentrations of calcineurin inhibitors were maintained between 13–19 ng/mL during the perioperative period and mycophenolic acid between 30 to 60 mg/mL.

Antifungal prophylaxis

All recipients received 5 mg of NAB at a flow rate of 7 L/min every 12 hours after transplantation using a Respigard medication nebulizer system (Marquest Medical Products, Englewood, CO, USA). The duration of NAB treatment was defined as a short course of less than 2 weeks, a medium course of 2 weeks to 3 months, and a prolonged course of over 3 months. The duration of NAB treatment was decided at the discretion of the clinicians with considerations of patient financial ability, compliance, types of transplantation, and anastomotic necrosis.

Caspofungin was administered universally during the initial 7 days following transplantation, followed by posaconazole oral suspension or voriconazole oral tablets, which were chosen at the discretion of the clinicians according to the specific condition of each patient. Triazoles were used for 3–4 months after transplantation in the recipients, with target plasma trough levels of 0.75–3.5 µg/mL. For the prevention of pneumocystis jirovecii pneumonia, oral sulfamethoxazole was used for 6 months after transplantation, unless the recipients had bone marrow suppression, impaired renal function, gastrointestinal intolerance, drug allergy, or severe adverse effects.

Data collection

The clinical data were retrieved from electronic medical records for both donors and recipients. Donor data such as age, sex, blood type, cigarette smoking, and history of positive cultures were collected. For recipients, data included demographics, primary indications for lung transplantation, human leukocyte antigen (HLA)-matched information with donors, operative and postoperative data, history of positive cultures, and immunosuppressive regimens. Pre-transplant clinical data were also collected,

such as aspergillus airway colonization and history of IFD. In addition, fungus-related laboratory data, which involved thoracic imaging, bronchoscopy test, fungal separation and culture in deep sputum or bronchoalveolar lavage fluid (BALF), level of serum (1,3)-β-D-glucan, galactomannan test results, and histopathology examination were collected.

Diagnosis of IFD

IFD was diagnosed and categorized into proven, probable, possible, and undefined cases, based on the revised definitions released by the European Organization for Research and Treatment of Cancer/Mycoses Study Group (10), the 2016 guidelines of the American Society for Infectious Diseases (8), the 2019 Chinese Clinical Specifications for Invasive Fungal Diseases of Organ Transplant Recipients (11), and the 2010 ISHLT consensus (12). Proven and probable cases were regarded as IFDs in the present study.

Airway IFDs with unremarkable thoracic radiographs were defined as the isolation of fungi in respiratory cultures with pathological findings of tissue invasion/necrosis or ulceration/pseudomembranes by bronchoscopy. Routine pathological biopsy was performed through bronchoscopy in case of any anastomotic lesions, such as decay, necrosis, ulcers, stenosis, cracking, and fistulas (13). From post-transplant day 2, the airway anastomosis was checked by bronchoscopy every 2–3 days, of which the frequency was adjusted according to anastomotic healing.

Clinical outcomes

The primary endpoint was the post-transplant 1-year incidences of lung IFDs and airway fungal colonization. Fungal colonization was identified as positive cultures, not during antifungal prophylaxis, without documentation of IFDs. IFD was defined based on the documentation of signs, symptoms, and positive respiratory cultures of fungi.

The secondary endpoints included amphotericin B safety and the incidences of IFD breakthroughs. Safety was evaluated by adverse symptoms such as cough, chest tightness, bronchospasm, dizziness, dyspnea, nausea, and vomiting. A breakthrough infection was defined as an IFD that occurred during NAB treatment.

Statistical analysis

Statistical analysis was performed by using SPSS 19.0 (IBM Corp., Armonk, NY, USA). Graphs were created with

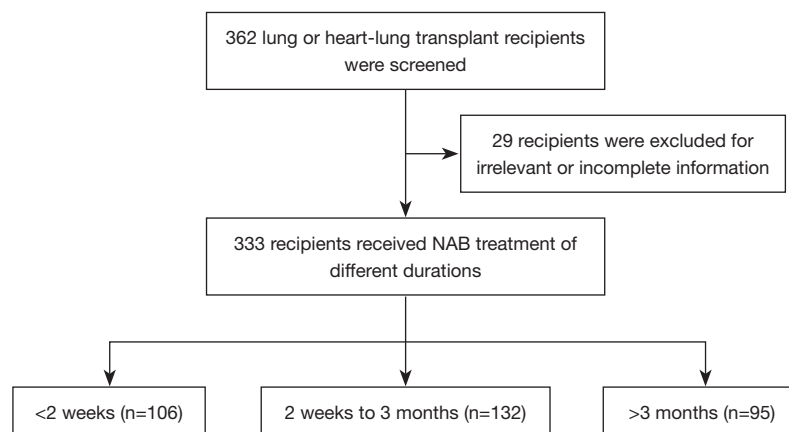


Figure 1 A flowchart of patient inclusion and exclusion. NAB, nebulized amphotericin B.

GraphPad Prism Version 5.04 for Windows. Continuous variables were described using mean values and standard deviations, while categorical variables were described using frequency and percentages. Between-group differences were analyzed by using the Chi-square test or Fisher's exact test for categorical variables, and the Student's *t*-test for continuous variables. Risk factors of survival that were statistically significant in the univariate analysis or clinically significant were included in the Cox regression analysis. Survival curves were drawn and compared using the Kaplan-Meier method. A *P* value less than 0.05 was considered statistically significant.

Results

Characteristics of the recipients

A total of 362 lung or heart-lung transplant recipients were screened for inclusion, and 29 of them were excluded for irrelevant or incomplete information. The final analysis included 333 recipients, which were classified into three groups by the durations of NAB treatment: short-course NAB (<2 weeks, *n*=106), medium-course NAB (2 weeks to 3 months, *n*=132; median 84 days, interquartile range 63–90 days), and prolonged-course NAB (>3 months, *n*=95) (Figure 1). The general characteristics of the recipients are shown in Table 1.

IFDs

A total of 103 recipients (30.9%) developed IFDs in the first year after transplantation (Table 2). During the first month

post-transplant, 51 patients were tested positive for *Candida*. The *Aspergillus* spp. growth was as follows: 5 *Aspergillus niger* (*A. niger*), 4 *Aspergillus flavus* (*A. flavus*), 1 *Aspergillus terreus* (*A. terreus*), and 1 *Aspergillus fumigatus* (*A. fumigatus*). A significantly higher rate of *Candida* growth was noticed in the short-course NAB group (*n*=30, 28.3%), including 3 cases of proven blood infection, 11 cases of airway candida infection, and 16 cases of airway colonization.

In the prolonged-course NAB group, no breakthrough IFDs occurred throughout the NAB treatment. In the medium-course NAB group, 12 (9.1%) patients had breakthrough IFDs, including 3 cases of mucormycosis and 9 cases of IPA. In the short-course NAB group, 3 (2.8%) patients had breakthrough IPA, which may be infections derived from the donors.

Adverse effects

NAB was well tolerated in most patients. Cough (15.3%), taste abnormality (8.4%), nausea (6.6%) and shortness of breath (6.6%) were the most prevalent adverse effects. The incidences of adverse effects were not significantly higher in the prolonged-course NAB group than the other two groups (Table 3). There was also no significant difference in the discontinuation rate of NAB among the three groups (*P*=0.45).

Survival and risk factors

The average follow-up time was 19.8±17.2 months. The post-transplant 1-year survival rate was significantly higher in the prolonged-course NAB group (94.7%) compared to the medium-course group (72.0%) and the short-course

Table 1 Pre-operative and peri-operative characteristics of the lung or heart-lung transplant recipients

Characteristics	s-NAB (n=106)	m-NAB (n=132)	p-NAB (n=95)	P value
Age (years), mean \pm SD	54.6 \pm 13.3	55.1 \pm 15.3	56.3 \pm 12.8	0.85
Male, n (%)	88 (83.0)	110 (83.3)	73 (76.8)	0.40
Transplantation type, n (%)				
Single-lung transplantation	48 (45.3)	80 (60.6)	62 (65.3)	0.01
Double-lung transplantation	50 (47.2)	47 (35.6)	30 (31.6)	0.056
Heart-lung transplantation	8 (7.5)	5 (3.8)	3 (3.2)	0.27
Primary indications for lung transplantation, n (%)				
Chronic obstructive pulmonary disease	30 (28.3)	36 (27.3)	29 (30.5)	0.87
Idiopathic interstitial pneumonia	47 (44.3)	56 (42.4)	39 (41.1)	0.51
CTD-ILD	12 (11.3)	8 (6.1)	6 (6.3)	0.27
Bronchiectasis	3 (2.8)	9 (6.8)	6 (6.3)	0.36
Other interstitial lung diseases	2 (1.9)	5 (3.8)	6 (6.3)	0.26
Pulmonary hypertension	6 (5.7)	5 (3.8)	5 (5.3)	0.77
Other	6 (5.7)	13 (9.8)	4 (4.2)	0.21
Respiratory colonization 6 months pre-transplant, n (%)	18 (17.0)	14 (10.6)	1 (1.1)	0.0008
Pre-operative severity, n (%)				0.34
NCOI	2 (1.9)	8 (6.1)	4 (4.2)	
NIMV	80 (75.5)	98 (74.2)	79 (83.2)	
IMV	16 (15.1)	18 (13.6)	10 (10.5)	
ECMO	8 (7.5)	8 (6.1)	2 (2.1)	
Diabetes, n (%)	31 (29.2)	30 (22.7)	11 (11.6)	0.0092

s-NAB, short-course nebulized amphotericin B (<2 weeks); m-NAB, medium-course nebulized amphotericin B (2 weeks to 3 months); p-NAB, prolonged-course nebulized amphotericin B (>3 months); SD, standard deviation; CTD-ILD, connective tissue disease-related interstitial lung disease; NCOI, nasal catheter oxygen inhalation; NIMV, non-invasive mechanical ventilation; IMV, invasive mechanical ventilation; ECMO, extracorporeal membrane oxygenation.

Table 2 Post-transplant 1-year incidences of lung IFDs and airway fungal colonization

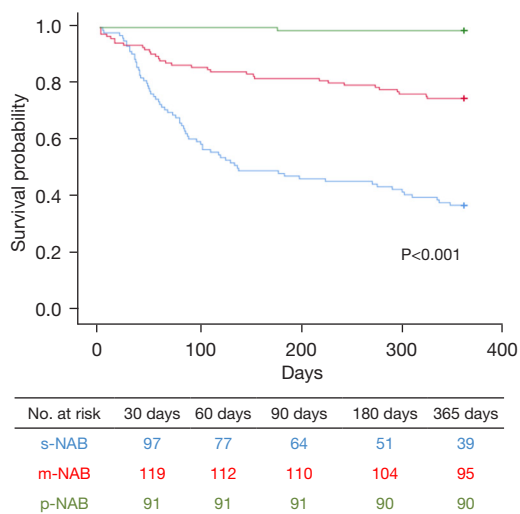
IFDs	s-NAB (n=106)	m-NAB (n=132)	p-NAB (n=95)	P value
Overall IFDs, n (%)	54 (50.9)	37 (28.0)	12 (12.6)	<0.001
Candidiasis	22 (20.8)	6 (4.5)	0 (0.0)	<0.001
<i>Aspergillus</i>	22 (20.8)	26 (19.7)	4 (4.2)	0.001
Cryptococcosis	1 (0.9)	1 (0.8)	0 (0.0)	0.635
Pneumocystis jirovecii pneumonia	5 (4.7)	4 (3.0)	5 (5.3)	0.362
Mucormycosis	4 (3.8)	0 (0.0)	3 (3.2)	0.038
Airway fungal colonization, n (%)	26 (24.5)	18 (13.6)	3 (3.2)	<0.001

IFDs, invasive fungal diseases; s-NAB, short-course nebulized amphotericin B (<2 weeks); m-NAB, medium-course nebulized amphotericin B (2 weeks to 3 months); p-NAB, prolonged-course nebulized amphotericin B (>3 months).

Table 3 Adverse effects and discontinuation rate of nebulized amphotericin B

Variables	s-NAB (n=106)	m-NAB (n=132)	p-NAB (n=95)	P value
Adverse effects, n				
Respiratory symptoms				
Cough	18	19	14	0.85
Wheezing	4	3	3	0.79
Chest tightness	7	7	5	0.89
Shortness of breath	9	7	6	0.61
Bronchospasm	5	4	3	0.56
Digestive symptoms				
Taste abnormality	11	9	8	0.62
Nausea	7	8	7	0.93
Vomiting	5	4	3	0.77
Palpitation	2	1	0	0.27
Discontinuation rate, n	12	11	6	0.45

s-NAB, short-course nebulized amphotericin B (<2 weeks); m-NAB, medium-course nebulized amphotericin B (2 weeks to 3 months); p-NAB, prolonged-course nebulized amphotericin B (>3 months).

**Figure 2** Survival curves of the lung or heart-lung transplant recipients. s-NAB, short-course nebulized amphotericin B (<2 weeks); m-NAB, medium-course nebulized amphotericin B (2 weeks to 3 months); p-NAB, prolonged-course nebulized amphotericin B (>3 months).

group (36.8%) ($P<0.001$; *Figure 2*).

Discussion

This is the first study that compared the antifungal prophylaxis effect of different durations of NAB treatment in lung transplant recipients. A very recent study investigated the safety and effectiveness of different dose regimens of NAB (twice daily compared with 3 times daily) for antifungal prophylaxis after lung transplantation (14). However, no previous study had compared the safety and effectiveness of different durations of NAB treatment after lung transplantation. Moreover, no previous studies had compared the effectiveness of NAB monotherapy alone with its combination with systemic antifungal agents. The combination therapy may enhance the efficacy of NAB and reduce the risk of fungal infection and adverse effects. Our study for the first time compared the effectiveness between NAB alone and NAB in combination with systemic antifungal agents after lung transplantation. We found that NAB, whether administered alone or in conjunction with systemic triazoles, is effective in preventing IFDs after lung transplantation without severe adverse effects. Our findings are consistent with previous studies (5,6,15), confirming the benefits of NAB for lung transplant recipients.

Our study used the conventional deoxycholate amphotericin B as an antifungal medication, which is the only formulation of amphotericin available in China. NAB dosing, formulation, and treatment duration varied in previous studies and guidelines (16-18). The dosing and duration of NAB may also vary depending on whether the liposomal or conventional formulation is used (6). Thus, there is still no consensus on the safest and most effective regimen and the optimal duration of NAB treatment. Nebulized liposomal amphotericin B has not been approved in China.

Our patients received deoxycholate amphotericin B formulations twice daily with different durations for antifungal prophylaxis. The study results showed that the prolonged course of NAB treatment was associated with a much lower rate of IPA and *Aspergillus* spp. colonization compared to the short- and medium-courses. In the early stage after transplant, *Candida* was the most prevalent fungi cultured, which often causes airway colonization. However, in the recipients who had received medium-course NAB,

more patients with *Aspergillus* infection or colonization were observed after the withdrawal of the systemic antifungal drugs. *Aspergillus* colonization is recognized as a risk factor for invasive aspergillosis in lung transplantation (19,20), which may be acquired from the donors. Other reasons for *Aspergillus* colonization may be related to the recipients themselves, including prolonged use of corticosteroids for underlying lung diseases or allograft rejection (15). The significantly lower incidence of IFDs associated with the prolonged course of NAB treatment suggests that longer antifungal prophylaxis with NAB may be more effective than shorter courses after lung transplantation.

Most of our patients received the medium course of NAB treatment, which means that the IFDs prophylaxis, either NAB or systemic antifungal drugs, was discontinued 3 months after transplantation. Previous studies suggested that most *Aspergillus* infections occur between 3.2 and 8.8 months after transplantation (17,21). Consistently, our previous study showed that most new-onset IPA occurred 4–6 months post-transplant (3). The present study showed the median time to *Aspergillus* spp. infection was 2.9 months post-transplant in the short-course NAB group, 4.5 months in the medium-course group, and 10 months in the prolonged-course group. The main reason for the higher rate of new-onset IPA in those patients might be attributed to the enhanced immunosuppressive agents, post-transplant time, and withdrawal of the anti-fungal medications. For lung transplantation, most recipients require a triple immunosuppressant regimen that include high doses of corticosteroids and calcineurin inhibitors, which may increase the risk of IPA. Another reason could be the discontinuation of antifungal medications, including systemic antifungal drugs and NAB.

In the present study, prolonged courses of NAB treatment were used for preventing *Aspergillus* infection, and, expectedly, no new-onset IFD was found in the prolonged-course NAB group, indicating the effectiveness of antifungal prophylaxis of NAB monotherapy. Our results suggested that lung transplant recipients should receive NAB for 4–6 months after lung transplantation, especially those who are at increased risk of IPA, such as single-lung transplant recipients and recipients with a history of pre-transplant IPA (3). In addition, prolonged courses of NAB treatment can decrease airway fungal infection and colonization in recipients with airway anastomosis.

Most of the NAB-related adverse effects were tolerable in our patients, including cough, chest tightness, palpitation, nausea, vomiting, taste abnormality, and

bronchospasm. Among them, bronchospasm was the most severe one. However, its incidence was low (3.6%) and it was improved by nebulized Ventolin or/and tiotropium before the use of NAB. Inconsistently, a previous study reported that bronchospasm was the main reason for NAB discontinuation (22). Therefore, our study suggested that systemic antifungal agents in combination with NAB should be given to lung transplant recipients for the synergic effect. This combination can reduce the high risk of IFDs and colonization at the early post-transplant stage, which is associated with intensified immunosuppressive therapy in this period. However, prolonged duration of NAB treatment is recommended beyond 3 months after lung transplantation.

Some limitations in this study should be noted. Firstly, the short-course NAB group had more double-lung and heart-lung transplantations and therefore might be sicker than the other two groups. This may lead to increased mortality and IFDs incidences in this group. Secondly, due to the retrospective design of our study, IFDs may not be clearly distinguished from fungal colonization. Thirdly, additional systemic antifungal agents were used in the short- and medium-course NAB groups, which may bias the results. Finally, the duration of NAB treatment was affected by patient compliance and financial ability.

Conclusions

A prolonged course of NAB treatment beyond post-transplant 3 months showed greater effectiveness in preventing IFDs, especially IPA, compared to short or medium courses of NAB in lung transplant recipients. The incidences of adverse effects were comparable between the three durations of NAB treatment. Continued use of NAB after the withdrawal of systemic antifungal agents may provide additional protection against IFDs.

Acknowledgments

We thank the Biobank for Respiratory Diseases in the National Clinical Research Center for Respiratory Disease (BRD-NCRCRD, Guangzhou, China).

Funding: This study was supported by grants from the State Key Laboratory of Respiratory Disease (No. SKLRHQ20205), the Zhongnanshan Medical Foundation of Guangdong Province (No. ZNSA-2020013), and the Guangzhou Institute of Respiratory Health (No. 2019GIRHZ04).

Footnote

Reporting Checklist: The authors have completed the STROBE reporting checklist. Available at <https://jtd.amegroups.com/article/view/10.21037/jtd-23-601/rc>

Data Sharing Statement: Available at <https://jtd.amegroups.com/article/view/10.21037/jtd-23-601/dss>

Peer Review File: Available at <https://jtd.amegroups.com/article/view/10.21037/jtd-23-601/prf>

Conflicts of Interest: All authors have completed the ICMJE uniform disclosure form (available at <https://jtd.amegroups.com/article/view/10.21037/jtd-23-601/coif>). JH serves as an unpaid Executive Editor-in-Chief of the *Journal of Thoracic Disease*. The other authors have no conflicts of interest to declare.

Ethical Statement: The authors are accountable for all aspects of the work in ensuring that questions related to the accuracy or integrity of any part of the work are appropriately investigated and resolved. The study was conducted in accordance with the Declaration of Helsinki (as revised in 2013). The study was approved by the Ethics Review Board of The First Affiliated Hospital of Guangzhou Medical University (No. K-2021.11) and individual consent for this retrospective analysis was waived.

Open Access Statement: This is an Open Access article distributed in accordance with the Creative Commons Attribution-NonCommercial-NoDerivs 4.0 International License (CC BY-NC-ND 4.0), which permits the non-commercial replication and distribution of the article with the strict proviso that no changes or edits are made and the original work is properly cited (including links to both the formal publication through the relevant DOI and the license). See: <https://creativecommons.org/licenses/by-nc-nd/4.0/>.

References

- Arthurs SK, Eid AJ, Deziel PJ, et al. The impact of invasive fungal diseases on survival after lung transplantation. *Clin Transplant* 2010;24:341-8.
- Nosotti M, Tarsia P, Morlacchi LC. Infections after lung transplantation. *J Thorac Dis* 2018;10:3849-68.
- Ju C, Lian Q, Xu X, et al. Epidemiology and Prognosis of Invasive Fungal Disease in Chinese Lung Transplant Recipients. *Front Med (Lausanne)* 2021;8:718747.
- Peghin M, Monforte V, Martin-Gomez MT, et al. 10 years of prophylaxis with nebulized liposomal amphotericin B and the changing epidemiology of *Aspergillus* spp. infection in lung transplantation. *Transpl Int* 2016;29:51-62.
- DiMondi VP, Drew RH. Aerosolized Antifungals for the Prevention and Treatment of Invasive Fungal Infections. *Current Fungal Infection Reports* 2013;7:110-8.
- Borro JM, Solé A, de la Torre M, et al. Efficiency and safety of inhaled amphotericin B lipid complex (Abelcet) in the prophylaxis of invasive fungal infections following lung transplantation. *Transplant Proc* 2008;40:3090-3.
- Rijnders BJ, Cornelissen JJ, Slobbe L, et al. Aerosolized liposomal amphotericin B for the prevention of invasive pulmonary aspergillosis during prolonged neutropenia: a randomized, placebo-controlled trial. *Clin Infect Dis* 2008;46:1401-8.
- Patterson TF, Thompson GR 3rd, Denning DW, et al. Practice Guidelines for the Diagnosis and Management of Aspergillosis: 2016 Update by the Infectious Diseases Society of America. *Clin Infect Dis* 2016;63:e1-60.
- De Mol W, Bos S, Beeckmans H, et al. Antifungal Prophylaxis After Lung Transplantation: Where Are We Now? *Transplantation* 2021;105:2538-45.
- De Pauw B, Walsh TJ, Donnelly JP, et al. Revised definitions of invasive fungal disease from the European Organization for Research and Treatment of Cancer/Invasive Fungal Infections Cooperative Group and the National Institute of Allergy and Infectious Diseases Mycoses Study Group (EORTC/MSG) Consensus Group. *Clin Infect Dis* 2008;46:1813-21.
- Ju C, Shi B, Group C. Technical specification for clinical diagnosis and treatment for invasive fungal disease in organ transplant recipients (2019 edition). *Organ Transpl* 2019;10:359-64.
- Costanzo MR, Dipchand A, Starling R, et al. The International Society of Heart and Lung Transplantation Guidelines for the care of heart transplant recipients. *J Heart Lung Transplant* 2010;29:914-56.
- Crespo MM, McCarthy DP, Hopkins PM, et al. ISHLT Consensus Statement on adult and pediatric airway complications after lung transplantation: Definitions, grading system, and therapeutics. *J Heart Lung Transplant* 2018;37:548-63.
- Alissa D, AlMaghrabi R, Nizami I, et al. Nebulized Amphotericin B Dosing Regimen for *Aspergillus* Prevention After Lung Transplant. *Exp Clin Transplant*

- 2021;19:58-63.
15. Bhaskaran A, Mumtaz K, Husain S. Anti-Aspergillus Prophylaxis in Lung Transplantation: A Systematic Review and Meta-analysis. *Curr Infect Dis Rep* 2013;15:514-25.
 16. Neoh CF, Snell GI, Kotsimbos T, et al. Antifungal prophylaxis in lung transplantation--a world-wide survey. *Am J Transplant* 2011;11:361-6.
 17. Chang A, Musk M, Lavender M, et al. Epidemiology of invasive fungal infections in lung transplant recipients in Western Australia. *Transpl Infect Dis* 2019;21:e13085.
 18. Monforte V, Ussetti P, López R, et al. Nebulized liposomal amphotericin B prophylaxis for Aspergillus infection in lung transplantation: pharmacokinetics and safety. *J Heart Lung Transplant* 2009;28:170-5.
 19. Yun JH, Lee SO, Jo KW, et al. Infections after lung transplantation: time of occurrence, sites, and microbiologic etiologies. *Korean J Intern Med* 2015;30:506-14.
 20. Gago S, Denning DW, Bowyer P. Pathophysiological aspects of Aspergillus colonization in disease. *Med Mycol* 2019;57:S219-27.
 21. Chong PP, Kennedy CC, Hathcock MA, et al. Epidemiology of invasive fungal infections in lung transplant recipients on long-term azole antifungal prophylaxis. *Clin Transplant* 2015;29:311-8.
 22. Chishimba L, Langridge P, Powell G, et al. Efficacy and safety of nebulised amphotericin B (NAB) in severe asthma with fungal sensitisation (SAFS) and allergic bronchopulmonary aspergillosis (ABPA). *J Asthma* 2015;52:289-95.

Cite this article as: Ju C, Lian Q, Wang X, Wang L, Zhang J, Cai Y, Xu X, Chen R, He J. Efficacy of different durations of antifungal prophylaxis with nebulized amphotericin B after lung transplantation: a retrospective cohort study. *J Thorac Dis* 2023;15(10):5396-5404. doi: 10.21037/jtd-23-601