

Invasive *Streptococcus agalactiae* Disease With Meningitis and Septic Arthritis in a Non-pregnant Patient

Review began 10/27/2022
Review ended 11/02/2022
Published 11/04/2022

© Copyright 2022

Coelho et al. This is an open access article distributed under the terms of the Creative Commons Attribution License CC-BY 4.0., which permits unrestricted use, distribution, and reproduction in any medium, provided the original author and source are credited.

Telmo Coelho¹, Maria Pacheco², Tiago Mendes³, João Valente¹, Pedro Gil¹

1. Internal Medicine, Centro Hospitalar Vila Nova de Gaia/Espinho, Vila Nova de Gaia, PRT 2. Internal Medicine, Hospital Sousa Martins - Unidade de Saúde Local da Guarda, Guarda, PRT 3. Medicina, Hospital Conde de Bertiandos, Unidade Local de Saude Do Alto Minho (ULSAM), Ponte de Lima, PRT

Corresponding author: Telmo Coelho, telmocoelho91@gmail.com

Abstract

Streptococcus agalactiae is a common constituent of the human flora. However, infection in immunocompetent adults is uncommon and the involvement of the central nervous system (CNS) or development of septic arthritis are exceedingly rare and by our knowledge, were only described simultaneously once in a retrospective study.

We present the case of a 66-year-old woman with *S. agalactiae* bacteremia presenting meningitis and septic arthritis of the left shoulder. The patient presented to the emergency department with altered mental status and fever. Lumbar puncture revealed cerebral spine fluid (CSF) pleocytosis and elevated proteins. Blood and CSF cultures identified the presence of a susceptible strain of *S. agalactiae*.

During hospitalization, the patient complained of left shoulder pain, enabling the identification of articular fluid collections, which were drained confirming their infectious origin. Colic ulcers were found to be the starting point of this infection with posterior involvement of the CNS and the development of septic arthritis by hematogenous dissemination.

Categories: Internal Medicine, Infectious Disease

Keywords: streptococcus agalactiae meningitis, streptococcus agalactiae, septic arthritis, meningitis, group b streptococcus agalactiae bacteremia

Introduction

Streptococcus agalactiae, a gram-positive coccus bacterium, is a common constituent of the normal flora of a human. It is primarily found in genital flora and eventually transmitted during labour and delivery, resulting in the colonisation of the baby [1]. Therefore, *S. agalactiae* infections are more common in pregnant women and neonates [2]. In some cases, it can cause bacteraemia in non-pregnant adults, mostly in immunocompromised hosts and patients with hepatic or renal failure [3].

However, the involvement of the central nervous system (CNS) or development of septic arthritis is exceedingly rare, and to our knowledge, was only described simultaneously once in a retrospective study [4]. In fact, in large cohort studies only 0.4% to 7.4% of bacterial meningitis were caused by *S. agalactiae*, usually associated with one of three predisposing conditions: immunocompromised patients, cerebral spinal fluid (CSF) leakage or extra meningeal sanctuary, like an abscess or endocarditis [5-7].

Septic arthritis due to *S. agalactiae* remains rare, being responsible for only 5%-10% of all septic arthritis [8,9]. Large retrospective studies found that articular involvement was associated with predisposing conditions, such as immunosuppressive diseases or vaginal colonization at the time of delivery [8,9]. Knee and shoulder joints were found to be more commonly affected [8,9].

Case Presentation

We present the case of a 66-year-old woman admitted to the emergency department (ED) with altered level of consciousness in the last 24 hours characterized by confusion and disorientation. She had a past medical history of hypertension, dyslipidaemia, being overweight, and alcohol consumption of 50 grams per week.

On physical examination, she was disoriented and had disorganized speech. She also had mild abdominal tenderness, but the evaluation was otherwise unremarkable, notably Kernig and Brudzinski signs were negative. She had a fever (body temperature of 38.3 degrees Celsius), normal blood pressure (122/73mmHg), heart rate (83 beats per minute) and oxygen saturation level (98% at room air). Blood tests performed in the ED revealed leucocytosis (9,470/ μ L) with neutrophilia (86%), and an elevated C-reactive protein level of 17.38mg/dL. Blood urea nitrogen (BUN) and liver function tests were normal. A head computed tomography

How to cite this article

Coelho T, Pacheco M, Mendes T, et al. (November 04, 2022) Invasive *Streptococcus agalactiae* Disease With Meningitis and Septic Arthritis in a Non-pregnant Patient. *Cureus* 14(11): e31077. DOI 10.7759/cureus.31077

(CT) scan showed no signs of increased intracranial pressure or other abnormal results. A lumbar puncture was performed which revealed pleocytosis (14 leukocytes, 50% polymorphonuclears) and high protein levels (662/ μ L).

Blood cultures were collected and empirical antibiotic therapy with Ceftriaxone, Ampicillin and Acyclovir was started, with the patient being admitted to the Internal Medicine Department. A susceptible strain of *S. agalactiae* was later identified in cerebrospinal fluid as well as in blood cultures, which allowed us to de-escalate antimicrobial therapy to Ampicillin alone.

The diagnosis of *S. agalactiae* bacteraemia with meningitis was clear but we still struggled to find an explanation for this infection in an immunocompetent and non-pregnant woman without previous history of head trauma or neurosurgical interventions. To exclude diseases associated with immunocompromise, viral serologies (HIV, HBV and HCV) were performed, which were negative. A complete cervical, thoracoabdominal and pelvic CT scan found no abnormalities.

During the first week at the hospital, the patient complained of abdominal pain, diarrhoea and haematochezia. She underwent endoscopic examinations: revealing a normal upper gastrointestinal endoscopy and a colonoscopy presenting ulcers with irregular edges in the sigmoid colon, without bleeding stigmata. Biopsy of ulcers confirmed an infectious aetiology, allowing us to presumably consider the colic ulcers as the primary source of the *S. agalactiae* infection. CNS involvement was probably due to hematogenous dissemination.

At this time, the fever recurred, and the patient started to complain about left shoulder pain, swelling and movement limitation. New blood cultures were collected, and antibiotic therapy was switched to Ceftriaxone. Articular ultrasound (Figure 1) showed hypoechoogenic fluid collections, which were confirmed by CT (Figure 2).

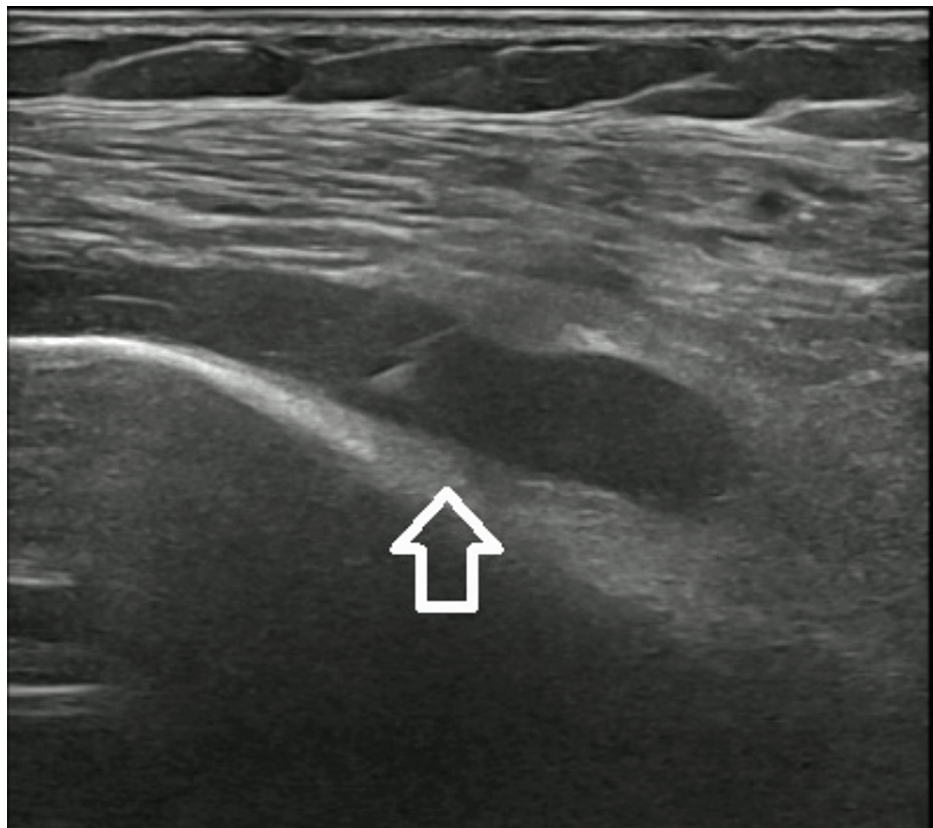


FIGURE 1: Left shoulder ultrasound revealing hypoechoogenic fluid collections.

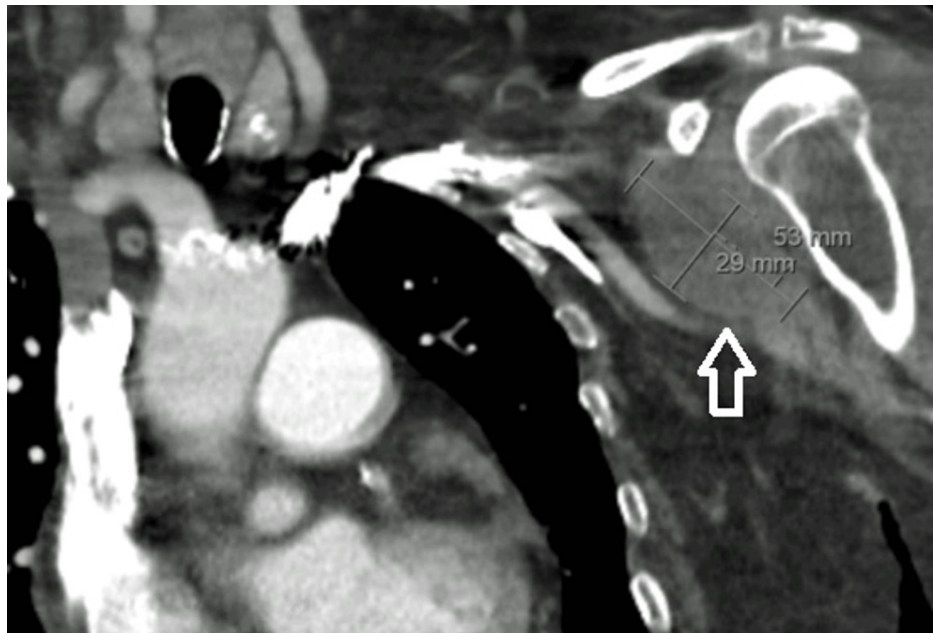


FIGURE 2: Left shoulder CT scan showing hypodense fluid collections.

The patient underwent ultrasound-guided arthrocentesis (Figure 3) and articular debridement. Fluid analysis (90.413/ μ L leukocytes, 95% polymorphonuclear) substantiated the diagnosis of septic arthritis. Nevertheless, blood and articular fluid cultures were negative.

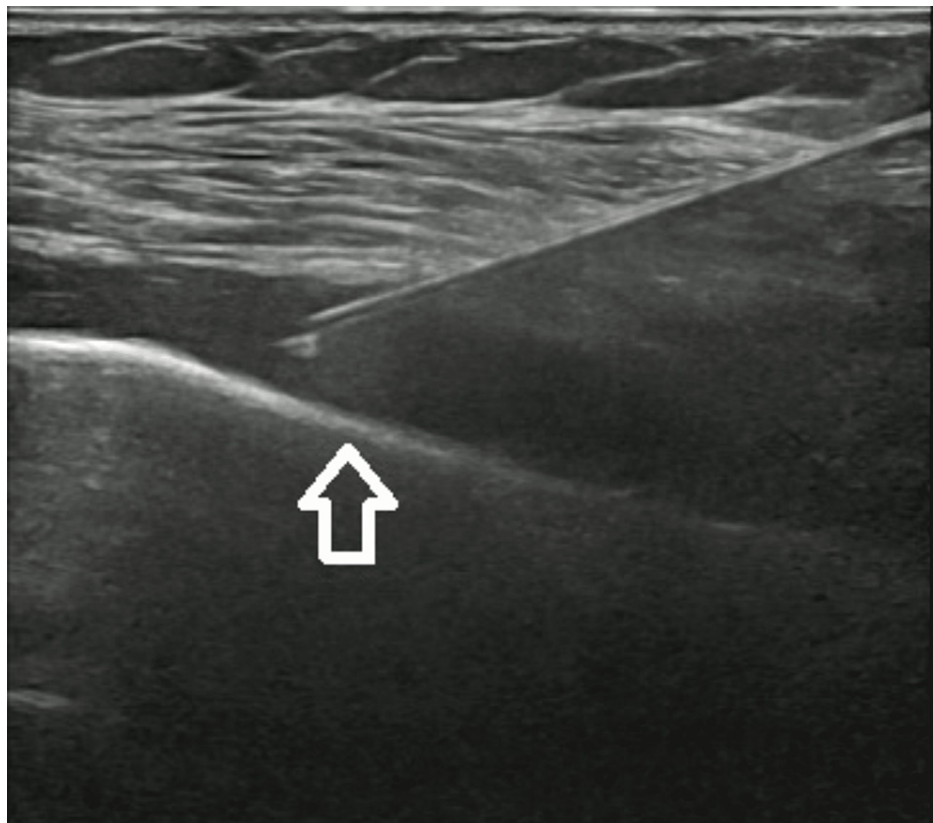


FIGURE 3: Ultrasound-guided left shoulder fluid drainage.

After a multidisciplinary team meeting, we concluded that an invasive *S.s agalactiae* infection with primary source in colic ulcers, resulting in bacteraemia and haematogenous dissemination causing CNS and articular

affection, was the most likely diagnosis. After six weeks of directed antimicrobial therapy, the patient had a complete resolution of confusion and shoulder pain and did not have any gastrointestinal complaints.

Discussion

S. agalactiae infections are more frequent in pregnant women and neonates but are much rarer in non-pregnant adults [1]. However, in some cases, it can present with bacteraemia in non-pregnant adults. Retrospective studies [2,3] and a recent meta-analysis [10] studied some factors predisposing to develop *S. agalactiae* infections and bacteraemia in non-pregnant adults, namely diabetes, malignancies, liver and renal disease and immunosuppressive disorders.

In this case, we report the occurrence of invasive *S. agalactiae* infection in a patient without any known predisposing condition. Furthermore, the involvement of either the central nervous system or joint is exceedingly rare in immunocompetent adults. Large cohort studies and a meta-analysis [5-7] reported *S. agalactiae* as responsible for only 0.4% to 7.4% of all bacterial meningitis. Moreover, the affection of the central nervous system was found to be more frequent in infants and neonates or associated with a predisposing condition such as CSF leakages or extra meningeal sanctuaries, like an abscess or endocarditis. Equally the development of septic arthritis is rare. Large retrospective studies [8,9] showed that *S. agalactiae* is responsible for only 5%-10% of all septic arthritis and is usually linked to a predisposing risk factor as well.

Our patient, despite having no known predisposing risk factor or immunosuppression, developed two unusual manifestations of invasive *S. agalactiae* disease, meningitis, and septic arthritis. To our knowledge, the simultaneous occurrence of these manifestations was only described once in a retrospective study [4].

The occurrence of new symptoms, such as haematochezia and diarrhoea motivated further etiological investigation which enabled us to find the source of this infection, infectious colic ulcers. Both the CNS and articular affection were presumably caused by hematogenous dissemination. Synovial fluid cultures were negative, most likely, due to ongoing directed antimicrobial therapy.

Conclusions

In conclusion, *S. agalactiae* infection is uncommon in immunocompetent, non-pregnant adults. Furthermore, *S. agalactiae* bacteraemia with CNS or articular involvement is exceedingly rare. A high clinical suspicion, combined with the clinical examination, allows the identification of joint or central nervous system involvement. The early acquisition of blood and fluid cultures allows microbiological identification and prompt treatment initiation, improving the prognosis.

Additional Information

Disclosures

Human subjects: Consent was obtained or waived by all participants in this study. **Conflicts of interest:** In compliance with the ICMJE uniform disclosure form, all authors declare the following: **Payment/services info:** All authors have declared that no financial support was received from any organization for the submitted work. **Financial relationships:** All authors have declared that they have no financial relationships at present or within the previous three years with any organizations that might have an interest in the submitted work. **Other relationships:** All authors have declared that there are no other relationships or activities that could appear to have influenced the submitted work.

References

- Colbourn T, Gilbert R: An overview of the natural history of early onset group B streptococcal disease in the UK. *Early Hum Dev.* 2007, 83:149-56. [10.1016/j.earlhumdev.2007.01.004](https://doi.org/10.1016/j.earlhumdev.2007.01.004)
- Mrazova M, Krcmery V Jr, Kacmarikova M, Fargasova J, Docze A, Beno P: Bacteremia due to *Streptococcus agalactiae*. *Infect Control Hosp Epidemiol.* 2005, 26:509. [10.1086/503516](https://doi.org/10.1086/503516)
- Saad EJ, Baenas DF, Boisseau CS, et al.: *Streptococcus agalactiae* bacteremia in non-pregnant adult patients at two teaching hospitals. *Rev Argent Microbiol.* 2018, 50:280-4. [10.1016/j.ram.2017.08.002](https://doi.org/10.1016/j.ram.2017.08.002)
- Chaiwarith R, Jullaket W, Bunchoo M, Nuntachit N, Sirisanthana T, Supparatpinyo K: *Streptococcus agalactiae* in adults at Chiang Mai University Hospital: a retrospective study. *BMC Infect Dis.* 2011, 11:149. [10.1186/1471-2334-11-149](https://doi.org/10.1186/1471-2334-11-149)
- Brouwer MC, Tunkel AR, van de Beek D: Epidemiology, diagnosis, and antimicrobial treatment of acute bacterial meningitis. *Clin Microbiol Rev.* 2010, 23:467-92. [10.1128/CMR.00070-09](https://doi.org/10.1128/CMR.00070-09)
- Oordt-Speets AM, Bolijn R, van Hoorn RC, Bhavsar A, Kyaw MH: Global etiology of bacterial meningitis: a systematic review and meta-analysis. *PLoS One.* 2018, 13:e0198772. [10.1371/journal.pone.0198772](https://doi.org/10.1371/journal.pone.0198772)
- Dance D, Zadoks RN, Luangraj M, Simpson A, Chen SL, Barkham T: Community-acquired Group B streptococcal meningitis in adults. *J Infect.* 2020, 81:147-78. [10.1016/j.jinf.2020.03.009](https://doi.org/10.1016/j.jinf.2020.03.009)
- Nolla JM, Gómez-Vaquero C, Corbella X, et al.: Group B streptococcus (*Streptococcus agalactiae*) pyogenic arthritis in nonpregnant adults. *Medicine (Baltimore).* 2003, 82:119-28. [10.1097/00005792-200303000-00006](https://doi.org/10.1097/00005792-200303000-00006)
- Wang VT, Tan JH, Pay LH, Wu T, Shen L, O'Neill GK, Kumar VP: A comparison of *Streptococcus agalactiae*

septic arthritis and non-*Streptococcus agalactiae* septic arthritis. *Singapore Med J.* 2018, 59:528-33.
[10.11622/smedj.2018127](https://doi.org/10.11622/smedj.2018127)

10. Navarro-Torné A, Curcio D, Moisi JC, Jodar L: Burden of invasive group B *Streptococcus* disease in non-pregnant adults: a systematic review and meta-analysis. *PLoS One.* 2021, 16:e0258030.
[10.1371/journal.pone.0258030](https://doi.org/10.1371/journal.pone.0258030)