



Hydrogen Peroxide Poisoning—A Rare Cause of Portal Venous Gas

Correpati Rohith¹ B. S. Rajesh¹ Elangovan Archana¹ K. Srinivasan¹

¹Department of General Surgery, Jawaharlal Institute of Postgraduate Medical Education and Research (JIPMER), Pondicherry, India

Address for correspondence B.S. Rajesh, MS, DNB, Department of General Surgery, Jawaharlal Institute of Postgraduate Medical Education and Research (JIPMER), Pondicherry – 605 006, India (e-mail: rajeshbs89@gmail.com).

Indian J Radiol Imaging 2021;31:492–494.

Abstract

Hydrogen peroxide is a clear and odorless liquid at room temperature that can easily be mistaken for water. Its ingestion results in varied clinical and radiological squeals depending on the volume and concentration of the liquid. We present a case of a 22-year-old lady who accidentally ingested 30 to 40 mL of 3% hydrogen peroxide and presented with hematemesis and abdominal pain. On further radiological evaluation, she was found to have portal venous gas and pneumatosis of the bowel wall. She was conservatively managed with 100% oxygen and nil per os for 2 days following which the portal venous gas resolved. Hydrogen peroxide ingestion causes a massive release of oxygen and when its volume exceeds its solubility in blood, gas embolism occurs that is responsible for portal venous gas and pneumatosis. Close monitoring with conservative management will suffice in mild cases without the need for any therapeutic intervention.

Keywords

- ▶ gas embolism
- ▶ hydrogen peroxide poisoning
- ▶ hyperbaric oxygen therapy
- ▶ portal venous gas

Introduction

Hydrogen peroxide of varying concentrations is utilized in several household, medical, and industrial facilities due to its oxidizing properties.¹ Being a clear liquid and relatively odorless in less concentration, it can be easily mistaken to water resulting in accidental consumption, especially when stored in unlabeled bottles.² This leads to a spectrum of effects ranging from completely asymptomatic to life-threatening conditions such as hollow viscous perforation and gas embolism.³ Adverse effects occur due to direct caustic injury to the tissue, lipid peroxidation, and release of large amounts of oxygen resulting in embolism. Techniques such as hyperbaric oxygen therapy were tried before for treating gas embolisms but no clear consensus exists in this respect.³ Through this report, we present a case of hydrogen peroxide poisoning who presented with multiple episodes of hematemesis and on further evaluation, was found to have portal venous gas.

Case Report

A 22-year-old lady presented to the emergency with an alleged history of accidental ingestion of 30 to 50 mL of 3% hydrogen peroxide from an unlabeled container mistaking it for water. Following this, she had a burning type of pain in the epigastric region and the oropharyngeal region. She also complained of nausea associated with multiple episodes of vomiting, which were nonprojectile and bilious, and blood clots and partially digested food materials. She complained of vague abdominal distention and bloating sensation that relieved with multiple episodes of belching.

She did not complain of any cough, breathlessness, cyanosis, or stridor. She did not complain of any convulsions or any other neurovascular deficits. On examination, she was conscious, oriented, and afebrile. She had no pallor, icterus, or cyanosis. She had tachycardia of 100 beats per minute and blood pressure was 110/70 mm Hg and the respiratory

published online
July 28, 2021

DOI <https://doi.org/10.1055/s-0041-1734354>
ISSN 0971-3026

© 2021. Indian Radiological Association.

This is an open access article published by Thieme under the terms of the Creative Commons Attribution-NonDerivative-NonCommercial-License, permitting copying and reproduction so long as the original work is given appropriate credit. Contents may not be used for commercial purposes, or adapted, remixed, transformed or built upon. (<https://creativecommons.org/licenses/by-nc-nd/4.0/>).

Thieme Medical and Scientific Publishers Private Ltd. A-12, Second Floor, Sector -2, NOIDA -201301, India

rate was 16/min. She had a posterior pharyngeal wall congestion without any oropharyngeal erosions or blistering of mucosae to the visualized extent. Bilateral normal vesicular breath sounds were heard with no additional sounds. On per-abdominal examination, the patient's abdomen was soft with mild epigastric tenderness with no guarding or rigidity and normal bowel sounds were heard. Per-rectal examination showed normal stool stain with no melena. Initial blood investigations including liver and renal function tests were unremarkable. An abdominal X-ray was taken that revealed linear branching air shadows overlying the liver shadow. No free air or altered bowel pattern was seen (►Fig. 1). Abdominal ultrasonography showed linear echogenic shadows within the parenchyma of the liver reaching up to its periphery. Intravenous contrast-enhanced computed tomography (CT) scan showed portal venous gas in the intrahepatic portal vein radicals and pneumatosis of the antropyloric region of the stomach and the first part of the duodenum (►Figs. 2 and 3). Lungs appeared unremarkable. Upper gastrointestinal endoscopy was done after 48 hours and it revealed linear erosions in the body of the stomach with edema and erythema in the antral region with no active bleeding from any of the erosions. She was kept on nil per os started on pantoprazole infusion and antiemetics along with intravenous fluid supplementation. She did not have any further episodes of hematemesis during her course of hospital stay. As the patient was asymptomatic, she was kept under close observation and conservatively managed with 100% oxygen in for 2 days. She was started on oral sips at the end of the second post-admission day that she had tolerated. Follow-up ultrasonography and plain CT showed complete resolution of the portal venous gas and pneumatosis of the stomach and duodenal wall (►Fig. 4). Oral intake was escalated to a normal diet and she was discharged from the hospital in a stable condition and was advised to follow up on an outpatient department basis.

Discussion

Hydrogen peroxide is an oxidizing and bleaching agent and has a wider application as a common ingredient in

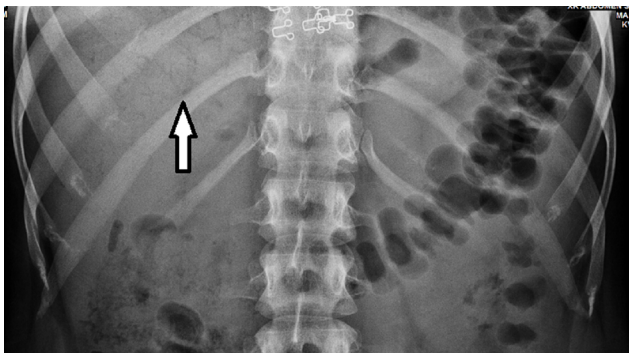


Fig. 1 Abdominal X-ray showing linear branching shadows over liver shadow (arrow).

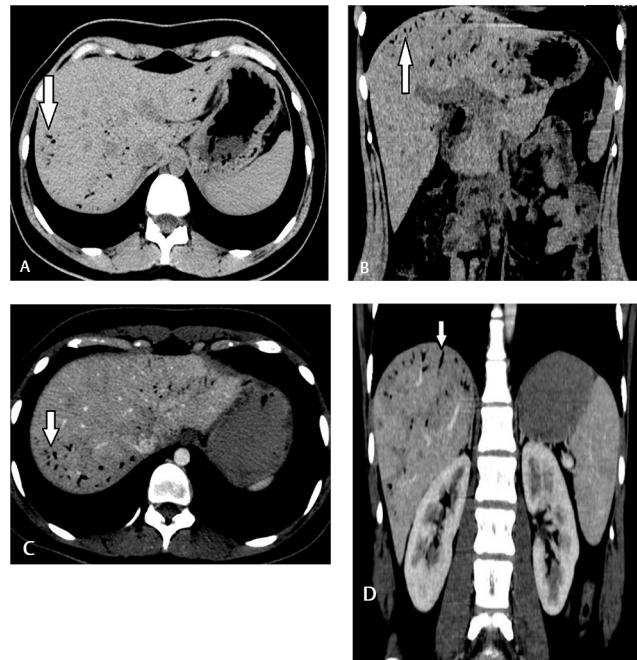


Fig. 2 (A) Axial section of plain computed tomography (CT) of the abdomen showing linear air pockets reaching the periphery (arrow). (B) Coronal section of plain CT of abdomen showing linear air pockets reaching the periphery (arrow). (C) Axial section of contrast-enhanced computed tomography (CECT) of the abdomen showing air within intrahepatic portal venous radicals (arrow). (D) Coronal section of CECT of the abdomen showing air within intrahepatic portal venous radicals (arrow).

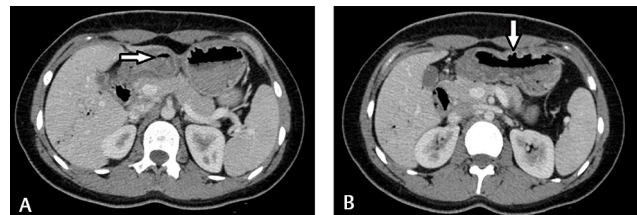


Fig. 3 (A) Axial section of contrast-enhanced computed tomography (CECT) of the abdomen showing pneumatosis within the wall of duodenum (arrow). (B) Axial section of CECT of the abdomen showing pneumatosis within the stomach wall with antropyloric wall thickening (arrow).

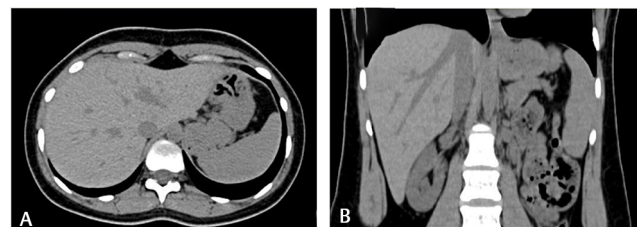


Fig. 4 (A) Axial section of plain computed tomography (CT) of abdomen showing complete resolution of the portal vein gas and pneumatosis within the stomach and duodenal wall. (B) Coronal section of plain CT of abdomen showing the complete resolution of the portal vein gas and pneumatosis within the stomach and duodenal wall.

domiciliary, industrial, and medical products such as hair dyes, bleaching agents, wound irrigation, and instrument sterilization liquids.¹ By forming oxygen free radicals, it mainly exerts its effects by causing corrosive damage, lipid peroxidation, and changes in normal acid–base balance.⁴

Only minor irritation of skin and mucosa occurs on its exposure in dilute concentrations. But, on ingestion, it causes painful gastric dilation, nausea, vomiting, belching, and other gastrointestinal symptoms. Respiratory symptoms ranging from mild cough and transient dyspnea to severe stridor, cyanosis resulting in cardiopulmonary arrest were reported depending on various concentrations ingested. Ocular exposure produces irritation and blurred vision but severe injury is unlikely. In cases of severe respiratory distress, immediate endotracheal intubation is advised for laryngeal edema. In the case of hematemesis, persistent vomiting, or significant dysphagia, upper gastrointestinal endoscopy is indicated.⁵

It releases oxygen in large quantities and when the gas levels exceed that of the maximum solubility in blood, air embolism occurs. This can have varied presentations such as multiple cerebral infarcts and loss of cardiac output based on the organ system involved.

Portal venous gas is a condition in which there is gas accumulation in the portal vein and its branches. Generally, it occurs due to conditions that involve bowel wall (bowel ischemia, inflammatory bowel disease, and peptic ulcer perforations) and inflammatory conditions (diverticulitis, colitis, or pancreatitis).⁶ Most of these conditions require aggressive intervention as it indicates serious underlying bowel pathology. It should be differentiated from pneumobilia in which the pattern of gas occurrence is central in contrast with peripheral gas formation in portal venous gas.⁷

But its occurrence can also be seen in less common and benign conditions such as hydrogen peroxide poisoning in which the underlying pathology is a gas embolism. In these cases, hyperbaric oxygen therapy will reduce the volume of gas emboli according to Boyle's law.³ In certain cases by administering 100% oxygen, these emboli can be resolved as occurred in this present case.⁸

Conclusion

Hydrogen peroxide ingestion causes gas embolism that may present with radiological findings like gastritis, pneumatosis, perforation, and portal venous gas. Active close monitoring with 100% oxygen in the Trendelenburg position can be considered in mild and asymptomatic cases instead of hyperbaric oxygen therapy.

Declaration of Patient Consent

Informed consent was taken from the patient for publication of the clinical details without revealing the identity.

References

- 1 Urban MV, Rath T, Radtke C. Hydrogen peroxide (H₂O₂): a review of its use in surgery. *Wien Med Wochenschr* 2019;169(9-10):222–225
- 2 Youssef EW, Chukwueke VS, Elsamaloty L, Moawad S, Elsamaloty H. Accidental concentrated hydrogen peroxide ingestion associated with portal venous gas. *J Radiol Case Rep* 2018;12(8):12–16
- 3 Papafragkou S, Gasparyan A, Batista R, Scott P. Treatment of portal venous gas embolism with hyperbaric oxygen after accidental ingestion of hydrogen peroxide: a case report and review of the literature. *J Emerg Med* 2012;43(1):e21–e23
- 4 Finnegan M, Linley E, Denyer SP, McDonnell G, Simons C, Maillard JY. Mode of action of hydrogen peroxide and other oxidizing agents: differences between liquid and gas forms. *J Antimicrob Chemother* 2010;65(10):2108–2115
- 5 Watt BE, Proudfoot AT, Vale JA. Hydrogen peroxide poisoning. *Toxicol Rev* 2004;23(1):51–57
- 6 Kesarwani V, Ghelani DR, Reece G. Hepatic portal venous gas: a case report and review of literature. *Indian J Crit Care Med* 2009;13(2):99–102
- 7 Sebastià C, Quiroga S, Espin E, Boyé R, Alvarez-Castells A, Armengol M. Portomesenteric vein gas: pathologic mechanisms, CT findings, and prognosis. *Radiographics* 2000;20(5):1213–1224, discussion 1224–1226
- 8 Dunbar EM, Fox R, Watson B, Akrill P. Successful late treatment of venous air embolism with hyperbaric oxygen. *Postgrad Med J* 1990;66(776):469–470