

A Rare Case of Metallosis Co-occurring With Chronic Prosthetic Joint Infection in Total Hip Arthroplasty

Review began 01/11/2022
Review ended 01/20/2022
Published 01/23/2022

© Copyright 2022

Imada et al. This is an open access article distributed under the terms of the Creative Commons Attribution License CC-BY 4.0., which permits unrestricted use, distribution, and reproduction in any medium, provided the original author and source are credited.

Allicia O. Imada¹, Brandon M. Painter¹, Bryce Clinger¹, Michael M. Decker^{2, 1}

1. Department of Orthopaedic Surgery and Rehabilitation, University of New Mexico School of Medicine, Albuquerque, USA 2. Department of Orthopaedic Surgery and Rehabilitation, University of New Mexico Sandoval Regional Medical Center, Rio Rancho, USA

Corresponding author: Allicia O. Imada, alimada@salud.unm.edu

Abstract

Prosthetic joint infection (PJI) and metallosis are known complications of total hip arthroplasty (THA) and are causes for revision surgeries. Articulating metal surfaces in total hip arthroplasty with corrosion at modular junctions can lead to the release of metal ions that can cause an immune-mediated biological reaction. There are few cases in the literature of both coinciding together. We describe a case of chronic *Cutibacterium acnes* PJI and metallosis co-occurring in a 64-year-old female after THA with a dual mobility construct. After undergoing uncomplicated left THA through a modified Hardinge approach, the patient dislocated anteriorly after four weeks and required revision of her acetabular component to a less anteverted position. Nine months later, she presented with hip pain and was found to have medial wall fragmentation and cystic changes around the greater trochanter on radiographs, elevated serum cobalt and chromium levels, and a benign noninfected hip aspiration. During her revision procedure, intraoperative histopathology showed over 20 neutrophils per high power field in multiple samples and fluid aspirates demonstrating Gram-positive rods. She was also found to have pseudotumor formation with the erosion of the anterior and posterior capsules with black debris on the femoral stem trunnion and the backside of the modular dual mobility liner. An antibiotic spacer was placed and her cultures grew into *C. acnes*. She completed six weeks of intravenous ceftriaxone and, during her "drug holiday," she dislocated her spacer and was found to have a lateral femoral diaphyseal stress fracture at the distal end of her spacer. She underwent stage II of her revision, and while the plan was to continue her antibiotics, she had an adverse reaction and was transitioned to oral antibiotics for six months. Due to delayed healing, she underwent additional irrigation and debridement with head and liner exchange. Her wound then healed, and at her one-year final follow-up, she was able to ambulate without pain, and her serum inflammatory and metal ion levels were within normal limits. Concurrent PJI and metallosis from articulating metal interfaces can occur, and a high index of suspicion is necessary to properly manage both conditions.

Categories: Orthopedics

Keywords: two-stage revision, prosthetic joint infection, adverse local tissue reaction, metallosis, total hip arthroplasty (tha)

Introduction

Metallosis is a known complication of articulating metal interfaces in total hip arthroplasty (THA) and is one type of adverse local tissue reaction (ALTR) [1]. Corrosion at modular junctions leads to the release of cobalt and chromium metal ions that penetrate soft and bony tissues, causing an immune-mediated biological reaction [2]. Patients typically present with groin, buttock, thigh, or peritrochanteric pain that is worse with weightbearing. Imaging findings include osteolysis on a radiograph as well as pseudotumor on MRI. Serum cobalt and chromium levels, erythrocyte sedimentation rate (ESR), and C-reactive protein (CRP) are often elevated. The overall incidence is as high as 5.3% in all types of THAs [3]. Treatment involves revision THA to remove the offending interfaces, diseased bone, and tissue in the periprosthetic space.

Prosthetic joint infections (PJI) occur in up to 2% of primary THAs and are the cause of approximately 15% of revisions [4]. PJI is caused by surface-adhering pathogens that create biofilms that are resistant to host defenses and microbial agents. There are various criteria for diagnosis, including sinus tract to the joint, two positive cultures of the same organism, elevated inflammatory markers, synovial cell counts, and alpha-defensins [5]. Treatment involves either partial or entire surgical removal of the prosthesis along with prolonged antibiotic therapy depending on the suspected timing and cause of infection [6].

There are a few cases in the literature of metallosis and PJI co-occurrence in total joint arthroplasty with various proposed mechanisms of metal ions leading to an increased risk of infection [7-10]. We present a rare case of a patient with early metallosis superimposed on chronic PJI (*Cutibacterium acnes*) in a THA with a modular dual mobility construct. Informed verbal consent was obtained prior to the preparation and submission of this manuscript.

How to cite this article

Imada A O, Painter B M, Clinger B, et al. (January 23, 2022) A Rare Case of Metallosis Co-occurring With Chronic Prosthetic Joint Infection in Total Hip Arthroplasty. Cureus 14(1): e21515. DOI 10.7759/cureus.21515

Case Presentation

A 63-year-old female presented with two years of left hip pain and a history of a right THA 10 years prior with good results. Radiographs demonstrated moderate osteoarthritis (Figure 1A, 1B), and serum metal ions and inflammatory markers were collected due to the presence of a modular neck construct in the right THA, which were found to be within normal limits. She failed nonoperative management, including full temporary pain relief from an intraarticular corticosteroid injection, and had evidence on magnetic resonance imaging (MRI) of cartilage loss. While her radiographs did not show severe osteoarthritis, radiographs do not always correlate with pain [11,12]. The patient underwent an uncomplicated left THA (Stryker Trident, modular dual mobility, high offset stem) using a posterolateral approach. Two grams of cefazolin were given after the induction of anesthesia, prior to skin incision. She was discharged on postoperative day (POD) 2 with a negative pressure incisional wound vac dressing (Avelle, ConvaTec, Deeside) as is standard in our practice.

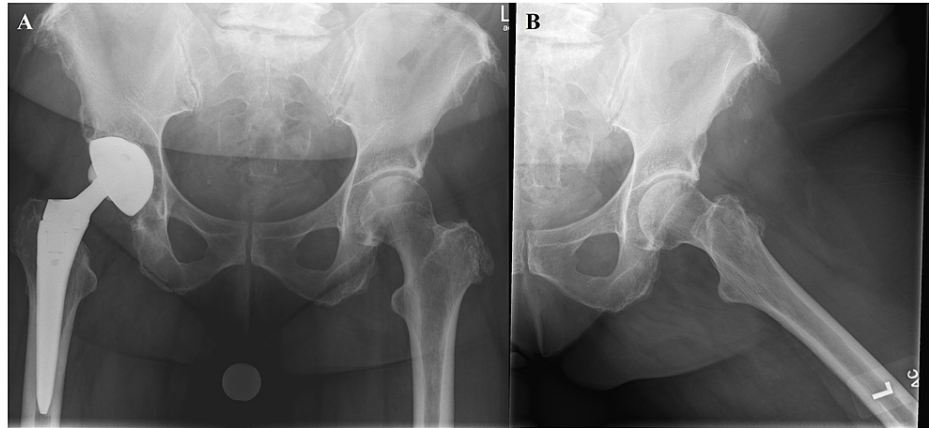


FIGURE 1: Preoperative anterior-posterior (A) and lateral (B) hip radiographs demonstrating moderate left hip osteoarthritis and a right total hip arthroplasty with a modular neck construct.

The patient developed early postoperative superficial wound breakdown, requiring frequent wound checks, dry dressing changes, and a short course of prophylactic oral antibiotics. The wound did heal and her staples were removed at POD 11 (Figure 2A). Her inflammatory labs were decreasing as expected. Her C-reactive protein decreased from 4.3 mg/dl (ref <0.3 mg/dl) on post-operative day 6 to 0.6 mg/dl at four weeks. Unfortunately, at four weeks postoperatively, the patient stepped awkwardly and sustained an anterior dislocation of her THA (Figure 2B, 2C). Radiographic appearance was concerning for intraprosthesis dislocation, which was a contraindication for closed reduction, so the decision was made to bring her to the operating room. Intraoperatively, we found that the bipolar head had not dissociated but was dislocated anteriorly. However, the version of the acetabular component was determined to be inappropriate for this patient, and the decision was made to revise her to decrease anteversion to reduce her future risk of dislocation (Figure 3A, 3B). Intraoperative cultures were negative. Her postoperative course went as expected, without wound complications and with normal radiographs. At five months, postoperative radiographs demonstrated a lucency medial to the acetabular component.

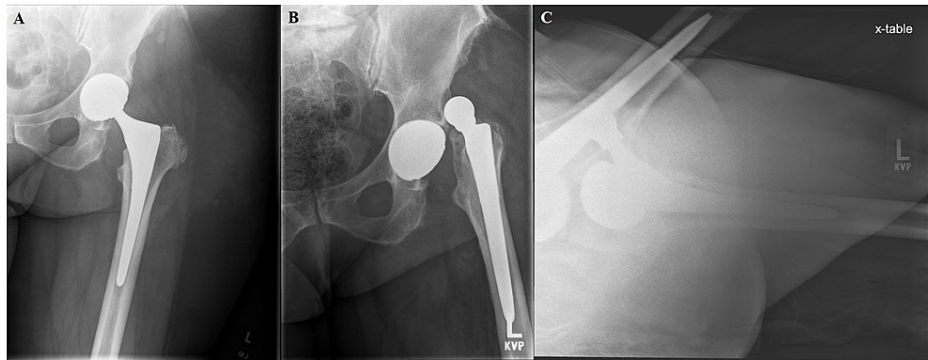


FIGURE 2: Anterior-posterior hip radiograph (A) at two weeks postoperatively after undergoing left THA (Stryker Trident, modular dual mobility, high offset stem) using a modified Hardinge approach. Patient sustained a fall and dislocated anteriorly as seen on anterior-posterior (B) and cross table lateral (C) radiograph.

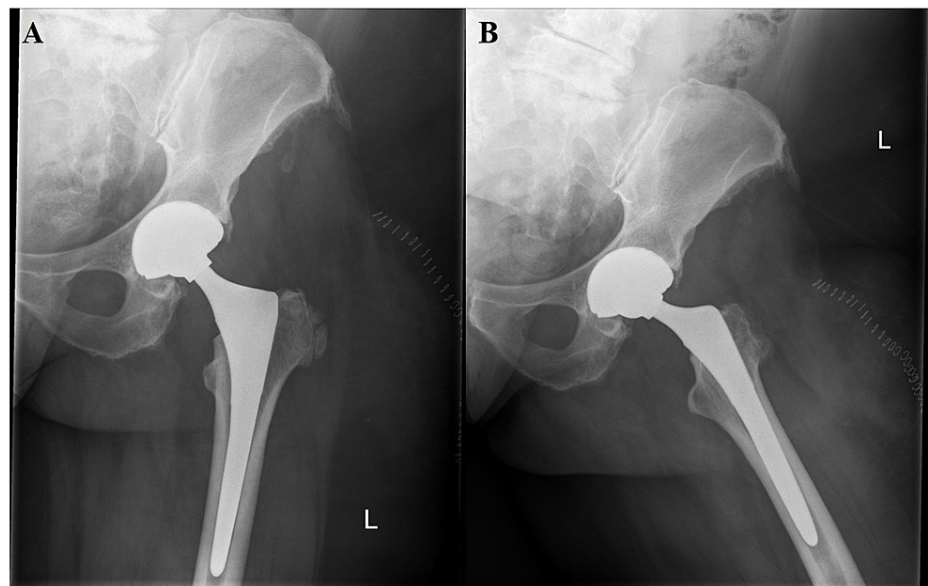


FIGURE 3: Two-week postoperative anterior-posterior (A) and lateral (B) radiographs after first revision surgery to a larger head and cup with decreased anteversion.

At nine months, she presented to the clinic with one week of increasing hip pain. She had pain with passive hip range of motion. Imaging showed previously noted medial wall fragmentation and cystic changes around the greater trochanter (Figure 4A, 4B). ESR was 91 mm/hour and CRP was 6.7 mg/dL, increased from 14 mm/hour and 0.6 mg/dL, respectively. Metal ions were also drawn with cobalt 4.4 $\mu\text{g/L}$ (ref $\leq 3.9 \mu\text{g/L}$) and chromium 1.7 $\mu\text{g/L}$ (ref $\leq 5.0 \mu\text{g/L}$). Hip aspiration showed cloudy, amber-colored fluid containing 1583 total nucleated cells, 7% neutrophils, 59% lymphocytes, and 34% mononucleated cells. Alpha defensin (Synovasure) was negative.

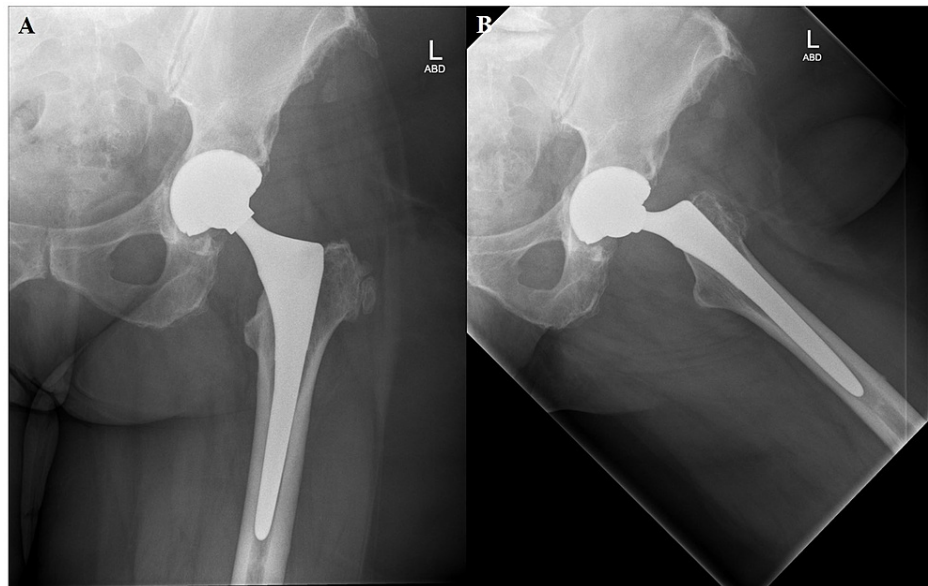


FIGURE 4: Nine-month postoperative anterior-posterior (A) and lateral (B) radiographs with signs of cup loosening. There is medial wall fragmentation and cystic change around the greater trochanter.

Given these findings, the patient was scheduled for revision THA. Intraoperative histopathology confirmed over 20 neutrophils per high power field in multiple samples and fluid aspirates demonstrating Gram-positive rods. There was also pseudotumor formation with the erosion of the anterior and posterior capsules with black debris on the femoral stem trunnion and the backside of the modular dual mobility liner. A thorough debridement was completed and a stage 1 revision with an antibiotic spacer was implanted with vancomycin and tobramycin cement (Figure 5A, 5B). She was made to touch down, weight-bearing. Cultures grew *C. acnes* and she was discharged on ceftriaxone 2 g intravenous daily and rifampin 300 mg twice a day for six weeks per infectious disease (ID) recommendations. Her wound healed appropriately. Antibiotics were discontinued after six weeks when her ESR and CRP normalized to 5 mm/hour and 0.3 mg/dL, respectively. The plan was for a two-and-a-half-week antibiotic holiday, rechecking her labs, and proceeding, if appropriate, with stage 2 of her revision.

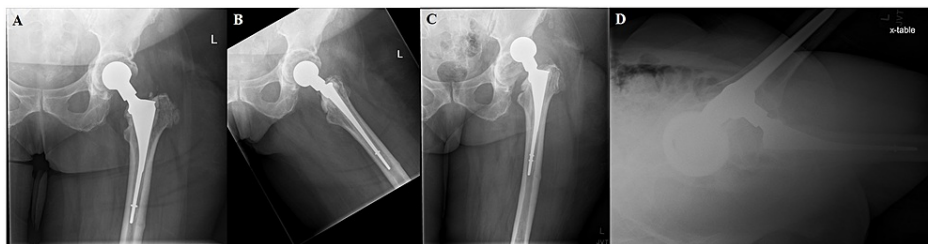


FIGURE 5: Six-week postoperative anterior-posterior (A) and lateral (B) radiographs after stage 1 of second revision procedure with placement of Zimmer antibiotic spacer. One week later, patient stepped awkwardly and dislocated the spacer (anterior-posterior - C, cross table lateral - D).

The patient, unfortunately, stepped awkwardly the following week and dislocated her spacer (Figure 5C, 5D) and had evidence on imaging of a lateral femoral diaphyseal stress fracture at the distal end of her spacer. After discussion with the patient about the residual risk of infection given that it had not been the full antibiotic holiday timeframe versus the morbidity of an extra surgical procedure, her second stage revision was completed the following day. Intraoperative histopathology and cultures were found to be negative. Despite this, ID recommended continuing ceftriaxone and rifampin due to concern about residual infection. The patient had an adverse reaction to ceftriaxone with flushing, pruritis, paresthesias, muscular weakness, palpitations, chest pain, and dyspnea. Therefore, she was transitioned to cephalexin at 1 g every eight hours and then to 500 mg for a total of six months.

On POD 16, she developed wound drainage and was taken to the operating room for irrigation and debridement, head and liner exchange, and wound vacuum placement. She was discharged on POD 3 with an ID recommendation to continue her current antibiotic regimen.

Her wound healed, and she progressed with physical therapy. At a one-year follow-up, she has weaned off all ambulatory aids and has no pain (Figure 6A-6C), with normal serum metal ions (cobalt <10.0 µg/L, chromium 1.6 µg/L) and inflammatory markers (ESR 17 mm/hour, CRP 1.0 mg/dL).

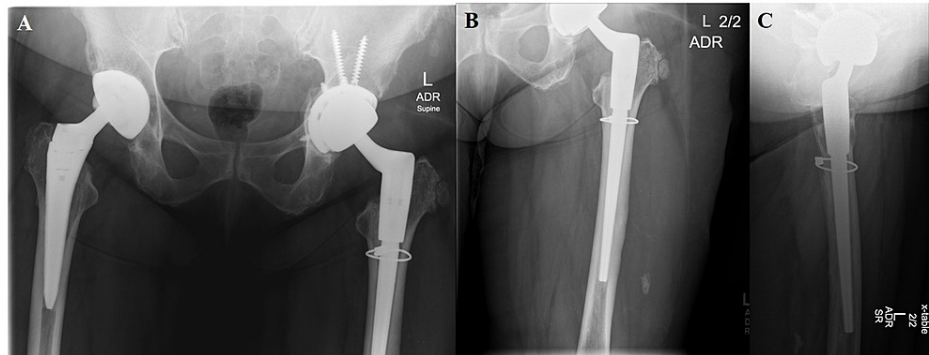


FIGURE 6: One-year postoperative radiographs [anterior-posterior pelvis (A), anterior-posterior left hip (B), lateral left hip (C)] after stage 2 of second revision using Stryker Res Mod system and cabling for femoral neck stress fracture with successful eradication of infection.

Discussion

To the best of our knowledge, we report the first case of metallosis and chronic PJI with isolated *C. acnes* in THA. PJI and metallosis do not often co-occur, with only case reports in the current literature [7-10]. These case reports describe nine patients: three THAs, three total knee arthroplasties, and three Birmingham hip resurfacings treated at various institutions with explants, one-stage revisions, or two-stage revisions and antibiotics. Infectious agents include *Klebsiella pneumoniae* and various species of *Streptococcus*, *Staphylococcus*, and *Enterobacter*. One case involved multiple bacteria, including two streptococcus species, *C. acnes*, and *staph hominis* [7]. The patient in our study had an infected revision THA after an initial revision for instability at nine months postoperatively. Infection was confirmed intraoperatively with over 20 neutrophils per high powered field, and while her aspiration numbers were not conclusive, they had grown Gram-negative rods by the time her stage one surgery occurred.

In previous case reports, the diagnosis was suspected preoperatively due to imaging (osteolysis, pseudotumor), serology (cobalt, chromium, ESR, CRP), aspiration, intraoperative findings, and/or histology. All these patients presented with pain and difficulty bearing weight, as in our case. Intraoperatively, evidence of ALTR includes metal-stained fluid/soft tissue, pseudocapsule, and pseudotumor [1]. In our patient, we found erosion of the anterior and posterior capsules with black corrosion of the femoral stem trunnion and modular metal acetabular liner intraoperatively. Histology can be an important diagnostic tool and will usually show necrotic and hemorrhagic tissues with a mixed inflammatory infiltrate of lymphocytes, plasma cells, and macrophages with intracytoplasmic metal debris [7,9].

Treatment and outcome varied greatly in the various case reports. Multiple patients were treated successfully with one-stage revision and intravenous antibiotics, while others required multiple irrigations and debridements, and one reported death. We propose that the bacteria's virulence, as well as the chronicity of actual infection, may play a role here. Our patient required multiple procedures but is not on life-long antibiotic suppression as in previous case reports. *C. acnes* has been found to be implicated in 4-6% of PJIs and has a high rate of successful eradication due to antibiotic susceptibility [13,14].

There is some evidence that metallosis may increase the risk of infection in total joint arthroplasty. Prieto et al. found a higher rate of infection in their MoM THAs (DePuy ASR) at the Mayo Clinic at 5.6% PJI compared to their normal documented 1.3% [15]. The exact cause of this is not clear. There is evidence that metal debris causes the release of proinflammatory cytokines [16]. Anwar et al. demonstrated that any type of particulate debris provides a scaffold for bacteria and biofilm formation, while cobalt and chromium debris specifically accelerate bacterial growth in vitro [17]. Our patient, unfortunately, had a very long and complicated clinical course due to her infection, metallosis, and instability. It is impossible to determine if PJI or metallosis occurred first, but there was some radiographic evidence of medial wall lucency at five months postoperatively.

Conclusions

While we often work to diagnose PJI or metallosis as our differential for painful THA, we need to keep in mind that they co-occur. Our case demonstrates the successful diagnosis and treatment of one such patient. Her clinical course was long and complicated, but at one year postoperatively, she was able to ambulate with a nonpainful hip.

Metallosis and PJI can present together in total hip arthroplasty and must not be missed to ensure appropriate treatment. These can be successfully treated with both antibiotics and staged revision surgery.

Additional Information

Disclosures

Human subjects: Consent was obtained or waived by all participants in this study. **Conflicts of interest:** In compliance with the ICMJE uniform disclosure form, all authors declare the following: **Payment/services info:** All authors have declared that no financial support was received from any organization for the submitted work. **Financial relationships:** All authors have declared that they have no financial relationships at present or within the previous three years with any organizations that might have an interest in the submitted work. **Other relationships:** All authors have declared that there are no other relationships or activities that could appear to have influenced the submitted work.

References

1. Drummond J, Tran P, Fary C: Metal-on-metal hip arthroplasty: a review of adverse reactions and patient management. *J Funct Biomater*. 2015, 6:486-99. [10.3390/jfb6030486](https://doi.org/10.3390/jfb6030486)
2. Cooper HJ: Diagnosis and treatment of adverse local tissue reactions at the head-neck junction. *J Arthroplasty*. 2016, 31:1581-4. [10.1016/j.arth.2016.02.082](https://doi.org/10.1016/j.arth.2016.02.082)
3. Chang JD, Lee SS, Hur M, Seo EM, Chung YK, Lee CJ: Revision total hip arthroplasty in hip joints with metallosis: a single-center experience with 31 cases. *J Arthroplasty*. 2005, 20:568-73. [10.1016/j.arth.2005.04.001](https://doi.org/10.1016/j.arth.2005.04.001)
4. Bozic KJ, Kurtz SM, Lau E, Ong K, Vail TP, Berry DJ: The epidemiology of revision total hip arthroplasty in the United States. *J Bone Joint Surg Am*. 2009, 91:128-33. [10.2106/JBJS.H.00155](https://doi.org/10.2106/JBJS.H.00155)
5. Parvizi J, Tan TL, Goswami K, Higuera C, Della Valle C, Chen AF, Shohat N: The 2018 definition of periprosthetic hip and knee infection: an evidence-based and validated criteria. *J Arthroplasty*. 2018, 33:1309-1314.e2. [10.1016/j.arth.2018.02.078](https://doi.org/10.1016/j.arth.2018.02.078)
6. Mussa M, Manciuoli T, Corbella M, et al.: Epidemiology and microbiology of prosthetic joint infections: a nine-year, single-center experience in Pavia, Northern Italy. *Musculoskelet Surg*. 2021, 105:195-200. [10.1007/s12306-020-00638-y](https://doi.org/10.1007/s12306-020-00638-y)
7. Barba T, Wach J, Lustig S, et al.: Metallosis-associated prosthetic joint infection. *Med Mal Infect*. 2015, 45:484-7. [10.1016/j.medmal.2015.09.009](https://doi.org/10.1016/j.medmal.2015.09.009)
8. Jagdale V: A case report and literature review to aid in the management of trunnion failure in hip arthroplasty patients: can trunnionosis and prosthetic joint infection co-exist?. *Cureus*. 2019, 11:e5544. [10.7759/cureus.5544](https://doi.org/10.7759/cureus.5544)
9. Donaldson JR, Miles J, Sri-Ram K, Poullis C, Muirhead-Allwood S, Skinner J: The relationship between the presence of metallosis and massive infection in metal-on-metal hip replacements. *Hip Int*. 2010, 20:242-7. [10.1177/112070001002000216](https://doi.org/10.1177/112070001002000216)
10. Helito CP, Buarque de Gusmão CV, Angelini FJ, Tirico LE, Pécora JR: Severe metallosis following total knee arthroplasty: a case report and review of radiographic signs. *Skeletal Radiol*. 2014, 43:1169-73. [10.1007/s00256-014-1860-3](https://doi.org/10.1007/s00256-014-1860-3)
11. Kim C, Nevitt MC, Niu J, et al.: Association of hip pain with radiographic evidence of hip osteoarthritis: diagnostic test study. *BMJ*. 2015, 351:h5983. [10.1136/bmj.h5983](https://doi.org/10.1136/bmj.h5983)
12. Dieppe PA, Cushnaghan J, Shepstone L: The Bristol 'OA500' Study: progression of osteoarthritis (OA) over 3 years and the relationship between clinical and radiographic changes at the knee joint. *Osteoarthritis Cartilage*. 1997, 5:87-97. [10.1016/S1063-4584\(97\)80002-7](https://doi.org/10.1016/S1063-4584(97)80002-7)
13. Zappe B, Graf S, Ochsner PE, Zimmerli W, Sendi P: *Propionibacterium* spp. in prosthetic joint infections: a diagnostic challenge. *Arch Orthop Trauma Surg*. 2008, 128:1039-46. [10.1007/s00402-007-0454-0](https://doi.org/10.1007/s00402-007-0454-0)
14. Figa R, Muñetón D, Gómez L, Matamala A, Lung M, Cuchi E, Corona PS: Periprosthetic joint infection by *Propionibacterium acnes*: clinical differences between monomicrobial versus polymicrobial infection. *Anaerobe*. 2017, 44:143-9. [10.1016/j.anaerobe.2017.03.008](https://doi.org/10.1016/j.anaerobe.2017.03.008)
15. Prieto HA, Berbari EF, Sierra RJ: Acute delayed infection: increased risk in failed metal on metal total hip arthroplasty. *J Arthroplasty*. 2014, 29:1808-12. [10.1016/j.arth.2014.04.008](https://doi.org/10.1016/j.arth.2014.04.008)
16. Hosman AH, van der Mei HC, Bulstra SK, Busscher HJ, Neut D: Effects of metal-on-metal wear on the host immune system and infection in hip arthroplasty. *Acta Orthop*. 2010, 81:526-34. [10.3109/17455674.2010.519169](https://doi.org/10.3109/17455674.2010.519169)
17. Anwar HA, Aldam CH, Visuvanathan S, Hart AJ: The effect of metal ions in solution on bacterial growth compared with wear particles from hip replacements. *J Bone Joint Surg Br*. 2007, 89:1655-9. [10.1302/0301-620X.89B12.19714](https://doi.org/10.1302/0301-620X.89B12.19714)