

One-Stage Posterior Only Corpectomy and Fusion in the Treatment of a Unique Acute Low Lumbar L4 Burst Fracture Without Neurologic Deficit: A Case Presentation

Abstract

L4 and L5 fractures are different from those at the thoracolumbar area. These differences include anatomy, biomechanics, classification, and treatment possibilities. Given the accessible literature and lack of high-quality information about the management of low lumbar fractures, we describe the case of a young 26-year-old male was referred to our emergency medical center with a severe L4 vertebral body comminuted burst fracture with complete spinal canal compression (AO type 4). Incredible, all neurological functions were intact initially. The patient was cured through a one-stage posterior only vertebrectomy and fusion with preservation of all neurological functions. Clinical and radiologic follow-up was satisfactory after 2 years. In more severe lumbar injuries, decisions contain spinal decompression and stabilization through a posterior or anterior approach based on the surgeon's favorite. In our experience in this patient, a posterior approach only was used both for decompression and stabilization without routine challenging existing in anterior approaches.

Keywords: Case presentation, fusion, L4 burst fracture, posterior corpectomy

Introduction

Lower lumbar injuries are rare, and here are small data that one spine center has pronounced experience. These fractures contain 14% of all thoracolumbar injuries and are the consequence of high impact trauma.^[1,2]

Acute lower lumbar Spine fractures can cause major neurologic damage and mechanical instability. The ultimate surgical method for the management of unstable lower lumbar spine fractures remains questionable.^[1]

L4 and L5 fractures are different from those at the thoracolumbar area. These differences include anatomy, biomechanics, classification, and treatment possibilities. The infrequency of these damages is marked by their inadequate documents in the literature. Treatments need to be customized, and the recommendations for thoracolumbar trauma managing cannot essentially be shifted to low lumbar trauma.^[3]

Given the accessible literature and lack of high-quality information about the

This is an open access journal, and articles are distributed under the terms of the Creative Commons Attribution-NonCommercial-ShareAlike 4.0 License, which allows others to remix, tweak, and build upon the work non-commercially, as long as appropriate credit is given and the new creations are licensed under the identical terms.

For reprints contact: WKHLRPMedknow_reprints@wolterskluwer.com

management of low lumbar fractures, we describe the case of a patient with an L4 lumbar burst fracture who was cured through a one-stage posterior only vertebrectomy and fusion with preservation all neurological functions.

Case Report

A young 26-year-old male was referred to our emergency medical center following a motorcycle accident. On early examination, the patient was totally consciousness without any neurologic deficit. Imaging performed after initial resuscitation. Visceral examination and imaging were normal. He has severe back pain and tenderness. Computed tomography (CT) of the whole spine also showed a severe L4 vertebral body comminuted burst fracture with complete spinal canal compression (AO type 4) [Figure 1]. Incredible, on late examination, the patient was completely neurologically intact. Magnetic resonance imaging was inevitable because of his heart pacemaker.

How to cite this article: Haddadi K, Hosseini SM, Khadem A, Hashemian MB. One-stage posterior only corpectomy and fusion in the treatment of a unique acute low lumbar L4 burst fracture without neurologic deficit: A case presentation. *Asian J Neurosurg* 2020;15:691-4.

Submitted: 26-Mar-2020 **Revised:** 07-Apr-2020
Accepted: 29-Apr-2020 **Published:** 28-Aug-2020

**Kaveh Haddadi,
Seyed Mostafa
Hosseini¹,
Aliakbar Khadem¹,
Mohammad Bagher
Hashemian¹**

Department of Neurosurgery, Orthopedic Research Center, Mazandaran University of Medical Sciences, ¹Department of Neurosurgery, Faculty of Medicine, Mazandaran University of Medical Sciences, Sari, Mazandaran, Iran

Address for correspondence:
Dr. Kaveh Haddadi,
Associate Professor of
Neurosurgery, Spine Fellowship,
Department of Neurosurgery,
Orthopedic Research Center,
Mazandaran University of
Medical Sciences, Sari, Iran.
E-mail: kavehhaddadi56@gmail.
com

Access this article online

Website: www.asianjns.org

DOI: 10.4103/ajns.AJNS_115_20

Quick Response Code:



The severity of symptoms and the presence of the L4 fracture encouraged the decision toward surgical management. The option of total bed rest for several months and wait for the fracture to heal, was undesirable by both the patient and the doctors. Finally, these following surgical decisions were offered to the patient and his family:

1. Anterior retroperitoneal approach, L4 corpectomy and L3–L5 fixation with anterior titanium cage insertion with either lateral or posterior instrumentation
2. Posterior midline approach, L2–S1 pedicle screw fixation, and posterior and posterolateral bone grafting and fusion
3. One-stage posterior only approach, L4 vertebrectomy, and L2–L5 pedicle screw fixation with posterior titanium cage supplemented
4. Posterior midline approach, L4 vertebroplasty, L3–L5 pedicle screw fixation, and posterior and posterolateral bone grafting and fusion.

The patient decided to proceed with the standalone posterior L4 corpectomy (option 3) to diminish the surgical morbidity and reserve lumbar mobility. The goal of surgery was to provide sufficient cord decompression, anterior spinal structural support, and an acceptable spinal balance. The Informed consent was taken, and the patient was taken to the operating room on day 3 after admission.

Surgical techniques

The patient was placed in a prone position with extreme caution. After prepping and draping and defining the level under the guidance of C-Arm, the appropriate skin incision at the appropriate level was given in the midline. Paraspinal muscles shaved with the subperiosteal method. Bone involvement was seen in fracture level, and laminectomy was performed at fracture level. Dura matter was intact in the compression level incredible. Regardless of multiple bony fragmentations. The pedicular screw was inserted on both sides of the L2, L3, L5 vertebral bodies, and the rod placed on the left side. The vertebrectomy by loop magnification has done through the right pedicle of L4 by meticulous preserving all spinal nerve roots. The fractured segments removed, the L3–L4 and L4–L5 discectomy performed completely. With proper retraction, an expandable cage filled by auto and allograft bone chips obliquely entered in the created space between the L3 and L4 roots and placed in an appropriate position. After expanding the cage and ensuring proper placement, rod placed on the right side. After that, the posterolateral fusion performed with autograft and allograft [Figure 2].

Follow-up

He was immediately mobilized in an LSO brace, with good satisfaction. All neurologic function has preserved. CT scans performed in the 1st postoperative week showed no loss of lower lumbar lordosis. The patient was able

to ambulate independently and was discharged on the 2 postoperative days. At 2-year postoperatively, construct stability and solid bony fusion have been maintained with no further lordosis loss of the lumbosacral in control CT scan, and the patient was symptom-free at this period and return to his normal daily work [Figure 3].

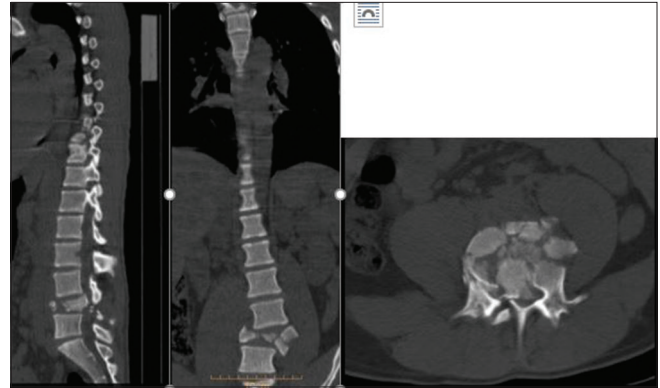

Figure 1: Sagittal, axial and coronal computed tomography scan revealed severe L4 burst fracture with completely canal compromise and posterior element involvement and decrease normal lumbar lordosis

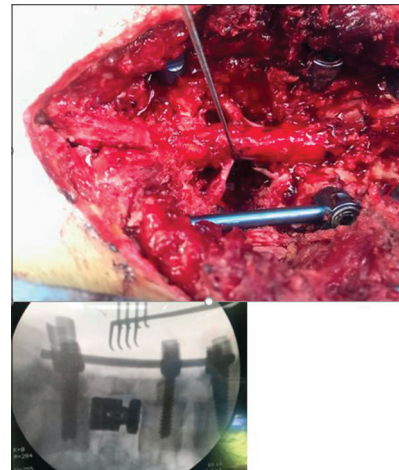


Figure 2: Intra-operative and final fluoroscopy imaging show one-stage corpectomy, titanium mesh implantation graft and pedicle screw fixation. Nerve hook retract gently the L4 nerve root and prepared a space for cage insertion (our practice in mazums spine center)

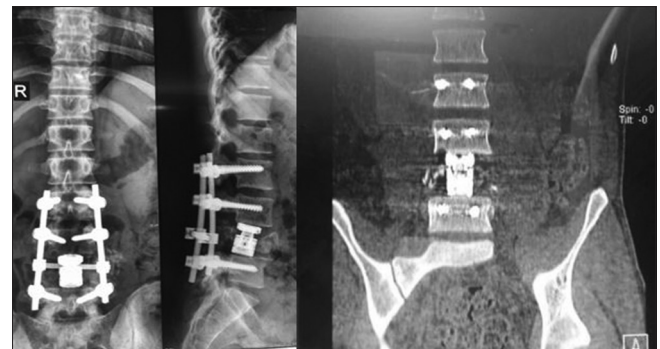

Figure 3: Two years postoperation computed tomography scan show good construct stability and solid bony fusion have been maintained with acceptable lumbar lordosis loss

Discussion

The L4 and L5 vertebra and related discs contribute to 50% of lordosis in the lumbar area.^[4-6] A narrow spinal canal has an opportunity for isolated nerve root injury in burst fractures or fracture-dislocation. The position of the lumbosacral junction inside the pelvic, the iliolumbar tendons, and the main muscle support sets need extraordinary level energy transmission to consequence in major damage to the lower lumbar vertebrae.^[5-7]

The classification for thoracolumbar trauma cannot be useful to fractures in L4 and L5 vertebra. This arrangement system would eliminate some common fractures and contain infrequent sub-groups.^[8] The compression and burst fracture, AO Type A, happens in the lower lumbar spine. AO Type B and C fractures like Chance and fracture-dislocations are extremely rare.^[8]

Here are distinctive anatomic features and particular biomechanics in the lower lumbar spine (L4–L5) that effect the response to trauma, and can defend diverse managements in this fracture.^[9]

Its regular lordosis permits the midpoint of gravity to drop posterior to the center of the body of L4 vertebra [Figure 4], cause fractures of lower lumbar fewer vulnerable to collapse or kyphosis, event that is routine in the thoracolumbar junction.^[3,10]

Neurologic problems are restricted through a wide neural canal, made the cauda equine less prone to damage, and mean its recovery rate high.^[11]

In these injuries, the anterior structures are commonly compromised. Anterior column insufficiency in the acute phase is associated with sagittal balance distortion. Deformity of the coronal plane will similarly consequence in unequal facet loading with probable faster degenerative change.^[4,12]

There is great controversy about the treatment of lumbar burst fractures without neurologic deficit.^[13,14] Surgical

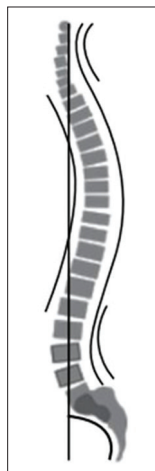


Figure 4: Center of gravity posterior to the body of L4^[3,10]

management classically includes: (1) A retroperitoneal corpectomy (2) posterior pedicle screw fixation (3) or a combined of them. The surgical indication and optimal procedure be influenced by numerous aspects, containing the severity of signs and symptoms, the amount of vertebral body height loss and spinal canal involvement, and finally, the continuity of the posterior spinal components.^[14-16]

Although, once the main aim is decompression of the spinal cord and stabilization of the spine unit, the anterior approach would be the optimal method.^[17] This approach delivers direct decompression of the neural elements, making proper anterior support and load sharing through the usage of a cage or graft.^[18] Conversely, vascular injury, extreme blood loss, injury of the abdominal wall, damages in the diaphragm, and incisional problems are associated with the anterior method.^[19] Newly, vertebrectomy through posterior only approaches via open or mini-open methods to the lumbar spine have been revealed to be safe and effective in the management of numerous spinal disorders counting vertebral fractures, with lowest blood loss, muscle injuries, and pain.^[19] The preservation of lumbar spinal nerve roots is vital in these approaches compared to the thoracic spine. The decision to use an anterior or posterior approach or a combination of these two approaches will vary depending on the individual patient and the surgeon's opinion.

Conclusion

Low lumbar spine fractures are relatively rare and have different injury configuration, biomechanical and neurological landscapes compared to thoracolumbar fractures. Hence, there has been great controversy about the paramount treatment for low lumbar burst fractures. Conservative care has been related to respectable outcomes for a patient with a burst fracture and neurologically intact. In more severe injuries, decisions contain spinal decompression and stabilization via a posterior or anterior approach based on surgeon's favorite. In our experience in this patient, a posterior approach only was used both for decompression and stabilization without routine challenging existing in anterior approaches, but, care must be taken to preserve all neural components.

Declaration of patient consent

The authors certify that they have obtained all appropriate patient consent forms. In the form the patient(s) has/have given his/her/their consent for his/her/their images and other clinical information to be reported in the journal. The patients understand that their names and initials will not be published and due efforts will be made to conceal their identity, but anonymity cannot be guaranteed.

Financial support and sponsorship

Nil.

Conflicts of interest

There are no conflicts of interest.

References

- Magerl F, Aebi M, Gertzbein SD, Harms J, Nazarian S. A comprehensive classification of thoracic and lumbar injuries. *Eur Spine J* 1994;3:184-201.
- Sansur CH, Shaffrey CI. Diagnosis and management of low lumbar burst fractures. *Semin Spine Surg* 2010;22(1):33-7.
- Islas DA, Jiménez Ávila JM. L4 fractures, biomechanics of cure foretold. *Coluna Columna* 2014;13:315-7.
- An HS, Vaccaro A, Cotler JM, Lin S. Low lumbar burst fractures. Comparison among body cast, Harrington rod, Luque rod, and Steffee plate. *Spine (Phila Pa 1976)* 1991;16:S440-4.
- Varlotta GP, Lefkowitz TR, Schweitzer M, Errico TJ, Spivak J, Bendo JA, *et al.* The lumbar facet joint: A review of current knowledge: Part 1: Anatomy, biomechanics, and grading. *Skeletal Radiol* 2011;40:13-23.
- Su BW, Kim PD, Cha TD, Lee J, April EW, Weidenbaum M, *et al.* An anatomical study of the mid-lateral pars relative to the pedicle footprint in the lower lumbar spine. *Spine (Phila Pa 1976)* 2009;34:1355-62.
- Vaccaro AR, Kepler CK, Rihn JA, Suzuki H, Ratliff JK, Harrop JS, *et al.* Anatomical relationships of the anterior blood vessels to the lower lumbar intervertebral discs. *J Bone Joint Surg Am* 2012;94:1088-94.
- Kriek JJ, Govender S. AO-classification of thoracic and lumbar fractures-reproducibility utilizing radiographs and clinical information. *Eur Spine J* 2006;15:1239-46.
- Schouten R, Fisher CG. Fusion for lower lumbar (L3-L5) fractures: Surgical indications and techniques. *Semin Spine Surg* 2011;23:249-56.
- Al-Khalifa FK, Adjei N, Yee AJ, Finkelstein JA. Patterns of collapse in thoracolumbar burst fractures. *J Spinal Disord Tech* 2005;18:410-2.
- Kingwell SP, Noonan VK, Fisher CG, Graeb DA, Keynan O, Zhang H, *et al.* Relationship of neural axis level of injury to motor recovery and health-related quality of life in patients with a thoracolumbar spinal injury. *J Bone Joint Surg Am* 2010;92:1591-9.
- Aihara T, Takahashi K, Yamagata M, Moriya H. Fracture-dislocation of the fifth lumbar vertebra. A new classification. *J Bone Joint Surg Br* 1998;80:840-5.
- Haddadi K, Yousefzadeh F. Epidemiology of traumatic spinal injury in North of Iran: A cross-sectional Study. *IrJNS* 2015;1.
- Robertson PA. Fractures of L4 and L5 (Low Lumbar Fractures). *Spineuniverse*; 2012.
- Oner FC, Wood KB, Smith JS, Shaffrey CI. Therapeutic decision making in thoracolumbar spine trauma. *Spine (Phila Pa 1976)* 2010;35:S235-44.
- Heary RF, Salas S, Bono CM, Kumar S. Complication avoidance: Thoracolumbar and lumbar burst fractures. *Neurosurg Clin N Am* 2006;17:377-88, Viii.
- Dai LY. Remodeling of the spinal canal after thoracolumbar burst fractures. *Clin Orthopaed Related Res* 2001;382:119-23.
- Verlaan JJ, Diekerhof CH, Buskens E, van der Tweel I, Verbout AJ, Dhert WJ, *et al.* Surgical treatment of traumatic fractures of the thoracic and lumbar spine: A systematic review of the literature on techniques complications, and outcome. *Spine* 2004;29:803-14.
- Dimar JR, Fisher C, Vaccaro AR, Okonkwo DO, Dvorak M, Fehlings M, *et al.* Predictors of complications after spinal stabilization of thoracolumbar spine injuries. *J Trauma* 2010;69:1497-500.