

# Repair of Uterine Rupture during Second Trimester Leading to Successful Pregnancy Outcome: Case Study and Literature's Review

Tae Sugawara, MD<sup>1</sup> Masaki Ogawa, MD, PhD<sup>1,2</sup> Toshinobu Tanaka, MD, PhD<sup>1</sup>

<sup>1</sup>Department of Obstetrics and Gynecology, Akita University School of Medicine, Hondo, Akita, Japan

<sup>2</sup>Perinatal Medical Center, Tokyo Women's Medical University, Shinjuku, Tokyo, Japan

Address for correspondence Masaki Ogawa, MD, PhD, Perinatal Medical Center, Tokyo Women's Medical University, Kawadacho 8-1, Shinjuku, Tokyo 1628666, Japan (e-mail: masakioogawa3@gmail.com).

Am J Perinatol Rep 2014;4:9–12.

## Abstract

### Keywords

- ▶ fleece-coated fibrin glue
- ▶ second trimester
- ▶ uterine rupture

It was thought to be impossible to prolong the pregnancy in a case of uterine rupture in the second trimester. We encountered a case of rupture of the pregnant uterus in early mid-trimester, which we repaired with suture and overlapping of collagen fleece coated with fibrin glue, resulting in pregnancy prolongation until the 34th week. Our case and five previously reported cases were reviewed. Pregnant uterine rupture in mid-trimester could be repaired with suture and overlapping of collagen fleece in the absence of placenta percreta.

Rupture of the pregnant uterus caused by separation of uterine myometrium is thought to be a life-threatening condition for the mother and fetus. For management of this condition, cesarean delivery may be suitable during the viable term of the fetus, followed by repair of the uterus. Hysterectomy may be appropriate if bleeding is uncontrolled.<sup>1</sup> However, during the previable term, we do not have any knowledge about what approach is better, cesarean section, repair, or hysterectomy.<sup>1</sup>

We encountered a case of rupture of the pregnant uterus that occurred during the early second trimester. Repair of the rupture site using collagen fleece led to successful pregnancy prolongation. In this case series study, we have reviewed our case and five previously reported cases, and have evaluated how repair of the pregnant ruptured uterus occurring in the second trimester would be managed.

## Materials and Methods

### Case

A 28-year-old Japanese woman, gravida 3 and para 2, was referred to our hospital with progressive abdominal pain after coitus at 14 + 5 weeks of gestation. Her pregnant history was (1) interruption, (2) cesarean section with low transverse

incision due to breech presentation, and (3) cesarean section with high transverse incision due to placental previa accreta, which needed intravenous methotrexate therapy and uterine arterial embolization. At admission, her vital signs were normal; blood pressure: 81/42 mm Hg; pulse: 66/min. Her hematocrit was 34.8%, hemoglobin 9.5 g/dL, and white blood cell count 7,400/ $\mu$ L. Ultrasonography revealed echo-free space in the vesicouterine pouch, suggesting hemoperitoneum. Six hours later, intra-abdominal bleeding increased, and signs of shock index were not observed, so minilaparotomy was performed. Hemoperitoneum (1,300 g of blood loss) was found with a myometrium defect on the uterine anterior wall, suggesting rupture of scarred uterus (**▶ Fig. 1a**). Her family did not give consent for total hysterectomy. Repair of the ruptured uterus was performed with three-layered separate stitches suture of 3–0 polyglactin 910 (Coated Vicryl, Ethicon, Inc., Somerville, NJ), subsequently covered using fleece-coated fibrin glue (TachoComb, CSL Behring, King of Prussia, PA). Her total blood loss was 1,745 g, for which she received four units of red blood cells. To prevent uterine rupture, she received continuous infusion of a tocolytic agent, ritodrine, with bed rest. We planned a laparotomy, as a second-look operation, to rule out placental percreta, and it was performed at 28 weeks of gestation. The rupture site was

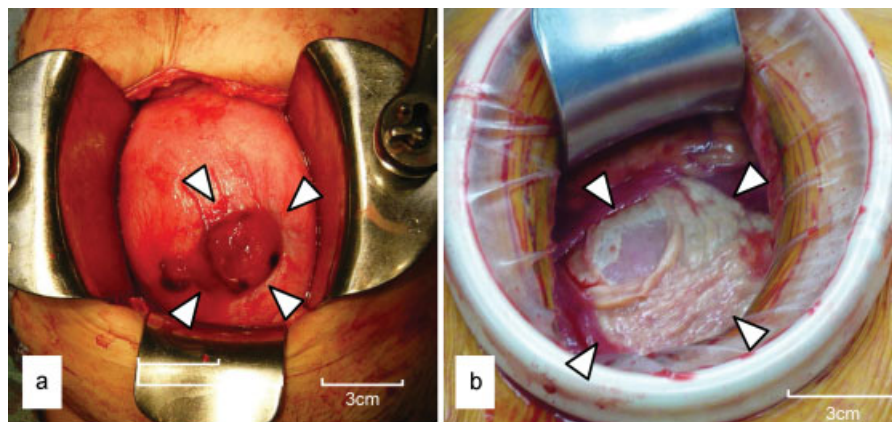
received  
September 6, 2013  
accepted after revision  
October 12, 2013  
published online  
December 17, 2013

DOI <http://dx.doi.org/10.1055/s-0033-1361926>.  
ISSN 2157-6998.

Copyright © 2014 by Thieme Medical Publishers, Inc., 333 Seventh Avenue, New York, NY 10001, USA.  
Tel: +1(212) 584-4662.

License terms





**Fig. 1** (a) Myometrium defect revealed on uterine surface (white arrows) at 14 + 5 weeks gestation and the placenta with continuous bleeding were represented. (b) White tissue (white arrows) derived from collagen fleece coated with fibrin glue covered the previous uterine wall defect at diagnostic laparotomy at 28th week.

completely covered with white tissue. No evidence of placenta percreta was noted (→**Fig. 1b**). A healthy baby weighing 2,600 g was delivered by elective cesarean section with normal Apgar scores at 34 + 6 gestational weeks.

#### Five Other Cases

A computer search was done using the terms “uterine rupture,” “second trimester,” and “repair” through the PubMed engine.<sup>2</sup> Twenty-seven articles were checked and five documents were extracted. The information from each is summarized in →**Tables 1 and 2**.

#### Discussion

Rupture of the pregnant uterus was thought to be a rare disorder, that is, less than 0.05% of pregnancies.<sup>3</sup> There has been an upward trend in threatened uterine rupture recently as the number of postcesarean section pregnancies has increased.<sup>4–6</sup> Eden et al<sup>7</sup> reported that rupture due to previous cesarean, referred to as scarred uterus, accounted for approximately 20% of all uterine ruptures in the 1980s. Furthermore, Rachagan et al<sup>8</sup> emphasized its frequency was over 50% in 1986. Pregnancy termination was indicated if uterine rupture occurred; hysterectomy may be needed in some instances. Repair of the ruptured uterus could possibly lead to pregnancy prolongation, and consequently could yield favorable maternal and fetal or neonatal outcomes.

Shirata et al<sup>9</sup> reported an interesting case of unscarred uterine rupture that occurred at 24 gestational weeks with massive hemoperitoneum of 2,200 g, which was repaired by combined therapy of absorbable suture and covering with fleece-coated fibrin glue, and then subsequently yielded favorable pregnancy prolongation until 35 gestational weeks. Their management was similar to our case. These two cases may suggest the utility of a collagen sheet for repair of uterine dehiscence. Collagen fleece has recent-

ly been used in many surgeries as a hemostatic agent, such as to treat pneumothorax. Collagen fleece maintains the strength of tissue by adhering to the tissue and forming a three-dimensional structure. Matsutani and Ozeki<sup>10</sup> examined the efficacy of overlapping of collagen fleece to repair pleural defects. They concluded that pleural circular defects 6 mm in diameter with overlapping of collagen fleece could withstand airway pressure of 40 cmH<sub>2</sub>O. They explained that collagen fleece resulted in adhesion of pleura. Therefore, collagen fleece may reinforce the uterine defect.

There have been several reports,<sup>9,11–14</sup> concerning repair of uterine ruptures in the second trimester using suture and/or patching. These five cases and our case are reviewed and summarized in →**Tables 1 and 2**. The putative cause of uterine rupture was mainly previous cesarean in early mid-trimester. The initial symptom was lower abdominal pain caused by hemoperitoneum. In complete rupture, rupture size was larger than in cases with incomplete rupture. All cases achieved sufficient pregnancy prolongation of more than 33 gestational weeks. In four cases, the placenta was located just beneath the rupture site. In these cases, it was impossible to distinguish uterine rupture and placenta percreta. Roeters et al<sup>15</sup> reported a case in which placenta percreta at 14 gestational weeks was repaired and subsequently resulted in pregnancy prolongation until the 35th week. However, they criticized their management because it did not rule out the possibility of a severe complication, that is, recurrence of hemoperitoneum due to placenta percreta. In our case, we performed diagnostic laparotomy to rule out placenta percreta. Repeated ultrasonographic examination may be needed for diagnosis of percreta.

In conclusion, uterine rupture in mid-trimester could be repaired with suture and overlapping of collagen fleece, if placenta percreta is absent. When placenta percreta is suspected, precise ultrasound monitoring or diagnostic laparotomy might be necessary after repair.

**Table 1** Outline of our case and five previous cases

No.	Age/G/P	Cause	Onset (GW)	Symptom	Shock vital	Hemoperitoneum (g)	Rupture site	Rupture size (cm)	Active bleeding from rupture site	Placental location	Complete rupture or incomplete rupture
1	28/3/2	Previous cesarean	14	Acute abdomen	Absent	1,300	Anterior	3	Continuously	Beneath	Complete
2	33/1/0	Previous cesarean	19	Acute abdomen	-	-	Right lateral	2	Present	Beneath	Complete
3	35/3/2	Previous cesarean	20	Acute abdomen	Present	-	Anterior	5	Continuously	Beneath	Incomplete
4	31/1/0	Unknown	21	Acute abdomen	Present	3,000	Fundal anterior	0.5	Present	Other	Complete
5	30/0/0	Unknown	24	Acute abdomen	Present	2,200	Fundal posterior	3	Continuously	Beneath	Complete
6	29/0/0	Unknown	26	Acute abdomen	-	Present	Fundal	3	Present	Other	Complete

Abbreviations: G, gravidity; GW, gestational weeks; P, parity.  
 Note: No. 1 is from our presented case, No. 2 from Martin et al,<sup>11</sup> No. 3 from Palacios-Jaraquemada et al,<sup>12</sup> No. 4 from Wang et al,<sup>13</sup> No. 5 from Shirata et al,<sup>9</sup> and No. 6 from Chen.<sup>14</sup>

**Table 2** Treatment and perinatal outcome of our case and five previous cases

No.	Repair	Delivery (GW)	Delivery route	Birth weight (g)	Apgar scores	Authors
1	Sutured with 3-0 Vicryl, patched by TachoComb	34	Cesarean	2,600	8/9	Present case
2	Sutured with Chromic Catgut and Ethibond, patched by GoreTex	33	Cesarean	2,220	8/9	Martin et al (1990)
3	Sutured with 5-0 Vicryl, patched by Vicryl Mesh	34	Cesarean	1,700	7/9	Palacios-Jaraquemada et al (2009)
4	Double layer sutured with 1-0 Monocryl, single layer sutured with 3-0 Vicryl	33	Cesarean	2,345	6/8/9	Wang et al (1999)
5	Sutured with Vicryl, patched by TachoComb	35	Cesarean	2,612	8/9	Shirata et al (2007)
6	Continuously sutured with 1 Chromic Catgut	37	Cesarean	2,842	-	Roeters et al (2007)

Abbreviation: GW, gestational weeks.  
 Note: No. 1 is from our presented case, No. 2 from Martin et al,<sup>11</sup> No. 3 from Palacios-Jaraquemada et al,<sup>12</sup> No. 4 from Wang et al,<sup>13</sup> No. 5 from Shirata et al,<sup>9</sup> and No. 6 from Chen.<sup>14</sup>

**Conflict of Interest**

The authors report no conflicts of interest. The authors are responsible for the content and writing the article.

**References**

- 1 Smith JF, Wax JR. Rupture of the unscarred uterus. in UpToDate. Available at: <http://www.uptodate.com/contents/rupture-of-the-unscarred-uterus>. Accessed February 17, 2012
- 2 PubMed Available at. Available at: <http://www.ncbi.nlm.nih.gov/pubmed/>. Accessed January 14, 2013
- 3 Hofmeyr GJ, Say L, Gülmezoglu AM. WHO systematic review of maternal mortality and morbidity: the prevalence of uterine rupture. *BJOG* 2005;112(9):1221–1228
- 4 Zwart JJ, Richters JM, Ory F, de Vries JI, Bloemenkamp KW, van Roosmalen J. Uterine rupture in The Netherlands: a nationwide population-based cohort study. *BJOG* 2009;116(8):1069–1078, discussion 1078–1080
- 5 Kieser KE, Baskett TF. A 10-year population-based study of uterine rupture. *Obstet Gynecol* 2002;100(4):749–753
- 6 Miller DA, Goodwin TM, Gherman RB, Paul RH. Intrapartum rupture of the unscarred uterus. *Obstet Gynecol* 1997;89(5 Pt 1):671–673
- 7 Eden RD, Parker RT, Gall SA. Rupture of the pregnant uterus: a 53-year review. *Obstet Gynecol* 1986;68(5):671–674
- 8 Rachagan SP, Raman S, Balasundram G, Balakrishnan S. Rupture of the pregnant uterus—a 21-year review. *Aust N Z J Obstet Gynaecol* 1991;31(1):37–40
- 9 Shirata I, Fujiwaki R, Takubo K, Shibukawa T, Sawada K. Successful continuation of pregnancy after repair of a midgestational uterine rupture with the use of a fibrin-coated collagen fleece (Tacho-Comb) in a primigravid woman with no known risk factors. *Am J Obstet Gynecol* 2007;197(4):e7–e9
- 10 Matsutani N, Ozeki Y. Pleural defect repair with an overlapping method using fibrin glue-coated collagen fleece. *Surg Today* 2011;41(9):1234–1237
- 11 Martin JN Jr, Brewer DW, Rush LV Jr, Martin RW, Hess LW, Morrison JC. Successful pregnancy outcome following mid-gestational uterine rupture and repair using Gore-Tex soft tissue patch. *Obstet Gynecol* 1990;75(3 Pt 2):518–521
- 12 Palacios-Jaraquemada JM, Fiorillo A, von Petery F, Colaci D, Leguizamón G. Uterine repair and successful pregnancy after myometrial and placental rupture with massive haemoperitoneum. *BJOG* 2009;116(3):456–460
- 13 Wang PH, Chao HT, Too LL, Yuan CC. Primary repair of cornual rupture occurring at 21 weeks gestation and successful pregnancy outcome. *Hum Reprod* 1999;14(7):1894–1895
- 14 Chen FP. Term delivery after repair of a uterine rupture during the second trimester in a previously unscarred uterus: a case report. *J Reprod Med* 2007;52(10):981–983
- 15 Roeters AE, Oudijk MA, Heydanus R, Bruinse HW. Pregnancy outcome after intra-abdominal bleeding due to placenta percreta at 14 weeks of gestation. *Obstet Gynecol* 2007;109(2 Pt 2):574–576