

RESEARCH

Open Access



# Effect of subacromial erosion shape on rotator cuff and clinical outcomes after hook plate fixation in type 5 acromioclavicular joint dislocations: a retrospective cohort study

Ho-Seok Oh, Sungmin Kim, Jeong-Hun Hyun and Myung-Sun Kim\*

## Abstract

**Background:** Surgical fixation using hook plates is widely used in the treatment of acromioclavicular (AC) joint dislocations. The purpose of this study was to evaluate the incidence and shape of subacromial erosions after removal of the hook plate in type 5 AC joint dislocations. Further, we evaluated the effect of the shape of the subacromial erosion on the rotator cuff.

**Methods:** We retrospectively reviewed 30 patients who underwent hook plate fixation for type 5 AC joint dislocations at our hospital between December 2010 and December 2018. Patients with a follow-up of at least 1 year were included. Clinical outcomes were assessed using the final follow-up Constant-Murley, Korean Shoulder, and visual analog scores. To ensure that the appropriate reduction was well maintained, the coracoclavicular distances of the injured and contralateral sides were evaluated at the last follow-up. Computed tomography was performed to investigate the presence and shape of the subacromial erosion after hook plate removal at 4 months after surgery. Ultrasonography was performed to investigate the presence of rotator cuff lesions at the last follow-up. Clinical and radiological outcomes were compared between groups divided according to the presence and types of subacromial erosions.

**Results:** Subacromial erosion was observed in 60% of patients (18/30): 13, 2, and 3 simple groove, cave, and marginal protrusion types, respectively. Four patients showed reduction loss at the final follow-up. There were no significant differences in clinical and radiological outcomes between the groups with and without subacromial erosion. Moreover, there were no significant differences between groups according to the types of subacromial erosion. There were no rotator cuff lesions, such as partial tears, in the injured shoulders.

**Conclusions:** Hook plate fixation may induce subacromial erosions. However, the subacromial erosions caused by the hook plate did not affect the clinical outcomes of type 5 AC joint dislocations. Moreover, regardless of its shape, the subacromial erosion did not affect the clinical outcomes nor cause rotator cuff lesions after plate removal.

**Keywords:** Acromioclavicular joint dislocation, Clavicle, Coracoclavicular distance, Hook plate fixation, Rotator cuff lesion, Shoulder, Subacromial erosion

## Background

Acromioclavicular (AC) joint dislocation is a common traumatic injury in the upper extremities, accounting for approximately 9% of all shoulder injuries. Moreover,

\*Correspondence: mskim@jnu.ac.kr  
Department of Orthopedic Surgery, Chonnam National University Hospital, 42 Jebong-ro, Dong-gu, Gwangju 61469, South Korea



© The Author(s) 2022. **Open Access** This article is licensed under a Creative Commons Attribution 4.0 International License, which permits use, sharing, adaptation, distribution and reproduction in any medium or format, as long as you give appropriate credit to the original author(s) and the source, provide a link to the Creative Commons licence, and indicate if changes were made. The images or other third party material in this article are included in the article's Creative Commons licence, unless indicated otherwise in a credit line to the material. If material is not included in the article's Creative Commons licence and your intended use is not permitted by statutory regulation or exceeds the permitted use, you will need to obtain permission directly from the copyright holder. To view a copy of this licence, visit <http://creativecommons.org/licenses/by/4.0/>. The Creative Commons Public Domain Dedication waiver (<http://creativecommons.org/publicdomain/zero/1.0/>) applies to the data made available in this article, unless otherwise stated in a credit line to the data.

up to 43.5% of athletes have AC joint dislocation after direct trauma to the shoulder [11, 16, 17, 22, 26, 28]. AC joint dislocations are classified into six types based on the extent of displacement of the clavicle relative to the acromion [1, 11, 21, 25]. For AC joint dislocation types 4–6, surgical indications are essential. For type 3 dislocations, the decision on conservative and surgical treatment is controversial [3, 8, 20, 23, 29].

Various surgical options are available for the treatment of acute AC joint dislocations. These include bandaging, fixation of the AC joint with pins, tension band wiring using the modified Weaver-Dunn procedure, fixation with washer and screw, and clavicular plate [5, 7, 13, 27]. Among these, the hook plate fixation technique shows excellent security. Its minimal surface contact yields sufficient blood supply and permits horizontal stability as a concomitant result of subacromial fixation [17, 29].

Stable fixation and early return to mobilization of the affected part are the main advantages of using a hook plate. However, previous studies have reported complications such as shoulder stiffness, subacromial erosion, impingement, and rotator cuff tear [4, 10, 12, 30]. The hook plate can be rigidly fixed on the clavicle while remaining mobile beneath the acromion. This may induce a pressure rise in the hook under the surface of the acromion causing erosion [30]. Some studies have evaluated the contact characteristics between the acromion and hook plate. These studies concluded that the pinpoint between the hook plate tip and the under surface of the acromion is the main factor inducing subacromial erosion [14, 30].

Many studies have revealed that the shape of the acromion affects the pathology of the rotator cuff. Thus, surgeons traditionally perform acromioplasty at the time of rotator cuff repair [2]. Outcomes after acromioplasty in the treatment of rotator cuff disease were good when surgeons converted a “curved” or “hooked” acromion into a “flat” shape [2, 9, 18]. Likewise, we hypothesized that if the subacromial erosion has a protruding shape so-called type III in our study, impingement of the rotator cuff can cause a rotator cuff lesion. To the best of our knowledge, there is lack of studies whether the subacromial erosion shape affects clinical outcomes and complications, such as shoulder impingement and rotator cuff lesions, in patients who undergo hook plate fixation.

This study analyzed clinical and radiological results after hook plate fixation surgery in patients with AC joint dislocation. The aim was to evaluate the incidence and shape of subacromial erosions after removal of the hook plate in type 5 AC joint dislocations. Further, the study evaluated the effect of the shape of the subacromial erosion on the rotator cuff.

## Methods

We enrolled 30 patients (26 men and 4 women; mean age, 47.5 years) who underwent hook plate fixation for AC joint dislocations at our hospital between December 2010 and December 2018. Cases with a follow-up period of at least 1 year were retrospectively analyzed. We only included patients with Rockwood classification type 5 AC joint dislocations [22] for consistency in evaluation conditions. Patients with clavicular fracture, contralateral upper arm impairment, nerve injury, previous surgical history in the same shoulder, and shoulder dysfunction due to previous injury were excluded. The mean follow-up duration was 31.0 months (range, 12.0–49.2 months). The hook plate was removed after a mean time interval of 4.6 months (range, 3.0–8.5 months).

The study was approved by the ethics committee of the institutional review board (IRB) of Chonnam National University Hospital (CNUH-2020-383). All methods were performed in accordance with the relevant guidelines and regulations. Written informed consent to participate was obtained from all the patients.

## Surgical technique

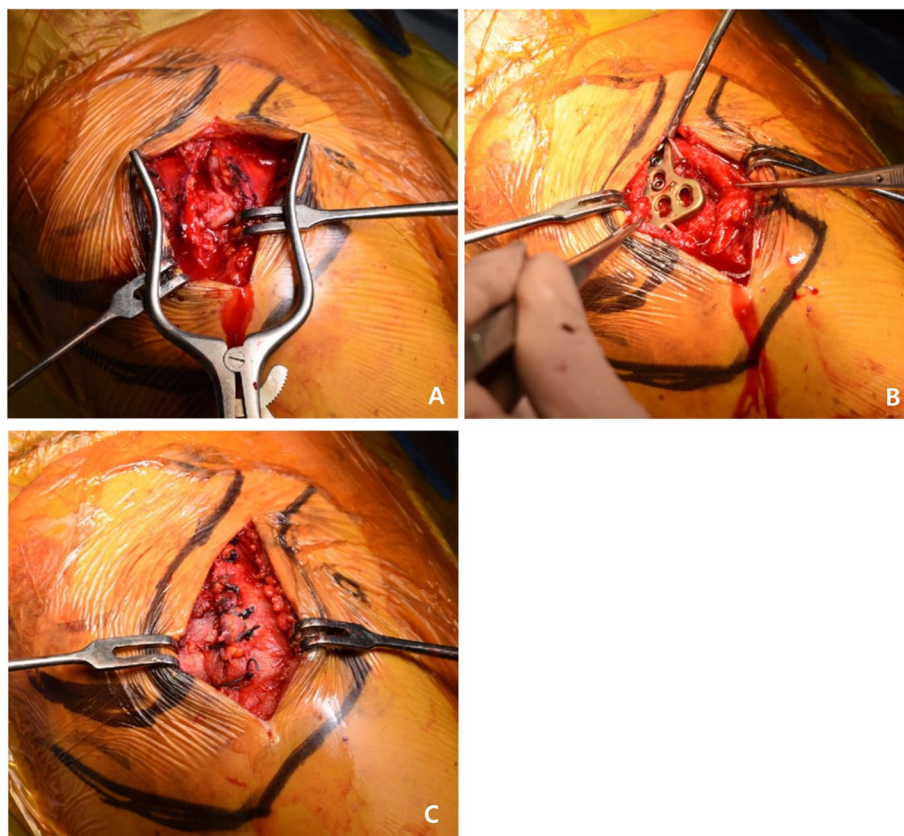
All surgeries were performed by a single orthopedic surgeon (MSK). Under general anesthesia, the patient was placed in the beach chair position. An anterior approach to the lateral part of the clavicle was used to perform a 4 cm straight incision. After cutting the deltotracheal fascia, the joint was reduced by direct visualization and fluoroscopy (Fig. 1A). An appropriately sized locking compression plate clavicle hook plate (DePuy Synthes, Oberdorf, Switzerland) was bended to fit the contour of acromion and clavicle, inserted into the rear bottom of the acromion, and the proximal end of the plate was fixed to the clavicle using several screws (Fig. 1B). Subsequently, the deltoid and trapezius muscle fascia were sutured at the avulsion site (Fig. 1C).

## Postoperative rehabilitation

After surgery, an arm sling was applied for 1 to 3 weeks depending on the patient's pain to protect the shoulder. Passive shoulder mobilization was initiated as soon as the postoperative pain had decreased. All patients were allowed to use their arms for daily activities. Non-restricted movement and strength-related activities were allowed 6 weeks and 3 months, respectively, after the surgery.

## Radiological evaluation

The anterior-posterior (AP) view of both shoulders was taken to evaluate the alignment of the lateral clavicle with the acromion on every follow-up day (Fig. 2). In all the patients, subacromial erosion was evaluated by



**Fig. 1** **A** The AC joint is exposed and reduced by direct visualization and fluoroscopy. **B** An LCP clavicle hook plate is inserted into the rear bottom of the acromion and proximal end of the plate. **C** Deltoid and trapezius muscle fascia are sutured at the avulsion site. AC, acromioclavicular; LCP, locking compression plate

computed tomography (CT) after implant removal. The type of subacromial erosion was determined based on the cut where the shape of the subacromial erosion was most clearly visible in the CT coronal view. When the width of the erosion at the upper level is the same or narrower than the width of the erosion at the acromial undersurface, the erosion is defined as type I (shallow groove). When the width of the erosion at the upper level is wide, it is defined as type II (cave). Bone protrusion around the subacromial erosion was defined as type III (marginal protrusion) (Fig. 3). We compared the clinical and radiological outcomes by dividing the patients into groups with and without subacromial erosion. Further, the patients were divided into three groups according to the subacromial erosion type (simple groove, cave, and marginal protrusion).

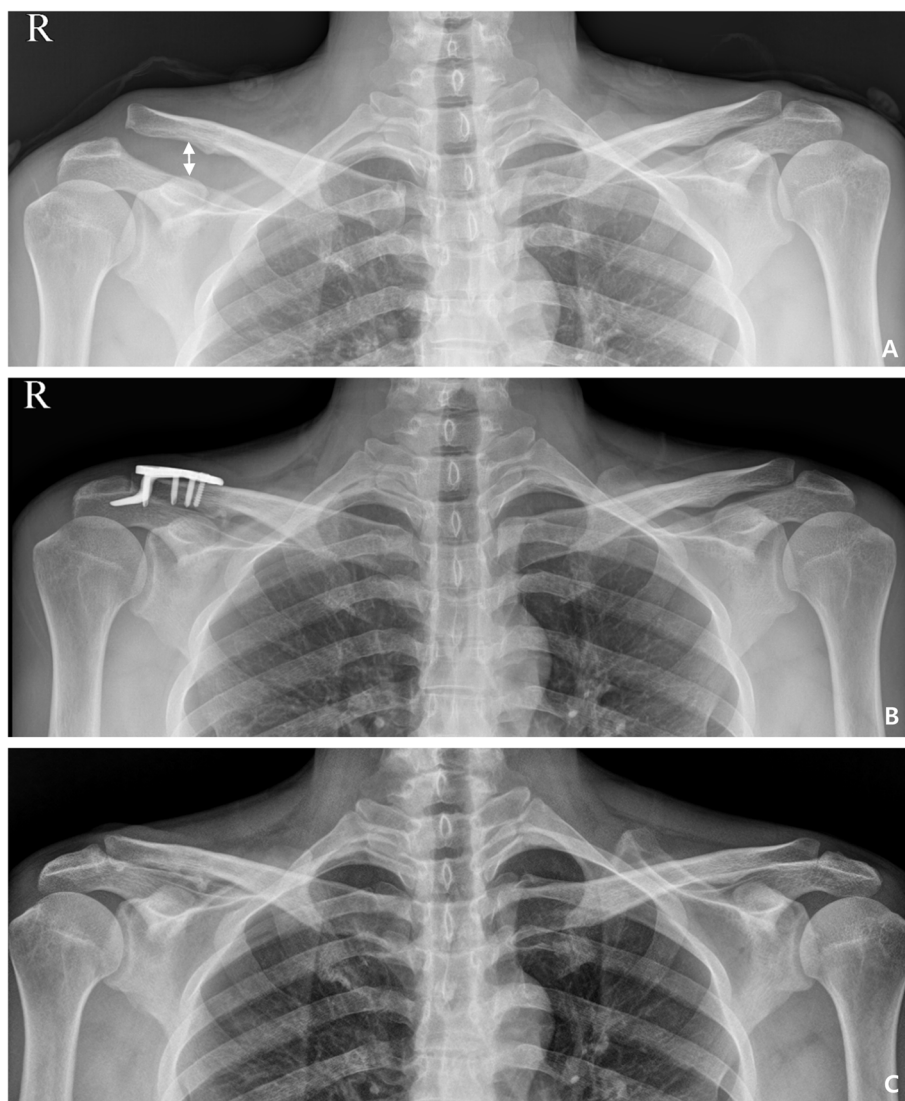
The coracoclavicular distance (CCD) of the injured and contralateral sides was evaluated by measuring the vertical distance between the upper border of the coracoid process and the lower end of the clavicle. This was done in the AP view of both shoulders at the final follow-up (Fig. 2). We considered subluxation when the CCD

increased from 50 to 100%. Dislocation was considered when the CCD was over 100% with respect to the contralateral side as assessed on final follow-up radiographs [10]. At the last follow-up, to compare CCDs, patients were divided into two groups according to the presence or absence of subacromial erosions. The CCDs were also compared in three groups divided according to subacromial erosion type. Additionally, we evaluated rotator cuff lesions using ultrasonography performed by a single orthopedic surgeon (MSK) at before surgery and the final follow-up.

All radiographic measurements were accurately assessed using a picture archiving and communication system (PACS; Maroview version 5.4; Marotech Inc.). Two orthopedic surgeons who were blinded to the surgical treatment performed the assessment.

#### Clinical evaluation

Clinical function was evaluated using the Constant-Murley score (CMS), Korean Shoulder score (KSS), range of motion (ROM), and visual analog scale (VAS) score. For the CMS, subjective and objective clinical outcomes were



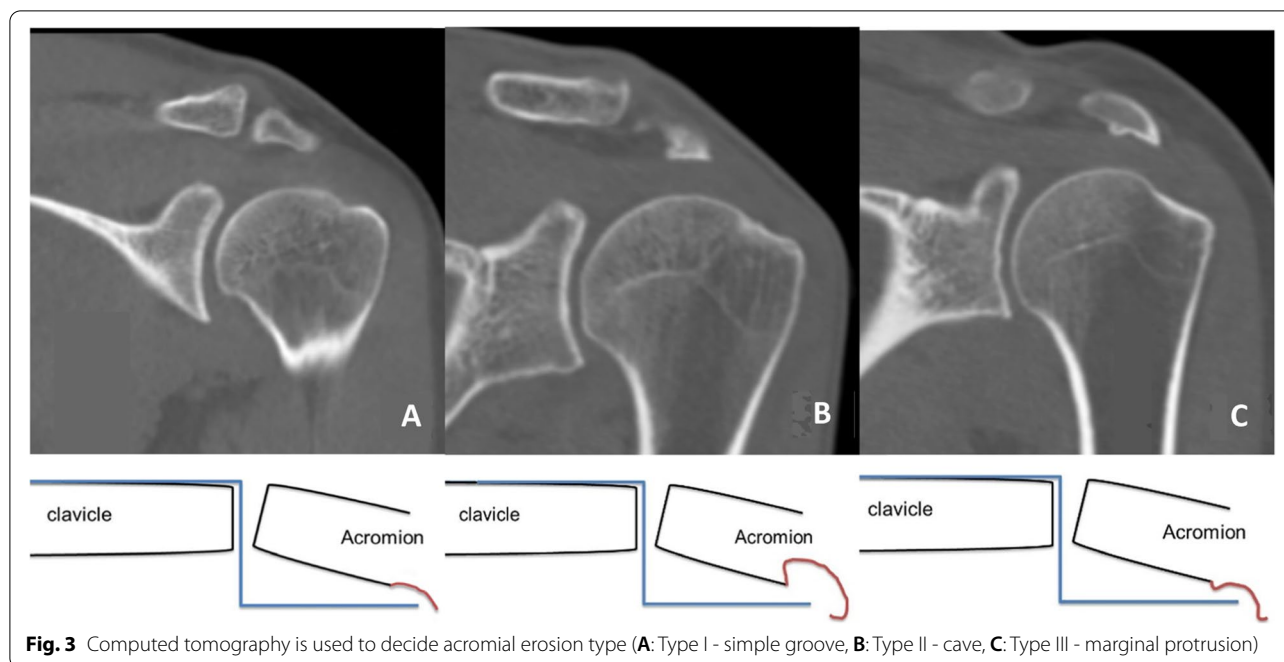
**Fig. 2** A 34-year-old male patient treated with hook plate fixation for acromioclavicular joint dislocation: (A) Preoperative (white arrow: coracoclavicular distance), (B) postoperative, and (C) last follow-up after implant removal

included with a maximum score of 100 points: pain, 15 points; activities of daily living, 20 points; ROM of the shoulder, 40 points; and muscle power, 25 points [6]. The KSS includes five domains totaling 100 points: function, 30 points; pain, 20 points; satisfaction, 10 points; ROM, 20 points; and muscle power, consisting of strength, 10 points; and endurance, 10 points [24]. The VAS was used to measure pain, with 0 indicating no pain and 10 indicating extremely severe pain. Measurements were performed at the final follow-up by an independent observer who was not involved in the study. An orthopedic surgeon who was not involved in the study measured the ROM using a full-circle manual goniometer.

**Statistical analyses**

Data were analyzed using SPSS Statistics for Windows, version 18.0 (SPSS Inc., Chicago, Ill., USA). A paired *t*-test was used to determine the significance of intergroup differences in clinical and radiological results between groups divided by the presence or absence of a subacromial erosion. Kruskal Wallis test was used to determine the significance of intergroup differences in clinical and radiological results between groups divided by subacromial erosion type. A *P*-value less than 0.05 was considered statistically significant.





**Fig. 3** Computed tomography is used to decide acromial erosion type (A: Type I - simple groove, B: Type II - cave, C: Type III - marginal protrusion)

**Results**

**Clinical and radiological outcomes**

Of the total ( $n=30$ ) patients, 18 showed subacromial erosion and 12 showed no subacromial erosion. Subacromial erosions were divided into three types according to shape: 13, 2, and 3 patients had subacromial erosions of types I, II, and III respectively.

Both groups showed significantly good clinical results. There were no significant differences in clinical results, including ROM, between the patients with and without subacromial erosions. Mean CCDs were also not significantly different at the final follow-up in patients with and without subacromial erosions. Further, there were no significant differences in the period from surgery to removal in both groups for patients with and without subacromial erosions (Table 1).

When the patients were divided into groups according to subacromial erosion shape, there were no significant differences in CMS, KSS, VAS score, ROM, and CCD between the groups (Table 2).

**Complications**

In patients with AC joint dislocations, 4 patients showed reduction loss (subluxation, 2; dislocation, 2; 13%), 1 patients showed shoulder stiffness, and 18 patients showed subacromial erosion, respectively, after implant removal. None of the patients had rotator cuff tears or scapular fractures at before surgery and final follow up.

**Table 1** Clinical and radiological outcomes compared between patients with and without subacromial erosion at final follow-up

	Subacromial erosion (n = 18)	No subacromial erosion (n = 12)	P-value
Removal time	4.61 ± 0.94	4.48 ± 1.33	0.771
Functional score			
CMS	96.72 ± 4.81	94.50 ± 5.52	0.252
KSS	97.06 ± 5.43	94.17 ± 5.18	0.157
VAS	0.94 ± 0.83	0.94 ± 0.58	0.717
Range of motion			
Forward elevation	154.44 ± 21.75	159.17 ± 14.43	0.515
Abduction	155.56 ± 21.75	153.33 ± 30.85	0.818
External rotation at side	63.33 ± 18.15	59.17 ± 7.93	0.462
CC distance (%)	26.05 ± 45.84	33.85 ± 48.23	0.658

CMS Constant-Murley score, KSS Korean Shoulder score, VAS visual analog score, CC coracoclavicular

**Discussion**

Many surgeries and different types of devices have been used to treat AC joint dislocations with varying outcomes. One of the surgical techniques that have proven to be effective in the treatment of AC joint dislocations is the use of a clavicle hook plate [7]. Hook plates are widely used as they enable secure fixation against rotational, horizontal, and vertical forces, as well as early motion [28]. Due to posterior displacement of the distal clavicle and severe superior displacement in type 4 and 5 injuries, respectively, most authors have suggested surgical

**Table 2** Clinical and radiological outcomes compared between groups divided according to acromion type at final follow-up

	Type I (Simple groove, n = 13)	Type II (Cave, n = 2)	Type III (Marginal protrusion, n = 3)	P-value
Functional score				
CMS	96.46 ± 5.55	97.00 ± 4.24	97.67 ± 1.15	0.933
KSS	96.31 ± 6.21	98.00 ± 2.83	99.67 ± 0.58	0.275
VAS	0.92 ± 1.04	1.50 ± 0.71	0.67 ± 0.58	0.335
Range of motion				
Forward elevation	152.31 ± 23.15	170.00 ± 14.14	153.33 ± 20.82	0.467
Abduction	151.54 ± 24.10	170.00 ± 14.14	163.33 ± 5.77	0.318
External rotation at side	58.46 ± 12.14	90.00 ± 0.00	66.67 ± 32.15	0.500
CC distance (%)	10.52 ± 17.23	93.91 ± 125.43	48.01 ± 36.27	0.096

CMS Constant-Murley score, KSS Korean Shoulder score, VAS visual analog score, CC coracoclavicular

treatment in these cases [3, 8, 20, 23, 29]. Yoon et al. [30] compared the clinical and radiological outcomes of 18 and 24 patients who underwent CC ligament reconstruction and hook plate fixation, respectively, for AC joint dislocation. Both groups achieved satisfactory clinical outcomes; however, maintenance of reduction indicated that hook plate fixation was a better treatment option. Similar to several previous studies, our study showed good clinical results after hook plate fixation in type 5 AC joint dislocations. In addition, radiological results, such as the CCD, at the final follow-up showed good outcomes.

Although the hook plate showed good clinical results, subacromial erosion was observed at a relatively high frequency after surgery [4, 10, 12]. Oh et al. reported that 38% (15/39) of patients treated for AC joint dislocations with hook plate fixation showed subacromial erosion [19]. Lee et al. reported that there were no significant differences in clinical and radiological results between patients with ( $n=18$ ) and without ( $n=34$ ) subacromial erosion after AC joint dislocation treatment with hook plate fixation [15]. Of the patients treated for AC joint dislocations (Rockwood type 5) with hook plate fixation in our study, 60% (18/30) showed subacromial erosion. However, both patients with and without subacromial erosions showed good clinical and radiological results. There were no significant differences in clinical results. Thus, although hook plate fixation of an AC joint dislocation can cause subacromial erosion, the resulting erosion does not significantly affect function, including pain.

This is the only study which has investigated whether subacromial erosion shape, evaluated by CT, affects clinical and radiological outcomes in patients treated with hook plate fixation. We hypothesized that if the subacromial erosion has a protruding shape, impingement of the rotator cuff can cause a rotator cuff lesion. Our study showed that there were no significant differences

in clinical and radiological results between the groups subdivided by subacromial erosion shape. Moreover, there were no rotator cuff lesions in any of the patients. Our study has some limitations, including its retrospective nature and small sample size. Additionally, long-term follow-up is required to evaluate the effect of the shape of the subacromial erosion on the rotator cuff. Not performing the dynamic US to check the subacromial impingement is also a limitation.

## Conclusions

Whether the shape of the subacromial erosion affects clinical outcomes and complications is unknown. Our study showed that the use of a clavicular hook plate is a good treatment option for AC joint dislocation. Subacromial erosion was a common finding after hook plate fixation in AC joint dislocation. However, the presence or absence of subacromial erosion did not affect functional outcomes at the final follow-up. Additionally, the shape of the subacromial erosion did not affect clinical and radiological results, nor the rotator cuff.

## Abbreviations

AC joint: Acromioclavicular; AP view: Anterior-posterior; CCD: Coracoclavicular distance; PACS: Picture archiving and communication system; CMS: Constant-Murley score; KSS: Korean Shoulder score; ROM: Range of motion; VAS: Visual analog scale.

## Acknowledgements

Not applicable.

## Authors' contributions

H.O., S.K. and J.H. contributed to the overall design and implementation of the study, analysis of the results, and drafting of the manuscript. M.K. and H.O. contributed to the overall design and management of the study and the analysis of the results. M.K., S.K. and H.O. contributed to the implementation of the experiments and analysis of the results. All authors have read and approved the final submitted manuscript.

**Funding**

None.

**Availability of data and materials**

The datasets used during the present study are available from the corresponding author on reasonable request.

**Declarations****Ethics approval and consent to participate**

This study was performed in line with the principles of the Declaration of Helsinki, and conducted with the approval of the institutional review board (IRB) of Chonnam National University Hospital. All methods were performed in accordance with the relevant guidelines and regulations. Written informed consent to participate was obtained from all the patients. No: CNUH-2020-383.

**Consent for publication**

The Consent for publication is not applicable for this study.

**Competing interests**

The authors declare that they have no competing interests.

Received: 19 August 2021 Accepted: 22 December 2021

Published online: 10 January 2022

**References**

- Allman FL Jr. Fractures and ligamentous injuries of the clavicle and its articulation. *J Bone Joint Surg Am.* 1967;49:774–84. <https://doi.org/10.2106/00004623-196749040-00024>.
- Bigliani LU, Ticker JB, Flatow EL, Soslowsky LJ, Mow VC. The relationship of acromial architecture to rotator cuff disease. *Clin Sports Med.* 1991;10:823–38. [https://doi.org/10.1016/S0278-5919\(20\)30586-X](https://doi.org/10.1016/S0278-5919(20)30586-X).
- Ceccarelli E, Bondi R, Alvititi F, Garofalo R, Miulli F, Padua R. Treatment of acute grade III acromioclavicular dislocation: a lack of evidence. *J Orthop Traumatol.* 2008;9:105–8. <https://doi.org/10.1007/s10195-008-0013-7>.
- Chiang CL, Yang SW, Tsai MY, Chen CKH. Acromion osteolysis and fracture after hook plate fixation for acromioclavicular joint dislocation: a case report. *J Shoulder Elb Surg.* 2010;19:e13–5. <https://doi.org/10.1016/j.jse.2009.12.005>.
- Cho NS, Bae SJ, Lee JW, Seo JH, Rhee YG. Clinical and radiological outcomes of modified Phemister operation with coracoclavicular ligament augmentation using suture anchor for acute acromioclavicular joint dislocation. *Clin Shoulder Elb.* 2019;22:93–9. <https://doi.org/10.5397/cise.2019.22.2.93>.
- Constant CR, Murley AHG. A clinical method of functional assessment of the shoulder. *Clin Orthop Relat Res.* 1987;214:160–4. <https://doi.org/10.1097/00003086-198701000-00023>.
- Dawood J, Hassan KS, Farid NM, Human SZ, Tahmineh M. Clinical and radiological results of fixation of acromioclavicular joint dislocation by hook plates retained for more than five months. *Trauma Mon.* 2014;19:e13728. <https://doi.org/10.5812/traumamon.13728>.
- Duan X, Zhang H, Zhang H, Wang Z. Treatment of coracoid process fractures associated with acromioclavicular dislocation using clavicular hook plate and coracoid screws. *J Shoulder Elb Surg.* 2010;19:e22–5. <https://doi.org/10.1016/j.jse.2009.09.004>.
- Epstein RE, Schweitzer ME, Frieman BG, Fenlin JM Jr, Mitchell DG. Hooked acromion: prevalence on MR images of painful shoulders. *Radiology.* 1993;187:479–81. <https://doi.org/10.1148/radiology.187.2.8475294>.
- Eschler A, Gradl G, Gierer P, Mittlmeier T, Beck M. Hook plate fixation for acromioclavicular joint separations restores coracoclavicular distance more accurately than PDS augmentation, however presents with a high rate of acromial osteolysis. *Arch Orthop Trauma Surg.* 2011;132:33–9. <https://doi.org/10.1007/s00402-011-1399-x>.
- Gilbert S, Andrea S, Roberto S. Clavicular hook plate for grade-III acromioclavicular dislocation. *J Orthop Surg (Hong Kong).* 2014;22:329–32. <https://doi.org/10.1177/230949901402200312>.
- Hoffler CE, Karas SG. Transacromial erosion of a locked subacromial hook plate: case report and review of literature. *J Shoulder Elb Surg.* 2010;19:e12–5. <https://doi.org/10.1016/j.jse.2009.10.019>.
- Jeong JY, Chun YM. Treatment of acute high-grade acromioclavicular joint dislocation. *Clin Shoulder Elb.* 2020;23:159–65. <https://doi.org/10.5397/cise.2020.00150>.
- Kim SJ, Kee YM, Park DH, Ko YI, Lee BG. Evaluation of the acromioclavicular joint morphology for minimizing subacromial erosion after surgical fixation of the joint using a clavicular hook plate. *Clin Shoulder Elb.* 2018;21:138–44. <https://doi.org/10.5397/cise.2018.21.3.138>.
- Lee SH, Kim JW, Kook SH. Clinical and radiological outcomes of acute acromioclavicular joint dislocation: comparison of hook plate fixation with single tight rope technique. *Clin Shoulder Elb.* 2017;20:153–61. <https://doi.org/10.5397/cise.2017.20.3.153>.
- Mazzocca AD, Arciero RA, Bicos J. Evaluation and treatment of acromioclavicular joint injuries. *Am J Sports Med.* 2007;35:316–29. <https://doi.org/10.1177/0363546506298022>.
- Min YK, Kim JH, Gwak HC. Clinical and radiological outcomes of hook plate fixation in the lateral end fracture of the clavicle and acromioclavicular dislocation. *Clin Shoulder Elb.* 2016;19:209–15. <https://doi.org/10.5397/cise.2016.19.4.209>.
- Morrison DS, Ofstein R. The use of magnetic resonance imaging in the diagnosis of rotator cuff tears. *Orthopedics.* 1990;13:633–7. <https://doi.org/10.3928/0147-7447-19900601-07>.
- Oh JH, Min S, Jung JW, Kim HJ, Kim JY, Chung SW, et al. Clinical and radiological results of hook plate fixation in acute acromioclavicular joint dislocations and distal clavicle fractures. *Clin Shoulder Elb.* 2018;21:95–100. <https://doi.org/10.5397/cise.2018.21.2.95>.
- Phillips AM, Smart C, Groom AF. Acromioclavicular dislocation: conservative or surgical therapy. *Clin Orthop Relat Res.* 1998;353:10–7.
- Rockwood CA Jr, Williams GR, Young DC. Disorders of the acromioclavicular joint. In: Rockwood CA, Masten II FA, editors. *The shoulder.* Philadelphia: Saunders; 1998. p. 483–553. ISBN No. 978-0721681344.
- Rockwood CA Jr, Williams GR, Young DC. Injuries of the acromioclavicular joint. In: Rockwood Jr CA, et al., editors. *Rockwood and Green's fractures in adults*, vol. ISBN No. 978-0397516025. 4th ed. Philadelphia: Lippincott-Raven; 1996. p. 1341–431.
- Spencer EE Jr. Treatment of grade III acromioclavicular joint injuries: a systematic review. *Clin Orthop Relat Res.* 2007;455:38–44. <https://doi.org/10.1097/BLO.0b013e318030df83>.
- Tae SK, Rhee YG, Park TS, Lee KW, Park JY, Choi CH, et al. The development and validation of an appraisal method for rotator cuff disorders: the Korean shoulder scoring system. *J Shoulder Elb Surg.* 2009;18:689–96. <https://doi.org/10.1016/j.jse.2008.11.019>.
- Tossy JD, Mead NC, Sigmund HM. Acromioclavicular separations: useful and practical classification for treatment. *Clin Orthop Relat Res.* 1963;28:111–9.
- van der Meijden OA, Gaskill TR, Millett PJ. Treatment of clavicle fractures: current concepts review. *J Shoulder Elb Surg.* 2012;21:423–9. <https://doi.org/10.1016/j.jse.2011.08.053>.
- Venjakob AJ, Salzmänn GM, Gabel F, et al. Arthroscopically assisted 2-bundle anatomic reduction of acute acromioclavicular joint separations: 58-month findings. *Am J Sports Med.* 2013;41:615–21.
- Walz L, Salzmänn GM, Fabbro T, Eichhorn S, Imhoff AB. The anatomic reconstruction of acromioclavicular joint dislocations using 2 TightRope devices: a biomechanical study. *Am J Sports Med.* 2008;36:2398–406. <https://doi.org/10.1177/0363546508322524>.
- Yoon JP, Lee BJ, Nam SJ, Chung SW, Jeong WJ, Min WK, et al. Comparison of results between hook plate fixation and ligament reconstruction for acute unstable acromioclavicular joint dislocation. *Clin Orthop Surg.* 2015;7:97–103. <https://doi.org/10.4055/cios.2015.7.1.97>.
- Yoon JP, Lee YS, Song HS, Oh JH. Morphological analysis of acromion and hook plate for the fixation of acromioclavicular joint dislocation. *Knee Surg Sports Traumatol Arthrosc.* 2017;25:980–6. <https://doi.org/10.1007/s00167-016-3987-3>.

**Publisher's Note**

Springer Nature remains neutral with regard to jurisdictional claims in published maps and institutional affiliations.